

UCLA

UCLA Previously Published Works

Title

A case of difficult epicardial access for ablation of ventricular tachycardia

Permalink

<https://escholarship.org/uc/item/72s243xs>

Journal

Journal of Atrial Fibrillation, 6(6)

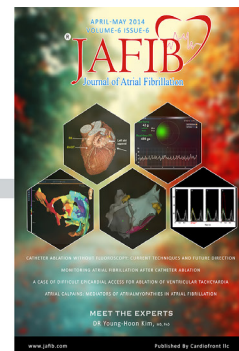
Authors

Stevens, SM
Tung, R
Shivkumar, K
et al.

Publication Date

2014

Peer reviewed



A Case Of Difficult Epicardial Access For Ablation Of Ventricular Tachycardia

Steven M. Stevens, MD, Roderick Tung, MD, Kalyanam Shivkumar, MD, PhD, Jason S. Bradfield, MD

UCLA Cardiac Arrhythmia Center, Ronald Reagan UCLA Health System, David Geffen School of Medicine at UCLA, Los Angeles, CA.

Abstract

We present a case of a 67-year-old patient with nonischemic cardiomyopathy and recurrent sustained ventricular tachycardia of epicardial origin referred for ablation. Due to two previous episodes of cardiac tamponade secondary to implantable cardioverter-defibrillator lead perforation at the time of device implant, the patient had significant pericardial adhesions making epicardial access and ablation challenging.

Case

We present a 67-year-old man with nonischemic cardiomyopathy (NICM), ejection fraction (EF) 20%, New York Heart Association class II congestive heart failure, and dual chamber implantable cardioverter-defibrillator (ICD) initially implanted for primary prevention in 2008. The previous ICD placement was complicated by lead perforation of the right ventricle (RV) with cardiac tamponade and the need for pericardiocentesis, which had been performed twice during that hospitalization.

The patient experienced recurrent ventricular tachycardia (VT) in 2009 and was referred for endocardial VT ablation at an outside hospital, which was unsuccessful. The patient continued to experience recurrent ICD shocks despite beta blockers and amiodarone therapy. He was initially referred to our institution for VT ablation after receiving three ICD shocks for monomorphic VT (cycle length (CL) 400–420ms). Only intracardiac electrograms were available for review prior to the procedure.

During the initial ablation procedure, noninvasive programmed stimulation (NIPS) was performed and the induced VT was thought to be originating from the basal infero-lateral left ventricle (LV), CL 496 ms, with a Q wave in lead I, superior axis, and positive concordance in precordium (FIGURE 1). The tachycardia met criteria suggestive of an epicardial exit based on QRS duration 253 ms, Q wave in lead I, pseudo-delta of 80 ms (>34ms) and intrinsicoid deflection of 106 ms (>85 ms), although the Maximum Deflection

Index (MDI) at 0.41 was <0.55.^{1,2}

Given the previous failed endocardial ablation, the NICM substrate, and the ECG criteria consistent with an epicardial exit, the decision was made to attempt percutaneous epicardial access using techniques originally described by Sosa et al. in 1996.³ Epicardial access was difficult and there was evidence of RV perforation and possible intramyocardial hematoma formation. (FIGURE 2) The decision was made not to attempt endocardial ablation with concern that systemic heparinization could extend the possible intramyocardial hematoma and the procedure was aborted. The patient was discharged on amiodarone and beta blockers with a plan to reschedule for ablation in one month.

Due to insurance issues, the patient was unable to return for repeat procedure for an extended period of time, during which he experienced multiple ICD shocks. One year later, the patient returned after experiencing VT storm with 18 ICD shocks secondary to monomorphic VT, CL 400–410 ms. The patient was transferred back to our facility from an outside hospital and taken to the electrophysiology lab for a second attempt at VT ablation. The VT induced by NIPS again had an apparent epicardial origin, but likely from a more inferior exit [positive concordance and superior axis, QRS 296 ms, pseudo-delta 181ms (>34 ms), intrinsicoid deflection 181 ms, (>85 ms) and MDI of 0.71 (>0.55)]. Since the patient had known difficult epicardial access, the decision was made to attempt endocardial ablation first and then decide whether repeat percutaneous epicardial access and ablation should be attempted versus a staged approach with plan for surgical hybrid epicardial ablation.

On endocardial mapping via a transseptal approach, scar was seen in the basal inferior and basal anterior LV but no late potentials or pacemaps matches were seen. Therefore, the decision was made to reverse anticoagulation with protamine and then attempt

Disclosures:
None.

Corresponding Author:
Jason S. Bradfield, MD
David Geffen School of Medicine at UCLA
100 UCLA Medical Plaza, Suite 660
Los Angeles CA 90095-1679

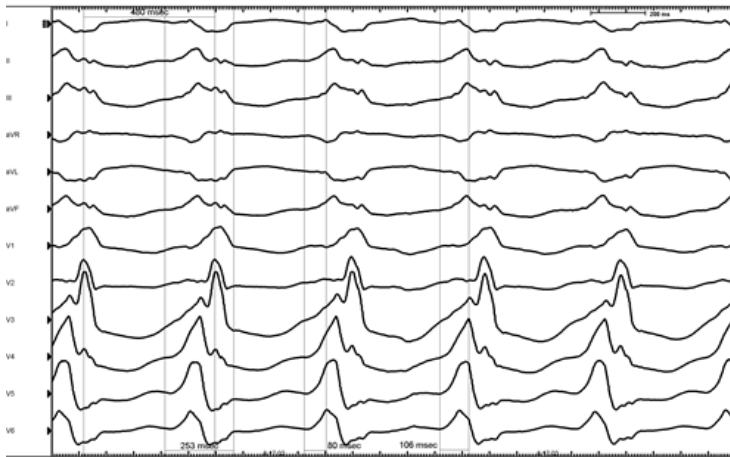


Figure 1: Noninvasive programmed stimulation induced ventricular tachycardia originating from the basal lateral LV with a QRS duration of 253 ms, cycle length 496 ms, with a Q wave in lead I, superior axis, and positive concordance in precordium. The pseudodelta was 80 ms and intrascoid deflection was 106 ms, consistent with an epicardial exit.

percutaneous epicardial access again, with hybrid surgical exposure as a backup plan.

Using a Tuohy needle (Havel's Inc, OH; BD Medical, NJ) epicardial access was attempted using a posterior approach. With the posterior approach it was difficult to determine the location of the advancing J-wire due to adhesions and therefore a decision was made to use an anterior approach instead, utilizing a micropuncture kit (Cook Medical, Bloomington, IA). After cardiac pulsations were felt and the pericardium was punctured, it remained difficult to pass the wire into the pericardium, so a contrast pericardiogram was performed via a 5 french soft-tipped dilator (FIGURE 3A and 3C). Significant adhesions were observed. Enough wire was able to be passed into the pericardium (FIGURE 3B) to allow for an 8 French SLO sheath (St. Jude Medical, Inc., Minnetonka, MN) to be placed in the pericardium, but mobility was severely limited due to adhesions.

Therefore, double-epicardial access was obtained by double wiring the SLO sheath. Using an exchange guidewire technique, an Agilis sheath (St. Jude Medical, Inc., Minnetonka, MN) and the SLO sheath were placed in the pericardium.⁴ A duodecapolar catheter was used to further manually disrupt adhesions, but there was not complete exposure of the entire epicardial surface (FIGURE 3D). After disrupting as many adhesions as possible, the duodecapolar catheter was used as a guide for ablation. Late potentials and scar

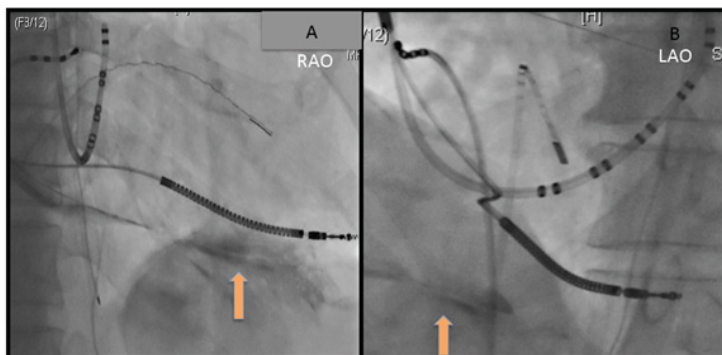


Figure 2: RAO (A) and LAO (B) fluoroscopy images demonstrating possible intramyocardial hematoma (arrows) from the initial pericardial access attempt.

were observed on the basal anterior lateral and inferior left ventricle with good pacemaps with an 11 of 12 match for the targeted VT from a wide area with split and late potentials in sinus rhythm. However, not all regions of the epicardial ventricular surface could be mapped due to persistent adhesions. (FIGURE 4). The corresponding endocardial surface did not demonstrate late potentials or promising pacemaps that matched the VT further confirming that endocardial ablation would be of little benefit. The VT was then reinduced to look for mid-diastolic activity, but was not tolerated hemodynamically and DC cardioversion was required before further mapping could be performed.

Extensive substrate modification on the epicardial surface was performed for a total of over 40 minutes of radiofrequency energy delivery through an irrigated 3.5 mm ablation catheter (Thermocool, Biosense Webster, Diamond Bar, CA). All late potentials that were seen and accessible were eliminated. After substrate modification, the VT was reinduced with a longer TCL (504ms) with a slight morphologic variation from the targeted VT. Further substrate modification on the epicardium in the same regions as before was performed until the VT was no longer inducible with triple extrastimuli.

The patient had recurrent VT one week after the procedure and was referred for bilateral stellate ganglionectomy, and has been observed for over 6 months without recurrent ICD therapies. He developed amiodarone induced thyrotoxicosis approximately four months after the ablation and did not have any arrhythmia during that time, even after amiodarone was discontinued.

Discussion

Percutaneous pericardial access using a subxiphoid approach for electroanatomical mapping and ablation of VT was first described

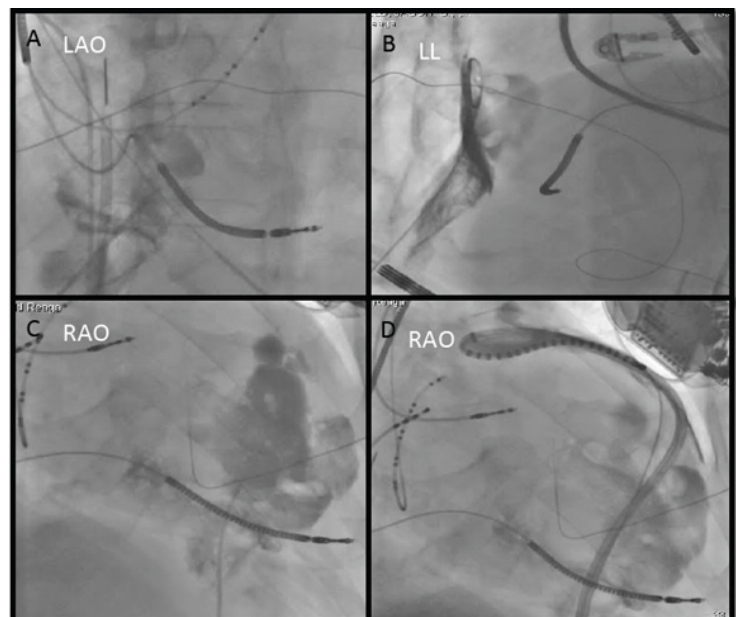


Figure 3: Fluoroscopy of difficult epicardial access with significant adhesions seen on pericardiogram. A: initial pericardial access in LAO projection with adhesions seen on inferior border of heart. B: Lateral projection with guide wire along anterior wall of heart and significant adhesions observed. C: RAO projection with pericardiogram showing multiple adhesions along the anterior right ventricle. D: RAO projection with duodecapolar catheter wrapped around lateral heart border and prolapsed while attempting to lyse adhesions.

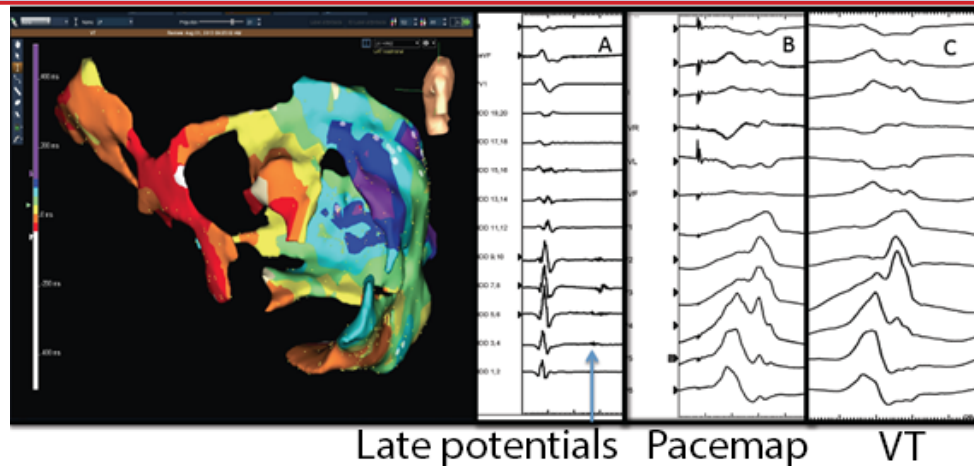


Figure 4:

Epicardial late activation map in sinus rhythm demonstrating areas of late potentials and potential targets for ablation. A: Late potentials (arrow) in sinus rhythm.

the Sosa and his colleagues in 1996 to treat patients with Chagas cardiomyopathy.³ Potential complications include right ventricular puncture, cardiac tamponade, intramyocardial hematoma, coronary laceration, fluoro-pericardial fistula, bowel perforation, liver laceration, phrenic injury, and diaphragm injury.⁵ The overall complication rate in a case series by Sacher et al. of 136 epicardial ablations was 5% for acute complications, and 2% for delayed complications, with tamponade the most common complication.⁶

Adhesions pose a significant risk to epicardial access and ablation. Patients with prior epicardial access, pericarditis and prior cardiothoracic surgery are at the highest risk for adhesion formation. Patients with previous cardiothoracic surgery with bypass grafts or previous valve surgery that require epicardial mapping and ablation necessitate a hybrid surgical approach for access.⁷ For patients with previous epicardial access and suspected adhesion, but without previous cardiac surgery, the approach is less clear.

Pericardial adhesions limit the mobility of catheter movement on the epicardial surface of the heart and unless the adhesions are broken up with direct manipulation of the catheter, some areas key for mapping and ablation may not be reached. Adhesion lysis with blunt dissection through catheter manipulation increases bleeding risk and this needs to be considered carefully. One technique used in this case was to manually disrupt the adhesions with the use of an Agilis steerable sheath in combination with a deflectable decapolar catheter. Deflectable sheaths have been demonstrated to be highly effective in mapping the epicardium in general.⁴ In a case series at the University of Pennsylvania, 10 patients with prior pericarditis (n=2) or non bypass graft cardiac surgery (n=8) underwent VT ablation with percutaneous epicardial access.⁸ Lysis of adhesions was performed by manipulating deflectable ablation catheters, deflectable sheaths, or multipolar mapping catheters using the curved surface of the catheter to lyse adhesions with direct blunt force. This is similar to the technique used in our case. In their series, only one patient required a subxiphoid window to be placed surgically to allow for appropriate epicardial access to the inferior wall of the heart. There was one right ventricular puncture, and no cases of severe bleeding, cardiac tamponade, or death. While this small study demonstrated the feasibility of such a technique in highly experienced hands, we believe it should be interpreted with caution especially with less experienced operators.

A variety of techniques are available to minimize pericardial

access risk in general, however none are specific in the case of known adhesions. A fiber-optic pressure sensor on the tip of the needle is under development, but human data is limited.⁹ Additionally, endoscopic video-guided pericardiocentesis techniques are in development.¹⁰ Our group has described incorporation of electroanatomic mapping systems into epicardial access. In this technique the Tuohy needle is attached to an alligator clip to allow it to be sensed as a catheter on the mapping system. This technique was applied to 8 consecutive patients, all of which achieved successful epicardial access from the subxiphoid approach, but 1 of the 8 did have RV puncture.¹¹

Indications for epicardial access for mapping and ablation of VT are expanding. Patients with prior epicardial access or prior pericarditis are increasingly being referred for epicardial mapping and ablation. A percutaneous subxiphoid approach has been used safely in experienced centers in these cases, but the overall number of cases still remains low, so it is difficult to assess the relative increased risk that adhesions may pose.

Conclusions:

In the case above, although epicardial access was achieved successful without morbidity, there was limited access to all surfaces of the heart, and the VT recurred leading to a referral for stellate ganglionectomy. Having a cardiothoracic surgery team available for possible thoracotomy and hybrid ablation is important in centers attempting such complex cases. Most importantly, higher risk cases such as those with adhesions should only be done at experienced centers well versed in pericardial interventions. Certainly, if done with minimal bleeding, percutaneous access to the epicardium offers patients a lower morbidity option to epicardial access compared to surgical thoracotomy. However, all options must be available and the case should be discussed within an experienced multidisciplinary team to give the patient the highest likelihood of a successful procedure.

References:

1. Berruezo A, Mont L, Nava S, Chueca E, Bartholomay E, Brugada J. Electrocardiographic recognition of the epicardial origin of ventricular tachycardias. *Circulation* 2004;109:1842-1847.
2. Valles E, Bazan V, Marchlinski FE. Ecg criteria to identify epicardial ventricular tachycardia in nonischemic cardiomyopathy. *Circ Arrhythm Electrophysiol* 2010;3:63-71.
3. Sosa E, Scanavacca M, d'Avila A, Pilleggi F. A new technique to perform epicardial mapping in the electrophysiology laboratory. *J Cardiovasc Electrophysiol*

1996;7:531-536.

4. Mizuno H, Maccabelli G, Della Bella P. The utility of manually controlled steerable sheath in epicardial mapping and ablation procedure in patients with ventricular tachycardia. *Europace* 2012;14 Suppl 2:ii19-ii23.
5. Boyle NG, Shivkumar K. Epicardial interventions in electrophysiology. *Circulation* 2012;126:1752-1769.
6. Sacher F, Roberts-Thomson K, Maury P, Tedrow U, Nault I, Steven D, Hocini M, Koplan B, Leroux L, Derval N, Seiler J, Wright MJ, Epstein L, Haissaguerre M, Jais P, Stevenson WG. Epicardial ventricular tachycardia ablation a multicenter safety study. *J Am Coll Cardiol* 2010;55:2366-2372.
7. Michowitz Y, Mathuria N, Tung R, Esmailian F, Kwon M, Nakahara S, Bourke T, Boyle NG, Mahajan A, Shivkumar K. Hybrid procedures for epicardial catheter ablation of ventricular tachycardia: Value of surgical access. *Heart Rhythm* 2010;7:1635-1643.
8. Tschabrunn CM, Haqqani HM, Cooper JM, Dixit S, Garcia FC, Gerstenfeld EP, Callans DJ, Zado ES, Marchlinski FE. Percutaneous epicardial ventricular tachycardia ablation after noncoronary cardiac surgery or pericarditis. *Heart Rhythm* 2013;10:165-169.
9. Tucker-Schwartz JM, Gillies GT, Mahapatra S. Improved pressure-frequency sensing subxiphoid pericardial access system: Performance characteristics during in vivo testing. *IEEE Trans Biomed Eng* 2011;58:845-852.
10. Nazarian S, Kantsevov SV, Zviman MM, Matsen FA, 3rd, Calkins H, Berger RD, Halperin HR. Feasibility of endoscopic guidance for nonsurgical transthoracic atrial and ventricular epicardial ablation. *Heart Rhythm* 2008;5:1115-1119.
11. Bradfield JS, Tung R, Boyle NG, Buch E, Shivkumar K. Our approach to minimize risk of epicardial access: Standard techniques with the addition of electroanatomic mapping guidance. *J Cardiovasc Electrophysiol* 2013;24:723-727.