

UC Irvine

UC Irvine Previously Published Works

Title

Perfusion Assessment in Laparoscopic Left-Sided/Anterior Resection (PILLAR II): A Multi-Institutional Study

Permalink

<https://escholarship.org/uc/item/7267v6m1>

Journal

Journal of the American College of Surgeons, 220(1)

ISSN

1072-7515

Authors

Jafari, Mehraneh D
Wexner, Steven D
Martz, Joseph E
et al.

Publication Date

2015

DOI

10.1016/j.jamcollsurg.2014.09.015

Peer reviewed

Perfusion Assessment in Laparoscopic Left-Sided/Anterior Resection (PILLAR II): A Multi-Institutional Study



Mehraneh D Jafari, MD, Steven D Wexner, MD, FACS, Joseph E Martz, MD, FACS, Elisabeth C McLemore, MD, FACS, David A Margolin, MD, FACS, Danny A Sherwinter, MD, FACS, Sang W Lee, MD, FACS, Anthony J Senagore, MD, FACS, Michael J Phelan, PhD, Michael J Stamos, MD, FACS

BACKGROUND: Our primary objective was to demonstrate the utility and feasibility of the intraoperative assessment of colon and rectal perfusion using fluorescence angiography (FA) during left-sided colectomy and anterior resection. Anastomotic leak (AL) after colorectal resection increases morbidity, mortality, and, in cancer cases, recurrence rates. Inadequate perfusion may contribute to AL. The PINPOINT Endoscopic Fluorescence Imaging System allows for intraoperative assessment of anastomotic perfusion.

STUDY DESIGN: This is a prospective, multicenter, open-label, clinical trial that assessed the feasibility and utility of FA for intraoperative perfusion assessment during left-sided colectomy and anterior resection at 11 centers in the United States.

RESULTS: A total of 147 patients were enrolled, of whom 139 were eligible for analysis. Diverticulitis (44%), rectal cancer (25%), and colon cancer (21%) were the most prevalent indications for surgery. The mean level of anastomosis was 10 ± 4 cm from the anal verge. Splenic-flexure mobilization was performed in 81% and high ligation of the inferior mesenteric artery in 61.9% of patients. There was a 99% success rate for FA, and FA changed surgical plans in 11 (8%) patients, with the majority of changes occurring at the time of transection of the proximal margin (7%). Overall morbidity rates were 17%. The anastomotic leak rate was 1.4% ($n = 2$). There were no anastomotic leaks in the 11 patients who had a change in surgical plan based on intraoperative perfusion assessment with FA.

CONCLUSIONS: PINPOINT is a safe and feasible tool for intraoperative assessment of tissue perfusion during colorectal resection. There were no anastomotic leaks in patients in whom the anastomosis was revised based on inadequate perfusion with FA. (*J Am Coll Surg* 2015;220:82–92. © 2015 by the American College of Surgeons. Published by Elsevier Inc. This is an open access article under the CC BY-NC-SA license [<http://creativecommons.org/licenses/by-nc-sa/3.0/>].)

Novel technologic advances, better understanding of physiology, and improved surgical technical skills allow surgeons to offer patients better outcomes after colorectal

resections with primary anastomosis.¹⁻³ For example, over the past 2 decades, long-term oncologic outcomes of rectal cancer have improved as a result of improved

Disclosure Information: Drs Wexner, McLemore, Sherwinter, and Stamos are paid consultants and speakers for Novadaq Technologies Inc. The study is fully funded by Novadaq Technologies Inc. All other authors have nothing to disclose.

Disclosures outside the scope of the current work: Dr Lee provided expert testimony for Covidien and is paid as a speaker by Applied Medical; Dr McLemore is a paid consultant for Covidien and Intuitive Surgical, received grants from Applied Medical, Covidien, and Stryker, received pay as a speaker for Applied Medical, Ethicon EndoSurgery, Cubist, Genomic Health, Covidien, and Novadaq, and owns stock in Cubist.

Received May 31, 2014; Revised September 11, 2014; Accepted September 11, 2014.

From the Departments of Surgery, University of California, Irvine Medical Center, Orange, CA (Jafari, Phelan, Stamos); Beth Israel Medical Center, New York, NY (Martz); University of California San Diego Medical Center, La Jolla, CA (McLemore); Maimonides Medical Center, Brooklyn, NY (Sherwinter); New York Presbyterian Hospital, Weill Cornell Medical Center, New York, NY (Lee); the Department of Colorectal Surgery, Cleveland Clinic Florida, Weston, FL (Wexner); the Department of Colon and Rectal Surgery, Ochsner Clinic Foundation, New Orleans, LA (Margolin); and Surgical Disciplines, Central Michigan University, College of Medicine, Saginaw, MI (Senagore).

Correspondence address: Michael J Stamos, MD, FACS, Department of Surgery, University of California, Irvine, 333 City Blvd. West Suite 1600, Orange, CA 92868. email: mstamos@uci.edu

Abbreviations and Acronyms

FA = fluorescence angiography
 ICG = indocyanine green
 IMA = inferior mesenteric artery
 NIR = near infrared
 VIS = visible

surgical technique and neoadjuvant treatment. Advances in surgical technique, technology, and neoadjuvant treatments currently allow surgeons to create lower anastomoses as an alternative to permanent colostomies.¹⁻³ However, anastomotic leak after colorectal resection increases morbidity, mortality, and, in patients with rectal cancer, local recurrence rates.^{4,5} The reported rate of anastomotic leak after colorectal surgery ranges from 3% to 20%.⁶⁻⁹ However, recent large randomized controlled trials¹⁰ and cohort comparison studies¹¹ have shown leak rates after rectal anastomosis of 11% to 15%. Morbidity related to an anastomotic leak can be substantial, with an increased associated mortality of 6% to 22%.^{9,12}

Anastomotic leak can be attributed to patient risk factors, technical factors, and blood supply of the distal and/or proximal segments of bowel. Literature has identified male sex, level of anastomosis, tobacco use, preoperative radiation, and the presence of adverse intraoperative events as markers of high-risk anastomoses.^{3,5,13-15} However, perfusion abnormalities and anastomotic technique are the 2 most commonly invoked factors having significant impact on the healing of an anastomosis.^{4,16-19}

We hypothesized that assessment of microperfusion at the time of the creation of an anastomosis may influence the rate of anastomotic leak. Therefore, a technology that would accurately predict perfusion may potentially improve outcomes. Fluorescence angiography has been shown to be an accurate tool for assessing microperfusion and has been associated with improved outcomes in hepatobiliary, foregut, transplant, and plastic surgery.²⁰⁻²⁶ Therefore, we proposed a multicenter, open label clinical trial to demonstrate the utility and feasibility of intraoperative perfusion assessment using near infrared (NIR) indocyanine green (ICG)-induced fluorescence angiography at the time of anastomosis creation.

METHODS

This was a multicenter prospective, open label clinical trial. Participating institutions were Beth Israel Medical Center, New York, NY; Cleveland Clinic Florida, Weston, FL; Maimonides Medical Center, Brooklyn, NY; Mayo Clinic, Rochester, MN; New York Presbyterian Hospital, Weill Cornell Medical Center, New York, NY; Ochsner Clinic Foundation, New Orleans, LA; Surgical Disciplines,



Figure 1. PINPOINT Endoscopic Fluorescence Imaging System (Novadaq). (Reprinted from Novadaq Technologies Inc, with permission.)

Central Michigan University, College of Medicine, Saginaw, MI; University of California, Irvine Medical Center, Orange, CA; University of California San Diego Medical Center, La Jolla, CA; University of California San Francisco Medical Center, San Francisco, CA; University Hospitals-Case Medical Center, Cleveland, OH. A total of 26 surgeons participated in the trial.

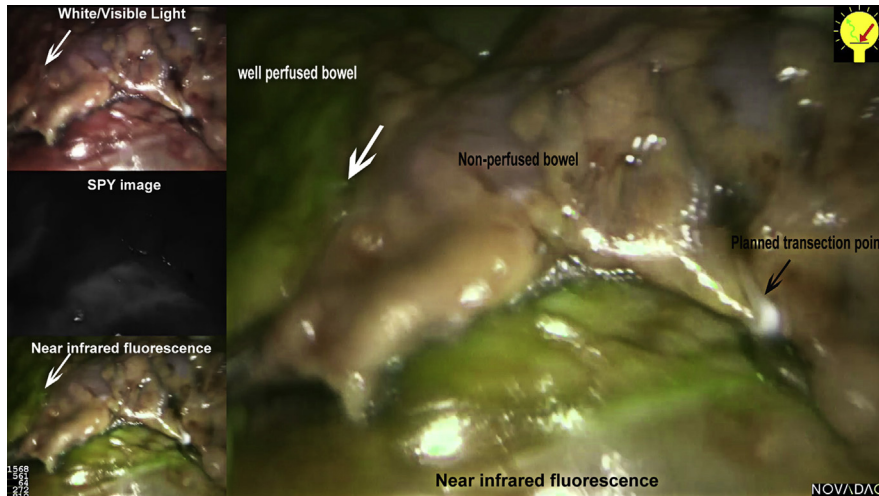


Figure 2. Proximal colonic point of transection was marked by a surgical clip under white/visible light. (Reprinted from Novadaq Technologies Inc, with permission.)

The study was conducted in accordance with the ethical principles of the Declaration of Helsinki (Edinburgh 2000), and Institutional Review Board approval was obtained by all institutions. Informed consent was obtained for all subjects. Patients were eligible for enrollment if they were over 18 years old and were scheduled for a laparoscopic left colectomy or anterior resection with a planned anastomosis located 5 to 15 cm from the anal verge. Patients with a history of adverse reaction or known allergy to ICG, iodine, or iodine dyes were not eligible. Pregnant and/or lactating patients were excluded.

Subjects received a baseline assessment. Demographics including age, sex, ethnicity or race, body mass index, American Society of Anesthesiologist class, preoperative diagnosis, history of preoperative chemotherapy (<90 days from day of operation) and radiotherapy, history of smoking or alcohol use, and complete medical history were collected.

During the surgical procedure, the PINPOINT Endoscopic Fluorescence Imaging System (Novadaq) (Fig. 1) was used to assess perfusion of colonic tissue at 2 critical steps of the operation: the planned point of proximal transection just before bowel resection and completion

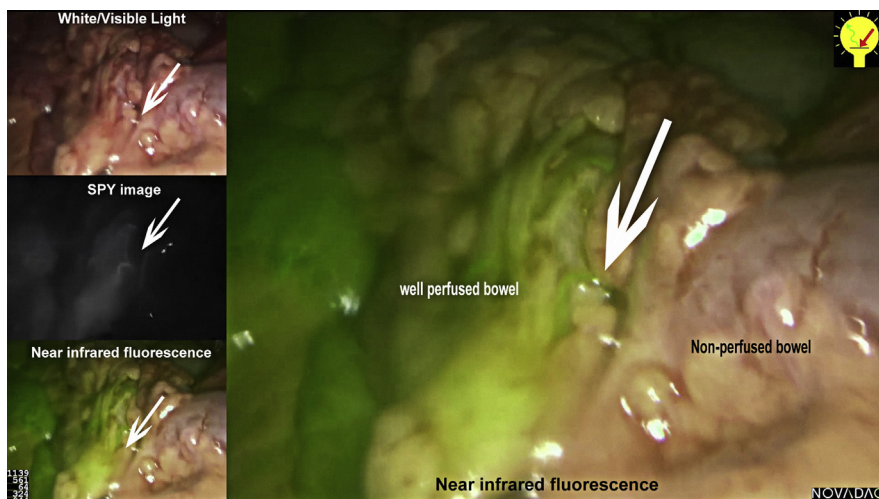


Figure 3. Perfusion of the planned transection point was visualized via fluorescence angiography. The line of demarcation between perfused and nonperfused tissue was noted and compared with the initial planned transection point. The bowel was transected at an area of well-perfused tissue. White arrow points to the line of demarcation between well-perfused and nonperfused bowel. (Reprinted from Novadaq Technologies Inc, with permission.)

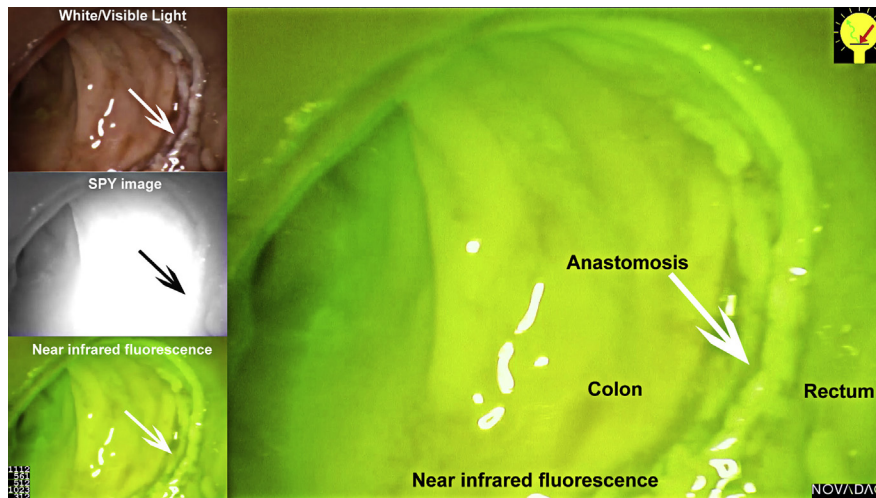


Figure 4. Fluorescence angiography of the completed anastomosis. (Reprinted from of Novadaq Technologies Inc, with permission.)

of the anastomosis (“baseline image”), and after completion of the anastomosis, when the integrity of the mucosal aspect of the completed anastomosis was assessed via proctoscopy. The protocol allowed for the surgical technique to otherwise be performed according to each surgeon’s standard practice, including the surgeon’s standard practice for assessing perfusion. The surgical plan (site of resection or anastomoses and plan for diversion) was documented before fluorescence angiography. Operative factors included planned surgical procedure, ostomy diversion plan and use, type and level of anastomosis, operative time, level of inferior mesenteric artery (IMA) ligation, splenic flexure mobilization, number of linear staple firings used to transect the proximal and distal bowel, and use of a pelvic drain, and all were recorded. Any revisions to the surgical plan were documented. All of the techniques mentioned above were left to the discretion of the attending surgeon. Ligation of the inferior mesenteric artery proximal to the left colic vessels was labeled as “high,” just distal to the left colic vessels as “mid,” and at the level of the colon marginal vessels as “low.” Anastomotic height was measured and was considered “low-risk” if located 10 to 15 cm and “high-risk” if located 5 to 10 cm from the dentate line. High-risk anastomosis also included patients with a history of pelvic radiation.

For the initial “baseline image” assessment, the planned point of proximal colon transection was marked by the surgeon, typically with a clip or by marking via an instrument, under white or visible light before imaging with PINPOINT (Fig. 2). This perfusion was performed after mobilization of the bowel, transection of the rectum, division of the rectal and colon mesentery and central vessels, before specimen

extraction or resection and creation of the anastomosis. This site was selected by the surgeon using his or her best judgment and typical standard of care assessment. After this selection, the anesthesiologist administered a bolus of 3.75 to 7.5 mg ICG intravenously. Perfusion of the colon was visualized and assessed via fluorescence angiography and the line of demarcation between perfused and nonperfused tissue was noted and compared with the initial planned transection point (Fig. 3). The colon was then divided within an area of well-perfused tissue (Video 1, online). Perfusion of the planned transection margin was assessed as inadequate, adequate, or optimal, and the impact of the perfusion assessment with fluorescence angiography was documented as “change” or “no change” to the resection margin. When a case required conversion to open, the laparoscope could be used to image the segment of bowel extracorporeally. Whether patients were imaged after conversion was left to the discretion of the surgeon. All converted cases that were not imaged were excluded from final analysis. All robotic cases were hybrid in nature and PINPOINT was used during the laparoscopic portion of the case.

After completion of the anastomosis (end-to-side or end-to-end, according to surgeon preference and standard practice), a standard air leak test was performed. Any leaks were documented and managed according to each individual surgeon’s standard of care. After the air leak test, perfusion of the completed anastomosis was assessed with fluorescence angiography. The PINPOINT endoscope was inserted into the anus using a disposable introducer and advanced to the staple line of the anastomosis under visible or white light guidance. A second bolus of 3.75 to 7.5 mg of ICG was administered intravenously. Real-time perfusion of both proximal and distal aspects

of the anastomosis was assessed as inadequate, adequate, or optimal, and any change to the surgical plan based on fluorescence angiography of the anastomosis was documented (Fig. 4). These included any revision to the anastomosis, and/or a change in the decision to perform a protective ostomy.

The primary end points were the feasibility and safety of fluorescence angiography during low anterior resection and left colectomy. The incidence of use of fluorescence angiography to aid in surgical decision-making was measured. The number of cases in which the planned location of resection margin of the colon or rectum and/or revision of the anastomosis changed due to perfusion assessment was recorded. Any change in decision to divert was also recorded. The incidence of successful imaging and assessment of perfusion of the planned resection margins based on the ability to obtain images that allowed adequate perfusion assessment, and the incidence of successful imaging and assessment of the completed anastomosis based on the ability to obtain images that allowed for adequate perfusion assessment were also evaluated.

Secondary endpoints included clinical outcomes of the procedures performed. The incidence of major postoperative clinical complications with a minimum 30-day postprocedure follow-up was collected. Major postoperative clinical complications included clinically evident anastomotic leak, radiologic anastomotic leak (when prompted by clinical suspicion), and postoperative fever and delay in return of bowel function. Clinical suspicion and surgeon standard of practice were used as guideline for assessment of an anastomotic leak. The appropriate modality for assessment of anastomotic leak was also left to the discretion of the surgeon. The incidence of all other operative complications was summarized based on relationship, seriousness, and severity. A complication was listed as mild if it was transient or easily tolerated, moderate if it caused discomfort or interfered with general condition, and severe if it caused considerable interference with general condition. The length of stay in the hospital and number of ICU days were also included as secondary endpoints. Postoperative recovery was at the discretion of the surgeon because no pathway was required. Thirty-day follow-up of all subjects was conducted, at which time all postoperative morbidity was captured and recorded.

PINPOINT Endoscopic Fluorescence Imaging System

The PINPOINT Endoscopic Fluorescence Imaging System is manufactured by Novadaq Technologies Inc. The system enables the surgeon to assess perfusion with real-time endoscopic high definition visible (VIS) and NIR

Table 1. Demographic Characteristics of Patients Who Underwent Fluorescence Angiography During Left Colectomy/Low Anterior Resection (n = 139)

Characteristic	Data
Age, y, mean \pm SD	58 \pm 14
Sex, n (%)	
Female	65 (46.8)
Male	74 (53.2)
Race, n (%)	
Asian	14 (10.0)
Black or African American	7 (5.0)
Hispanic	10 (7.2)
Middle Eastern	2 (1.4)
White	106 (76.3)
Hispanic	3 (2.2)
Body mass index (BMI), kg/m ² , mean \pm SD	29 \pm 6
BMI > 30, n (%)	42 (30.2)
BMI \leq 30, n (%)	97 (69.8)
American Society of Anesthesiologists, n (%)	
I	17 (12.2)
II	73 (52.5)
III	46 (33.1)
IV	3 (2.2)
Diagnosis, n (%)	
Diverticulitis	61 (43.9)
Rectal cancer	35 (25.2)
Colon cancer	29 (20.9)
Polyp	6 (4.3)
Proctidemia	4 (2.9)
Crohn's disease	1 (0.7)
Colovesical fistula	1 (0.7)
Radiation stricture	1 (0.7)
Sigmoid volvulus	1 (0.7)
Preoperative chemotherapy, n (%)	13 (9.4)
Preoperative radiation therapy, n (%)	15 (10.8)

fluorescence imaging. The PINPOINT system includes a surgical laparoscope optimized for VIS/NIR illumination and imaging, a camera head that is also optimized for VIS/NIR imaging and mounts to the laparoscope eyepiece, and an endoscopic video processor/illuminator capable of providing VIS/NIR illumination to the surgical laparoscope via a flexible light guide cable and the image processing required to generate simultaneous, real-time high definition video color (VIS) and NIR fluorescence images. PINPOINT is designed to be connected to a medical grade-high definition color video monitor and all components may be mounted on a stand-alone endoscopy tower.

The PINPOINT system allows simultaneous display of multiple images, including standard high definition white light imaging. Real time NIR fluorescence video

Table 2. Comorbidities of Patients Who Underwent Fluorescence Angiography During Left Colectomy/Low Anterior Resection (n = 139)

Comorbidity	n	%
Cardiovascular	61	43.9
Endocrine	33	23.7
Hematologic/lymphatic	8	5.8
Metabolic/nutritional	36	25.9
Musculoskeletal	31	22.3
Nervous/psychiatric	23	16.5
Respiratory	10	7.2
Skin	14	10.1
Ear, nose and throat	21	15.1
Urogenital	55	39.6
Current smoker	18	12.9
Former smoker	30	21.6
Alcohol weekly	52	37.4

images are acquired by using the imaging agent, ICG, and may be viewed in 2 ways: PINPOINT image, in which NIR fluorescence is superimposed in pseudo-color (green) on a white light image; and SPY image, in which a black and white NIR fluorescence image is displayed (Figs. 2 and 3). The PINPOINT system can include various components and software upgrades with a list price of \$167,500 to \$223,750 and a cost per case of \$999 to \$1,099.

Indocyanine green

Indocyanine green (ICG) is approved for human use by the United States Food and Drug Administration (FDA). It is a sterile, water-soluble, tricarbo-cyanine compound that can be administered intravenously or intra-arterially. It absorbs NIR light at 800 nm, and emits fluorescence (light) at a slightly longer wavelength of 830 nm. Indocyanine green rapidly and extensively binds to plasma proteins and is confined to the intravascular compartment, with minimal leakage into the interstitium. It is cleared by the liver in 3 to 5 minutes into bile with no known metabolites. Indocyanine green contains no more than 5.0% sodium iodide and should be used with caution in patients who have a history of allergy to iodides or iodinated imaging agent. The most serious, but rare, risk of ICG when administered intravenously in humans, according to the IC-GREEN (Akorn) product label, is anaphylactic death, which has been reported after IC-GREEN administration during cardiac catheterization.²⁷⁻²⁹

RESULTS

A total of 147 patients were enrolled between July 2012 and July 2013 at 11 institutions in the United States, of whom 139 were eligible for final analysis. Ineligibility was secondary to planned anastomosis < 5 cm, no anastomosis, and/or ileorectal anastomosis, as listed in

Table 3. Description of Operative Technique and Findings During Utilization of Fluorescence Angiography (n = 139)

Operative technique and finding	Data
Laparoscopic left colectomy/anterior resection, n (%)	120 (86.3)
Robotic left colectomy/anterior resection, n (%)	19 (13.7)
Converted to an open procedure, n (%)	5 (3.6)
Splenic flexure mobilization, n (%)	112 (80.6)
Level vessel ligation, n (%)	
High ligation of IMA (proximal to left colic takeoff)	86 (61.9)
Low ligation of IMA	19 (13.7)
Mid ligation IMA (distal to left colic takeoff)	33 (23.7)
IMA not ligated	1 (0.7)
Ileostomy, n (%)	26 (18.7)
Level of anastomosis, cm, mean ± SD (range)	10.4 ± 3.9 (5–15)
<8, n (%)	36 (25.9)
8–9, n (%)	16 (11.5)
≥10, n (%)	87 (62.6)
Baseline PINPOINT image acquired, n (%)	137 (98.6)
Change to resection margin, n (%)	9 (6.5)
Distance from planned transection, cm, mean ± SD (range)	3.6 ± 4 (0.5–14)
PINPOINT alters surgical plan after creation of anastomosis, n (%)	2
Revision of anastomosis	1 (0.7)
Confirmation of vascular supply to anastomosis	1 (0.7)
Operative time, h, mean ± SD (range)	4 ± 1.4 (1–10)

Table 4. Postoperative Morbidity of Patients Who Underwent Fluorescence Angiography During Left Colectomy/Low Anterior Resection (n = 139)

Morbidity	n	%
Postoperative morbidity	23	16.5
Anastomotic leak	2	1.4
Pelvic abscess	2	1.4
Abdominal wall infection	1	0.7
Acute renal failure	1	0.7
Blood transfusion	1	0.7
<i>C. difficile</i> colitis	1	0.7
Fever	1	0.7
Ileus	1	0.7
Ileus requiring nasogastric tube	1	0.7
Small bowel obstruction	1	0.7
Incisional hernia	1	0.7
Thrombosed left renal artery	1	0.7
Urinary retention	1	0.7
Urinary tract infection	1	0.7
Wound infection	1	0.7
Other	6	4.3
Morbidity related to		
Surgical procedure	17	12.2
Comorbid condition	1	0.7
Other	5	3.6
Severity of complication		0.0
Mild	14	10.1
Moderate	7	5.0
Severe	2	1.4
Return to operating room	0	0.0

Length of stay (mean \pm SD [range]) was 6 ± 3 days (1–25 days).

Appendix 1 (online only). The average age of patients (\pm SD) was 58 ± 14 years, and 53% of patients were male. Obesity (BMI >30 kg/m²) was prevalent in 30%, and the majority of patients were American Society of Anesthesiologists (ASA) II (53%). Diverticulitis (44%), rectal cancer (25%), and colon cancer (21%) were the most prevalent preoperative diagnoses. Of the patients with rectal cancer (n = 35), 43% underwent preoperative pelvic radiation (Table 1). Cardiovascular disease (44%), and urogenital disease (40%) were the most prevalent comorbidities (Table 2).

Laparoscopic resection was used in 86% and robotic surgery in 14% of the patients imaged. There was an overall conversion rate of 7.8% (n = 12); 5 of these patients were imaged, and 7 patients were not included due to a decision not to image. The splenic flexure was mobilized in 81% of patients, and a high ligation of the IMA was performed in 61.9% of cases. Successful imaging was obtained in 98.6% of cases in which perfusion imaging was attempted. Imaging was unsuccessful in 2 patients

Table 5. Secondary Endpoints at 30-Day Follow-up of Patients Who Underwent Fluorescence Angiography During Left Colectomy/Low Anterior Resection (n = 139)

Endpoint	n	%
Clinical anastomotic leak (day 30)*	2	1.4
Anastomotic leak confirmed by radiology (day 30)*	2	1.4
Postoperative fever (day 30)	7	5.0
Delay in return of bowel function (day 30)	5	3.6

*The 2 patients with anastomotic leak were discovered via clinical findings and confirmed via radiologic imaging.

secondary to equipment malfunction. Fluorescence angiography imaging changed the surgical plan in 11 (7.9%) patients. This included revision of the point of proximal colon transection (Video 1), as indicated by perfusion assessment in 9 patients (6.5%); takedown and revision of the completed anastomosis after transanal perfusion assessment in 1 patient; and confirmation of viability of anastomosis with concerns of malperfusion based on traditional methods of assessing viability of the anastomosis under white light in 1 patient. The use of transanal fluorescence angiography with findings of adequate perfusion altered the intraoperative plan for diversion to no diversion in this patient. There were no anastomotic leaks in the 11 patients in whom a change in the surgical plan occurred based on fluorescence angiography findings (Table 3). The rate of splenic flexure mobilization was similar in patients with change in surgical plan (82%) and those who did not require revision (81%). There were no reported cases in which change in surgical plan was based on standard assessment of bowel before the use of fluorescence angiography.

Postoperative complications were observed in 17% of patients; 12% of these were secondary to the surgical procedure and 2 (1.4%) were severe in nature (Table 4). The 2 abscesses reported were not associated with an anastomotic leak. The first case was a recurrent abscess in a patient with a colovesicular fistula, in whom an abscess adjacent to the bladder was discovered at the index operation. In the second case, the abscess was proven to have no communication with the anastomosis, as evidenced by lack of contrast extravasation on imaging and a lack of air within the abscess cavity. Therefore, this abscess was deemed not related to an anastomotic leak. These 2 patients with abscesses were treated with only antibiotics and had complete resolution, with no other intervention. There were 2 patients who received postoperative antibiotics beyond the 24-hour postoperative period; both patients were treated for abscess or phlegmon found during the index operation for diverticular disease, and antibiotics were discontinued by postoperative day 4. All recorded fevers had an attributable source as listed

Table 6. Postoperative Morbidity for High-Risk (Anastomosis < 10 and/or Pelvic Radiation) Compared with Low-Risk Anastomosis of Patients Who Underwent Fluorescence Angiography During Left Colectomy/Low Anterior Resection

Morbidity	Low-risk anastomosis (n = 86)	High-risk anastomosis (n = 53)
PINPOINT image acquired, %	98.8	98.1
Impact on surgical plan, %	5.8	7.5
PINPOINT altered surgical plan after anastomosis, %	1.2	1.9
Revision of anastomosis	0.0	1.9
Confirmation of vascular supply to anastomosis	1.2	0.0
Postoperative morbidity, %	16.3	17.0
Morbidity related to, %		
Surgical procedure	12.8	11.3
Comorbid condition	0.0	1.9
Other	3.5	3.8
Severity of complication, %	0.0	0.0
Mild	12.8	5.7
Moderate	1.2	11.3
Severe	2.3	0.0
In-hospital postoperative complications, %		
Anastomotic leak	1.2	1.9
Pelvic abscess	1.2	1.9
Abdominal wall infection	1.2	0.0
Acute renal failure	1.2	0.0
Blood transfusion	0.0	1.9
<i>C. difficile</i> colitis	1.2	1.9
Fever	1.2	0.0
Ileus	0.0	1.9
Ileus requiring nasogastric tube	0.0	1.9
Small bowel obstruction	0.0	1.9
Incisional hernia	1.2	0.0
Thrombosed left renal artery	1.2	0.0
Urinary retention	1.2	0.0
Urinary tract infection	0.0	1.9
Wound infection	0.0	1.9
Other	5.8	1.9
30-d outcomes, %		
Clinical anastomotic leak	1.2	1.9
Anastomotic leak confirmed by radiology*	1.2	1.9
Postoperative fever	2.3	9.4
Delay in return of bowel function	1.2	7.5

*The 2 patients with anastomotic leak were discovered via clinical findings and confirmed via radiologic imaging.

in Table 4, including urinary tract infection, wound infection, and/or *Clostridium difficile* infection.

Two (1.4%) anastomotic leaks were clinically suspected and radiologically confirmed (Table 5). Both patients had undergone low ligation of the IMA with an end-to-end anastomosis without diversion. One patient had rectal cancer with no history of preoperative chemotherapy or radiation and underwent a 6-hour laparoscopic anterior resection with splenic flexure mobilization with anastomosis at 6 cm. A defect of the anastomosis was

demonstrated on CT scan, which was obtained due to clinical suspicion on postoperative day 12. The patient was treated with a readmission, antibiotics, and transgluteal percutaneous drainage without diversion. The second patient had a diagnosis of diverticulitis and underwent a 3-hour laparoscopic anterior resection with anastomosis at 11 cm. A CT scan performed on postoperative day 12 due to clinical suspicion of a leak showed a small abscess containing air adjacent to the anastomosis. The patient was treated with readmission and antibiotics. Both

patients had complete resolution of symptoms without any further treatment. Table 6 lists outcomes with regard to high-risk (anastomosis < 10 cm and/or pelvic radiation) vs low-risk (≥ 10 cm and no radiation) patient populations.

DISCUSSION

Anastomotic leak is a significant complication of colorectal resection and leads to increased length of stay, cost, local recurrence, and mortality rates.^{4,5} Factors leading to anastomotic leak include patient characteristics, anastomotic integrity, and viability. Perfusion and tissue viability remain an area in which improvement may be achieved with the introduction of new technology. The ability to assess intraoperative perfusion accurately via easy to use and accessible methods is, therefore, of potential importance. This clinical trial demonstrated that PINPOINT is feasible and safe with no reported adverse events. Successful imaging was obtained in 98.6% of cases. Perfusion imaging led to a change in surgical plan in 7.9% of patients; all of these patients were discharged without any reported severe complications. The anastomotic leak rate (1.4%) in this trial was lower than the reported rates in multiple recent large prospective randomized and cohort comparison studies in the literature (3% to 15%).^{7,8,10,11}

The primary objective was to demonstrate the safety and feasibility of the intraoperative assessment of colon and rectal perfusion using fluorescence angiography during left colectomies and low anterior resections. This technology was easy to implement because the device is similar to a standard laparoscope, with a minimal learning curve for application and use. This technology was used by 11 institutions according to surgeon preference, and there were no reported difficulties in assessment despite the absence of any “run in” or practice cases. No complications attributable to the use of the ICG or the device were observed. Successful imaging demonstrated no apparent limitation with regard to imaging converted cases. There were no reported limitations to imaging and/or interpretation with regard to patient comorbidities. Fluorescence angiography has been found to be beneficial in assessing perfusion in earlier reports, aiding in surgical decision making and improving outcomes in cardiothoracic, hepatobiliary, colorectal, foregut, transplant, and plastic surgery.^{1,5,20-26} The feasibility and applicability of this new technology with the implications of potentially reducing anastomotic leak rates could make it an invaluable tool for use in high-risk colorectal resections.²⁸

Our results indicate that assessment of microperfusion of the transected bowel and planned site of anastomosis

was associated with revision of surgical plan in nearly 8% of patients. To our knowledge, there are only 2 studies in the literature that have demonstrated the benefits of angiography in colorectal surgery.^{1,5} Kudzus and colleagues⁵ reported a 14% ($n = 201$) change in resection margin using laser fluorescence angiography. These findings were confirmed by Jafari and colleagues¹ using Firefly (Intuitive Surgical Inc). The authors demonstrated a 19% change in transection point using fluorescence angiography compared with 4.5% using visible or white light during robotic low anterior resections. Our data confirm earlier reports that conventional methods of assessing bowel perfusion are not entirely reliable.^{1,5,30} To date, subjective methods such as active bleeding, palpable pulsation in the mesentery, and bowel discoloration, have been used. These methods are not objective and can be lacking in a laparoscopic colon resection secondary to the lack of tactile sensation and change in visual cues. In the majority of laparoscopic colectomies, as opposed to open technique, the bowel is transected and reanastomosed shortly after transection of the mesentery, thereby limiting observation time. Conventional techniques of assessing perfusion may not be entirely applicable with laparoscopy and even with laparotomy are not objective. Our data suggest that conventional assessment may have a failure rate that contributes to anastomotic leak. Although laser Doppler flowmetry and laser fluorescence angiography are earlier described reliable methods of measuring intraoperative perfusion,^{17-19,24,31,32} they can be cumbersome and difficult to implement, especially during laparoscopic operations.

The use of fluorescence angiography has potential for great clinical significance on outcomes of colorectal surgery especially with regard to high-risk anastomoses. Our data are consistent with this hypothesis by demonstrating lower anastomotic leak rates than those reported in the literature, even within the high-risk group. This result concurs with earlier reports by both Kudzus and colleagues⁵ and Jafari and colleagues,¹ which demonstrated decreases in leak rates of 60% and 66%, respectively, when compared with a control group. Jafari and colleagues¹ included a high-risk population of rectal cancer patients undergoing low anterior resection with anastomoses at a mean level of <5.5 cm from the anal verge. There was a reported 63% rate of history of radiation use in the fluorescence group. We demonstrated an anastomotic leak rate of 1.4% ($n = 2$), which is a promising reduction compared with that reported in the literature (12%).^{7,8} Considering the incidence of changes in the resection margin/anastomosis ($n = 10$) as high-risk patients who may have had leaks due to relative ischemia, it is intriguing to note that if half of these patients had

suffered leaks, the overall leak rate would have been 5%. If all of these patients had leaks, the rate would have been 8.6%, putting the leak rate into an expected range for a heterogeneous group of medium- and high-risk patients.

Adequate perfusion is a key component of anastomotic integrity. To date, conventional methods have been inadequate, as demonstrated by a high rate of anastomotic failures, and almost mandatory use of diverting ileostomy for low pelvic, high risk anastomoses. These anastomotic leaks have a substantial impact on the morbidity and mortality of patients.^{2,3,13,27,30,33,34} Therefore, any method to decrease the rate of anastomotic leak is of significant interest. Although patient-related-factors cannot be easily altered, there is potential to improve the assessment of bowel perfusion, viability, and anastomotic integrity. Our data may support the use of fluorescence angiography to allow for visualization of microperfusion of the bowel, which may, in turn, improve outcomes and decrease morbidity rates associated with anastomotic leaks. The 2 patients who developed anastomotic leaks in our series had minimal morbidity and required minimal interventions to manage the leak.

This study should be viewed with certain significant limitations. As a prospective single armed study of moderate size, inherent biases exist. There was no standardization with regard to technique of operation and anastomosis or preoperative or postoperative care. Although total operative time was recorded, the total imaging time was not recorded. Importantly, there was no standardization of the “standard of care” assessment of proximal bowel viability based on normal visual assessment or assessment of bleeding at the transection line. The patients were a heterogeneous group undergoing low pelvic and relatively high-risk anastomoses. This heterogeneous population and our sample size did not allow us to draw any specific conclusions with regard to the consequence that patient characteristics may have on interpretation of data. However, we report a 98.6% successful imaging rate and did not encounter any difficulty in interpreting fluorescence angiography in patients with peripheral vascular disease ($n = 3$), and/or diabetes ($n = 11$). The low conversion rates may imply a more experienced and skilled set of surgeons as compared with those reported in the literature, which may translate into a lower morbidity.^{7,35}

Despite the modest variability in practice, surgical preference, and technique, we have demonstrated that this technology for assessing anastomotic perfusion is reliable, safe, easy to use, and may lower the rate of anastomotic leaks in patients undergoing colorectal surgery. Although many factors that contribute to failure of an anastomosis are out of a surgeon’s control, this technology offers a new

and seemingly reliable technique to lend credence to the surgical dogma that blood supply and viability have a large impact on the creation of a healthy anastomosis.

CONCLUSIONS

In conclusion, this study demonstrates the feasibility and safety of fluorescence angiography using PINPOINT during left segmental colectomy and anterior resection. The study further demonstrates that the use of this technology may result in revisions of the proximal planned bowel transection point, and provide fluorescence angiography perfusion assessment of a completed anastomosis. Intraoperative assessment of perfusion of the bowel planned for primary anastomosis with fluorescence angiography may decrease the rates of anastomotic leak and thereby improve patient outcomes. A randomized controlled clinical trial is planned to further evaluate the true clinical significance of this new technology compared with the more standard assessment of the proximal transection line.

Author Contributions

Study conception and design: Stamos

Acquisition of data: Jafari, Wexner, Martz, McLemore,

Margolin, Sherwinter, Lee, Senagore, Phelan, Stamos

Analysis and interpretation of data: Jafari, Wexner, Martz,

McLemore, Margolin, Sherwinter, Lee, Senagore,

Phelan, Stamos

Drafting of manuscript: Jafari, Wexner, Stamos

Critical revision: Jafari, Wexner, Martz, McLemore,

Margolin, Sherwinter, Lee, Senagore, Phelan, Stamos

Acknowledgment: We would like to acknowledge all participating sites and staff, especially Drs Conor P Delaney, David W Larson, and Madhulika G Varma, for their invaluable contribution to the study as well as to the preparation of the manuscript.

REFERENCES

1. Jafari MD, Lee KH, Halabi WJ, et al. The use of indocyanine green fluorescence to assess anastomotic perfusion during robotic assisted laparoscopic rectal surgery. *Surgical Endosc* 2013;27:3003–3008.
2. Law WL, Chu KW. Anterior resection for rectal cancer with mesorectal excision: a prospective evaluation of 622 patients. *Ann Surg* 2004;240:260–268.
3. Montedori A, Cirocchi R, Farinella E, et al. Covering ileo- or colostomy in anterior resection for rectal carcinoma. *Cochrane database of systematic reviews* 2010;(5):CD006878.
4. Kingham TP, Pachter HL. Colonic anastomotic leak: risk factors, diagnosis, and treatment. *J Am Coll Surg* 2009;208:269–278.
5. Kudzus S, Roesel C, Schachtrupp A, Hoer JJ. Intraoperative laser fluorescence angiography in colorectal surgery: a

- noninvasive analysis to reduce the rate of anastomotic leakage. *Langenbeck's Arch Surg* 2010;395:1025–1030.
6. Kang CY, Halabi WJ, Chaudhry OO, et al. Risk factors for anastomotic leakage after anterior resection for rectal cancer. *JAMA Surg* 2013;148:65–71.
 7. Guillou PJ, Quirke P, Thorpe H, et al. Short-term endpoints of conventional versus laparoscopic-assisted surgery in patients with colorectal cancer (MRC CLASICC trial): multicentre, randomised controlled trial. *Lancet* 2005;365:1718–1726.
 8. Sauer R, Fietkau R, Wittekind C, et al. Adjuvant vs. neoadjuvant radiochemotherapy for locally advanced rectal cancer: the German trial CAO/ARO/AIO-94. *Colorectal Dis* 2003;5:406–415.
 9. Hyman N, Manchester TL, Osler T, et al. Anastomotic leaks after intestinal anastomosis: it's later than you think. *Ann Surg* 2007;245:254–258.
 10. Senagore A, Lee EC, Wexner SD, et al. Bioabsorbable staple line reinforcement in restorative proctectomy and anterior resection: a prospective randomized study. *Dis Colon Rectum* 2014;57:324–330.
 11. Pigazzi A, Luca F, Patriiti A, et al. Multicentric study on robotic tumor-specific mesorectal excision for the treatment of rectal cancer. *Ann Surg Oncol* 2010;17:1614–1620.
 12. Rullier E, Laurent C, Garrelon JL, et al. Risk factors for anastomotic leakage after resection of rectal cancer. *Br J Surg* 1998; 85:355–358.
 13. Matthiessen P, Hallbook O, Rutegard J, et al. Defunctioning stoma reduces symptomatic anastomotic leakage after low anterior resection of the rectum for cancer: a randomized multicenter trial. *Ann Surg* 2007;246:207–214.
 14. McArdle CS, McMillan DC, Hole DJ. Impact of anastomotic leakage on long-term survival of patients undergoing curative resection for colorectal cancer. *Br J Surg* 2005;92:1150–1154.
 15. Choi HK, Law WL, Ho JW. Leakage after resection and intraperitoneal anastomosis for colorectal malignancy: analysis of risk factors. *Dis Colon Rectum* 2006;49:1719–1725.
 16. Boyle NH, Manifold D, Jordan MH, Mason RC. Intraoperative assessment of colonic perfusion using scanning laser Doppler flowmetry during colonic resection. *J Am Coll Surg* 2000;191:504–510.
 17. Vignali A, Gianotti L, Braga M, et al. Altered microperfusion at the rectal stump is predictive for rectal anastomotic leak. *Dis Colon Rectum* 2000;43:76–82.
 18. Sheridan WG, Lowndes RH, Young HL. Tissue oxygen tension as a predictor of colonic anastomotic healing. *Dis Colon Rectum* 1987;30:867–871.
 19. Kologlu M, Yorganci K, Renda N, Sayek I. Effect of local and remote ischemia-reperfusion injury on healing of colonic anastomoses. *Surgery* 2000;128:99–104.
 20. Holm C, Tegeler J, Mayr M, et al. Monitoring free flaps using laser-induced fluorescence of indocyanine green: a preliminary experience. *Micorsurgery* 2002;22:278–287.
 21. Hutteman M, van der Vorst JR, Mieog JS, et al. Near-infrared fluorescence imaging in patients undergoing pancreaticoduodenectomy. *Eur Surg Res* 2011;47:90–97.
 22. Rodriguez-Hernandez A, Lawton MT. Flash fluorescence with indocyanine green videoangiography to identify the recipient artery for bypass with distal middle cerebral artery aneurysms: operative technique. *Neurosurgery* 2012;70: 209–220.
 23. Shimada Y, Okumura T, Nagata T, et al. Usefulness of blood supply visualization by indocyanine green fluorescence for reconstruction during esophagectomy. *Esophagus* 2011;8: 259–266.
 24. Still J, Law E, Dawson J, et al. Evaluation of the circulation of reconstructive flaps using laser-induced fluorescence of indocyanine green. *Ann Plastic Surg* 1999;42:266–274.
 25. Waseda K, Ako J, Hasegawa T, et al. Intraoperative fluorescence imaging system for on-site assessment of off-pump coronary artery bypass graft. *JACC* 2009;2:604–612.
 26. Nachiappan S, Askari A, Currie A, Kennedy RH, Faiz O. Intraoperative assessment of colorectal anastomotic integrity: a systematic review. *Surg Endosc* 2014;28:2513–2530.
 27. Cahill RA, Mortensen NJ. Intraoperative augmented reality for laparoscopic colorectal surgery by intraoperative near-infrared fluorescence imaging and optical coherence tomography. *Minerva Chir* 2010;65:451–462.
 28. Cahill RA, Ris F, Mortensen NJ. Near-infrared laparoscopy for real-time intra-operative arterial and lymphatic perfusion imaging. *Colorectal Dis* 2011;13:12–17.
 29. Alander JT, Kaartinen I, Laakso A, et al. A review of indocyanine green fluorescent imaging in surgery. *Int J Biomed Imag* 2012;2012:940585.
 30. Karliczek A, Harlaar NJ, Zeebregts CJ, et al. Surgeons lack predictive accuracy for anastomotic leakage in gastrointestinal surgery. *Int J Colorectal Dis* 2009;24:569–576.
 31. Chung RS. Blood flow in colonic anastomoses. Effect of stapling and suturing. *Ann Surg* 1987;206:335–339.
 32. Hoer J, Tons C, Schachtrupp A, et al. Quantitative evaluation of abdominal wall perfusion after different types of laparotomy closure using laser-fluorescence videography. *Hernia* 2002;6: 11–16.
 33. Dehni N, Schlegel RD, Cunningham C, et al. Influence of a defunctioning stoma on leakage rates after low colorectal anastomosis and colonic J pouch-anal anastomosis. *Br J Surg* 1998; 85:1114–1117.
 34. Enker WE, Merchant N, Cohen AM, et al. Safety and efficacy of low anterior resection for rectal cancer: 681 consecutive cases from a specialty service. *Ann Surg* 1999;230:544–552; discussion 552–554.
 35. Kang CY, Chaudhry OO, Halabi WJ, et al. Outcomes of laparoscopic colorectal surgery: data from the Nationwide Inpatient Sample 2009. *Am J Surg* 2012;204:952–957.

Appendix 1. Patients Excluded from Final Analysis

Reason for exclusion	Anastomotic leak
Anastomosis < 5 cm from the anal verge*	Yes
The tumor was at the splenic flexure. Anastomosis at 25 cm*	No
Ileo-colonic anastomosis at 20 cm*	No
Laparoscopic total abdominal colectomy with ileo-rectal anastomosis*	No
Laparoscopic total abdominal colectomy with ileo-rectal anastomosis*	No
Total proctocolectomy with ileo-anal anastomosis with j-pouch*	No
No anastomosis due to intraoperative pathology findings	N/A
Abdominoperineal resection (no anastomosis)	N/A

*Fluorescence angiography was performed.