

# UC San Diego

## UC San Diego Previously Published Works

### Title

A L2HGDH initiator methionine codon mutation in a Yorkshire terrier with L-2-hydroxyglutaric aciduria

### Permalink

<https://escholarship.org/uc/item/7188k5dw>

### Journal

BMC Veterinary Research, 8(1)

### ISSN

1746-6148

### Authors

Farias, Fabiana HG  
Zeng, Rong  
Johnson, Gary S  
et al.

### Publication Date

2012-07-26

### DOI

<http://dx.doi.org/10.1186/1746-6148-8-124>

Peer reviewed

CASE REPORT

Open Access

# A *L2HGDH* initiator methionine codon mutation in a Yorkshire terrier with L-2-hydroxyglutaric aciduria

Fabiana HG Farias<sup>1\*</sup>, Rong Zeng<sup>1</sup>, Gary S Johnson<sup>1</sup>, G D Shelton<sup>2</sup>, Dominique Paquette<sup>3</sup> and Dennis P O'Brien<sup>4</sup>

## Abstract

**Background:** L-2-hydroxyglutaric aciduria is a metabolic repair deficiency characterized by elevated levels of L-2-hydroxyglutaric acid in urine, blood and cerebrospinal fluid. Neurological signs associated with the disease in humans and dogs include seizures, ataxia and dementia.

**Case presentation:** Here we describe an 8 month old Yorkshire terrier that presented with episodes of hyperactivity and aggressive behavior. Between episodes, the dog's behavior and neurologic examinations were normal. A T2 weighted MRI of the brain showed diffuse grey matter hyperintensity and a urine metabolite screen showed elevated 2-hydroxyglutaric acid. We sequenced all 10 exons and intron-exon borders of *L2HGDH* from the affected dog and identified a homozygous A to G transition in the initiator methionine codon. The first inframe methionine is at p.M183 which is past the mitochondrial targeting domain of the protein. Initiation of translation at p.M183 would encode an N-terminal truncated protein unlikely to be functional.

**Conclusions:** We have identified a mutation in the initiation codon of *L2HGDH* that is likely to result in a non-functional gene. The Yorkshire terrier could serve as an animal model to understand the pathogenesis of L-2-hydroxyglutaric aciduria and to evaluate potential therapies.

**Keywords:** L-2-hydroxyglutaric aciduria, *L2HGDH*, Yorkshire terrier, Initiator methionine codon

## Background

L-2 hydroxyglutaric aciduria (L-2-HGA) was first described in 1980 in a young boy with psychomotor retardation and musculoskeletal dystrophy [1]. This rare autosomal recessive inherited disease is characterized by an elevated concentration of L-2-hydroxyglutaric acid in plasma, cerebrospinal fluid, and urine [1]. In human patients, the clinical features are mild psychomotor delay, followed by progressive cerebellar ataxia, dysarthria, moderate to severe mental deterioration and in some cases seizures [2,3]. Magnetic resonance imaging (MRI) of L-2-HGA patients shows abnormal signal in the peripheral subcortical white matter, basal ganglia and dentate nuclei. Also, cerebellar atrophy is present. The

distribution of signal abnormalities in the MRI of L-2-HGA patients is distinct and differentiates it from other diseases [4,5].

In 2004, mutations in *L2HGDH* were shown to cause human L-2-HGA [3,6]. *L2HGDH* is comprised of 10 exons which encode a protein of 463 amino acids that contains a N-terminal mitochondrial targeting sequence and C-terminal amino acid sequence homology to FAD-dependent oxidoreductases [6]. L-2-hydroxyglutarate dehydrogenase is bound to mitochondrial membranes and catalyzes the conversion of L-2-hydroxyglutarate to  $\alpha$ -ketoglutarate [6].

L-2-HGA was described in Staffordshire bull terriers in 2003 [7]. These dogs presented with ataxia, dementia, tremors and seizures, and they showed MRI changes similar to the human disease. L-2-hydroxyglutaric acid levels were elevated in urine, cerebrospinal fluid and plasma from affected dogs. In 2007, Penderis et al. [8]

\* Correspondence: fhfdpd@mail.missouri.edu

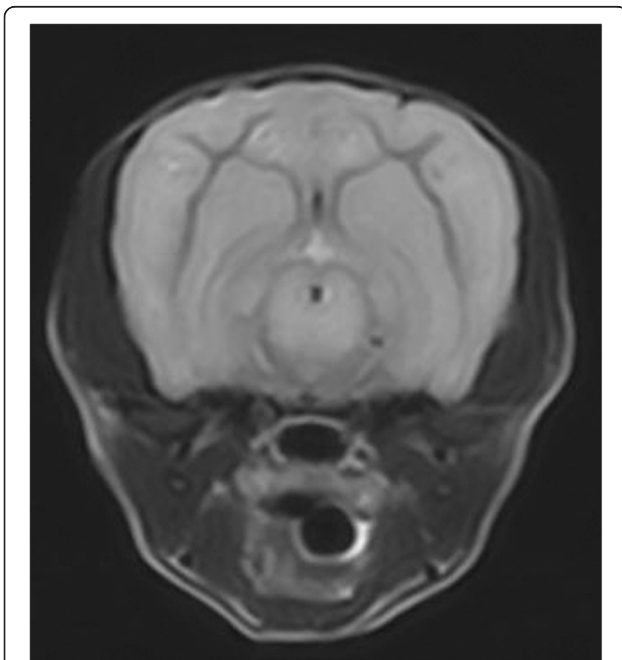
<sup>1</sup>Department of Veterinary Pathobiology, University of Missouri, Columbia, USA

Full list of author information is available at the end of the article

identified a 2 bp substitution in exon 10 of *L2HGDH* predicting a two amino acid substitution in Staffordshire bull terriers affected with L-2-HGA. A case of L-2-HGA was also reported in a West Highland white terrier with clinical and MRI characteristics of the disease [9], but no molecular genetic cause was determined. In this report, we describe the clinical features and the likely molecular genetic cause of L-2-HGA in a Yorkshire terrier.

### Case presentation

An 8 month old neutered male Yorkshire terrier was presented with episodes of hyperactivity and aggressive behavior. The episodes would last for about 40 minutes and then the dog behaved normally between episodes. No abnormalities were found on neurologic examination. Cerebrospinal fluid analysis showed a mild mononuclear pleocytosis (WBC 23/ul {N<8} with 92% mononuclear cells and 8% small lymphocytes) and normal protein (7 mg/dl {N<36}). An MRI of the brain (Figure 1) demonstrated hyperintensity of the gray matter of the thalamus, cerebral cortex and cerebellum on T2 weighted images similar to previously described MRIs from Staffordshire bull terriers and a West Highland white terrier with L-2-HGA [7,9]. No abnormalities were apparent on FLAIR, gradient echo or T1 weighted images with or without gadolinium contrast. Urine organic acid levels were quantified by gas chromatography-mass



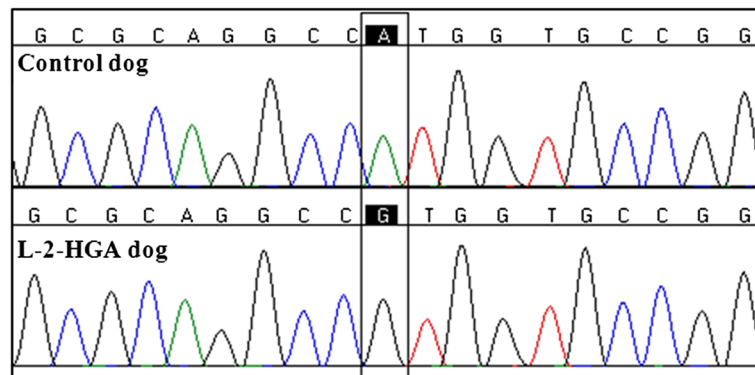
**Figure 1** Transverse T2-weighted image (TR = 3000, TE = 90) through the midbrain of the Yorkshire terrier with L-2-HGA. The gray matter of the cerebrum and brainstem shows the symmetric hyperintensity characteristic of the disease [7,9].

spectroscopy as previously described [10], and showed an elevated concentration of hydroxyglutaric acid (1,743 mmol/mol creatinine {N = 0.6–5.7}). Plasma amino acid levels were also quantified and showed elevated lysine (600  $\mu$ mol/L {N = 145–201}). A lysine restricted diet was developed, but it was not palatable so the dog was placed on a commercial protein restricted diet<sup>1</sup>. The dog was also started on phenobarbital at 2.5 mg/kg. The frequency of the episodes decreased with treatment, and the dog showed no progression of signs over 6 months.

Because MRI findings and urinary organic acid profiles were consistent with a diagnosis of L-2-HGA, *L2HGDH* became the most likely candidate gene to harbor the mutation responsible for the 2-HGA in this dog. DNA was extracted from an EDTA blood sample using a previously described method [11]. First, we eliminated the presence of the mutation identified in Staffordshire bull terriers [8]. To investigate whether there were other sequence variants in the affected dog's *L2HGDH*, we sequenced all 10 exons and intron–exon junctions as previously described [12]. Primer sequences are provided in Additional file 1. Comparison of the sequencing data from all 10 exons of canine *L2HGDH* from the affected dog to the published canine sequence (Ensembl Gene ID ENSCAF0000001437) revealed a homozygous *c.1A>G* substitution (Figure 2). This nucleotide substitution changes the initiation methionine codon, which is predicted to alter the translation start site [13].

We genotyped 6 unaffected Yorkshire terriers and 97 dogs from other breeds at *L2HGDH:c.1* by PCR-RFLP with PCR primers 5'-GCGCTCGATTGGCCCTTG-3' and 5'-GCAGGCCAGCGGCTACTCAC-3' which produced a 298 bp amplicon. The wild type allele was hydrolyzed by restriction enzyme *NcoI* into fragments of 157 and 141 bp; whereas, the mutant allele lacked the *NcoI* restriction site. All 103 normal dogs were homozygous for the wild type A allele.

*L2HGDH* encodes a FAD-dependent L-2-hydroxyglutarate dehydrogenase that is bound to mitochondrial membranes and converts L-2-hydroxyglutarate to  $\alpha$ -ketoglutarate [6]. L-2-hydroxyglutarate is endogenously produced but is not an intermediate of any currently recognized mammalian metabolic pathway. Instead, L-2-hydroxyglutarate is formed because mitochondrial L-malate dehydrogenase is not completely specific for oxaloacetate, its primary substrate. This enzyme can also reduce  $\alpha$ -ketoglutarate to L-2-hydroxyglutarate as a side reaction [14]. L-2-hydroxyglutarate dehydrogenase prevents the accumulation of L-2-hydroxyglutarate by FAD-dependent oxidation back to  $\alpha$ -ketoglutarate. Thus, L-2-HGA is considered to be a deficiency of 'metabolite repair' [6,15,16].



**Figure 2** Partial nucleotide sequence of *L2HGDH* exon 1 from a control dog and the Yorkshire terrier with L-2-HGA illustrating the *L2HGDH:c.1A>G* mutation.

The deleterious consequence of L-2-hydroxyglutarate dehydrogenase deficiency is the accumulation of L-2-hydroxyglutarate. L-2-hydroxyglutarate induces oxidative stress and inhibits mitochondrial creatine kinase in the cerebellum [17,18]. Also, L-2-hydroxyglutarate is a structural analog of glutamate, and thus a potential inhibitor of the many biologic processes that involve this key metabolite and neurotransmitter [15]. The exact mechanism by which accumulation of L-2-hydroxyglutaric acid causes brain injury is still unknown.

Since the identification of the first human *L2HGDH* mutations [3,6], about 70 L-2-HGA-causing mutations have been reported [19]. Among these are two that occur in the initiator codon (*c.1A>C* and *c.1A>G*), similar to the canine *L2HGDH:c.1A>G* mutation reported here. The canine initiator codon mutation was absent from 103 unaffected dogs. Mutations in initiator codons require the use of an alternative downstream methionine codon [13]. The next potential translational start site in the canine *L2HGDH* is out of frame and would encode a peptide of only 4 amino acids before it reaches a stop codon. The first inframe methionine codon is located 183 codons downstream from the original start codon, which if used would encode a protein without the N-terminal mitochondrial targeting domain [15]. Thus, the mutant *L2HGDH* in the Yorkshire terrier with L-2-HGA is unlikely to be functional.

The only clinical signs shown by the Yorkshire terrier were episodes of hyperactivity and aggression. At the time of this report, the dog has not shown any dementia, ataxia or generalized seizures as has been described in human patients and dogs with L-2-HGA from other breeds. Unless there is an unidentified splice variant that provides an alternative initiator methionine codon, the milder phenotype is unlikely to be due to residual enzyme activity. It could reflect a response to therapy or the younger age of the Yorkshire terrier. The decreased severity may have been due to the altered diet or to the

phenobarbital therapy which would suggest that these episodes were complex partial seizures, possibly with post-ictal behavior changes.

## Conclusion

We described a previously unreported mutation in *L2HGDH* in a Yorkshire terrier with L-2-HGA. This mutation is predicted to result in a non-functional gene. We recently learned that another group has independently found the same mutation in two European Yorkshire terriers with L-2-HGA [20]. The occurrence of L-2-HGA in two European Yorkshire terriers with an identical mutation is additional evidence that the *L2HGDH:c.1A>G* transition is the cause of L-2-HGA in this breed. The similarities between canine L-2-HGA and the human disease suggest that the canine disease could be a useful model to understand the pathogenesis of the disease and to evaluate potential therapies.

## Endnotes

<sup>1</sup>L/D, Hill's Pet Nutrition, Inc., Topeka, KS, USA.

## Additional file

**Additional file 1: Primer sequences for amplification of canine *L2HGDH*.**

## Author details

<sup>1</sup>Department of Veterinary Pathobiology, University of Missouri, Columbia, USA. <sup>2</sup>Department of Pathology, University of California at San Diego, La Jolla, USA. <sup>3</sup>Centre Veterinaire DMV, Montreal, Canada. <sup>4</sup>Department of Veterinary Medicine and Surgery, University of Missouri, Columbia, USA.

## Authors' contribution

FHGF analyzed sequences of *L2HGDH*, genotyped normal dogs and drafted the manuscript and submitted the manuscript for publication. RZ genotyped the Yorkshire terrier for the mutation identified in Staffordshire bull terriers. GSJ designed experiments and helped to draft the manuscript. Analysis of organic acids in the urine was performed by GDS. DP performed the clinical and neurological examinations and generated the MRI. DPO contributed to the clinical assessment and helped to draft the manuscript. All authors

contributed to the preparation of the manuscript. All authors read and approved the final manuscript.

Received: 9 April 2012 Accepted: 4 July 2012

Published: 26 July 2012

## References

1. Duran M, Kamerling JP, Bakker HD, van Gennip AH, Wadman SK: **L-2-Hydroxyglutaric aciduria: an inborn error of metabolism?** *J Inherit Metab Dis* 1980, **3**:109–112.
2. Barth PG, Hoffmann GF, Jaeken J, Lehnert W, Hanefeld F, Van Gennip AH, Duran M, Valk J, Schutgens RBH, Trefz FK, et al: **L-2-hydroxyglutaric acidemia: a novel inherited neurometabolic disease.** *Ann Neurol* 1992, **32**:66–71.
3. Topçu M, Jobard F, Halliez S, Coskun T, Yalçınkaya C, Gerceker FO, Wanders RJA, Prud'homme J-F, Lathrop M, Özguc M, Fischer J: **L-2-Hydroxyglutaric aciduria: identification of a mutant gene C14orf160, localized on chromosome 14q22.1.** *Hum Mol Genet* 2004, **13**:2803–2811.
4. Barbot C, Fineza I, Diogo L, Maria M, Melo J, Guimarães A, Melo Pires M, Luis Cardoso M, Vila rinho L: **L-2-Hydroxyglutaric aciduria: clinical, biochemical and magnetic resonance imaging in six Portuguese pediatric patients.** *Brain Dev* 1997, **19**:268–273.
5. D'Incerti L, Farina L, Moroni I, Uziel G, Savoiardo M: **L-2-Hydroxyglutaric aciduria: MRI in seven cases.** *Neuroradiology* 1998, **40**:727–733.
6. Rzem R, Veiga-da-Cunha M, Noël G, Goffette S, Nassogne M-C, Tabarki B, Schöller C, Marquardt T, Vikkula M, Van Schaftingen E: **A gene encoding a putative FAD-dependent L-2-hydroxyglutarate dehydrogenase is mutated in L-2-hydroxyglutaric aciduria.** *Proc Natl Acad Sci U S A* 2004, **101**:16849–16854.
7. Abramson CJ, Platt SR, Jakobs C, Verhoeven NM, Dennis R, Garosi L, Shelton GD: **L-2-Hydroxyglutaric aciduria in staffordshire bull terriers.** *J Vet Intern Med* 2003, **17**:551–556.
8. Penderis J, Calvin J, Abramson C, Jakobs C, Pettitt L, Binns MM, Verhoeven NM, O'Driscoll E, Platt SR, Mellersh CS: **L-2-hydroxyglutaric aciduria: characterisation of the molecular defect in a spontaneous canine model.** *J Med Genet* 2007, **44**:334–340.
9. Garosi LS, Penderis J, McConnell JF, Jacobs C: **L-2-hydroxyglutaric aciduria in a West Highland white terrier.** *Vet Rec* 2005, **156**:145–147.
10. Hoffmann G, Aramaki S, Blum-Hoffmann E, Nyhan WL, Sweetman L: **Quantitative analysis for organic acids in biological samples: batch isolation followed by gas chromatographic-mass spectrometric analysis.** *Clin Chem* 1989, **35**:587–595.
11. Katz ML, Khan S, Awano T, Shahid SA, Siakotos AN, Johnson GS: **A mutation in the CLN8 gene in English Setter dogs with neuronal ceroid-lipofuscinosis.** *Biochem Biophys Res Commun* 2005, **327**:541–547.
12. Farias FHG, Johnson GS, Taylor JF, Giuliano E, Katz ML, Sanders DN, Schnabel RD, McKay SD, Khan S, Gharahkhani P, et al: **An ADAMTS17 splice donor site mutation in dogs with primary lens luxation.** *Investig Ophthalmol Vis Sci* 2010, **51**:4716–4721.
13. Wolf A, Caliebe A, Thomas NST, Ball EV, Mort M, Stenson PD, Krawczak M, Cooper DN: **Single base-pair substitutions at the translation initiation sites of human genes as a cause of inherited disease.** *Hum Mutat* 2011, **32**:1137–1143.
14. Rzem R, Vincent MF, Van Schaftingen E, Veiga-da-Cunha M: **L-2-Hydroxyglutaric aciduria, a defect of metabolite repair.** *J Inherit Metab Dis* 2007, **30**:681–689.
15. Van Schaftingen E, Rzem R, Veiga-da-Cunha M: **L-2-Hydroxyglutaric aciduria, a disorder of metabolite repair.** *J Inherit Metab Dis* 2009, **32**:135–142.
16. Struys E, Gibson K, Jakobs C: **Novel insights into L-2-hydroxyglutaric aciduria: mass isotopomer studies reveal 2-oxoglutaric acid as the metabolic precursor of L-2-hydroxyglutaric acid.** *J Inherit Metab Dis* 2007, **30**:690–693.
17. Latini A, Scussiato K, Borba Rosa R, Leipnitz G, Llesuy S, Belló-Klein A, Dutra-Filho CS, Wajner M: **Induction of oxidative stress by L-2-hydroxyglutaric acid in rat brain.** *J Neurosci Res* 2003, **74**:103–110.
18. da Silva CG, Bueno ARF, Schuck PF, Leipnitz G, Ribeiro CAJ, Wannmacher CMD, Wyse ATS, Wajner M: **L-2-Hydroxyglutaric acid inhibits mitochondrial creatine kinase activity from cerebellum of developing rats.** *Int J Dev Neurosci* 2003, **21**:217–224.
19. Steenweg ME, Jakobs C, Errami A, van Dooren SJM, Adeva Bartolomé MT, Aerssens P, Augoustides-Savvopoulou P, Baric I, Baumann M, Bonafé L, et al: **An overview of L-2-hydroxyglutarate dehydrogenase gene (L2HGDH) variants: a genotype–phenotype study.** *Hum Mutat* 2010, **31**:380–390.
20. Sanchez-Masian DAR, Mascort J, Jakobs C, Salomons G, Zamora A, Casado M, Fernandez M, Recio A, Luján Feliu-Pascual A: **L-2-hydroxyglutaric aciduria in two female Yorkshire terriers.** *J Am Anim Hosp Assoc* 2012, in press.

doi:10.1186/1746-6148-8-124

Cite this article as: Farias et al.: A L2HGDH initiator methionine codon mutation in a Yorkshire terrier with L-2-hydroxyglutaric aciduria. *BMC Veterinary Research* 2012 **8**:124.

Submit your next manuscript to BioMed Central and take full advantage of:

- Convenient online submission
- Thorough peer review
- No space constraints or color figure charges
- Immediate publication on acceptance
- Inclusion in PubMed, CAS, Scopus and Google Scholar
- Research which is freely available for redistribution

Submit your manuscript at  
www.biomedcentral.com/submit

