

UCLA

Proceedings of UCLA Health

Title

Brown Tumor in a Patient with Primary Hyperparathyroidism

Permalink

<https://escholarship.org/uc/item/70t0c2rf>

Journal

Proceedings of UCLA Health, 21(1)

Authors

Grock, Shira

Smooke-Praw, Stephanie

Publication Date

2017-03-24

CLINICAL VIGNETTE

Brown Tumor in a Patient with Primary Hyperparathyroidism

Shira Grock, M.D., and Stephanie Smooke-Praw, M.D.

Case Report

An 86-year-old female presented with a two-month history of an enlarging, left-sided jaw mass. The mass persisted after a course of antibiotics prescribed by her dentist. A CT scan of the mandible (Fig. 1) and biopsy from an outside hospital demonstrated characteristics consistent with a benign Giant Cell Tumor. The patient was referred to Head and Neck Surgery for resection. Upon presentation to our institution, physical exam revealed a 3.5 cm x 4 cm mass along the left lateral aspect of the mandible that was firm and non-tender. Laboratory evaluation revealed calcium 12.0 mg/dL (N: 8.6-10.3), PTH 368 pg/mL (N: 11-51), creatinine 1.2 mg/dL (N: 0.6-1.3), vitamin D-25 43 ng/mL (N: 20-50), vitamin D-1,25 93.1 (N: 19.9-79.3), and alkaline phosphatase 184 U/L (N: 37-113). Bone densitometry demonstrated osteoporosis with a T-score of -4.1 at the left hip and -5.9 at the right distal radius. Parathyroid sestamibi scintigraphy (Fig. 1) and a neck ultrasound did not demonstrate parathyroid adenoma. Parathyroid 4D-CT Scan (Fig. 1) subsequently revealed a 7 mm left sided nodule inferior to the thyroid consistent with parathyroid adenoma. Patient denied a history of nephrolithiasis, acid reflux, constipation or other symptoms of hypercalcemia. The patient underwent left inferior parathyroidectomy. At the time of surgery, a 650 mg left lower pole parathyroid adenoma was removed. Intraoperative PTH levels decreased from 259 pg/mL to 32 pg/mL. Calcium normalized to 10.1 mg/dL post-operatively. At two months follow-up, calcium remained normal at 9.4 mg/dL with a PTH of 27 pg/mL. Her jaw mass was notably diminished in size.

Discussion

Brown tumors are an unusual presenting manifestation of primary hyperparathyroidism. The introduction of automated blood testing and routine calcium screening in the 1970s has led to an increase in the early diagnosis of hyperparathyroidism at a stage when most patients are asymptomatic.¹ Estimates in recent decades report that brown tumors occur in 0.8%-2.4% of hyperparathyroid cases.²⁻⁴ Tumors may be located in any part of the skeleton and are generally asymptomatic until they are quite large.⁵ Brown tumors result from increased osteoclastic activity and localized accumulation of vascular fibrous tissue in the setting of uncontrolled hyperparathyroidism.⁵ The tumor derived its name from the brown color caused by hemorrhage and hemosiderin deposits. It is considered a local form of osteitis fibrosa cystica.² Management of brown tumors

generally involves treating the underlying hyperparathyroidism. Surgery for the brown tumor itself can be considered if the lesion does not resolve after 1-2 years of proper medical treatment or if the lesion is causing physical impairment or disfigurement.⁵

One point of interest exemplified by this case is that multiple imaging modalities may be required to localize a parathyroid adenoma. In our case, parathyroid sestamibi scintigraphy and neck ultrasound were unrevealing, while parathyroid 4D-CT scan localized a 7mm adenoma. Parathyroid sestamibi scintigraphy is reported to have a sensitivity of 88% for solitary adenomas, while ultrasound is less sensitive at 71-80%.⁶ SPECT/CT and parathyroid 4D-CT are two alternative imaging techniques. While SPECT/CT can improve anatomic detail, this modality is limited in evaluation of smaller adenomas.⁶ The 4D-CT takes advantage of the perfusion qualities observed over the "fourth" dimension referred to as "time." While 4D-CT requires significantly more radiation exposure, it is reported to have a sensitivity approaching 90% in patients who previously had a negative sestamibi and ultrasound.^{6,7}

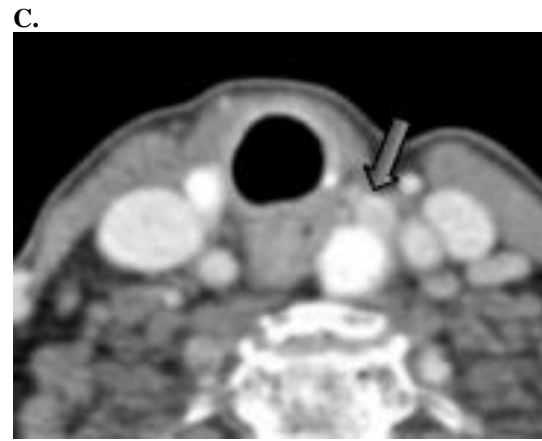
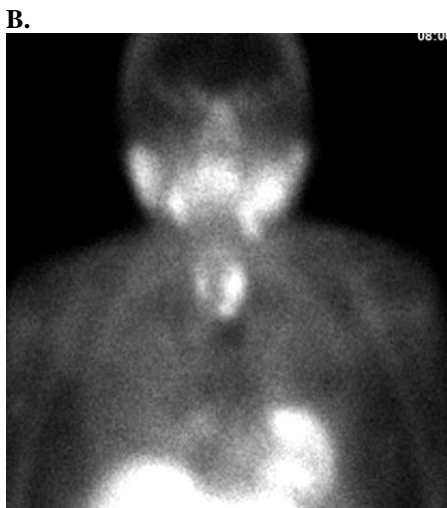
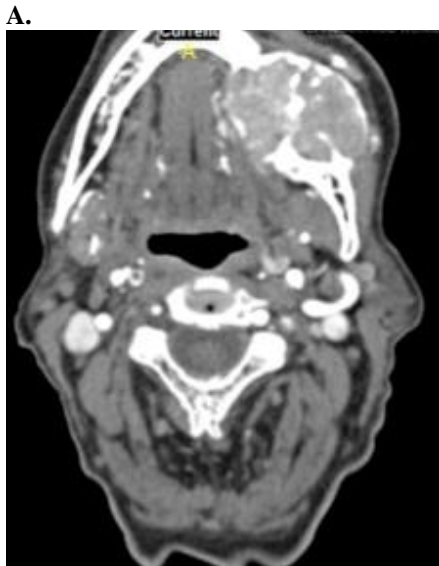
It is important to consider that not all patients with primary hyperparathyroidism require surgical treatment. The 2014 JCEM guidelines recommend surgical intervention for patients with serum calcium 1 mg/dL above upper limit of normal, osteoporosis, nephrolithiasis, creatinine clearance <60 cc/min, and 24-hour urinary calcium >400 mg/day or age <50.⁸ Of note, bone mineral density (BMD) may improve dramatically following successful parathyroidectomy.^{1,9} In one study, mean BMD at the lumbar spine increases by 8% at 1 year and 12% at 10 years postoperatively.⁹ Similarly, the mean BMD at the femoral neck increased by 6% at 1 year and 14% at 10 years.⁹ The dramatic post-operative improvement in BMD often obviates the need for future antiresorptive therapies. The ideal time to start antiresorptive therapy for patients with osteoporosis who will likely require treatment despite postoperative improvements in BMD is not defined in the consensus guidelines and remains controversial. While some clinicians use caution in prescribing antiresorptive agents in the perisurgical time period given the risk for post-operative hypocalcemia from hungry bone syndrome or hypoparathyroidism; others have suggested a possible decreased risk of hungry bone syndrome with preoperative bisphosphonates.¹⁰⁻¹³ Whether antiresorptive agents affect postoperative bone remodeling is another area that requires

further research. In our case, we opted to treat with an antiresorptive agent three months post-operatively given the severity of bone disease.

In conclusion, it has become quite rare in recent decades for patients with primary hyperparathyroidism to present with late stage bone manifestations.¹ Nonetheless, brown tumor should be considered in the differential diagnosis for a patient with a benign jaw tumor and bone loss. Furthermore, multiple forms of imaging may need to be pursued in order to accurately localize a parathyroid adenoma. Negative sestamibi should not preclude surgical intervention. In patients with osteoporosis, further research is required to define the ideal timing for initiation of antiresorptive agents.

Figures

Figure 1: A) Axial CT scan showing tumor in left mandible. B) Sestamibi scintigraphy displaying left thyroid enlargement without parathyroid adenoma on delayed imaging. C) 4D-Parathyroid CT showing left thyroid nodule and left inferior parathyroid adenoma



REFERENCES

1. **Kearns AE, Thompson GB.** Medical and surgical management of hyperparathyroidism. *Mayo Clin Proc.* 2002 Jan;77(1):87-91. Review. Erratum in: *Mayo Clin Proc* 2002 Mar;77(3):298. PubMed PMID: 11794462.
2. **Mahfoudhi M, Khamassi K, Battikh AG, Lahiani R, Sami T, Ben Salah M.** Brown tumor of the maxilla revealing primary hyperparathyroidism. *International Journal of Clinical Medicine.* 2015;6:252-6.
3. **Pappu R, Jabbour SA, Regianto AM, Reginato AJ.** Musculoskeletal manifestations of primary hyperparathyroidism. *Clin Rheumatol.* 2016 Dec;35(12):3081-3087. Epub 2016 Nov 4. Review. Erratum in: *Clin Rheumatol.* 2017 Jan 14;36(3):735. PubMed PMID: 27815654.
4. **Bilezikian JP, Silverberg SJ, Shane E, Parisien M, Dempster DW.** Characterization and evaluation of asymptomatic primary hyperparathyroidism. *J Bone Miner Res.* 1991 Oct;6 Suppl 2:S85-9; discussion S121-4. PubMed PMID: 1662460.
5. **Can Ö, Boynueğri B, Gökçe AM, Özdemir E, Ferhatoglu F, Canbakan M, Şahin GM, Titiz Mİ, Apaydın S.** Brown Tumors: A Case Report and Review of the Literature. *Case Rep Nephrol Dial.* 2016 Mar 18;6(1):46-52. doi: 10.1159/000444703. eCollection 2016 Mar 18. PubMed PMID: 27066494; PubMed Central PMCID: PMC4821153.
6. **Hinson AM, Lee DR, Hobbs BA, Fitzgerald RT, Bodenner DL, Stack BC Jr.** Preoperative 4D CT Localization of Nonlocalizing Parathyroid Adenomas by Ultrasound and SPECT-CT. *Otolaryngol Head Neck Surg.* 2015 Nov;153(5):775-8. doi: 10.1177/0194599815599372. Epub 2015 Aug 6. PubMed PMID: 26248963.
7. **Day KM, Elsayed M, Beland MD, Monchik JM.** The utility of 4-dimensional computed tomography for preoperative localization of primary hyperparathyroidism in patients not localized by sestamibi or ultrasonography. *Surgery.* 2015 Mar;157(3):534-9. doi: 10.1016/j.surg.2014.11.010. Epub 2015 Feb 7. PubMed PMID: 25660183.
8. **Bilezikian JP, Brandi ML, Eastell R, Silverberg SJ, Udelsman R, Marcocci C, Potts JT Jr.** Guidelines for the management of asymptomatic primary hyperparathyroidism: summary statement from the Fourth

- International Workshop. *J Clin Endocrinol Metab.* 2014 Oct;99(10):3561-9. doi: 10.1210/jc.2014-1413. Epub 2014 Aug 27. PubMed PMID: 25162665.
9. **Silverberg SJ, Shane E, Jacobs TP, Siris E, Bilezikian JP.** A 10-year prospective study of primary hyperparathyroidism with or without parathyroid surgery. *N Engl J Med.* 1999 Oct 21;341(17):1249-55. Erratum in: *N Engl J Med* 2000 Jan 13;342(2):144. PubMed PMID: 10528034.
 10. **Mayilvaganan S, Vijaya Sarathi HA, Shivaprasad C.** Preoperative zoledronic acid therapy prevent hungry bone syndrome in patients with primary hyperparathyroidism. *Indian J Endocrinol Metab.* 2017 Jan-Feb;21(1):76-79. doi:10.4103/2230-8210.196023. PubMed PMID: 28217502; PubMed Central PMCID:PMC5240085.
 11. **Corsello SM, Paragliola RM, Locantore P, Ingraudo F, Ricciato MP, Rota CA, Senes P, Pontecorvi A.** Post-surgery severe hypocalcemia in primary hyperparathyroidism preoperatively treated with zoledronic acid. *Hormones (Athens).* 2010 Oct-Dec;9(4):338-42. PubMed PMID: 21112866.
 12. **Lee IT, Sheu WH, Tu ST, Kuo SW, Pei D.** Bisphosphonate pretreatment attenuates hungry bone syndrome postoperatively in subjects with primary hyperparathyroidism. *J Bone Miner Metab.* 2006;24(3):255-8. PubMed PMID: 16622740.
 13. **Witteveen JE, van Thiel S, Romijn JA, Hamdy NA.** Hungry bone syndrome: still a challenge in the post-operative management of primary hyperparathyroidism: a systematic review of the literature. *Eur J Endocrinol.* 2013 Feb 20;168(3):R45-53. doi: 10.1530/EJE-12-0528. Print 2013 Mar. Review. PubMed PMID: 23152439.

Submitted March 24, 2017