

UC Davis
Dermatology Online Journal

Title

Clinical and histopathologic findings in cutaneous sting ray wounds: a case report

Permalink

<https://escholarship.org/uc/item/6z13g8bw>

Journal

Dermatology Online Journal, 19(8)

Authors

Tartar, Danielle
Limova, Marketa
North, Jeffrey

Publication Date

2013

DOI

10.5070/D3198019261

Copyright Information

Copyright 2013 by the author(s). This work is made available under the terms of a Creative Commons Attribution-NonCommercial-NoDerivatives License, available at <https://creativecommons.org/licenses/by-nc-nd/4.0/>

Peer reviewed

Case Presentation

Clinical and histopathologic findings in cutaneous sting ray wounds: a case report

Danielle Tartar, PhD¹, Marketa Limova, MD², Jeffrey North, MD¹

Dermatology Online Journal 19 (8): 4

¹University of Missouri School of Medicine, Department of Dermatology, ²University of California San Francisco, Department of Dermatology, and private practice, Fresno, California

Correspondence:

Jeffrey North MD
University of Missouri School of Medicine
Department of Dermatology
northjp@health.missouri.edu

Abstract

Human injuries related to stingray attacks include deep puncture wounds, envenomation, and foreign body reactions owing to retained tail fragments. Herein we report a patient who sustained a stingray injury that produced a subcutaneous granulomatous dermatitis and panniculitis with necrobiosis and review the topic of stingray injuries.

Introduction

Stingrays are cartilaginous fish that are grouped into four families: gymnurid (butterfly rays), urolophid (round stingrays), myliobatid (bat or eagle rays), and dasyatid (proper stingrays) [1,2]. In the United States alone, 1,500-2,000 stingray attacks are reported each year [1-3]. Stingrays are typically encountered in the waters off of coastal regions, where they lie partially submerged in the sand with only their eyes visible [1,4]. Most injuries to humans occur on the lower leg or foot when the stingray is inadvertently stepped on, although injuries to the upper extremities, chest, and back have also been reported [2]. When the ray is disturbed, it reflexively swings a barbed tail upwards, which can inflict deep puncture wounds [2]. The barbed tail has retro-serrated teeth making removal extremely difficult (Figure 1), which can lead to retained tail fragments in the wound [1].

In addition to producing traumatic injury, stingray tails have 1-4 stingers that release venom during an attack. Because the barbed tail is driven into the victim, a thin integument over the stinger ruptures, leading to envenomation [5]. Here, we present a case report of a stingray injury in which the stinger penetrated the full-thickness of skin and embedded into the patient's bone. The injury resulted in a subcutaneous mass of granulomatous dermatitis and panniculitis with large zones of necrobiosis.

Case synopsis

History: A 63-year-old man sustained a penetrating wound from the tail of a stingray while fishing in San Francisco bay, California. A portion of the barbed tail (Figure 1) was embedded into the man's posterior lower leg penetrating through the musculature to the periosteum of the tibia. The tail piece was removed in the emergency room and he was treated with a 10 day course of trimethoprim/sulfamethoxazole. Over the next two months he developed a non-fluctuant, subcutaneous mass at the site of the injury. The puncture site continued to drain a clear serous fluid that did not grow any pathogenic organisms (alpha-hemolytic *Streptococcus* sp. only).



Figure 1. Stingray tailpiece removed from patient's lower leg.

Physical Examination: Two months after the injury, the patient presented with a firm, erythematous, 1 cm nodule with a central puncture site. The nodule was surrounded by a slightly violaceous subcutaneous plaque, approximately 4 cm overall, on the posterior aspect of the lower leg (Figure 2). Incisional biopsies for both tissue culture and histopathologic analysis were obtained.

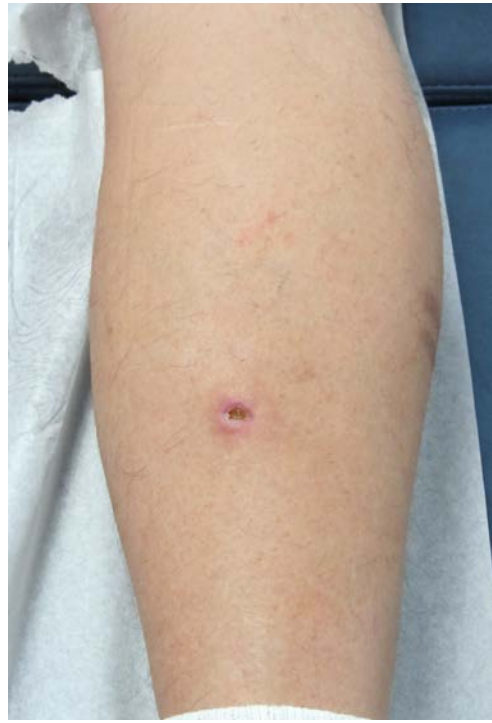

Figure 2. Ulcerated nodule at site of the stingray tail wound present 2 months after the initial injury.

Histopathology: Routine H&E-stained sections showed superficial ulceration with a large zone of paucicellular necrosis (“necrobiosis”) extending from the dermis into the subcutis, preferentially affecting the fat septa (Figure 3). A granulomatous inflammatory infiltrate with multinucleated histiocytes was present around the zone of necrobiosis (Figure 4). No foreign material was visualized with polarized light microscopy. Foci with a small number of neutrophils and areas of lipomembranous fat necrosis were present (Figure 5). PAS-D, Gram, and Fite stains were negative for fungi, bacteria, and mycobacteria, respectively.

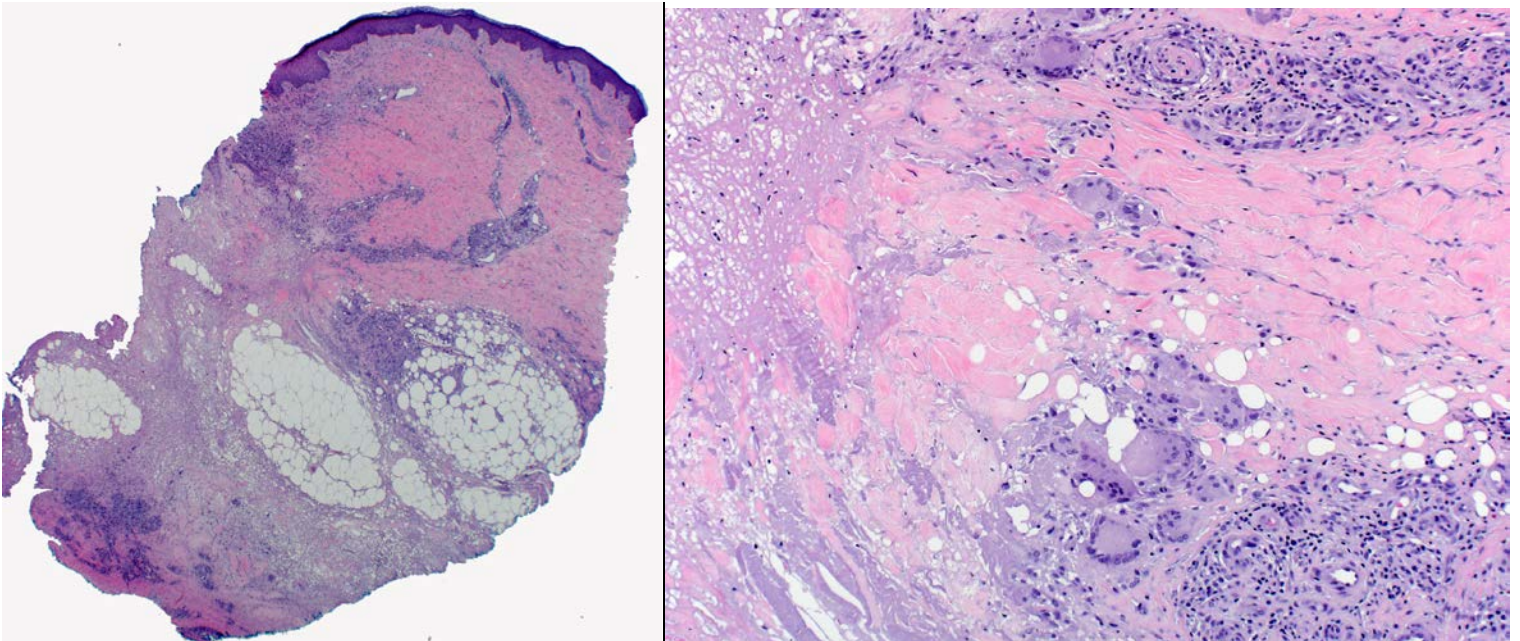


Figure 3. Biopsy of the persistent nodule showed granulomatous inflammation surrounding a broad zone of paucicellular necrosis (necrobiosis) that extended down widened septa in the subcutis with overlying ulceration. H & E 20x. **Figure 4.** High power magnification of multinucleated histiocytes surrounding the central zone of necrosis in a palisaded pattern. H & E 100x

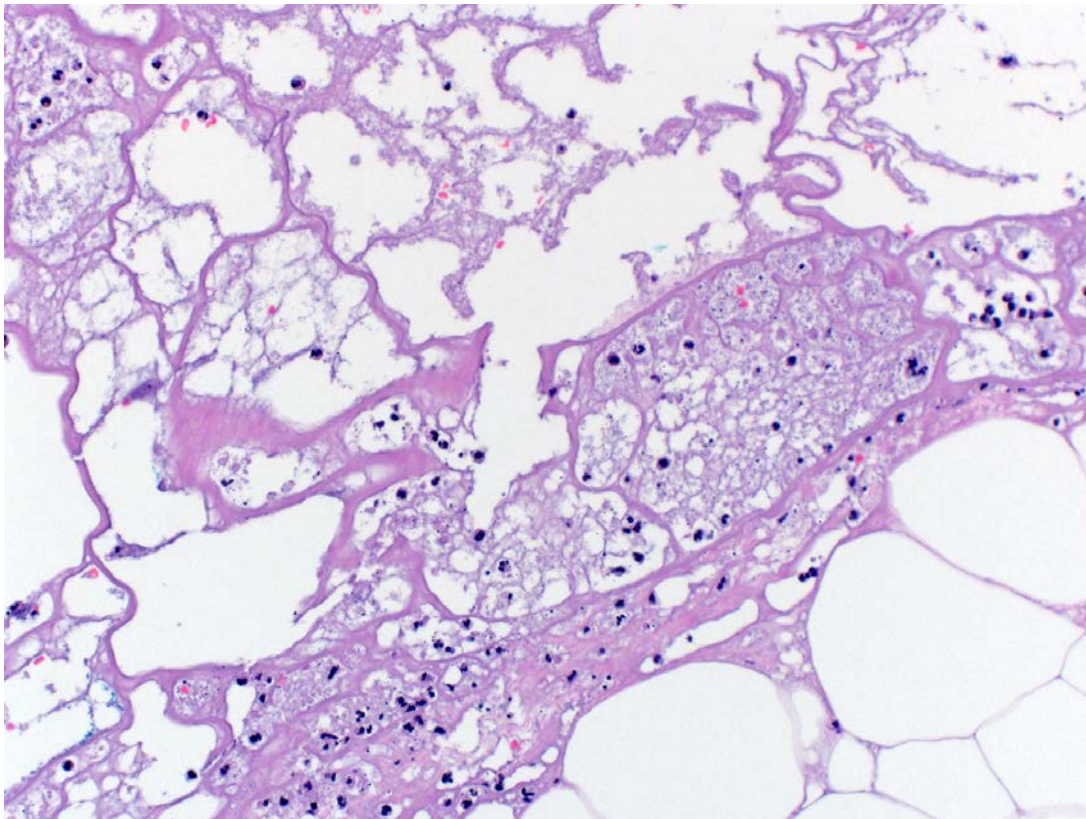


Figure 5. Neutrophils were present in small numbers in the inflammatory infiltrate, and areas of lipomembranous fat necrosis were prominent. H & E 200x

Laboratory Data: Tissue culture was positive for *Stenotrophomonas maltophilia* (*Xanthomonas maltophilia*), an aerobic, non-fermentative, Gram-negative bacterium. Sensitivities showed susceptibility to levofloxacin, ticarcillin/clavulante, and trimethoprim/sulfamethoxazole. All mycobacterial and fungal cultures were negative.

Follow up: The patient was treated with a 21-day course of levofloxacin 500mg PO daily with full resolution of symptoms. No recurrence has been detected in over a year of follow up.

Discussion

Although stingray injuries can cause significant morbidity and occur approximately 2000 times a year in the United States, the medical literature describing these injuries is sparse. Injury results from both the penetrating trauma and from envenomation from the ray's tail. The venom contains phosphodiesterase, 5'-nucleotidase, and serotonin, and can cause both local and systemic effects. Locally, the venom triggers vasoconstriction and ischemia that leads to poor wound healing [5]. The victim often reports intense pain, out of proportion to the injury [1,6]. In fact, the pain can be so severe that it leads to disorientation in the victim [7]. Systemically, the venom can cause weakness, diaphoresis, nausea, vomiting, diarrhea, dysrhythmias, syncope, hypotension, muscle cramps, paralysis, and even rarely, death [5].

The histopathologic findings in stingray injuries have not been well characterized. In our case, a large zone of pauci-cellular necrosis (necrobiosis) with surrounding granulomatous inflammation and superficial ulceration was present in a biopsy taken 2 months after the injury occurred. This pattern of necrosis may stem from direct toxicity of the stingray venom on the soft tissues of the skin.

The mainstays of treatment are removal of the stinger and irrigation with hot water, which can denature the heat-labile stingray venom. Recommended treatment includes soaking the wound in hot water (45-50°C) for 30-60 minutes. Xylocaine (without epinephrine) can be used for anesthesia [7]. An X-ray of the wound should be performed to ensure that all fragments of the stinger are removed. If wound closure is desired, it should be done loosely given the risk for infection and compartment syndrome [5,7]. Given the size, penetrating nature, and slow healing of stingray injuries, there is also a significant risk for secondary infection [8]. All patients should be given tetanus prophylaxis and may benefit from treatment with a course of antibiotic therapy. Bowers et al. suggest trimethoprim/sulfamethoxazole (160 and 800 mg, respectively, twice a day), ciprofloxacin (500 mg twice a day), or tetracycline (500 mg four times a day) for 7 days [7]. This, however, may not be adequate for some patients. In the case of our

patient, a short course of trimethoprim/sulfamethoxazole appears to have been insufficient and a longer course of levofloxacin was needed. *S. maltophilia* is highly resistant to multiple antibiotics and slow-growing small colony variants have been reported to cause human disease [9]. Clinicians may need to consider a longer course of antibiotics following a stingray injury to prevent or treat any secondary infection.

References

1. Trickett R, Whitaker IS, Boyce DE. Sting-ray injuries to the hand: case report, literature review and a suggested algorithm for management. *J Plast, Reconstruct & Aesthetic Surg.* 2009; 62:e270-e273. [PMID: 18313375]
2. Daly JS, Scharf MJ. Injuries caused by venomous fish spines in Fitzpatrick's *Dermatology in General Medicine* (8th ed). McGraw-Hill 2012.
3. Auerbach PS: Marine envenomations. *N Engl J Med* 325:486, 1991. [PMID: 1677161]
4. Edmonds, C. *Marine Animal Injuries* in Bove and Davis' *Diving Medicine* (3rd ed.). Saunders 1997.
5. Auerbach PS, Norris RL. *Marine Envenomations* in Harrison's *Principles of Internal Medicine* (18th ed.). McGraw-Hill 2012.
6. Myer PK. Stingray injuries. *Wilderness Environ Med.* 1997; 8:24-8. [PMID: 11990133]
7. Bowers RC, Mustain M. Chapter 46. Disorders Due to Physical & Environmental Agents. In: Humphries RL, Stone C, eds. *CURRENT Diagnosis & Treatment Emergency Medicine.* 7th ed. New York: McGraw-Hill; 2011.
8. Isbister GK. Chapter 207. Trauma and Envenomations from Marine Fauna. In: Tintinalli JE, Stapczynski JS, Cline DM, Ma OJ, Cydulka RK, Meckler GD, eds. *Tintinalli's Emergency Medicine: A Comprehensive Study Guide.* 7th ed. New York: McGraw-Hill; 2011.
9. Anderson SW, Stapp JR, Burns JL, and Qin X. Characterizations of small colony variant *Stenotrophomonas maltophilia* isolated from the sputum specimens of five patients with cystic fibrosis. *J Clin Microbiol.* 2007, 45(2): 529-535. [PMID: 17135443]