

UCLA

Proceedings of UCLA Health

Title

Collagenous Colitis Presenting as Diffuse Pseudomembranes

Permalink

<https://escholarship.org/uc/item/6w98p0dp>

Journal

Proceedings of UCLA Health, 23(1)

Authors

Zaki, Timothy A.

Grewal, Jasleen K.

Braun, Adam

et al.

Publication Date

2020-02-04

CLINICAL VIGNETTE

Collagenous Colitis Presenting as Diffuse Pseudomembranes

Timothy A. Zaki, BS¹, Jasleen K. Grewal, MD^{2,3}, Adam Braun, MD³, Bitu V. Naini, MD⁴, Robert M. Mocharla, MD^{2,3},
and Priyam V. Tripathi, MD, MPH^{2,3}

¹New York University School of Medicine

²Vatche and Tamar Manoukian Division of Digestive Diseases, David Geffen School of Medicine at UCLA

³Department of Medicine, David Geffen School of Medicine at UCLA

⁴Department of Pathology and Laboratory Medicine, David Geffen School of Medicine at UCLA

Abstract

A 60-year-old female with six weeks of chronic diarrhea who was found to have confluent *C. difficile*-negative pseudomembranous colitis on endoscopy with histologic collagenous colitis (subepithelial collagen thickening) in the setting of nonsteroidal anti-inflammatory drug (NSAID) use. Her symptoms resolved completely after treatment with budesonide and discontinuation of NSAIDs.

Introduction

Pseudomembranous colitis refers to an inflammatory condition of the colon that presents endoscopically with yellow exudative plaques that coalesce to form mucosal pseudomembranes in the colon. It is a nonspecific pattern of inflammation stemming from impaired blood flow, decreased oxygenation, and endothelial damage causing necrosis and eruption of neutrophils and nuclear debris at the level of the colonic mucosa.¹ In most cases, pseudomembranous colitis is triggered by toxin-mediated *Clostridioides (C.) difficile* infection. Additional etiologies include other infections, ischemia, inflammatory bowel disease, and rarely, microscopic colitis.²

Microscopic colitis is divided into lymphocytic and collagenous subtypes. Both subtypes can be precipitated by smoking or use of medications including nonsteroidal anti-inflammatory drugs (NSAIDs) and proton pump inhibitors (PPIs).³ Classically, endoscopic findings are absent in patients with microscopic colitis. However, macroscopic findings such as edema, erythema, friability, and exudative lesions may occasionally be visualized.

Synchronous pseudomembranous and collagenous colitis, also known as pseudomembranous collagenous colitis, has rarely been described in the literature. When infectious causes are ruled out, the precipitating cause is often medication-related or undetermined.

Case Report

A 60-year-old female presented with chronic diarrhea for 6 weeks. Her past medical history included remote ductal carcinoma in situ of the right breast, which was surgically removed and treated with radiation therapy. Her family history was non-contributory. Screening colonoscopy two years prior to presentation showed three hyperplastic polyps, removed without complication.

Initially, the patient presented with one week of small-volume, watery, non-bloody diarrhea five to ten times per day. It was associated with mild, diffuse abdominal pain, subjective fevers, and fecal urgency. The patient's medications included aspirin 325 milligrams twice daily as needed and ibuprofen 200 milligrams several times per week for chronic musculoskeletal pain. She denied recent travel, antibiotic or PPI use, and exposure to animals, bodies of fresh water, or sick contacts. She was afebrile with stable vital signs and a benign physical exam. Initial diagnostics were notable for hyponatremia (131 mmol/L) and elevated C-reactive protein (5.0 mg/dL). Complete blood count, thyroid and celiac tests, and erythrocyte sedimentation rate were unremarkable. Bacterial and parasitic enteric pathogen panels as well as a fecal leukocyte stain were negative.

Aspirin and ibuprofen were discontinued and the patient was advised to adhere to a bland diet and avoid lactose. She was given azithromycin empirically for three days without improvement. Colonoscopy was recommended but the patient deferred. She was started on loperamide, diphenoxylate-atropine, and dicyclomine as needed and a 14-day rifaximin course for presumed diarrhea-predominant irritable bowel syndrome. Four days later, rifaximin was discontinued due to worsening diarrhea and colonoscopy was performed.

Colonoscopy showed thick, confluent, yellow-white exudative pseudomembranes throughout the entire examined colon that was easily sloughed off with irrigation, revealing erythematous and edematous underlying mucosa without ulceration but with spontaneous petechial hemorrhage (Figure 1). The colonoscopic exam extended to the mid-transverse colon without

further intubation given the patient's notable severe, diffuse colitis. During colonoscopy, the patient became hypotensive and tachycardic and was admitted to the hospital with concern for severe colitis and dehydration. She was started on empiric oral vancomycin therapy for presumed *C. difficile* infection. Colonic aspirates taken during colonoscopy for *C. difficile* PCR were negative and a repeat stool *C. difficile* PCR was also negative. Repeat stool studies for bacterial and parasitic pathogenic organisms were also negative. Fecal calprotectin was elevated (1104 ug/g). Colonic biopsies revealed collagenous microscopic colitis (Figure 2). The patient was started on budesonide 9mg daily and her diarrhea subsided completely within one week, and she was slowly tapered off.

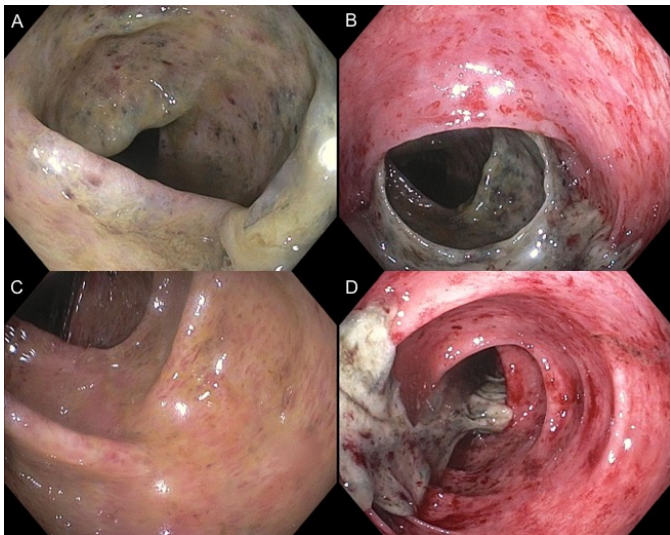


Figure 1. Colonoscopy showing thick, confluent layers of yellow-white pseudomembrane that were easily sloughed off with irrigation, revealing erythematous and edematous underlying mucosa with spontaneous petechial hemorrhage.

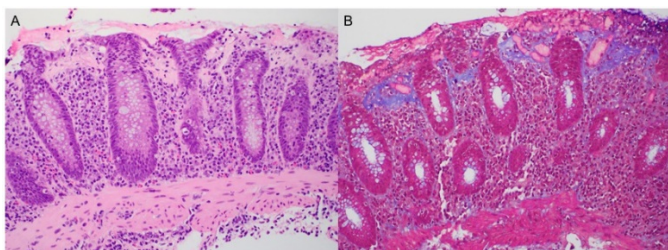


Figure 2. A. Pathology from biopsy of random colonic segment showing mild expansion of the lamina propria by chronic inflammatory cells consisting of lymphocytes, plasma cells, scattered eosinophils, and rare neutrophils; there is conspicuous thickening of subepithelial collagen table (highlighted by trichrome stain in B) with entrapment of inflammatory cells and capillaries as well as detachment of the surface epithelium from the underlying thickened collagen table, consistent with collagenous colitis.

Discussion

Our patient showcased a unique and rare presentation of severe collagenous colitis with a striking endoscopic appearance of confluent *C. difficile*-negative pseudomembrane formation in the setting of chronic, intermittent NSAID use. Although rare, NSAIDs have been documented to cause colitis of various forms including eosinophilic colitis, collagenous colitis, and pseudomembranous colitis.⁴ Amongst the rare cases of pseudomembranous collagenous colitis, the etiology remains unknown in most cases despite comprehensive stool studies and thorough review of medications. In one case series of 10 patients with histologically-confirmed pseudomembranous collagenous colitis, only one tested positive for *C. difficile* and only two of ten patients had taken NSAIDs.⁵ The remainder had no identifiable precipitating factors. Additionally, none of these patients had gross pseudomembrane formation. Whereas all patients with pseudomembranous collagenous colitis exhibit histologic evidence of subepithelial collagen thickening with pseudomembranous changes, gross endoscopic evidence of pseudomembrane formation is rarely observed. A recent case report described a patient with *C. difficile*-negative pseudomembranous collagenous colitis and endoscopic evidence of pseudomembrane formation in the setting of consumption of raw oysters, without history of NSAID use.⁶ There have been limited case series of patients with NSAID use as an underlying etiology. One series described two men with *C. difficile*-negative pseudomembranous collagenous colitis in the setting of prolonged NSAID use. Only one had endoscopic evidence of pseudomembrane formation while the other had normal-appearing colonic mucosa.⁷

We could identify only a handful of case reports describing pseudomembranous collagenous colitis with macroscopic evidence of pseudomembrane formation visualized endoscopically, particularly in association with NSAID use. Our case highlights the importance of considering microscopic colitis in the differential diagnosis of patients with macroscopic findings of pseudomembrane formation on endoscopy and we urge routine colon biopsies in this setting, even if the gross endoscopic appearance of the pseudomembranes are not as confluent or diffuse as seen in this case. This case also illustrates that the clinical presentation of microscopic colitis can be severe, mimicking the clinical severity of *C. difficile* colitis. Notably, microscopic colitis is still a rare cause of pseudomembrane formation in the colon, thus the more common *C. difficile* should always be tested and empirically treated for in severe cases until it has been ruled out. Once microscopic colitis is confirmed, any potential precipitating agents such as NSAIDs should be discontinued if possible.

REFERENCES

1. Farooq PD, Urrunaga NH, Tang DM, von Rosenvinge EC. Pseudomembranous colitis. *Dis Mon.* 2015 May; 61(5):181-206. doi: 10.1016/j.disamonth.2015.01.006. Epub 2015 Mar 11. Review. PubMed PMID: 25769243; PubMed Central PMCID: PMC4402243.

2. **Tang DM, Urrunaga NH, von Rosenvinge EC.** Pseudomembranous colitis: Not always *Clostridium difficile*. *Cleve Clin J Med*. 2016 May;83(5):361-6. doi:10.3949/ccjm.83a.14183. Review. PubMed PMID: 27168512.
3. **Masclee GM, Coloma PM, Kuipers EJ, Sturkenboom MC.** Increased risk of microscopic colitis with use of proton pump inhibitors and non-steroidal anti-inflammatory drugs. *Am J Gastroenterol*. 2015 May; 110(5):749-59. doi: 10.1038/ajg.2015.119. Epub 2015 Apr 28. PubMed PMID: 25916221.
4. **Price AB.** Pathology of drug-associated gastrointestinal disease. *Br J Clin Pharmacol*. 2003 Nov;56(5):477-82. Review. PubMed PMID: 14651719; PubMed Central PMCID: PMC1884388.
5. **Yuan S, Reyes V, Bronner MP.** Pseudomembranous collagenous colitis. *Am J Surg Pathol*. 2003 Oct;27(10): 1375-9. PubMed PMID: 14508399.
6. **Grunwald D, Mehta M, Sheth SG.** Pseudomembranous Collagenous Colitis: A Case of Not-so-Microscopic Colitis. *ACG Case Rep J*. 2016 Dec 21;3(4):e187. doi: 10.14309/crj.2016.160. eCollection 2016 Aug. PubMed PMID: 28119938; PubMed Central PMCID: PMC 5226204.
7. **Giardiello FM, Hansen FC 3rd, Lazenby AJ, Hellman DB, Milligan FD, Bayless TM, Yardley JH.** Collagenous colitis in setting of nonsteroidal antiinflammatory drugs and antibiotics. *Dig Dis Sci*. 1990 Feb;35(2):257-60. PubMed PMID: 2302984.