

UCSF

UC San Francisco Previously Published Works

Title

A review of craniofacial and dental findings of the RASopathies

Permalink

<https://escholarship.org/uc/item/6pp9q732>

Journal

Orthodontics and Craniofacial Research, 20(S1)

ISSN

1601-6335

Authors

Cao, H

Alrejaye, N

Klein, OD

et al.

Publication Date

2017-06-01

DOI

10.1111/ocr.12144

Peer reviewed



Published in final edited form as:

Orthod Craniofac Res. 2017 June ; 20(Suppl 1): 32–38. doi:10.1111/ocr.12144.

A review of craniofacial and dental findings of the RASopathies

Haotian Cao^{1,2}, Najla Alrejaye², Ophir D. Klein^{2,3}, Alice F. Goodwin^{2,*}, and Snehlata Oberoi^{2,*}

¹State Key Laboratory of Oral Diseases and Branch of Cleft Lip and Palate Surgery, Department of Oral and Maxillofacial Surgery, West China Hospital of Stomatology, Sichuan University, Chengdu, Sichuan, China

²Department of Orofacial Sciences and Program in Craniofacial Biology, University of California, San Francisco, San Francisco, CA, USA

³Department of Pediatrics and Institute for Medical Genetics, University of California, San Francisco, San Francisco, CA, USA

Abstract

Objectives—The RASopathies are a group of syndromes that have in common germline mutations in genes that encode components of the Ras/mitogen-activated protein kinase (MAPK) pathway and have been a focus of study to understand the role of this pathway in development and disease. These syndromes include Noonan syndrome (NS); Noonan syndrome with multiple lentiginos (NSML or LEOPARD syndrome); neurofibromatosis type 1 (NF1); Costello syndrome (CS); cardio-facio-cutaneous (CFC) syndrome; neurofibromatosis type 1-like syndrome (NFLS or Legius syndrome); and capillary malformation-arteriovenous malformation syndrome (CM-AVM). These disorders affect multiple systems, including the craniofacial complex. Although the craniofacial features have been well described and can aid in clinical diagnosis, the dental phenotypes have not been analyzed in detail for each of the RASopathies. In this review, we summarize the clinical features of the RASopathies, highlighting the reported craniofacial and dental findings.

Methods—Review of the literature.

Results—Each of the RASopathies reviewed, caused by mutations in genes that encode different proteins in the Ras pathway, have unique and overlapping craniofacial and dental characteristics.

Conclusions—Careful description of craniofacial and dental features in the RASopathies can provide information for dental clinicians treating these individuals and can also give insight into the role of Ras signaling in craniofacial development.

Keywords

RASopathy; Ras/MAPK pathway; craniofacial development; dental anomalies; malocclusion

*Co-corresponding authors: Snehlata Oberoi DDS, MDS, School of Dentistry, University of California, San Francisco, 707 Parnassus Ave, D-3000, San Francisco, CA 94143, Sneha.Oberoi@ucsf.edu, Alice Goodwin DDS, PhD, University of California, San Francisco, 513 Parnassus, HSE1509, San Francisco, CA 94143 Alice.Goodwin@ucsf.edu.

Conflict of interest

No conflict of interest to declare

Introduction

The RASopathies are a class of human genetic syndromes caused by germline mutations in genes that encode components of the Ras/mitogen-activated protein kinase (MAPK) pathway (1). The Ras pathway is an essential signaling cascade that controls many aspects of cell behavior, including proliferation, differentiation, and survival (2). The *RAS* genes, *HRAS*, *NRAS*, and *KRAS*, encode small, monomeric GTPases that are activated by upstream regulators, including receptor tyrosine kinases (RTKs), G-protein-coupled receptors, and integrins. Once activated, Ras-GTP conveys the extracellular signal through multiple effector pathways, including Raf/MEK/ERK and PI3K/AKT (Figure 1).

The RASopathies include 1. Noonan syndrome (NS); 2. Noonan syndrome with multiple lentiginos (NSML or LEOPARD syndrome); 3. neurofibromatosis type 1 (NF1); 4. Costello syndrome (CS); 5. cardio-facio-cutaneous (CFC) syndrome; 6. neurofibromatosis type 1–like syndrome (NFLS or Legius syndrome); and 7. capillary malformation–arteriovenous malformation syndrome (CM-AVM). Altogether, the RASopathies represent one of the most prevalent groups of developmental malformation syndromes, affecting more than 1 in 1,000 individuals (3). Although each of the RASopathies is a distinct syndrome caused by mutations at different points in the pathway, these syndromes share many overlapping characteristics, including craniofacial dysmorphism, cardiovascular abnormalities, musculoskeletal anomalies, cutaneous lesions, neurocognitive impairment, and increased risk of tumor formation (4). In the craniofacial complex, each syndrome has common and distinct features, and well-delineated craniofacial characteristics aid in clinical diagnosis of the RASopathies prior to genetic testing. Characterization of the craniofacial and dental features can also provide insight into the role of the Ras pathway in craniofacial development. For example, determining which of the RASopathies has a particular malocclusion and correlating the malocclusion to the disrupted gene has the potential to increase our understanding of the genetics underlying malocclusion and advance personalized orthodontics. In this review, we summarize the clinical characteristics and genetic etiologies of each of the most common RASopathies, emphasizing the craniofacial and dental features of these syndromes (summarized in Table 1).

Noonan syndrome (NS)

NS (OMIM 163950) is a relatively common, autosomal dominant inherited disorder with a prevalence between 1:1000 and 1:2500 live births. Individuals with NS typically have reduced postnatal growth and short stature, congenital heart defects, including hypertrophic cardiomyopathy (HCM), skeletal anomalies, and cognitive deficits (5, 6). NS is a genetically heterogeneous disorder, and germline mutations in more than 10 genes have been associated with the syndrome. The 3 genes primarily affected in NS are *PTPN11*, mutated in ~50% of cases; *SOS1* (~10%); and *RAF1* (5–10%) (7). NS is less frequently associated with mutations in *KRAS*, *NRAS*, *BRAF*, *SOS2*, *RASA2*, *LZTR1*, *RRAS*, and *RIT* (1, 8, 9).

Craniofacial features of NS include relative macrocephaly, distinctive “triangular facies” with high forehead, hypertelorism, and pointed chin, downslanting palpebral fissures, epicanthal folds, ptosis, and low-set, posteriorly rotated ears with thickened helices (Figure

2A, B). Other NS craniofacial features include short and/or webbed neck and a low posterior hairline. Although rare, benign multiple giant cell lesions (MGCLs) of hard and/or soft tissues have been reported to develop in the craniofacial region of NS individuals. MGCLs are associated with jaw enlargement in 46% of affected individuals, and lesions of the mandible, and to a lesser extent of the maxilla, are first detected between ages 2 and 19 years (10, 11).

Oral findings in NS individuals, reported in case studies, include micrognathia, high-arched palate, dental malocclusion, impacted teeth, and giant cell lesions in the maxilla and mandible (12). In a cohort of mutation positive NS subjects (N=20), we noted a normal distribution of class I occlusion and class II malocclusion and increased incidence of open bite (29%; $p=0.0001$) and posterior crossbite (30%; $p=0.0001$) compared to the general population (Figure 3A, B). More severe dental phenotypes have been reported, including a case report of a 13-year-old boy with multiple unerupted permanent teeth, multiple submerged and retained deciduous teeth, and supernumerary teeth (13).

Noonan syndrome with multiple lentiginos (NSML or LEOPARD syndrome)

NSML (OMIM 151100) is a rare, autosomal dominant genetic disorder that overlaps phenotypically with NS. The prevalence of NSML is unknown; however, more than 200 patients have been reported (14). The syndrome was formerly referred to as LEOPARD syndrome, an acronym that describes the disorder: Lentiginos; Electrocardiographic conduction abnormalities; Ocular hypertelorism; Pulmonic valve stenosis; Abnormal genitalia; Retardation of growth; and sensorineural Deafness (15). In addition, features of NSML include poor linear growth/short stature, cardiac abnormalities, particularly HCM, skeletal anomalies, cognitive deficits, sensorineural hearing loss, and café-au-lait macules. NSML is a genetically heterogeneous disorder caused by mutations in 3 genes: *PTPN11*, *RAF1*, and *BRAF* (16).

NSML individuals have NS-like facial features, although the features of NSML are considered to be milder than NS. In addition, craniofacial features of NSML include mandibular prognathism, macroglossia, and short, but usually not webbed, neck with nuchal skin (16). The characteristic multiple lentiginos, which are flat, black-brown macules, are primarily present on the face, neck, and upper torso. Typically, lentiginos start to appear at the age of 4 to 5 years old and increase in number exponentially throughout childhood to reach into the thousands by puberty. Café-au-lait spots, or hyperpigmented lesions that vary in size and in color from light to dark brown, are also observed, alone or in association with lentiginos, in up to 70–80% of NSML individuals and usually precede the appearance of lentiginos.

The oral features of NSML have not been well delineated in the literature; however, case reports show variability in the dental phenotype. One case report documented high-arched palate, primary maxillary central incisor caries, missing primary mandibular left lateral incisor, and increased overjet (17). Dental anomalies such as maxillary lateral incisor and canine agenesis and decreased head circumference have also been reported (18). A recent case study reported an NSML individual with bilateral facial swelling due to unusual

mandibular osteolytic lesions with multiple osteoclastic-like giant cells and disrupted tooth eruption (19).

Neurofibromatosis type 1 (NF1)

NF1 (OMIM 162200) is an autosomal dominant disorder caused by mutations in the tumor suppressor gene *NF1*, with a prevalence of 1:3,000 live births (20). The features of NF1 include dermatologic abnormalities, such as café-au-lait macules, ocular defects including Lisch nodules, skeletal anomalies like dysplastic bony changes and cysts, and neural defects including optic pathway gliomas. The hallmark feature of NF1 is the development of plexiform neurofibromas, which are benign tumors of peripheral nerve sheaths. These tumors have the potential to transform into malignant peripheral nerve sheath tumors (MPNSTs) that affect 10% of NF1 individuals (21).

The distinctive neurofibromas of NF1 can occur in the head and neck region. Although benign, these tumors are expansive and can cause deformities due to involvement of soft tissue and bones of the orbital, cranial and jaw regions; these are typically hemifacial but can also be bilateral (22). Café-au-lait spots can develop on the scalp and skin of the peri- and intra-orbital, maxillary, and mandibular regions. Intraoral findings include dental irregularities, such as retained deciduous molars and congenitally missing mandibular second molars. There have been reports of hypoplasia of the mandibular body and ramus and abnormal coronoid process and zygomatic arch shape (23). Mandibular cysts have also been reported, which resulted in mandibular expansion with convex outer contour and increased vertical height (22).

Costello syndrome (CS)

CS (OMIM 218040) is a rare, multiple anomaly syndrome caused by activating, germline mutations in *HRAS* with severe failure to thrive, growth retardation, dermatologic abnormalities, heart defects, including HCM, musculoskeletal anomalies, intellectual disability, and a predisposition to malignancies; the prevalence is estimated to be 1:1,290,000 (24).

CS individuals have a distinct “coarse” facial appearance that includes relative macrocephaly with high forehead, bitemporal narrowing, hypertelorism appearance, downslanting palpebral fissures, epicanthal folds, short nose with depressed bridge and wide nasal tip, full cheeks, large mouth, thick lips, and low set, posteriorly rotated ears ((25), Figure 2C, D). Intraoral findings include high-arched palate and malocclusion with increased incidence of class III malocclusion, posterior crossbite, and open bite (Figure 3C, D). Bifid uvula, gingival hypertrophy, and thickening of the alveolar ridge have also been reported in CS. Additionally, CS individuals have delayed tooth development and eruption and a unique enamel defect characterized by thin, hypomineralized enamel (26).

Cardio-facio-cutaneous (CFC) syndrome

CFC (OMIM 115150) is a rare (prevalence 1:810,000 live births (27)), autosomal dominant, multiple congenital anomalies syndrome that significantly overlaps with NS and CS, making the clinical diagnosis challenging, particularly during the neonatal stage. CFC is

characterized by failure to thrive, growth retardation, congenital heart defects, including HCM and septal defects, dermatologic abnormalities, such as pigmented lesions and hemangiomas, ectodermal abnormalities, including hyperkeratotic skin, neurocognitive delay, seizures, cognitive deficiency, and gastrointestinal dysfunction (28). CFC can be caused by activating, heterozygous mutations in *KRAS*, *BRAF*, *MAP2K1*, and *MAP2K2* (29).

Craniofacial features of CFC include relative macrocephaly, which is usually associated with high cranial vault and forehead, bitemporal narrowing, hypoplastic supraorbital ridges, hypertelorism appearance, short nose with depressed nasal bridge and wide nasal tip, and low set posteriorly rotated ears (Figure 2E, F). Intraoral findings of CFC include high-arched palate, anterior open bite, and posterior crossbite ((30), Figure 3E, F).

Neurofibromatosis type 1-like syndrome (NFLS or Legius Syndrome)

NFLS (OMIM 611431) is an autosomal dominant disorder that overlaps phenotypically with NF1; however, NFLS is less severe. NFLS is caused by inactivating mutations in *SPRED1* (31). The prevalence of Legius syndrome is not known; however, studies show nearly 2% of NF1 individuals have *SPRED1* mutations (32). Individuals with NFLS typically have multiple cafe-au-lait spots, sometimes associated with skin fold freckling, lipomas, and mild learning disabilities; however, NFLS individuals do not present with neurofibromas, optic gliomas, Lisch nodules, or MPNSTs observed in NF1. Craniofacial features of NFLS include macrocephaly and hypertelorism (33).

Capillary malformation-arteriovenous malformation syndrome (CM-AVM)

CM-AVM (OMIM 163000) is an autosomal dominant disorder caused by mutations in *RASA1* characterized by capillary malformations (CMs), that may be associated with high flow lesions, arteriovenous malformations (AVMs), and arteriovenous fistulas (AVFs) (34). These CMs, AVMs, and AVFs are multifocal and can be cutaneous, subcutaneous, intramuscular, or intraosseous and can also appear in various internal organs, including the heart and the brain. The prevalence of CM-AVM is not known.

CM-AVMs can be present on the face (forehead, lip, and/or nose) and/or neck. In the craniofacial region, CM-AVMs may cause soft tissue hypertrophy, and intraosseous AVMs in the maxilla or mandible may cause occlusal distortion, tooth mobility, and gingival bleeding (35).

Discussion

Here, we reviewed the reported craniofacial and dental findings of the most common RASopathies. Although the analysis of dental findings in the RASopathies in the literature is limited, oral features may prove useful in diagnosis. For example, CFC and NSML are similar syndromes, and while a distinguishing feature of NSML is the development of lentiginosities, these may not present until 4 to 5 years of age, making early diagnosis difficult. From the limited case reports available, missing teeth in both primary and permanent dentition have been noted in NSML but not CFC individuals. Thus, tooth number could provide a diagnostic feature to differentiate NSML from CFC. However, much work is

necessary to carefully delineate the oral and dental findings in large cohorts of individuals with the RASopathies in order to use these features as diagnostic criteria.

In addition, characterization of intraoral and dental features of the RASopathies can help dentists and orthodontists treat these individuals. NS, CS, and CFC individuals should be monitored for development of malocclusion and referred to an orthodontist at the appropriate time, possibly in early mixed dentition to treat crossbite and class III malocclusion. However, additional clinical studies are necessary to provide clear treatment guidelines.

Finally, the RASopathies may be used as genetic models to understand malocclusion. For example, analyzing the malocclusion in a particular RASopathy, such as class III malocclusion in CS, and correlating to the causative gene, *HRAS* in this case, may begin to further elucidate the genetics underlying malocclusion. Once we understand more fully the genes involved in specific malocclusions, we may modulate these genes and the proteins they encode to treat patients in a more precise method, thus advancing the goal of personalized orthodontics.

Acknowledgments

Financial support for this work was provided by the program of China Scholarships Council (H.C.), K12-DE023574-04 and AAOF PFA CA-0089103 (A.F.G.), and R01-DE024988 (O.D.K.).

References

1. Aoki Y, Niihori T, Inoue S, Matsubara Y. Recent advances in RASopathies. *J Hum Genet.* 2016; 61:33–9. [PubMed: 26446362]
2. Aoki Y, Niihori T, Narumi Y, Kure S, Matsubara Y. The RAS/MAPK syndromes: novel roles of the RAS pathway in human genetic disorders. *Hum Mutat.* 2008; 29:992–1006. [PubMed: 18470943]
3. Tidyman WE, Rauen KA. Pathogenetics of the RASopathies. *Human Molec Genet.* 2016; 25:R123–32. [PubMed: 27412009]
4. Rauen KA. The RASopathies. *Annu Rev Genomics Hum Genet.* 2013; 14:355–69. [PubMed: 23875798]
5. Allanson JE. Noonan syndrome. *Am J Med Genet C Semin Med Genet.* 2007; 145C:274–9. [PubMed: 17639592]
6. Noonan JA. Noonan syndrome. An update and review for the primary pediatrician. *Clin Pediatr (Phila).* 1994; 33:548–55. [PubMed: 8001324]
7. Zenker M. Genetic and pathogenetic aspects of Noonan syndrome and related disorders. *Horm Res.* 2009; 72(Suppl 2):57–63.
8. Aoki Y, Niihori T, Banjo T, Okamoto N, Mizuno S, Kurosawa K, et al. Gain-of-function mutations in *RIT1* cause Noonan syndrome, a RAS/MAPK pathway syndrome. *Am J Hum Genet.* 2013; 93:173–80. [PubMed: 23791108]
9. Tartaglia M, Gelb BD, Zenker M. Noonan syndrome and clinically related disorders. *Best Pract Res Clin Endocrinol Metab.* 2011; 25:161–79. [PubMed: 21396583]
10. Karbach J, Coerdts W, Wagner W, Bartsch O. Case report: Noonan syndrome with multiple giant cell lesions and review of the literature. *Am J Med Genet A.* 2012; 158A:2283–9. [PubMed: 22848035]
11. Romano AA, Allanson JE, Dahlgren J, Gelb BD, Hall B, Pierpont ME, et al. Noonan syndrome: clinical features, diagnosis, and management guidelines. *Pediatrics.* 2010; 126:746–59. [PubMed: 20876176]

12. Mallineni SK, Yung Yiu CK, King NM. Oral manifestations of Noonan syndrome: review of the literature and a report of four cases. *Rom J Morphol Embryol*. 2014; 55:1503–9. [PubMed: 25611289]
13. Uloopi KS, Madhuri V, Gopal AS, Vinay C, Chandrasekhar R. Multiple Unerupted Permanent Teeth Associated with Noonan Syndrome. *Ann Med Health Sci Res*. 2015; 5:317–20. [PubMed: 26229724]
14. Sarkozy A, Digilio MC, Dallapiccola B. Leopard syndrome. *Orphanet J Rare Dis*. 2008; 3:13. [PubMed: 18505544]
15. Gorlin RJ, Anderson RC, Moller JH. The leopard (multiple lentigines) syndrome revisited. *Laryngoscope*. 1971; 81:1674–81. [PubMed: 4398858]
16. Digilio MC, Sarkozy A, de Zorzi A, Pacileo G, Limongelli G, Mingarelli R, et al. LEOPARD syndrome: clinical diagnosis in the first year of life. *Am J Med Genet A*. 2006; 140:740–6. [PubMed: 16523510]
17. Urs P, Konde S, Chouta N, Raj S. LEOPARD syndrome: you could be the first one to diagnose! *J Indian Soc Pedod Prev Dent*. 2015; 33:57–60. [PubMed: 25572376]
18. Yam AA, Faye M, Kane A, Diop F, Coulybaly-Ba D, Tamba-Ba A, et al. Oro-dental and craniofacial anomalies in LEOPARD syndrome. *Oral Dis*. 2001; 7:200–2. [PubMed: 11495198]
19. Aboh IV, Chisci G, Gennaro P, Gabriele G, Cascino F, Ginori A, et al. LEOPARD syndrome: maxillofacial care. *J Craniofac Surg*. 2014; 25:1094–5. [PubMed: 24705231]
20. Oderich GS, Sullivan TM, Bower TC, Glovicski P, Miller DV, Babovic-Vuksanovic D, et al. Vascular abnormalities in patients with neurofibromatosis syndrome type I: clinical spectrum, management, and results. *J Vasc Surg*. 2007; 46:475–84. [PubMed: 17681709]
21. Bernier A, Larbrisseau A, Perreault S. Cafe-au-lait Macules and Neurofibromatosis Type 1: A Review of the Literature. *Pediatr Neurol*. 2016; 60:24–9. [PubMed: 27212418]
22. Friedrich RE, Giese M, Schmelzle R, Mautner V-F, Scheuer HA. Jaw malformations plus displacement and numerical aberrations of teeth in neurofibromatosis type 1: a descriptive analysis of 48 patients based on panoramic radiographs and oral findings. *J Craniomaxillofac Surg*. 2003; 31:1–9. [PubMed: 12553919]
23. Hunt JA, Hobar PC. Common craniofacial anomalies: conditions of craniofacial atrophy/hypoplasia and neoplasia. *Plast Reconstr Surg*. 2003; 111:1497–508. [PubMed: 12618611]
24. Rauen KA. HRAS and the Costello syndrome. *Clin Genet*. 2007; 71:101–8. [PubMed: 17250658]
25. Goodwin AF, Oberoi S, Landan M, Charles C, Massie JC, Fairley C, et al. Craniofacial and dental development in Costello syndrome. *Am J Med Genet A*. 2014; 164a:1425–30. [PubMed: 24668879]
26. Goodwin AF, Tidyman WE, Jheon AH, Sharir A, Zheng X, Charles C, et al. Abnormal Ras signaling in Costello syndrome (CS) negatively regulates enamel formation. *Hum Mol Genet*. 2014; 23:682–92. [PubMed: 24057668]
27. Pierpont ME, Magoulas PL, Adi S, Kavamura MI, Neri G, Noonan J, et al. Cardio-facio-cutaneous syndrome: clinical features, diagnosis, and management guidelines. *Pediatrics*. 2014; 134:e1149–62. [PubMed: 25180280]
28. Reynolds JF, Neri G, Herrmann JP, Blumberg B, Coldwell JG, Miles PV, et al. New multiple congenital anomalies/mental retardation syndrome with cardio-facio-cutaneous involvement--the CFC syndrome. *Am J Med Genet*. 1986; 25:413–27. [PubMed: 3789005]
29. Niihori T, Aoki Y, Narumi Y, Neri G, Cave H, Verloes A, et al. Germline KRAS and BRAF mutations in cardio-facio-cutaneous syndrome. *Nat Genet*. 2006; 38:294–6. [PubMed: 16474404]
30. Goodwin AF, Oberoi S, Landan M, Charles C, Groth J, Martinez A, et al. Craniofacial and dental development in cardio-facio-cutaneous syndrome: the importance of Ras signaling homeostasis. *Clin Genet*. 2013; 83:539–44. [PubMed: 22946697]
31. Brems H, Pasmant E, Van Minkelen R, Wimmer K, Upadhyaya M, Legius E, et al. Review and update of SPRED1 mutations causing Legius syndrome. *Hum Mutat*. 2012; 33:1538–46. [PubMed: 22753041]
32. Stevenson, D., Viskochil, D., Mao, R. Legius Syndrome. In: Pagon, RA, Adam, MP, Ardinger, HH., et al., editors. *GeneReviews*® [Internet]. Seattle (WA): University of Washington, Seattle; p. 1993-2016.

33. Benelli E, Bruno I, Belcaro C, Ventura A, Berti I. Legius syndrome: case report and review of literature. *Ital J Pediatr.* 2015; 41:8. [PubMed: 25883013]
34. Eerola I, Boon LM, Mulliken JB, Burrows PE, Domp Martin A, Watanabe S, et al. Capillary malformation-arteriovenous malformation, a new clinical and genetic disorder caused by RASA1 mutations. *Am J Hum Genet.* 2003; 73:1240–9. [PubMed: 14639529]
35. Macmurdo CF, Wooderchak-Donahue W, Bayrak-Toydemir P, Le J, Wallenstein MB, Milla C, et al. RASA1 somatic mutation and variable expressivity in capillary malformation/arteriovenous malformation (CM/AVM) syndrome. *Am J Med Genet A.* 2016; 170:1450–4. [PubMed: 26969842]

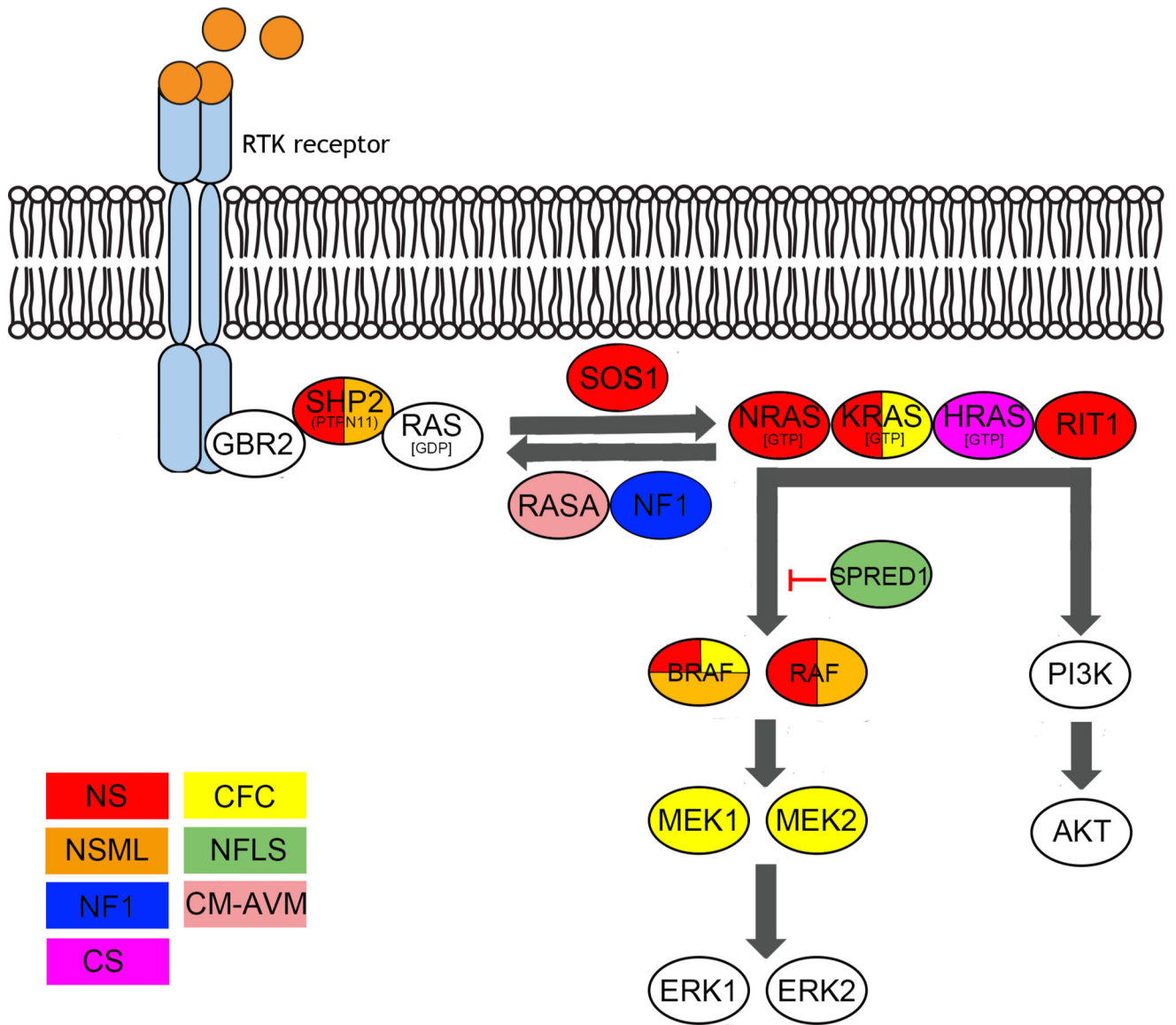


Figure 1. Syndromes of the Ras pathway

Schematic representation of the Ras signaling pathway. Each syndrome is represented by a color, and the protein in the pathway encoded by the causative mutated gene is illustrated in that color.

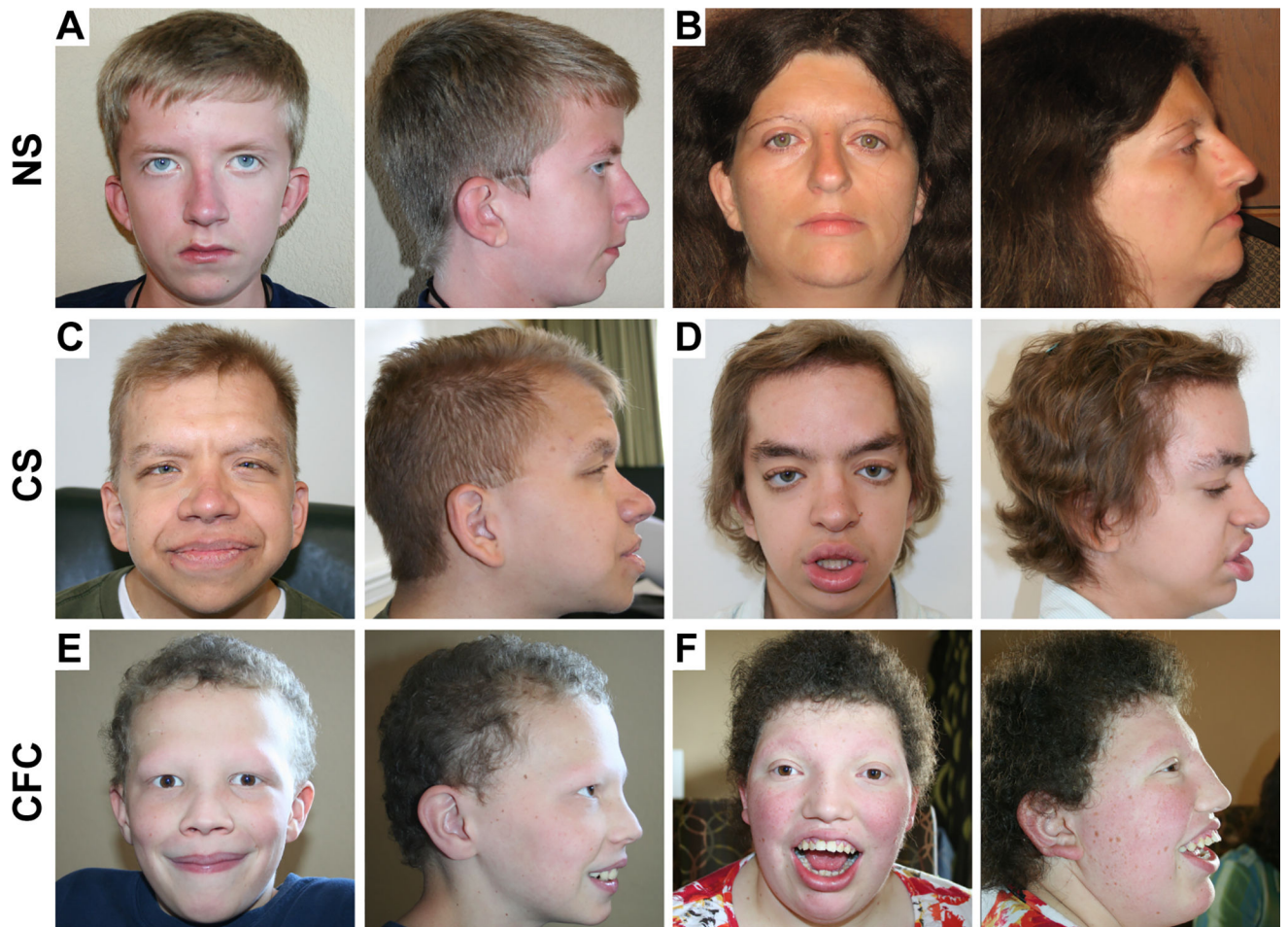


Figure 2. Craniofacial features of NS, CS, and CFC

Frontal and profile photographs of (A) a 15-year-old male and (B) 31-year-old female with NS, (C) 26-year-old male and (D) 17-year-old female with CS, and (E) 12-year-old male and (F) 17-year-old female with CFC.

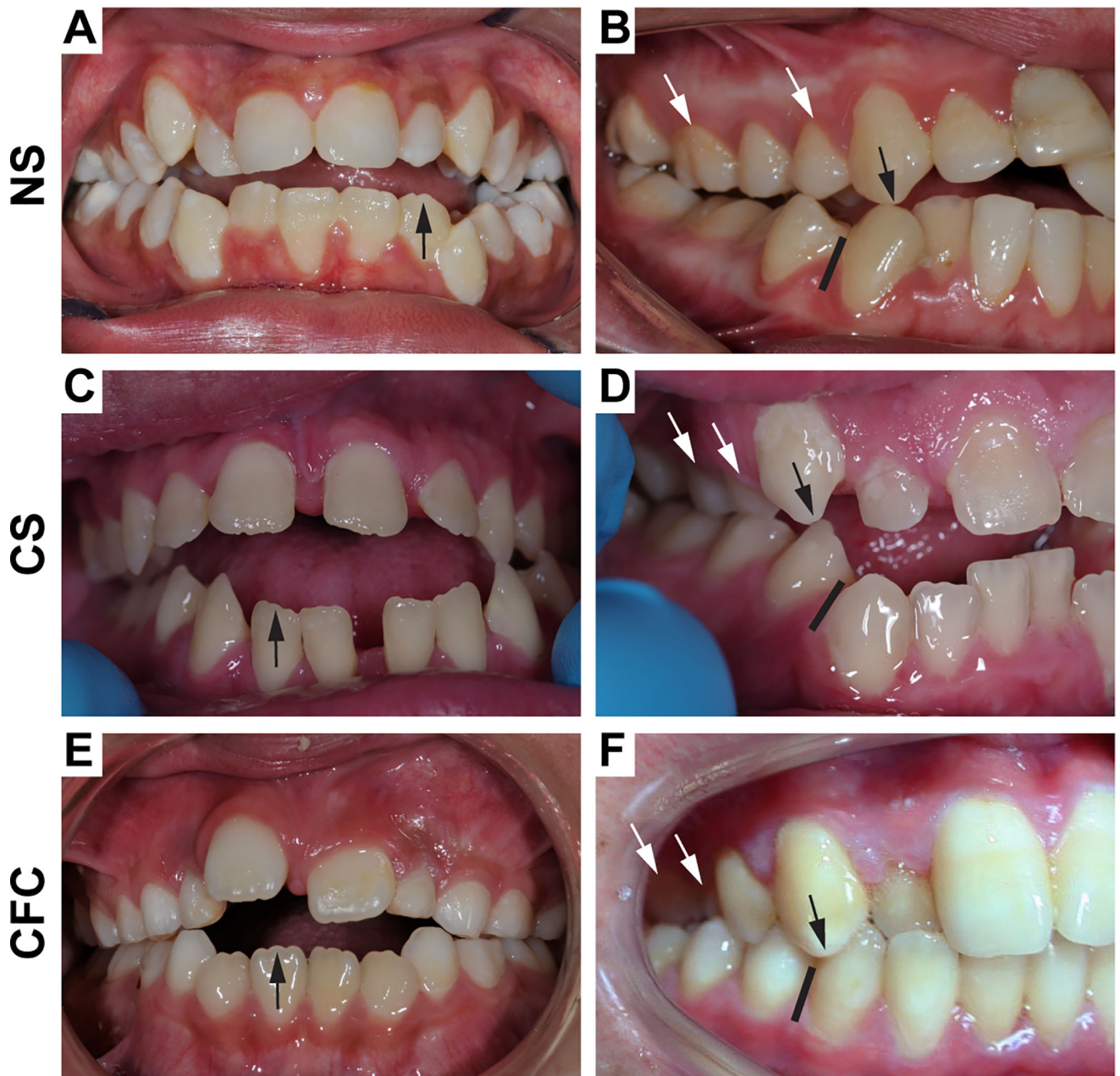


Figure 3. Dental characteristics of NS, CS, and CFC

(A, C, E) Open bite. Black arrows point to mamelons, which are normally abraded by contact. (B, D, F) Posterior crossbite (demarcated by white arrows). (B) Individuals with NS present with expected incidence of class I occlusion and class II malocclusion as shown by black arrow demarcating maxillary canine cusp tip anterior relative to the contact between the mandibular canine and first premolar (black line). (D) CS individuals have higher incidence of class III malocclusion with the maxillary canine (black arrow) posterior to the contact (black line) while (F) CFC individuals present with normal distribution of class I

occlusion with the maxillary canine (black arrow) in line with the contact (black line) or class II malocclusion (as shown in B).

Author Manuscript

Author Manuscript

Author Manuscript

Author Manuscript

Table 1

Craniofacial and dental findings of the RASopathies

Syndrome	Associated Gene	Craniofacial Findings	Dental Findings	Reference for Craniofacial and Dental Findings
Noonan syndrome (NS)	<i>PTPN11, SOS1, RAF1, KRAS, NRAS, BRAF, SOS2, RASA2, LZTR1, RRAS, RIT1</i>	Relative macrocephaly, "triangular facies" with high forehead, hypertelorism, and pointed chin, downslanting palpebral fissures, epicanthal folds, ptosis, low-set, posteriorly rotated ears, short and/or webbed neck, low posterior hairline	High-arched palate, open bite, posterior crossbite Case reports: Multiple giant cell lesions (MGCLs) in the jaws or soft tissues, multiple unerupted permanent teeth, multiple submerged and retained deciduous teeth, supernumerary teeth	[10–13]
NS with multiple lentiginos (NSML or LEOPARD syndrome)	<i>PTPN11, RAF1, BRAF</i>	NS-like facies, multiple lentiginos and café-au-lait spots on the face and neck, short neck with nuchal skin (usually not webbed), mandibular prognathism, macroglossia	Case report: high-arch palate, missing primary and permanent teeth, mandibular osteolytic lesions, disrupted tooth eruption	[17–19]
Neurofibromatosis type 1 (NF1)	<i>NF1</i>	Neurofibromas in head and neck region that may cause deformities, café-au-lait spots	Hypoplastic mandible, mandibular cysts, retained deciduous teeth, missing permanent teeth	[22, 23]
Costello syndrome (CS)	<i>HRAS</i>	Coarse facies, relative macrocephaly, high forehead, bitemporal narrowing, hypertelorism appearance, downslanting palpebral fissures, epicanthal folds, short nose with depressed bridge and wide nasal tip, full cheeks, large mouth, thick lips, low set, posteriorly rotated ears	High-arched palate, thickening of alveolar ridge, class III malocclusion, open bite, posterior crossbite, gingival hypertrophy, delayed tooth development and eruption, hypoplastic enamel defect	[25, 26]
Cardio-facio-cutaneous syndrome (CFC)	<i>KRAS, BRAF, MAP2K1, MAP2K2</i>	Relative macrocephaly, high cranial vault and forehead, bitemporal narrowing, hypoplastic supraorbital ridges, hypertelorism appearance, short nose with depressed nasal bridge and wide nasal tip, low set, posteriorly rotated ears	High-arched palate, open bite, posterior crossbite	[30]
Neurofibromatosis type 1-like syndrome (NFLS or Legius syndrome)	<i>SPRED1</i>	Macrocephaly, hypertelorism, café-au-lait spots in head and neck region	Not reported	[33]
Capillary malformation-arteriovenous syndrome (CM-AVM)	<i>RASA1</i>	CM-AVMs in head and neck region may cause soft tissue hypertrophy	Intraosseous CM-AVMs in the maxilla and mandible may cause malocclusion,	[35]

Syndrome	Associated Gene	Craniofacial Findings	Dental Findings	Reference for Craniofacial and Dental Findings
			tooth mobility, and gingival bleeding	

Author Manuscript

Author Manuscript

Author Manuscript

Author Manuscript