

UCSF

UC San Francisco Previously Published Works

Title

Congenital Pseudoarthrosis of the Distal Radius Treated With Physeal-Sparing Double-Barrel Vascularized Free Fibula Transfer: A Case Report

Permalink

<https://escholarship.org/uc/item/6pn1m4sm>

Journal

Hand, 12(5)

ISSN

1558-9447

Authors

Ding, David Y
LaMartina, Joey
Tai, Chau
et al.

Publication Date

2017-09-01

DOI

10.1177/1558944717702472

Copyright Information

This work is made available under the terms of a Creative Commons Attribution License, available at <https://creativecommons.org/licenses/by/4.0/>

Peer reviewed

Congenital Pseudoarthrosis of the Distal Radius Treated With Physeal-Sparing Double-Barrel Vascularized Free Fibula Transfer: A Case Report

HAND
2017, Vol. 12(5) NP140–NP144
© The Author(s) 2017
Reprints and permissions:
sagepub.com/journalsPermissions.nav
DOI: 10.1177/1558944717702472
hand.sagepub.com

David Y. Ding¹, Joey LaMartina², Chau Tai³, and Nirav K. Pandya^{2,3}

Abstract

Background: Neurofibromatosis type I is a hereditary disease that can lead to pseudoarthrosis of various long bones. Rarely, pseudoarthrosis affects the forearm, and to the best of our knowledge, this is the first reported case of pseudoarthrosis of the distal radius treated by this unique method. **Methods:** We present a case of a 7-year-old male who underwent multiple operations to treat pseudoarthrosis of the distal radius. **Results:** After failed conservative and operative fixation augmented with autologous iliac crest bone grafting, the patient underwent a successful double-barrel vascularized free fibula graft while preserving the physis of the distal radius. **Conclusion:** Double-barrel vascularized free fibula bone graft can be successfully used as the definitive treatment in refractory cases of distal forearm pseudoarthrosis and we believe that our technique can be applied to all cases of pseudoarthrosis in other patients with a similar presentation and lesion location.

Keywords: congenital pseudoarthrosis, vascularized free fibular graft, distal radius fracture, neurofibromatosis, forearm fracture

Introduction

Neurofibromatosis type 1 (NF1) is a hereditary disease affecting 1 out of 3000 births worldwide. Although pathognomonic findings include neurofibromas, café-au-lait spots, and Lisch nodules, orthopedic manifestations are common, including short stature, kyphoscoliosis, congenital bowing, and pseudoarthrosis of the tibia.³ Congenital pseudoarthrosis associated with NF1 is often very difficult to treat. Occurring in approximately 13% of neurofibromatosis patients, pseudoarthrosis more commonly affects the tibia or fibula.⁶ Rare case reports have described pseudoarthrosis developing in the forearm with treatments ranging from bone grafting³ to vascularized fibular graft.^{8,10} We report a unique case of pseudoarthrosis of the distal radius treated by double-barrel vascularized free fibula graft.

Methods and Results

A 7-year-old male initially presented to another physician's office with a minimally displaced both-bone forearm fracture. He was initially treated with a short-arm cast that was removed 1 month after injury. At that time, the patient had

no pain at the fracture site and was converted to a removable forearm splint (Figures 1a and 1b). Bowing of the radius and ulna was noted at the time of the radiography. He then subsequently presented to our clinic 2 years later, at that time he was noted to have a swollen deformed wrist. He had fallen 2 months earlier but did not seek orthopedic care as he had minimal to no pain. Imaging demonstrated a pseudoarthrosis of the distal radius (Figures 2a and 2b). During further history and physical examination, it was noted that the patient had café-au-lait spots and Lisch nodules, which led to the diagnosis of NF1.

Treatment options were discussed with the family, including operative management involving open reduction internal fixation with autogenous iliac crest bone graft (ICBG) or a vascularized fibula transfer. The decision was

¹The Permanente Medical Group, San Francisco, CA, USA

²University of California, San Francisco, USA

³UCSF Benioff Children's Hospital Oakland, CA, USA

Corresponding Author:

David Y. Ding, Department of Orthopaedic Surgery, The Permanente Medical Group, 1600 Owens Street, 2nd Floor, San Francisco, CA 94158, USA.
Email: daviddingmd@gmail.com

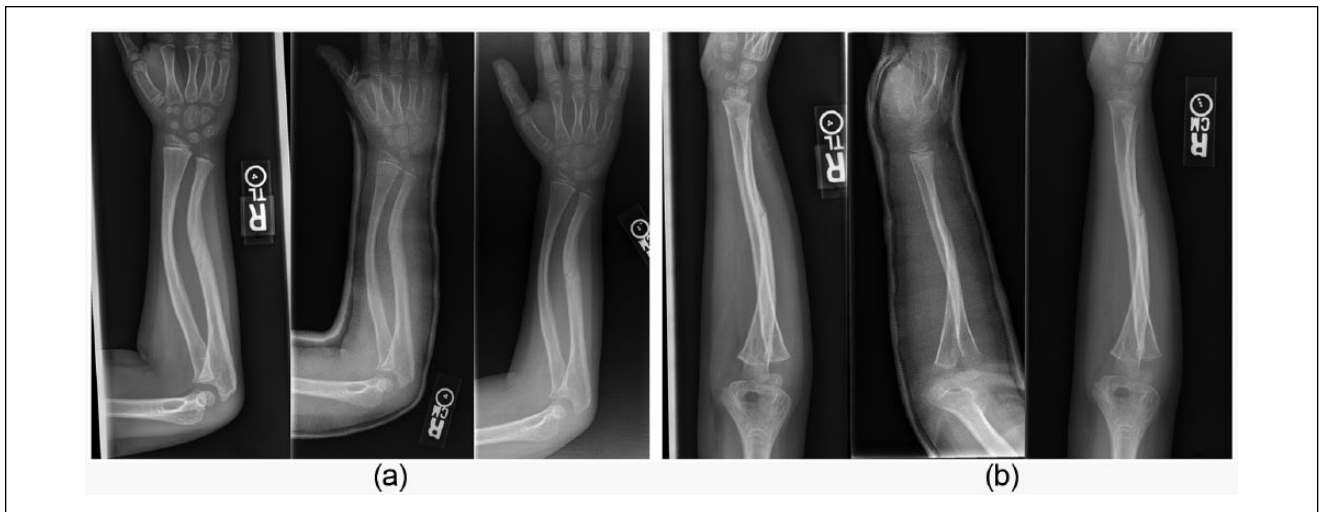

Figure 1. Radiographs after the patient sustained his initial injury. (a) Anterior-posterior and (b) lateral radiographs of both-bone forearm fracture, sustained by a 7-year-old boy, treated in a long-arm cast. Radiographs shown are at the time of injury, 2 weeks, and 4 weeks, respectively.

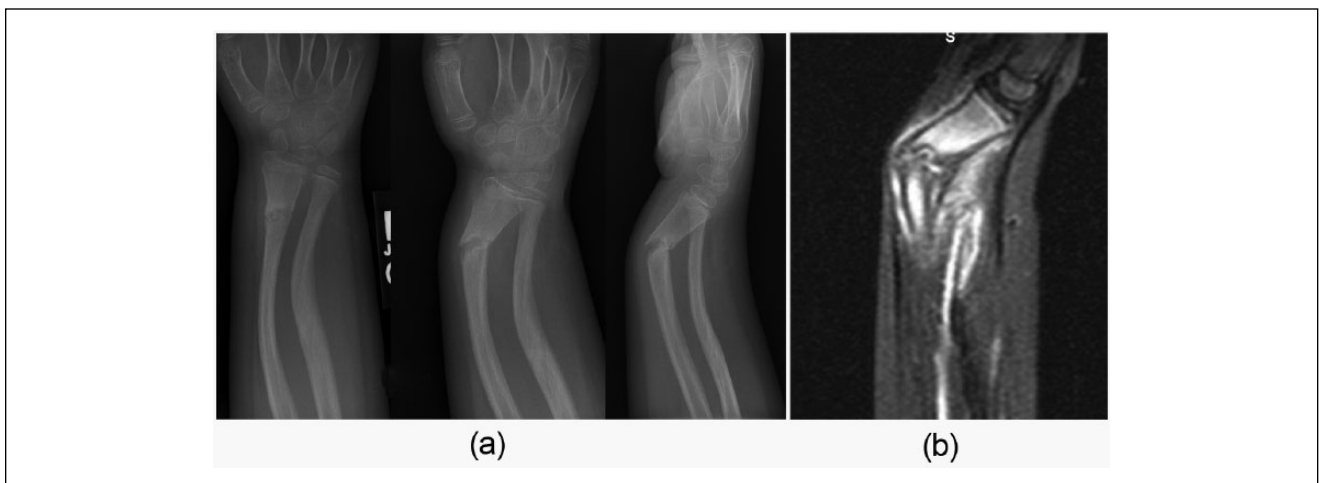


Figure 2. Images after the patient sustained a subsequent injury to his distal radius. (a) Radiographs show a repeat fracture while the (b) magnetic resonance imaging shows a pseudoarthrosis of the distal radius.

made to start with the less complicated surgery involving ICBG with the understanding that additional surgery would be needed if this was unsuccessful. The patient tolerated this procedure well with no issues early on (Figure 3). However, over the next 6 months, follow-up radiographs demonstrated a gradual loss of reduction (Figures 4a-4d). As a result, the decision to proceed with the vascularized free fibula transfer was made.

At this point, it had been 18 months since the patient's initial distal radius fracture. A team consisting of orthopedic surgery and plastic hand surgery collaborated to reconstruct the patient's distal radius using a vascularized free fibula transfer. During the operation, the pseudoarthrosis was removed, and a 6-cm bone defect was noted. The middle 12 cm of the patient's

fibula was removed with a vascular pedicle, staying 10 cm away from both the proximal and distal fibula. Due to the small caliber of the fibula (~8 mm), it was folded in half to create a double-barrel type of graft. The graft was stabilized using k-wires proximally and distally. Additional internal plate fixation was deferred as to not put additional pressure on the vascular pedicle. The fibular vascular pedicle was maintained throughout the case and anastomosed to the radial artery that was transected at a 45-degree angle to provide a larger lumen. An external fixator was placed to supplement the fixation (Figure 5). The patient was monitored in the intensive care unit postoperatively with hourly Doppler monitoring on the pedicle for the first 24 hours, then every 2 hours the next 24 hours, and then every 4 hours the next 24 hours.

Given the amount of swelling, the forearm wound was kept open, and a split thickness skin graft was applied 5 days later. Follow-up radiographs over the next 6 months demonstrated gradual healing of the free fibula graft. The ex-fix was completely removed at 8 months postoperatively. There were no complications associated with the external fixator pins. Final follow-up 18 months after surgery showed complete incorporation and remodeling of the graft as well as a preserved distal

radius physis (Figure 6). The patient has reported no ankle problems at latest follow-up.

Discussion

To the best of our knowledge, this is the first reported case of a physal-preserving, double-barrel vascularized free fibula graft for pseudarthrosis of the distal radius after failed autologous iliac crest bone grafting and primary fixation. Pseudarthrosis of the forearm secondary to neurofibromatosis has classically been treated using bone grafting with varying success.³ However, with improvements in microvascular surgery, vascularized free fibular grafts have been used more successfully. Bauer et al² reported on 5 cases with successful resolution of forearm pseudarthrosis treated with free fibular grafts. Olekas and Guobys⁹ published successful primary union in 11 of 15 patients treated with vascularized grafts who had failed as many as 6 previous operations for pseudarthrosis of the forearm. Mathoulin et al⁸ reported on 6 cases of single or both-bone forearm pseudarthrosis treated with good results with vascularized fibular grafts, 5 of which carried a diagnosis of NF1 like our patient. In each of these series and others in the literature, all vascularized grafts were single-strut constructs. In our patient's case, an attempt at autologous bone grafting ultimately failed. Also given the more distal location of the pseudarthrosis in the radius, the width of the native bone was greater than that of a single

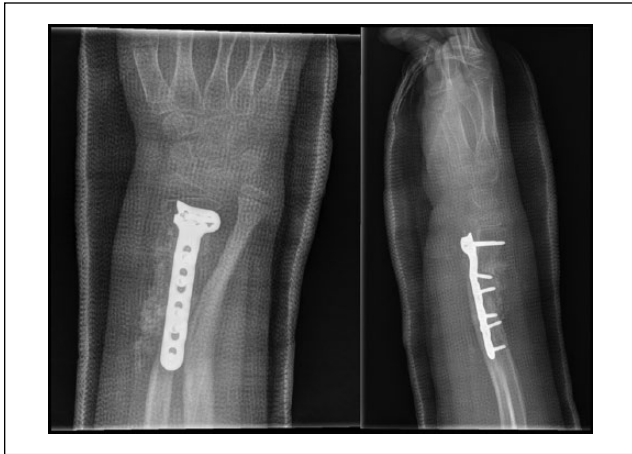


Figure 3. The injury did not heal with nonoperative management so the patient underwent surgical fixation and autologous iliac crest bone grafting.

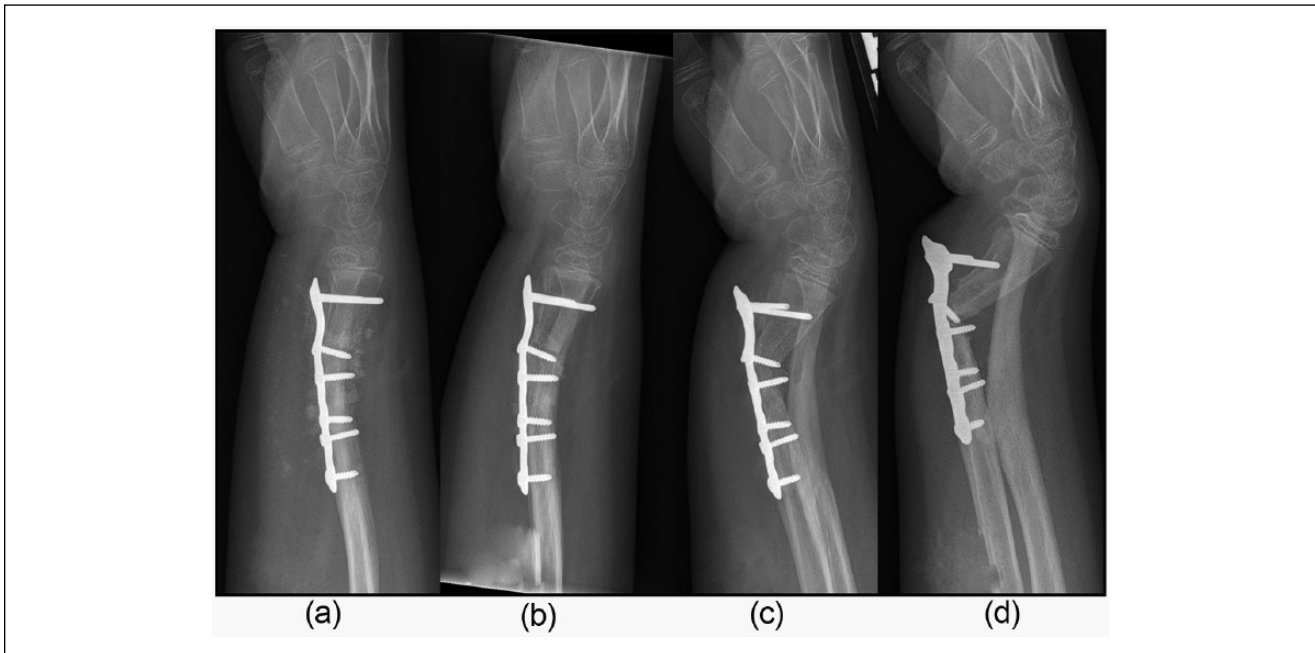


Figure 4. Sequence of events following an attempted open reduction internal fixation. (a) Radiographs at the time of surgery, (b) 1 month, (c) 3 months, and (d) 10 months, demonstrated a gradual loss of reduction. The patient returned to his native country between 3 and 10 months, which accounted for the loss of follow-up.

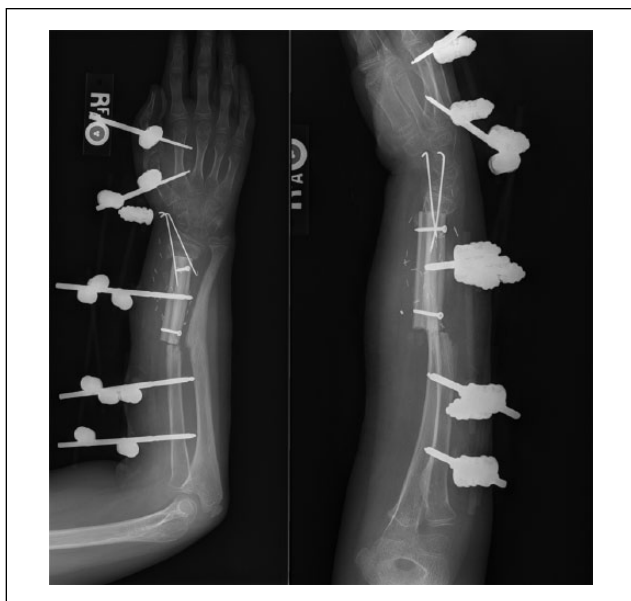

Figure 5. Postoperative radiographs following the open reduction, double-barrow vascularized free fibular graft, and ex-fix placement.

fibular strut. As a result, a double-barrel vascularized free fibular graft was used to better match the native bony anatomy, so far yielding a promising result.

Another issue with our patient's case was the rapid resorption of the ICBG from his first operation and the subsequent lack of bone available distally to unite with the double-barrel vascularized fibular graft in the second operation. Boyd et al⁴ reported a significant association with nonunion and age of surgery. Although 86% of his patients over the age of 5 years achieved union, only 14% of his patients who underwent surgery under the age of 5 years achieved union. This was thought to be secondary to rapid resorption of graft in younger patients and poor fixation to small osteoporotic fragments.⁷ Our patient was significantly older but still encountered the same complications. Our first attempt at bone grafting was unsuccessful secondary to rapid resorption. We also encountered difficulty in stabilizing the double-barrel vascularized fibula graft due to the bulk of the graft and the small remnant osteopenic fragments of the patient's native radius distally. In reviewing the literature, a number of techniques have been used to stabilize the fibular graft, including cross-pinning, intramedullary rods, stepcut osteotomies with screw fixation, plate fixation, and external fixators.^{1,8,9} Due to the small segment of bone distally in our patient, an external fixator was added to the cross-pinned fibular graft to provide enough stability to allow for healing of the graft.

Pseudarthrosis is typically only a regional disorder, affecting only certain bones—tibia/fibula and radius/ulna.

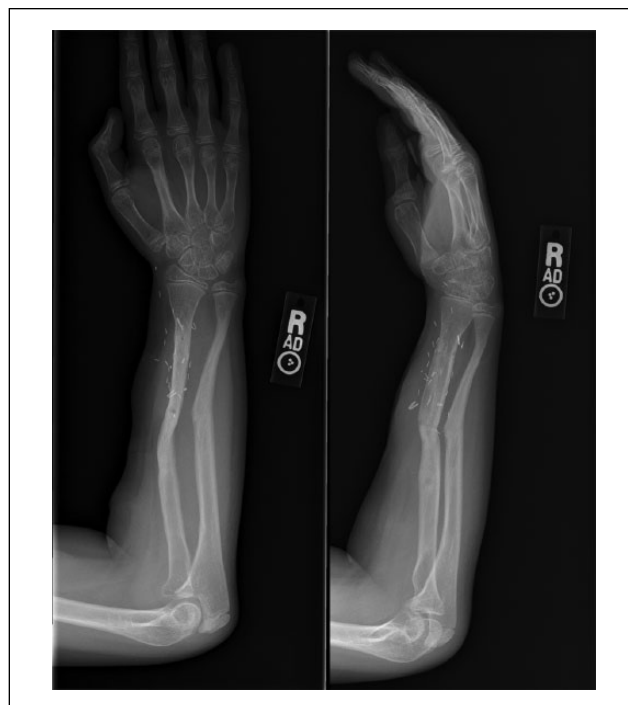

Figure 6. Final follow-up 18 months after surgery showed complete incorporation and remodeling of the graft as well as a preserved distal radius growth plate.

Although pseudarthrosis may involve both the radius and ulna as in our case report, we believe that stabilizing the radius will help stabilize the ulna. The histology is nonspecific—thickened fibrous tissue accompanied by a paucity of vascular ingrowth without evidence of schwannoma or neurofibroma. Brown et al⁵ reiterated that histology and electron microscopy are unable to differentiate between neurofibromatous pseudarthrosis and pseudarthrosis without either neurofibromatosis or fibrous dysplasia. Fortunately, the published cases in the literature demonstrate successful use of vascularized fibular graft for pseudarthrosis in patients both with and without neurofibromatosis. Our particular patient did carry a diagnosis of NF1, but we have every reason to believe that our technique can be applied to all cases of pseudarthrosis in other patients with a similar presentation and lesion location.

Ethical Approval

This study was approved by our institutional review board.

Statement of Human and Animal Rights

All procedures followed were in accordance with the ethical standards of the responsible committee on human experimentation (institutional and national) and with the Helsinki Declaration of 1975, as revised in 2008.

Statement of Informed Consent

Informed consent was obtained from all patients for being included in the study

Declaration of Conflicting Interests

The author(s) declared no potential conflicts of interest with respect to the research, authorship, and/or publication of this article.

Funding

The author(s) received no financial support for the research, authorship, and/or publication of this article.

References

1. Allieu Y, Meyer zu Reckendorf G, Chammas M, Gomis R. Congenital pseudarthrosis of both forearm bones: long-term results of two cases managed by free vascularized fibular graft. *J Hand Surg Am.* 1999;24:604-608.
2. Bauer AS, Singh AK, Amanatullah D, Lerman J, James MA. Free vascularized fibular transfer with langenskiold procedure for the treatment of congenital pseudarthrosis of the forearm. *Tech Hand Up Extrem Surg.* 2013;17:144-150.
3. Bell DF. Congenital forearm pseudarthrosis: report of six cases and review of the literature. *J Pediatr Orthop.* 1989;9:438-443.
4. Boyd HB, Fox KW. Congenital pseudarthrosis; follow-up study after massive bone-grafting. *J Bone Joint Surg Am.* 1948;30A:274-283.
5. Brown GA, Osebold WR, Ponseti IV. Congenital pseudarthrosis of long bones: a clinical, radiographic, histologic and ultrastructural study. *Clin Orthop Relat Res.* 1977;128:228-242.
6. Crawford AH Jr, Bagamery N. Osseous manifestations of neurofibromatosis in childhood. *J Pediatr Orthop.* 1986;6:72-88.
7. Manske PR. Forearm pseudarthrosis—neurofibromatosis: case report. *Clin Orthop Relat Res.* 1979;139:125-127.
8. Mathoulin C, Gilbert A, Azze RG. Congenital pseudarthrosis of the forearm: treatment of six cases with vascularized fibular graft and a review of the literature. *Microsurgery.* 1993;14:252-259.
9. Olekas J, Guobys A. Vascularised bone transfer for defects and pseudarthroses of forearm bones. *J Hand Surg Br.* 1991;16:406-408.
10. Witoonchart K, Uerpaiojkit C, Leechavengvongs S, Thuvathakul P. Congenital pseudarthrosis of the forearm treated by free vascularized fibular graft: a report of three cases and a review of the literature. *J Hand Surg Am.* 1999;24:1045-1055.