

UC Davis
Dermatology Online Journal

Title

Mycobacterium avium complex infection

Permalink

<https://escholarship.org/uc/item/6p34j2dc>

Journal

Dermatology Online Journal, 21(12)

Authors

Vedvyas, Chetan
Shvartsbeyn, Marianna
Brinster, Nooshin
et al.

Publication Date

2015

DOI

10.5070/D32112029543

Copyright Information

Copyright 2015 by the author(s). This work is made available under the terms of a Creative Commons Attribution-NonCommercial-NoDerivatives License, available at <https://creativecommons.org/licenses/by-nc-nd/4.0/>

Peer reviewed

Case presentation

***Mycobacterium avium* complex infection**

Chetan Vedvyas MD, Marianna Shvartsbeyn MD, Nooshin Brinster MD, and Alisa Femia MD

Dermatology Online Journal 21 (12): 16

New York University School of Medicine

Special Guest Editor: Nicholas A Soter MD

Abstract

We report the case of a 30-year-old woman with a three-year history of papules, nodules, and multiple ulcers of the left lower extremity. A skin biopsy specimen showed dermal fibrosis and patchy granulomatous inflammation in the upper-to-mid dermis that was associated with a perivascular, lymphohistiocytic infiltrate along with granulomas and necrosis in the subcutaneous fat. Tissue culture showed *Mycobacterium avium* complex infection. Clinical manifestations of cutaneous nontuberculous mycobacterial infections are discussed as well as their potential association with pedicures.

Case synopsis

History: A 30-year-old woman presented to the Dermatology Clinic of Bellevue Hospital Center for the evaluation of recurrent papules, nodules, and ulcers on the left lower extremity of more than three-years duration. The patient noted that her skin lesions began as pimples, which subsequently ulcerated. The ulcers had fluctuated over time; they improved while on tetracyclines, intravenous azole antifungal medications, and holistic remedies, but never resolved. Multiple biopsies and tissue cultures performed by outside physicians failed to show a definitive diagnosis.

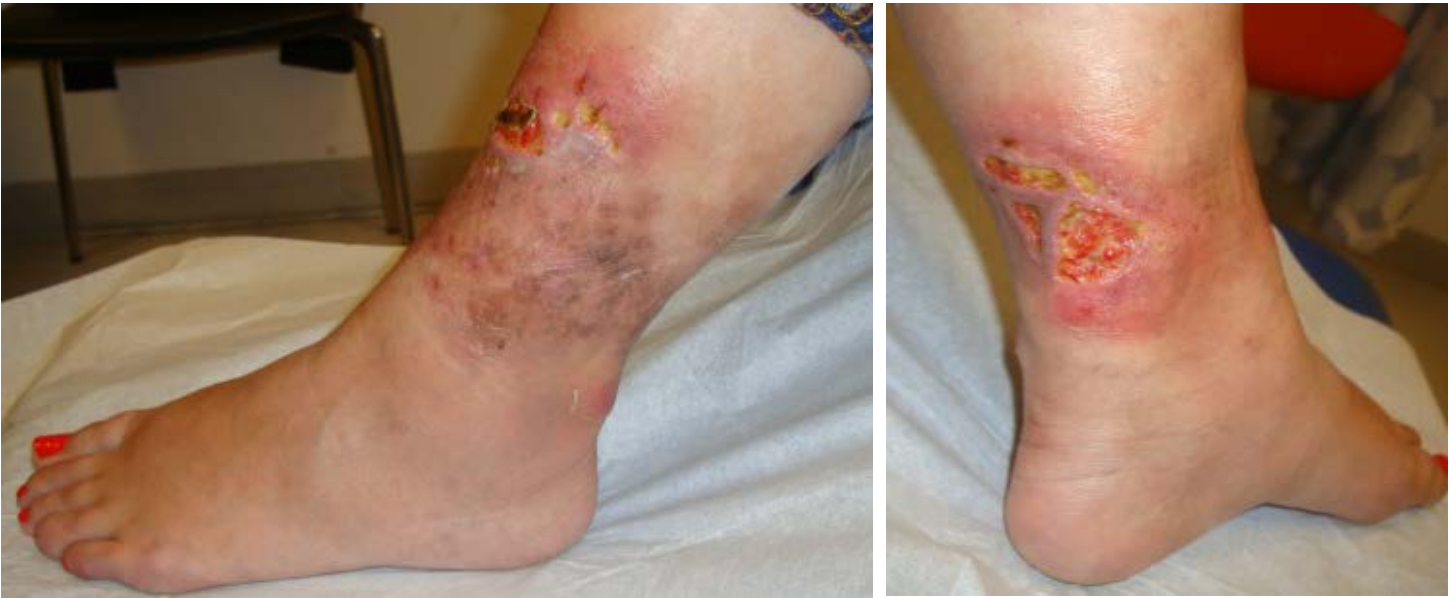Past medical history and surgical history were normal. Family history was negative for autoimmune diseases. She denied toxic habits. She was born in Colombia and her travel history included visits there and to the Caribbean. The patient recalled having undergone a pedicure and leg waxing three years prior to the onset of her skin disease. A punch biopsy was performed and tissue samples were sent for bacterial, fungal, and mycobacterial cultures. The patient was empirically treated with mupirocin, doxycycline, and topical glucocorticoids, which resulted in some improvement. Based on the results of a diagnostic study, the patient was sent for evaluation for further management to a medical specialist.

Physical examination: Several, deep ulcers, each with a clean, granulation tissue base were noted on the inferior aspect of the shin and the posterior, inferior aspect of the calf. Retiform, blanching erythema with admixed hyperpigmentation surrounded the ulcers. Inferior to the erythema and hyperpigmentation, there was an isolated, erythematous, blanching nodule, which was not tender to palpation.

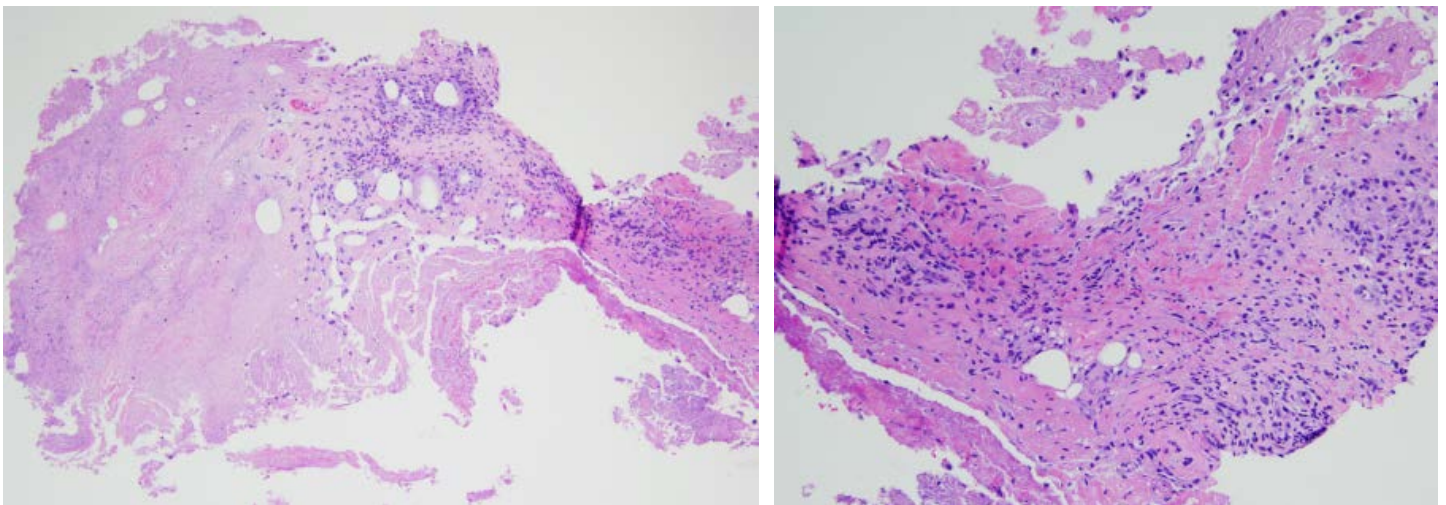
Laboratory data: Bacterial culture showed a few *Staphylococcus epidermidis*. Mycobacteriologic culture was initially negative for acid-fast bacilli but showed *Mycobacterium avium* complex by DNA hybridization. Fungal culture showed moderate *Candida parapsilosis*.

Histopathology: There is dermal fibrosis and patchy, granulomatous inflammation in the upper-to-mid dermis that is associated with a perivascular, lymphohistiocytic infiltrate. Granulomas extend into the subcutaneous fat where there also is marked necrosis.

Vasculitis is not identified. Although special stains for microorganisms that include Gram's, periodic acid-Schiff with diastase, and acid-fast bacilli are negative, the most recent tissue culture is positive for *Mycobacteria avium* complex, and the histologic findings are consistent with a mycobacterial infection.



Figures 1, 2. Ulcers within erythematous plaques



Figures 3, 4. Dermal fibrosis and granulomatous inflammation

Discussion

Diagnosis: *Mycobacterium avium* complex infection

Comment: We review the case of a patient who presented with recurrent papules, nodules, and ulcers on the left lower extremity, who was subsequently found to have a *Mycobacterium avium* complex infection.

Mycobacterium avium complex includes species that are identified as both *Mycobacterium avium* and *Mycobacterium intracellulare*. At least 20 subtypes exist, but the species are grouped owing to their similar clinical relevance [1-2]. Clinical manifestations may vary widely and a broad array may present in the infected patient. Multiple ulcers with erythematous borders, painless yellow plaques, lesions similar to ecthyma, deep-seated inflammatory nodules, verrucous ulcers, and draining sinuses have been reported [1,3-5].

Cutaneous nontuberculous mycobacterial infections usually result from exposure to an external inoculum, local spread of an already established deeper infection, or hematogenous dissemination [6]. Infection with nontuberculous mycobacteria comprises four main clinical entities, which include skin and soft tissue infection, lymphadenitis, pulmonary disease, and disseminated infection [6-7]. Although certain cutaneous nontuberculous mycobacterial infections yield a specific clinical presentation owing

to a well-known route of exposure, such as *Mycobacterium marinum* or *Mycobacterium ulcerans*, other infections may present with an unclear clinical picture [6]. In a study of the clinical patterns of cutaneous nontuberculous mycobacterial infections in 51 patients with such infections, the clinical patterns were observed in mycobacterial infection by various species. The authors suggest that local cutaneous disease with sporotrichoid lesions in the setting of a non-aquagenic source could be associated with *Mycobacterium avium* complex, *Mycobacterium kansasii*, or rapidly-growing mycobacterial infections.

Once rare, nontuberculous mycobacterial infections are being observed with an increase in frequency in a variety of settings, which include cosmetic and spa procedures, fractionated carbon dioxide laser resurfacing, and pedicures [8-9]. In 2000, a case-control study investigated an outbreak in four patients in a California community with recalcitrant, culture-negative boils on the lower extremities. Of 110 nail salon customers with furunculosis, 34 tested positive for nontuberculous mycobacterial infections [10]. The study showed that all of the nail salon's footbaths were contaminated with nontuberculous mycobacteria, which implied that a single patron was unlikely to be responsible for the contamination. The authors posited that rapidly-growing mycobacteria, which commonly are present in municipal water supplies, flourished in the warm, recirculated water and organic debris in the footbaths [10-11]. The study also identified leg shaving with a razor prior to treatment as a risk factor for the development of nontuberculous mycobacterial infection. Despite the large size of the outbreak, it was not detected for more than six months, owing to the relatively innocuous appearance of the early lesions. Patients who were treated for mycobacterial infection had eventual resolution of their lesions; one untreated patient ultimately developed dissemination. Several subsequent reports in different regions also documented nontuberculous mycobacterial infection in pedicure recipients [9,12-14].

When evaluating recalcitrant soft tissue infections of the lower extremity, especially in nail salon patrons, clinicians should consider nontuberculous mycobacterial infection. In the patient presented, multiple biopsies for tissue culture were negative, but a biopsy of an inflamed nodule ultimately yielded *Mycobacterium avium* complex.

References

1. Lugo-Janer G, et al. Disseminated cutaneous infection caused by *Mycobacterium avium* Complex. *Arch Dermatol* 1990;126:1108
2. Schaefer WB. Incidence of serotypes of *M avium* and atypical mycobacteria in human and animal disease. *Am Rev Respir Dis* 1968;97:18
3. Cox SK, Strausbaugh LJ. Chronic cutaneous infection caused by *Mycobacterium intracellulare*. *Arch Dermatol* 1981;117:794
4. Kaplan MH, et al. Dermatologic findings and manifestations of acquired immunodeficiency syndrome. *J Am Acad Dermatol* 1987;16:485
5. Schmidt JD, et al. Cutaneous infections due to Runyon group III atypical *Mycobacterium*. *Am Rev Respir Dis* 1972;106:469
6. Bartralot R, et al. Clinical patterns of cutaneous nontuberculous mycobacterial infections. *Br J Dermatol* 2005;152:727
7. American Thoracic Society. Diagnosis and treatment of disease caused by nontuberculous mycobacteria. *Am J Respir Crit Care Med* 1997;156:S1
8. Culton DA, et al. Nontuberculous mycobacterial infection after fractionated CO2 laser resurfacing. *Emerg Infect Dis* 2013;19:365
9. Redbord KP, et al. Atypical *Mycobacterium furunculosis* occurring after pedicures. *J Am Acad Dermatol* 2006;54:520
10. Winthrop KL, et al. An outbreak of mycobacterial furunculosis associated with footbaths at a nail salon. *N Engl J Med* 2002;346:1366
11. Covert TC, et al. Occurrence of non-tuberculous mycobacteria in environmental samples. *Appl Environ Microbiol* 1999;65:2492
12. Sniezek PJ, et al. Rapidly growing mycobacterial infections after pedicures. *Arch Dermatol* 2003;139:629
13. Gira AK, et al. Furunculosis due to *Mycobacterium mageritense* associated with footbaths at a nail salon. *J Clin Microbiol* 2004;42:1813
14. Wertman R, et al. *Mycobacterium bolletii*/*Mycobacterium massiliense* furunculosis associated with pedicure footbaths. *Arch Dermatol* 2011;147:454