

UC Davis

Dermatology Online Journal

Title

Deep dermatofibrosarcoma protuberans in a ninety-year old-woman

Permalink

<https://escholarship.org/uc/item/6ns8n7m7>

Journal

Dermatology Online Journal, 20(11)

Authors

Gracia-Cazana, T
Pastushenko, I
Concellon, MA
[et al.](#)

Publication Date

2014

DOI

10.5070/D32011024619

Copyright Information

Copyright 2014 by the author(s). This work is made available under the terms of a Creative Commons Attribution-NonCommercial-NoDerivatives License, available at <https://creativecommons.org/licenses/by-nc-nd/4.0/>

Peer reviewed

Case Presentation

Deep dermatofibrosarcoma protuberans in a ninety-year old-woman.

T Gracia-Cazaña MD, I Pastushenko MD, MA Concellón MD, MP Grasa MD

Dermatology Online Journal 20 (11): 3

Dermatology Service. Hospital Clínico Lozano Blesa, Zaragoza, Spain

Correspondence:

Dr. T. Gracia-Cazaña
Department of Dermatology
Hospital Clínico Universitario “Lozano Blesa”
Street San Juan Bosco 15.
P.O.Box: 50009 – Zaragoza (Spain)
Telephone number: (+34) 657571403
E-mail: tamgracaz@gmail.com

Abstract

A 92-year-old woman was referred for the assessment of an asymptomatic subcutaneous tumor that developed after an accidental fall. The mass clinically and radiologically simulated a subcutaneous hematoma. Finally, the histological study was consistent with subcutaneous dermatofibrosarcoma protuberans.

Keywords: Dermatofibrosarcoma protuberans, Subcutaneous Tissue, Sarcomas, Soft Tissue, Magnetic Resonance Imaging

Introduction

Dermatofibrosarcoma Protuberans (DFSP) is a mesenchymal tumor of intermediate malignancy, normally affecting the dermis and subcutaneous tissue. Although DFSP rarely gives rise to metastasis, it shows high rates of local recurrence. DFSP represents 6% of soft tissue sarcomas. There are atypical cases of DFSP, such as a subcutaneous variant that is characterized by the absence of dermal involvement, which could lead to the delay in the diagnosis [1].

Case synopsis

A 92-year-old woman was referred to our division for the assessment of an asymptomatic subcutaneous tumor on her right leg, at a site injured five months prior after an accidental fall. The physical examination revealed a 7-cm movable mass, without any skin changes (Figure 1). Leg ultrasound revealed a 6.6 cm well circumscribed and heterogeneous mass located over the tibial muscle. Magnetic Resonance Imaging was performed, showing an extra-aponeurotic mass affecting subcutaneous tissue compatible with a chronic hematoma (Figure 2). Conservative treatment was recommended. However, after 2 months no improvement was observed and a biopsy was performed.

Histological examination revealed a large subcutaneous tumor (Figure 3), composed by a storiform proliferation of spindle cells (Figure 4), showing strong positivity for CD34, Apo D, Ki-67; stains were negative for S-100 protein, factor XIIIa, and smooth-muscle actin. According to these findings, the diagnosis of subcutaneous DFSP was made. The tumor was surgically removed with 3 cm margins and no recurrence could be detected after 8 months of follow-up.

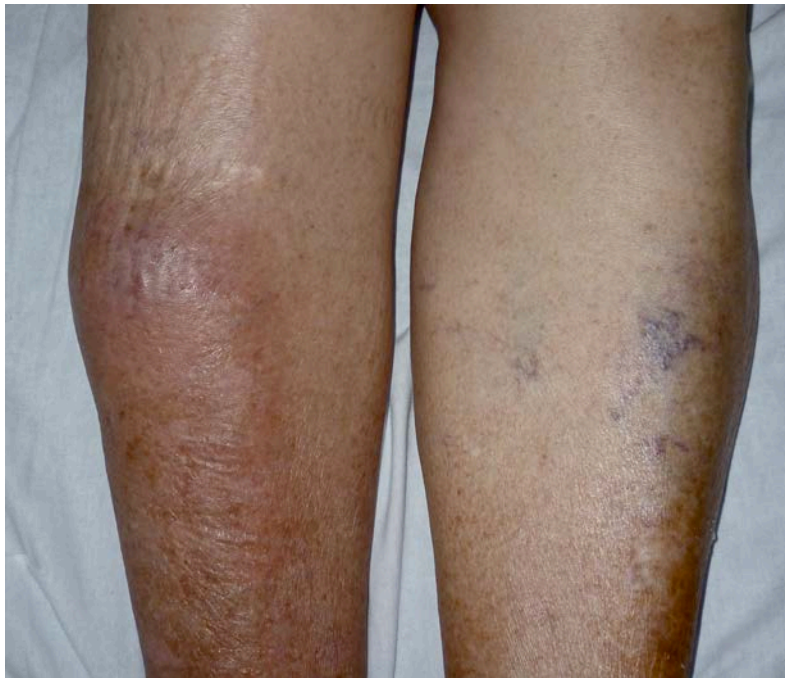


Figure 1. Physical examination revealed a 7 cm subcutaneous tumor with normal skin on right leg.

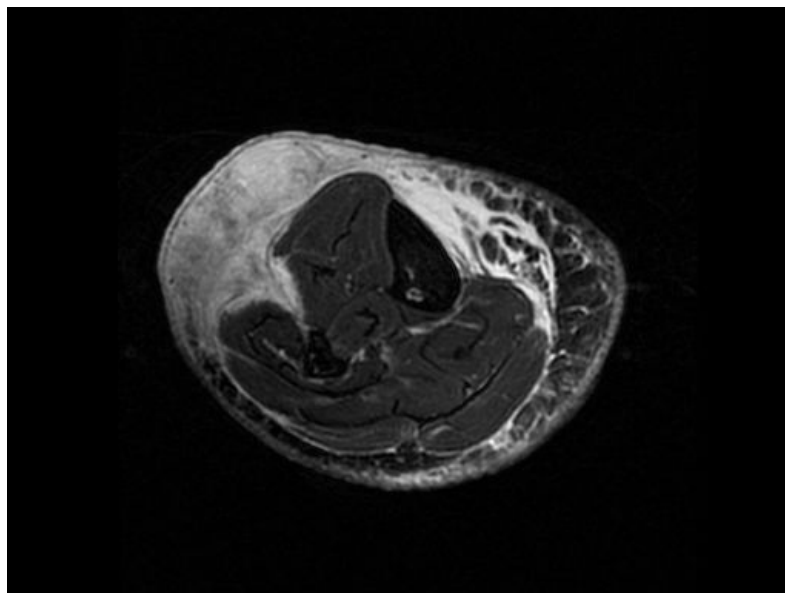


Figure 2. Magnetic Resonance Imaging showed an extra-aponeurotic mass affecting subcutaneous tissue with a T2 hypersignal.

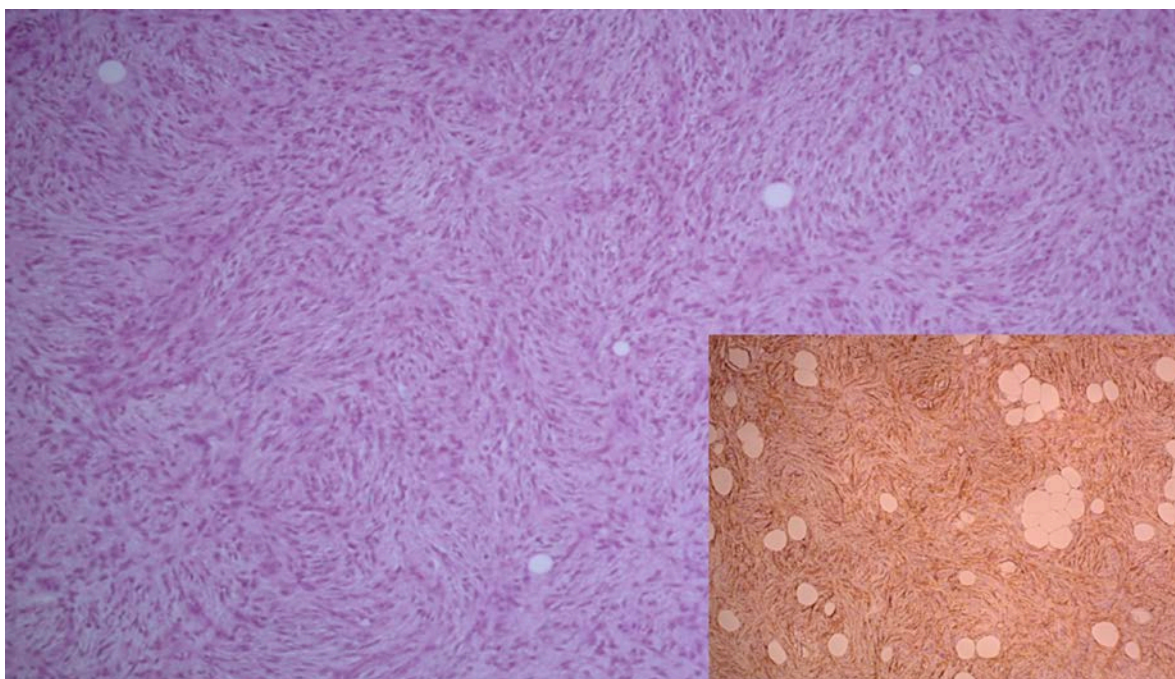


Figure 3. Deep DFSP. The tumor is mainly located in the subcutaneous compartment.

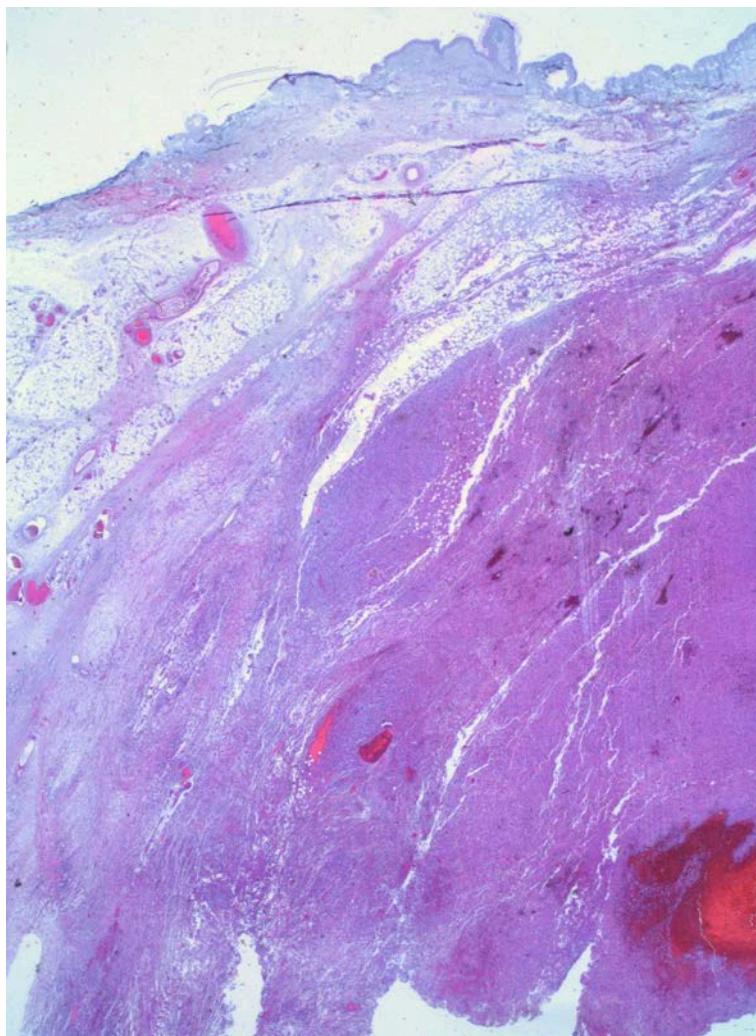


Figure 4. Histological examination revealed a storiform proliferation of spindle cells and entrapped fat cells forming a honeycomb. Immunohistochemical study of the sample showed the tumor cells to be positive for CD34.

Discussion

In 1924, Darier and Ferrand described DFSP as a cutaneous spindle cell tumor with deep local invasion, typically affecting adults. Clinically, it presents as an indurated plaque or nodule, located on the trunk or the extremities. However, atypical presentations of DFSP have been described, such as dermatofibrosarcoma non protuberans or atrophic, morphea-like, angioma-like, pedunculated, and deep or subcutaneous DFSP [2].

Histologically, subcutaneous DFSP is a non-encapsulated tumor composed by spindle-shaped cells with a storiform pattern in the subcutaneous tissue without primary dermal involvement. The immunohistochemical pattern is similar to that of more typical forms of DFSP and is characterized by positivity for CD34 and vimentin with negativity for S-100 protein, factor XIIIa, and smooth- muscle actin. These immunohistochemical markers help us to differentiate DFSP from liposarcoma, perineuroma, deep benign fibrous histiocytoma, and spindle cell lipoma [1]. History of local trauma has been reported as a precipitating factor for DFSP development; this event can precede growth of the tumor by two months to twenty years [3].

There are few published cases of deep DFSP, the first three were reported by Diaz-Cascajo *et al.* [1] and were located on the back and shoulder; no recurrences or metastases were detected. Subsequently, a subcutaneous DFSP of the breast in a 47-year-old woman was described with translocation (17;22)(q22;q13) [4], similar to classic DFSP [5]. Another case in the same location was reported by Bulliard *et al.*[6]. It was a tumor with clinical findings of an epidermal cyst; this diagnostic impression is the most frequently described [7].

The largest series was published by Bague *et al.*[8]. Fifteen patients were described, but only in one of them was the tumor located on the leg, as in our case. Although this series had limited follow up, there were no recurrences or metastases. Subcutaneous DFSP usually evolve over several years and are generally large at diagnosis because they are often painless and subtle [9].

We report the second case of deep DFSP located on a leg that appeared to occur after trauma. It is of utmost importance to bear in mind this atypical variant of DFSP in order to allow the correct diagnosis and the early and optimal management of these patients.

References

1. Diaz-Cascajo C, Weyers W, Rey-Lopez A, Borghi S. Deep dermatofibrosarcoma protuberans: a subcutaneous variant. *Histopathology*. 1998 Jun;32(6):552-5. [PMID: 9675595]
2. Martin L, Piette F, Blanc P, Mortier L, Avril MF, Delaunay MM, et al. Clinical variants of the prepotuberant stage of dermatofibrosarcoma protuberans. *Br J Dermatol*. 2005 Nov;153(5):932-6. [PMID: 16225602]
3. Bashara ME, Jules KT, Potter GK. Dermatofibrosarcoma protuberans: 4 years after local trauma. *J Foot Surg*. 1992 Mar-Apr;31(2):160-5. [PMID: 1353770]
4. Dobin SM, Diaz JA, Silva MT, Truss LM, Donner LR. Translocation (17;22)(q22;q13) in a case of subcutaneous dermatofibrosarcoma protuberans in an adult. *Cancer Genet Cytogenet*. 1999 Feb;109(1):86-7. [PMID: 9973968]
5. Llombart B, Serra-Guillén C, Monteagudo C, López Guerrero JA, Sanmartín O. Dermatofibrosarcoma protuberans: a comprehensive review and update on diagnosis and management. *Semin Diagn Pathol*. 2013 Feb;30(1):13-28. [PMID: 23327727]
6. Bulliard C, Murali R, Chang LY, Brennan ME, French J. Subcutaneous dermatofibrosarcoma protuberans in skin of the breast: may mimic a primary breast lesion. *Pathology*. 2007 Aug;39(4):446-8. [PMID: 17676490]
7. Bathelier E, Ly A, Kanitakis J, Ranchere-Vince D, Chouvet B, Allombert C, et al. Subcutaneous dermatofibrosarcoma protuberans masquerading as a cyst. *J Eur Acad Dermatol Venereol*. 2007 Sep;21(8):1127-8. [PMID: 17714149]
8. Bague S, Folpe AL. Dermatofibrosarcoma protuberans presenting as a subcutaneous mass: a clinicopathological study of 15 cases with exclusive or near-exclusive subcutaneous involvement. *Am J Dermatopathol*. 2008 Aug;30(4):327-32. [PMID: 18645303]
9. Oh SH, Ryu DJ, Choi J, Chung KY. A subcutaneous nodule without surface changes on the upper arm. Subcutaneous dermatofibrosarcoma protuberans (DFSP). *Clin Exp Dermatol*. 2010 Apr;35(3):e60-1. [PMID: 20500183]