

UC Irvine

UC Irvine Previously Published Works

Title

Orbital pseudotumor as the presenting symptom of Crohn's disease in a male child

Permalink

<https://escholarship.org/uc/item/6nn620s1>

Authors

Ishihara, Rhys
Jain, Samiksha Fouzdar
Perry, Deborah
et al.


Publication Date

2020-06-01

DOI

10.1016/j.ajoc.2020.100669

Peer reviewed



Orbital pseudotumor as the presenting symptom of Crohn's disease in a male child



Rhys Ishihara^{a,*}, Samiksha Fouzdar Jain^b, Deborah Perry^b, Adam Reinhardt^b, Donny Suh^b, Richard Legge^c

^a Creighton University, 2500, California Plaza, Omaha, NE, USA

^b Children's Hospital and Medical Center, 8200, Dodge St, Omaha, NE, USA

^c University of Nebraska Medical Center, S 42nd St & Emile St, Omaha, NE, 68198, USA

ARTICLE INFO

Keywords:

Orbital pseudotumor
Idiopathic orbital inflammation
Crohn's disease
Inflammatory bowel disease

ABSTRACT

Purpose: This report will describe a case of orbital pseudotumor that is associated with underlying Crohn's disease in a pediatric patient.

Observations: An 8-year-old male with a past medical history of chronic constipation who presented to the ophthalmologist in July 2017 with a 7-month history double vision, left upper lid ptosis, left abducens nerve palsy, and an abnormal thyroid test. The patient's family history was negative for any autoimmune disease including, juvenile idiopathic arthritis, rheumatoid arthritis, thyroid disease, type 1 diabetes mellitus or inflammatory bowel disease. Diagnosis of orbital pseudotumor of the left eye was made based on CT scan findings and he was then treated with a one-week course of oral prednisone. After resolution of his initial symptoms, he presented a month later with swelling in his left eye and was treated with a 6-month steroid taper with resolution of symptoms. In June 2018, the patient presented with swelling in his right eye and was treated with prednisone plus steroid sparing agents. Extraocular muscle biopsy was negative for IgG4 related disease, fungal infection, or malignant lymphoma and workup for sarcoidosis and granulomatosis with polyangiitis was unremarkable. In September 2018, the patient presented with bloody stools, diagnosed and treated for a perirectal abscess. Subsequent colonoscopy performed in January 2019 confirmed Crohn's disease. He is currently undergoing treatment with adalimumab and is in remission in terms of orbital pseudotumor.

Conclusion and Importance: In conclusion, although the association between orbital pseudotumor and Crohn's disease is very rare, medical professionals should remember this connection when a patient presents with idiopathic orbital pseudotumor. To rule out this possibility, we recommend a thorough history of GI findings should be taken on the initial patient encounter. Crohn's disease may be an underlying cause of certain cases of orbital pseudotumor, and treatment and control of the underlying Crohn's disease may help to reduce recurrence rates of orbital pseudotumor. Additional studies need to be performed to better understand the association between the two diseases.

1. Introduction

Orbital pseudotumor, also known as idiopathic orbital inflammation (IOI), is the third most common disease of the orbit and is characterized by nonspecific inflammation of the orbit with no identifiable cause.¹ The known association between orbital pseudotumor and Crohn's disease is very rare, and the current prevalence is unknown. To the best of our knowledge, this is the first report of orbital pseudotumor preceding the diagnosis of Crohn's disease in a pediatric, prepubescent male patient.

2. Case report

In July 2017, an 8-year-old male with a past medical history of chronic constipation presents to the ophthalmologist with a 7-month history of left upper lid ptosis, double vision, an abnormal thyroid test and left abducens nerve palsy. The patient denied any recent history of cold or flu like symptoms. The patient's family history was negative for any autoimmune disease, including juvenile idiopathic arthritis, rheumatoid arthritis, thyroid disease, type 1 diabetes mellitus or inflammatory bowel disease. On physical exam, the visual acuity in the right and left eyes was 20/20. Orbital soft tissue was edematous with

* Corresponding author.

E-mail address: rhyshihara@creighton.edu (R. Ishihara).

<https://doi.org/10.1016/j.ajoc.2020.100669>

Received 7 May 2019; Received in revised form 9 March 2020; Accepted 12 March 2020

Available online 16 March 2020

2451-9936/© 2020 The Authors. Published by Elsevier Inc. This is an open access article under the CC BY-NC-ND license (<http://creativecommons.org/licenses/by-nc-nd/4.0/>).

ptosis of the upper eyelid with limited abduction and adduction of the eye. There was no pain with eye movement. There was mild left sided proptosis with Hertel measurements 16 mm OD and 19 mm OS. A thyroid function test was repeated (TSH, T4) and was within normal limits. Furthermore, thyroid stimulating immunoglobulin was within normal limits. Inflammatory markers were mildly elevated (ESR 49, CRP 3.5, Platelets 588). Results of an MRI showed the medial and lateral rectus muscles were enlarged. Furthermore, there was no evidence of posterior scleritis by MRI and B scan. With these findings, the patient was diagnosed with idiopathic pseudotumor of the left orbit and treated with a course of oral prednisone. One week later, his symptoms had resolved, and prednisone was tapered. During a 1-month follow up, the patient presented with ptosis and swelling in his left eye. He was restarted on oral prednisone and was treated with a 6-month taper that resolved his symptoms. He was off steroids in January 2018.

In June 2018, the patient returned with ptosis and conjunctival injection of the right eye with intact range of motion and no pain with eye movement. A repeat MRI of the orbit showed significant enlargement of the right superior and inferior rectus muscle and mild enlargement of the medial rectus, superior and inferior obliques with mild preseptal and postseptal edema (Fig. 1). Additionally, the patient presented a severe weight gain of 70 pounds impacted by lifestyle and corticosteroid side-effects from his prior 6-month taper. There was decreased left extraocular muscle enlargement when compared to the results of the MRI from the previous year. The extraocular muscle biopsy was negative for IgG4 related disease, fungal infection or malignant lymphoma, and the workup for sarcoidosis and granulomatosis with polyangiitis was unremarkable. The periorbital biopsy demonstrated small lymphocytes and plasma cells, with predominate T-cells, which infiltrate between the fibrous tissue (Figs. 2 and 3). The lymphocytic infiltrate suggested an autoimmune etiology of disease. The patient was treated with a combination of methotrexate and prednisone with clinical remission, but had residual CN3 palsy and intraocular HTN OD. The prednisone was tapered over a period of six months.

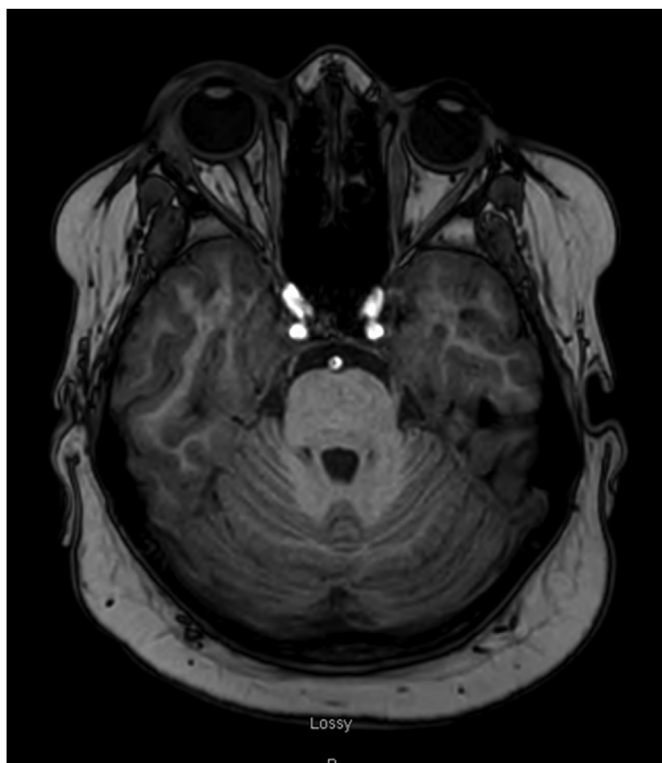


Fig. 1. Axial view of a T1 weighted MRI of the brain. Demonstrates enlargement of the right and left medial rectus. There is also pre and post septal edema present on the right.

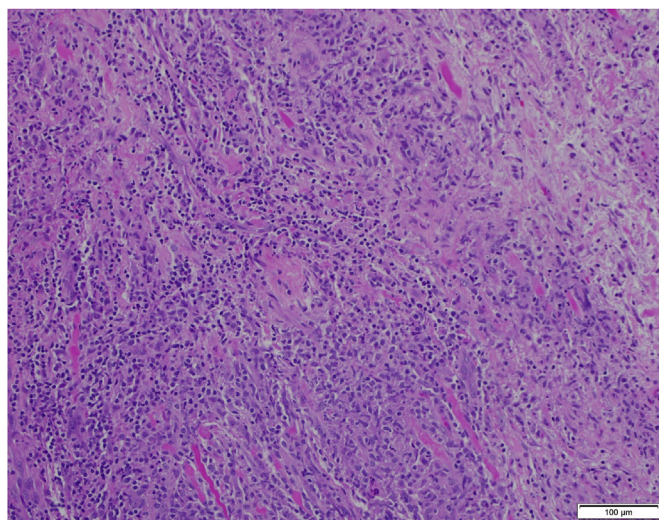


Fig. 2. The periorbital biopsy exhibits small lymphocytes and plasma cells which infiltrate between the fibrous tissue. There is no acute inflammation.

In September 2018, during the beginning of his steroid taper, the patient presented with bloody stools and was diagnosed with a perirectal abscess. He was treated with a fistulotomy, which was tolerated well. After treatment, the patient continued to have intermittent loose and bloody bowel movements. Inflammatory bowel disease (IBD) was suspected. The patient had a colonoscopy in January 2019, which confirmed Crohn's disease with evidence of ileitis and mucosal ulcerations. He is currently being treated with adalimumab, and the orbital pseudotumor is in remission.

2. Discussion

The prevalence of ocular pathology in patients with Crohn's disease is very rare and estimated at 3%.² Reported cases in the adult population show an increased incidence of ocular features with Crohn's disease over those cases associated with ulcerative colitis, and most of these cases occurred in women.³ According to a meta-analysis, ocular extraintestinal manifestations of IBD is less prevalent in the pediatric population (0.62–1.82%).⁴ However, this meta-analysis focused on uveitis as the main ocular extraintestinal manifestation of IBD. Previous case reports on pseudotumor of the orbit as an extraintestinal manifestation of IBD in the pediatric population only presented cases with postpubertal females.^{5–7}

Diagnosis of orbital pseudotumor is clinical and a diagnosis of exclusion. Patients can present with a variety of symptoms, including the abrupt onset of ocular pain, swelling, redness and proptosis. Depending on the extent of inflammation, patients can also have other symptoms including ptosis, chemosis, extraocular muscle dysfunction, optic neuropathy and oculomotor nerve palsy.¹ When there is no clear identifiable cause, patients are treated with a trial of oral or IV corticosteroids. If the patient is unresponsive to corticosteroids, then a biopsy of the tissue is warranted to find underlying cause.⁸ A recent review recommends performing tissue biopsies in those patients where clinical and radiologic findings are inconclusive instead of treating with corticosteroids empirically because most inflammatory diseases are steroid responsive.⁹

Although there has been no definitive evidence in the pathogenesis of orbital pseudotumor, it has been proposed that it is an aberrant response of macrophages and lymphocytes. Harris proposes that a combination of an autoimmune response due to molecular mimicry from an unknown antigen and exposure to tissue damage is responsible for the findings in orbital pseudotumor.¹⁰

First line treatment of orbital pseudotumor is oral corticosteroids.

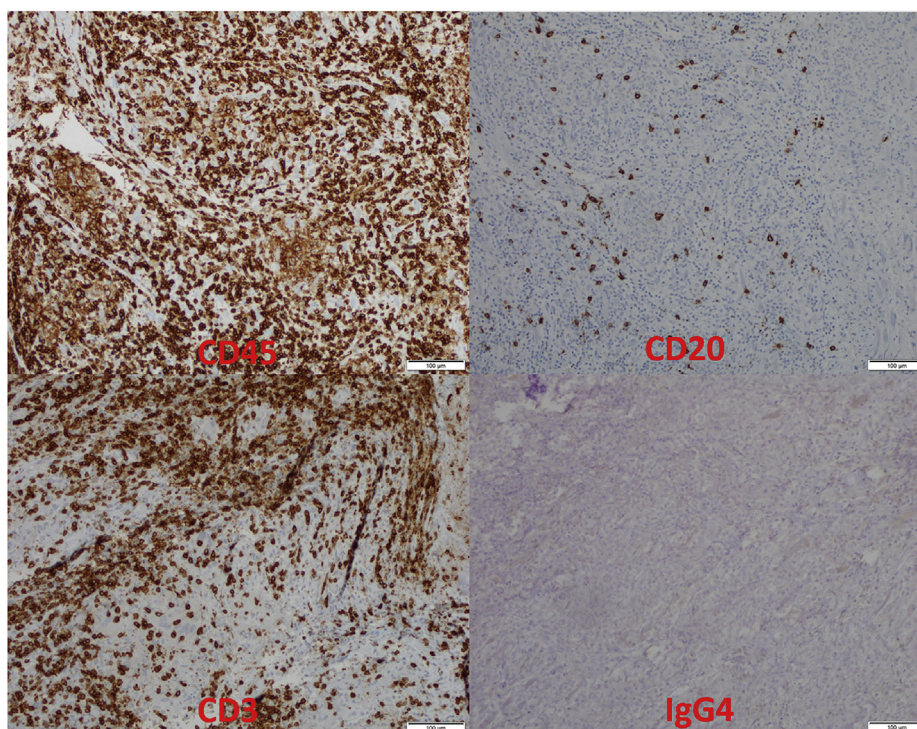


Fig. 3. The CD45 (leukocyte common antigen) shows numerous hematopoietic cells which are predominantly T-cells (CD3 positive). A few B-cells are present (CD20 positive). None of the inflammatory cells express IgG4.

The initial response rate to corticosteroids is very good, but there is a high incidence of recurrence (56%).¹¹ Radiation therapy was ineffective in preventing recurrence in those patients refractory to treatment with corticosteroids.¹¹ In cases of refractory orbital pseudotumor, patients treated with rituximab,¹² azathioprine, methotrexate, mycophenolate and ciclosporin also showed improvement.¹³ In addition, a patient with Crohn's and orbital pseudotumor who was treated with adalimumab showed remission of both diseases.¹⁴

In our case, the patient was initially responsive to oral corticosteroids, but had multiple recurrences when steroids were tapered. An orbital biopsy of the muscle and soft tissue was obtained during the third relapse and ruled out other causes, such as IgG4 related disease, infection due to acid-fast bacilli or fungus, vasculitis and malignant lymphoma. Furthermore, thyroid eye disease was ruled out. Although the pediatric population can have orbital inflammation in a euthyroid state, the lack of thyroid stimulating immunoglobulin in our patient eliminates it from the differential diagnosis.¹⁵ In addition, there have been a few reported cases of orbital myositis and posterior scleritis associated with prior streptococcus infection. Even if an ASO titer was not performed, the patient had no recent history of a strep-like illness.^{16,17}

After the patient's third relapse, methotrexate was added to reduce side effects of oral corticosteroids and helped achieve remission of the patient's symptoms. However, when oral corticosteroids were tapered, the patient presented with bloody stools and was diagnosed with Crohn's disease. The patient's history of recurrent constipation could have led us to look for IBD related orbital pseudotumor. It is, however, most likely that chronic steroids were partially treating underlying IBD for most of his course, and clinical symptoms were masked until he was weaned to lower doses. The anal fistula and perirectal abscess were also strong indicators of IBD. The patient is currently on treatment with adalimumab and has not had a flare up of his pseudotumor for two months.

In conclusion, although the association between orbital pseudotumor and Crohn's disease is very rare, medical professionals should remember this connection when a patient presents with idiopathic

orbital pseudotumor. To rule out this possibility, we recommend a thorough history of GI findings should be taken on the initial patient encounter. Crohn's disease may be an underlying cause of certain cases of orbital pseudotumor, and treatment and control of the underlying Crohn's disease may help to reduce recurrence rates of orbital pseudotumor. Additional studies need to be performed to better understand the association between the two diseases.

Patient consent

Patient consent was obtained, and the consent form is uploaded separately as a PDF file.

Funding

No funding or grant support.

Authorship

All authors attest that they meet the current ICMJE criteria for Authorship.

Declaration of competing interest

The following authors have no financial disclosures: RI, SFJ, DP, AR, DS, RL.

Acknowledgements

None.

References

- Ahn Yuen SJ, Rubin PA. Idiopathic orbital inflammation: distribution, clinical features and treatment outcome. *Arch Ophthalmol.* 2003;121(4):491–499.
- Lakatos L, Pandur T, David G, et al. Association of extraintestinal manifestations of

- inflammatory bowel disease in a province of western Hungary with disease phenotype: results of a 25-year follow-up study. *World J Gastroenterol.* 2003;9(10):2300–2307.
3. Katsanos A, Asproudis I, Katsanos KH, Dastiridou AI, Aspiotis M, Tsianos EV. Orbital and optic nerve complications of inflammatory bowel disease. *J Crohns Colitis.* 2013;7(9):683–693. <https://doi.org/10.1016/j.crohns.2012.09.020>.
 4. Ottaviano G, Salvatore S, Salvatoni A, Martelossi S, Ventura A, Naviglio S. Ocular. Manifestations of paediatric inflammatory bowel disease: a systematic review and meta-analysis. *J Crohns Colitis.* 2018;12(7):870–879. <https://doi.org/10.1093/ecco-jcc/jjy029>.
 5. Young RSK, Hodes BL, Cruse RP, Koch KL, Garovoy MR. Orbital pseudotumor and Crohn's disease. *J Pediatr.* 1981;99:250–252.
 6. Weinstein JM, Koch K, Lane S. Orbital pseudotumor in Crohn's colitis. *Ann Ophthalmol.* 1984;16:275–278.
 7. Camfield PR, White M, Warner HA, Lythgoe C. Orbital pseudotumor and Crohn's disease. *J Pediatr.* 1982;101:157–158.
 8. Leone CR, Lloyd WC. Treatment protocol for orbital inflammatory disease. *Ophthalmol.* 1985;92(10):1325–1331.
 9. Mombaerts I, Rose GE, Garrity JA. Orbital inflammation: biopsy first. *Surv Ophthalmol.* 2016;61(5):664–669.
 10. Harris GJ. Idiopathic orbital inflammation: a pathogenetic construct and treatment strategy. *Ophthalmic Plast Reconstr Surg.* 2006;22(2):79–86.
 11. Mombaerts I, Koornneef L. Current status in the treatment of orbital myositis. *Ophthalmol.* 1997;104(3):402–408.
 12. Shao EH, Karydis A, Gemenetzi M, Taylor SRJ. Successful corticosteroid-sparing effect of rituximab in the treatment of refractory idiopathic orbital inflammatory disease. *Case Rep Ophthalmol.* 2013;4:216–218. <https://doi.org/10.1159/000356523>.
 13. Swamy BN, McCluskey P, Nemet A, et al. Idiopathic orbital inflammatory syndrome: clinical features and treatment outcomes. *Br J Ophthalmol.* 2007;91(12):1667–1670.
 14. Hernández-Garfella M-L, Gracia-García A, Cervera-Taulet E, García-Villanueva C, Montero-Hernández J. Adalimumab for recurrent orbital myositis in Crohn's disease: report of a case with a 3-year follow-up. *J Crohns Colitis.* 2011;5(3):265–266.
 15. Szczapa-Jagustyn J, Gotz-Więckowska A, Kocięcki J. An update on thyroid-associated ophthalmopathy in children and adolescents. *J Pediatr Endocrinol Metab.* 2016, Oct 1;29(10):1115–1122. <https://doi.org/10.1515/jpem-2016-0122>.
 16. Hilkert SM, Koreishi AF, Pyatetsky D. Poststreptococcal syndrome presenting as posterior scleritis in a child. *J AAPOS.* 2017 Apr;21(2):163–165. <https://doi.org/10.1016/j.jaapos.2016.09.019> Epub 2016 Dec 19.
 17. Alshaikh M, Kakakios AM, Kemp AS. Orbital myositis following streptococcal pharyngitis. *J Paediatr Child Health.* 2008, Apr;44(4):233–234. <https://doi.org/10.1111/j.1440-1754.2008.01288.x>.