

# UCSF

## UC San Francisco Previously Published Works

### Title

Proximal Hamstring Repair With All-Suture Anchors and an Accelerated Rehabilitation and Bracing Protocol Demonstrates Good Outcomes at 1-Year Follow-Up.

### Permalink

<https://escholarship.org/uc/item/6nc722x9>

### Journal

Arthroscopy, Sports Medicine, and Rehabilitation, 6(2)

### Authors

Wong, Stephanie

Julian, Kaitlyn

Carpio, Jocelyn

et al.

### Publication Date

2024-04-01

### DOI

10.1016/j.asmr.2024.100891

### Copyright Information

This work is made available under the terms of a Creative Commons Attribution-NonCommercial-NoDerivatives License, available at

<https://creativecommons.org/licenses/by-nc-nd/4.0/>

Peer reviewed



# Proximal Hamstring Repair With All-Suture Anchors and an Accelerated Rehabilitation and Bracing Protocol Demonstrates Good Outcomes at 1-Year Follow-Up

Stephanie E. Wong, M.D., Kaitlyn R. Julian, B.S., Jocelyn G. Carpio, B.S., and Alan L. Zhang, M.D.

**Purpose:** To evaluate patient-reported outcomes and risk for rerupture after surgical treatment of proximal hamstring tendon ruptures using all-suture anchors and a unique postoperative bracing strategy. **Methods:** A retrospective review of a prospectively collected database was conducted of patients undergoing proximal hamstring repair or reconstruction from 2020 to 2022 at a tertiary, academic institution. Patients were included if they reached minimum 1-year follow-up and completed postoperative patient-reported outcomes. The surgical protocol for proximal hamstring repairs included all-suture anchors placed either in an open or endoscopic fashion in the ischial tuberosity. After surgery, all patients underwent an accelerated rehabilitation protocol, including 6 weeks touchdown weight-bearing in a hinged knee brace locked in extension for ambulation, allowing passive knee flexion to 90° while seated. Descriptive statistics were used to analyze the data. **Results:** Twenty-one patients were included (mean age 50.4 ± 9.5 years, body mass index 24.4 ± 3.5, 66.7% female). Lower Extremity Functional Scale score achieved postoperatively was 74.2 ± 7.5 (out of 80). Patients had minimal pain (mean visual analog scale pain score of 0.9 ± 1.2). 61.9% of patients were able to return to the same level of activity after based on Tegner score by 1 year. Postoperative Single Assessment Numeric Evaluation activity of daily living was 94.3 ± 8.3, and Single Assessment Numeric Evaluation Sports was 82.3 ± 19.0. Mean Short Form Survey (SF-12) postoperative scores were 51.6 ± 6.8 for SF-12 Physical Component Score and 53.9 ± 9.7 for Mental Component Score. 95.2% (20 of 21) patients were satisfied with their outcome. There were no reruptures, infections, or reoperations. One patient of 21 (4.8%) incurred a postoperative deep venous thrombosis, which was treated with therapeutic anticoagulation for 3 months. **Conclusions:** All-suture anchors for proximal hamstring repair with a unique accelerated postoperative rehabilitation and bracing protocol result in good outcomes and patient satisfaction with minimal risk of complications. **Level of Evidence:** Level IV, case series, therapeutic.

Proximal hamstring tendon injuries are increasingly common orthopaedic injuries and range in severity from a partial tendon tear to complete tendon avulsions.<sup>1-4</sup> Common mechanisms of injury include acute, traumatic injuries from falls where the legs separate

(i.e., slip and fall on ice or other slippery surface, waterskiing) or sports, or chronic mechanical overload associated with kicking sports, including soccer, football, and track and field athletes (in athletes who participate in hurdles and jumping). Injury occurs due to rapid muscle lengthening with combined hip flexion and knee extension.<sup>1,2,5</sup> With this injury, there is the potential for retraction, continued weakness, loss of function, and pain. Current guidelines in the literature favor surgical repair of tears involving 3 tendons in active patients younger than 60 years old and with 2 tendon tears if retraction exceeds 2 cm.<sup>1,3</sup>

Surgical techniques for proximal hamstring repair include primary repair with suture anchors for acute or nonretracted ruptures, or reconstruction with autografts or allografts in chronic cases in which primary repair is not possible due to retraction of the tendons.<sup>6,7</sup> In both repair and reconstruction scenarios,

From the Department of Orthopaedic Surgery, University of California San Francisco, San Francisco, California, U.S.A. (S.E.W., J.G.C., A.L.Z.); and School of Medicine, University of California San Francisco, San Francisco, California, U.S.A. (K.R.J.).

Received September 11, 2023; accepted January 10, 2024.

Address correspondence to Stephanie E. Wong, M.D., University of California, San Francisco, 1500 Owens St. Suite 170, San Francisco, California 94158, U.S.A. E-mail: [swong@ucsf.edu](mailto:swong@ucsf.edu)

© 2024 THE AUTHORS. Published by Elsevier Inc. on behalf of the Arthroscopy Association of North America. This is an open access article under the CC BY-NC-ND license (<http://creativecommons.org/licenses/by-nc-nd/4.0/>). 2666-061X/231238

<https://doi.org/10.1016/j.asmr.2024.100891>

suture anchors typically are used to anchor either the native tendon or the autograft/allograft tendon to the ischium. A variety of suture anchors have been used for repair, including solid body anchors and all-suture anchors.<sup>8-10</sup> All-suture anchors have been shown to have similar strength to solid body anchors in cadaveric, biomechanical studies and have added benefits of using smaller drill holes, with potential lower risk for iatrogenic stress riser or fracture, and preserved bone stock.<sup>8</sup> Moreover, in surgical repairs of the rotator cuff and distal biceps tendon, all-suture anchors have demonstrated similar strength and functional outcomes clinically compared with solid body anchors.<sup>11-14</sup> The use of all-suture anchors for proximal hamstring tendon repair is not well understood.

In addition, traditional recommended rehabilitation protocol following proximal hamstring surgery has included bracing with knee flexion fixed at 30-45° and offloading with crutches for 6 weeks to protect the surgical repair and allow healing.<sup>6</sup> This knee flexed position relaxes tension on the hamstring muscle group; however, it may be associated with anterior knee pain, calf pain, and is generally uncomfortable and cumbersome for patients. Since there are elevated rates of venous thromboembolism (VTE, 6.9%)<sup>15</sup> after proximal hamstring avulsion, being able to differentiate calf pain from knee flexed bracing protocol versus VTE is a concern. Recent studies suggest good outcomes may be achieved after proximal hamstring repair with an accelerated rehabilitation protocol that does not require bracing and allows for weight-bearing as tolerated.<sup>16,17</sup> While rerupture is a major complication that often requires reoperation, it is important to balance protection of the repair with progressing rehabilitation.

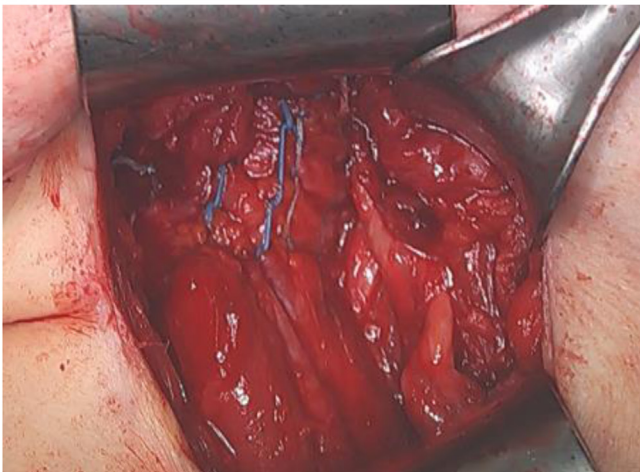
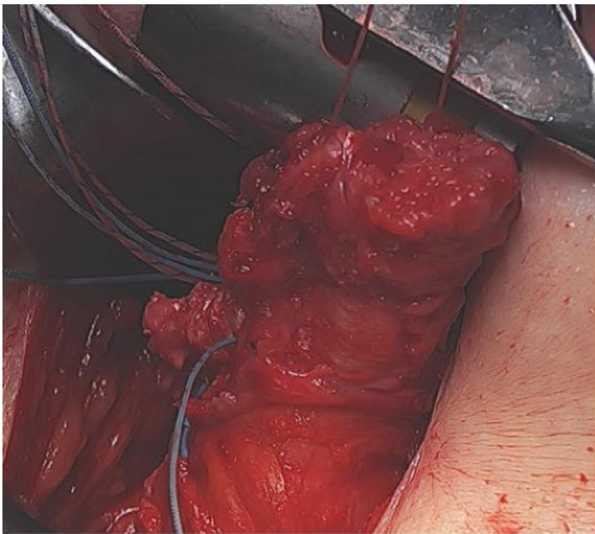
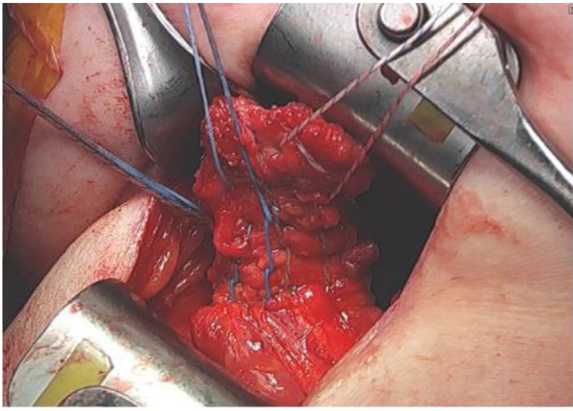
Variation exists in outcomes based on surgical technique, and there is a current lack of consensus on optimal rehabilitation strategies after proximal hamstring tendon repairs.<sup>7,18</sup> Therefore, our institution uses all-suture anchors for proximal hamstring repair followed by a postoperative protocol with 6 weeks touchdown weight-bearing in a hinged knee brace locked in extension for ambulation and allowing passive knee flexion to 90° while seated. The purpose of this study is to evaluate patient-reported outcomes (PROs) and risk for rerupture after surgical treatment of proximal hamstring tendon ruptures using all-suture anchors and an accelerated postoperative bracing strategy. We hypothesized that surgical treatment of proximal hamstring ruptures using all-suture anchors and this bracing strategy would lead to significant clinical improvement without increased risk for re-rupture or other complication.

## Methods

A retrospective review of a prospectively collected database was conducted of patients undergoing proximal hamstring repair or reconstruction from 2020 to 2022 at a tertiary, academic institution. This study was exempted by the institutional review board. Patients were included if they had complete 3 tendon proximal hamstring ruptures or 2 tendons ruptured with more than 2 cm of retraction, or if they have partial tendon tears that did not respond to nonoperative treatment (rest, nonsteroidal anti-inflammatory drugs, physical therapy), and met minimum 1-year follow-up and completed either 1- or 2-year postoperative PROs. The following surgical details were recorded: injury type, mechanism of injury, tear type, repair type, repair technique, amount of retraction, sciatic neurolysis, number of all-suture anchors used, tension of repair, and suture configuration. Patient demographics and complications (infection, VTE, rerupture) were also recorded. One- or two-year postoperative PRO scores were collected by trained, clinical research coordinators and were selected based on previous research.<sup>19,20</sup> The Lower Extremity Functional Scale (LEFS), Tegner Activity Scale, visual analog scale (VAS) for pain, and 12-Item Short Form Survey (SF-12) were collected. Single Assessment Numeric Evaluation (SANE) was collected for activities of daily living (ADLs) and sports. Outcomes were analyzed and compared by acute and chronic repair groups as well as primary and reconstructive repair groups.

The surgical protocol for proximal hamstring repairs included all-suture anchors placed either in an open or endoscopic fashion (per surgeon discretion based on degree of retraction/chronicity) in the ischial tuberosity into the footprint (number and configuration of anchor placement was at surgeon's discretion). For all open repairs, a running, locking suture configuration was used (Fig 1). For endoscopic repairs, either a simple or mattress configuration was used (Fig 2). For tendon reconstructions, an Achilles allograft was directly attached to the ischial tuberosity proximally with all-suture anchors and a running Krakow technique and then sewn into the remaining native proximal hamstring tendon stump distally with nonabsorbable sutures. Intraoperatively, both surgeons assess for tension on the repair by extending the knee to ensure there is not tension on the repair with the knee in full extension.

After surgery, all patients underwent an accelerated rehabilitation protocol including 6 weeks touchdown weight-bearing in a hinged knee brace. The brace was locked in extension for ambulation, and patients were allowed passive knee flexion to 90° while seated. Patients were advanced to weight-bearing as tolerated without brace or crutches at 6 weeks followed by



**Fig 1.** Complete proximal hamstring rupture undergoing open repair with running, locking suture configuration. The last image shows completed repair. This patient is in the prone position and this is a right open proximal hamstring repair. The medial side of the thigh is on the left side of the images.

low-impact exercises at 3 months. They were allowed to start high-impact exercises at 4 months and return to sports after 6 months. All patients were placed on

aspirin 325 mg or 81 mg daily for 6 weeks or apixaban 5 mg for 4 weeks for thromboprophylaxis per surgeon choice. Descriptive statistics were used to analyze the data.

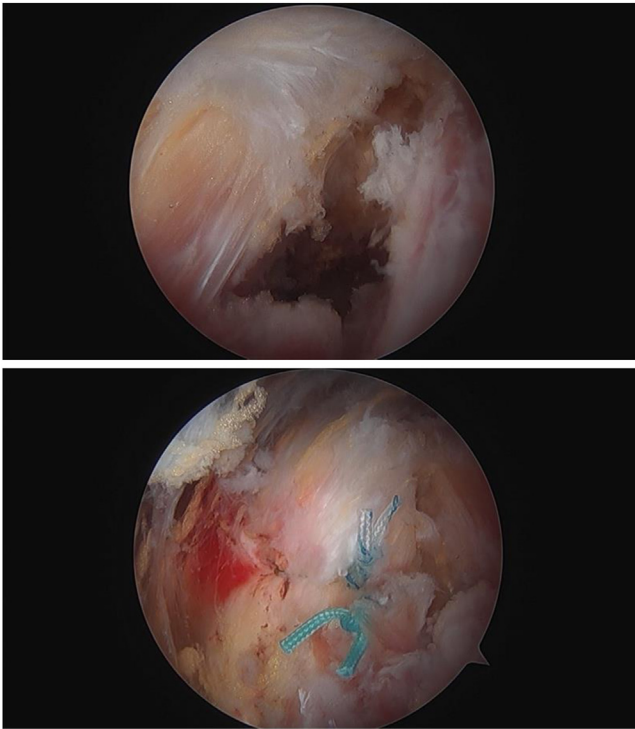
## Results

Twenty-three patients were treated with the aforementioned surgical procedure and bracing protocol, with 21 patients meeting follow-up criteria for study inclusion (91.3%). Two patients were excluded due to incomplete PROs. The mean age was  $50.4 \pm 9.5$  years, body mass index  $24.4 \pm 3.5$ , and 66.7% were female (Table 1). Six patients had 2-year postoperative follow-up, and 15 patients had 1-year follow-up (mean 1.29 years follow-up). Twenty of the 21 proximal hamstring ruptures resulted from traumatic injuries. Eighty percent (17 of the 21) involved ruptures of 2 or 3 tendons, and 20% (4 of the 21) were partial injuries involving one tendon. The mean amount of retraction was  $4.9 \pm 3.2$  cm. Mean preoperative Tegner score was 6.0 (standard deviation 2.1).

Fifty seven percent (12 of the 21) were treated surgically within 6 weeks. In this acute group, only one of the acute injuries resulted in a partial, 2-tendon tear, the remainder of the acute injuries were full-thickness, complete ruptures. Of those, 10 were repaired in open fashion, and 2 underwent endoscopic repair, using an average of 2 all-suture anchors (mean  $1.95 \pm 0.2$ ). No allograft was used in the acute repair group as the native tendon was able to be repaired directly without tension. Surgery after 6 weeks (chronic group) was done in 9 of 21 patients due to delayed presentation or partial-thickness tearing that did not respond to nonoperative management. Of the 9, 5 patients had open repair (of whom 3 patients required reconstruction with allograft tendon) and 4 underwent endoscopic repair. The surgical characteristics of participants are summarized in Table 1.

LEFS score achieved postoperatively was  $74.2 \pm 7.5$  (maximum score 80). Patients had minimal pain postoperatively (mean VAS pain score  $0.9 \pm 1.2$ ). Mean postoperative Tegner score was 4.9 (standard deviation 5). In total, 61.9% of patients (13 of 21) were able to return to the same level of activity after proximal hamstring repair based on Tegner score. Mean postoperative SANE ADL was  $94.3 \pm 8.3$  and SANE sports was  $82.3 \pm 19.0$ . Mean SF-12 postoperative scores were  $51.6 \pm 6.8$  for SF-12 Physical Component Score and  $53.9 \pm 9.7$  for Mental Component Score. Nearly all patients, 95.2% (20 of 21), were satisfied with their outcome.

There were no reruptures, infections, or reoperations. Of 21 patients, 1 patient (4.8%) who was on aspirin 325 mg daily for prophylaxis incurred a postoperative deep venous thrombosis at 4 weeks after surgery,



**Fig 2.** Proximal hamstring tear in the first image, as viewed from the inferomedial portal. The second image demonstrates endoscopic repair using simple suture repair configuration of a left proximal hamstring tear. The patient is in the prone position and the medial part of the thigh is on the right side of the images.

which was treated with therapeutic anticoagulation for 3 months.

Patients with acute injury underwent primary repair (12 of 12) more often than reconstructive repair when compared with patients with chronic injury (3 of 9,  $P < .001$ ). In addition, patients with acute injuries ( $P = .005$ ) and those undergoing primary repair ( $P = .01$ ) scored greater on the SF-12 Mental Component Summary, indicating better mental health function. When comparing patients who underwent primary repair compared with reconstruction, patients in the primary repair group had more acute injury ( $P = .03$ ), less tendon retraction ( $P \leq .001$ ), and were able to return to the same activity level after surgery based on the Tegner Activity Scale ( $P = .02$ ) and greater SANE Sports ( $P = .03$ ) scores (Table 2). There were no significant differences in repair technique (open vs endoscopic), LEFS scores, VAS Pain scores, SANE ADL scores, patient satisfaction, or physical function as measured by the SF-12 Physical Component Summary among both groups (Table 2 and Table 3).

## Discussion

We found that all-suture anchor repair and this postoperative bracing and rehabilitation protocol

**Table 1.** Demographics and Proximal Hamstring Injury and Repair Characteristics

Mean age, y	50.4 ± 9.5
Mean BMI	24.4 ± 3.5
% Female	66.7%
Acute injury	12 (57%)
Chronic injury	9 (43%)
Partial tears	4 (19%)
Complete tears (2- or 3-tendon involvement)	17 (81%)
Primary repairs	18 (86%)
Reconstruction with allograft	3 (14%)
Open repairs	15 (71%)
Endoscopic repairs	6 (29%)
Retraction ≤2 cm	5 (24%)
Retraction >2 cm	16 (76%)

NOTE. Mean ± standard deviation is listed for average values. Numbers are listed with percentage in parentheses.

resulted in good outcomes and high satisfaction without rerupture or reoperation at minimum 1-year follow-up. Patients in this study overall had good activity-related outcome scores in addition to general physical function scores, low pain scores, and high satisfaction (95.2%).

Patients undergoing primary repair had overall similar outcomes compared with those undergoing reconstruction for chronic injuries but had improved ability to participate in sports. Those undergoing primary repair and those with acute proximal hamstring injuries had better mental health scores postoperatively. One patient in our study had a postoperative deep venous thrombosis (1 of 21, or 4.8%). This is similar to other studies showing a rate of VTE after proximal hamstring repair ranging from 0.5% to 6.9%.<sup>15,21,22</sup>

All-suture anchors have been used throughout the body for various tendon repairs with overall excellent outcomes.<sup>8,11-13</sup> Several studies show similar biomechanical strength of all-suture anchors compared with solid body anchors for proximal hamstring repair,<sup>8,9</sup> and one clinical study shows excellent outcomes in a group of 34 patients who underwent acute repair of proximal hamstring rupture with either metal or resorbable suture anchors with flexed knee bracing.<sup>10</sup> Our study is the first to our knowledge to report on all-suture anchor repair of proximal hamstring rupture with bracing in the knee extended position when upright and knee flexed to 90° when seated. We had over 95% satisfaction rate, good ability to return to daily activities and sports, without reruptures or reoperations. There are additional benefits to using all-suture anchors. All-suture anchors are smaller than solid body anchors, and thus require smaller drill holes for placement. In the event of anchor pullout, all-suture anchors show a significantly smaller cortical defect and smaller bone cavity.<sup>23</sup> Because all-suture anchors

**Table 2.** Outcomes by Comparing Acute Versus Chronic Proximal Hamstring Injury

	Total, N = 21	Acute, N = 12	Chronic, N = 9	P Value
Gender, n%				1
Male	7 (33%)	4 (33%)	3 (33%)	
Female	14 (67%)	8 (67%)	6 (67%)	
Age, y, mean (SD)	50.4 (9.5)	49.4 (9.2)	51.7 (10.3)	.60
Tear type, n (%)				.15
Complete	17 (81%)	11 (92%)	6 (67%)	
Partial	4 (19%)	1 (8%)	3 (33%)	
Repair type, n (%)				<b>.03</b>
Primary	18 (85.7%)	12 (100%)	6 (66.7%)	
Reconstruction	3 (14.2%)	0 (0%)	3 (33.3%)	
Repair technique, n (%)				.16
Open	15 (71%)	10 (83%)	5 (56%)	
Endoscopic	6 (29%)	2 (17%)	4 (44%)	
Retraction, cm, mean (SD)	4.9 (3.2)	4.5 (1.9)	5.3 (4.5)	.57
Sciatic neurolysis, n (%)				.80
Yes	11 (52%)	6 (50%)	5 (56%)	
No	10 (48%)	6 (50%)	4 (44%)	
LEFS score, mean (SD)	74.2 (7.5)	75.1 (8.4)	73.1 (6.5)	.57
Tegner Activity Scale, n%				.15
Score before injury = after injury	13 (62%)	9 (75%)	4 (44%)	
Score before injury ≠ after injury	8 (38%)	3 (25%)	5 (56%)	
VAS Pain score, mean (SD)	2.1 (0.8)	2 (0.8)	2.2 (0.8)	.73
SANE ADL score, mean (SD)	94.4 (8.3)	94.8 (8.3)	93.8 (8.7)	.78
SANE Sports score, mean (SD)	82.3 (19)	86.2 (13.6)	77.2 (24.4)	.23
Patient satisfaction, n%				.37
Satisfied	20 (95%)	11 (92%)	9 (100%)	
Dissatisfied	1 (5%)	1 (5%)	0 (0%)	
SF-12V2 Physical Component Summary (PCS), mean (SD)	52.9 (6.8)	53.9 (6.9)	51.6 (6.8)	.47
SF-12V2 Mental Component Summary (MCS), mean (SD)	53.9 (9.7)	58.7 (3.3)	47.4 (11.7)	<b>.005</b>

NOTE. P-values > .05 are significant and are listed in bold.

ADL, activities of daily living; LEFS, Lower Extremity Functional Scale; SANE, Single Assessment Numeric Evaluation; SD, standard deviation; SF-12, 12-Item Short Form Survey; VAS, visual analog scale.

rely on cortical fixation, the pullout force depends on the thickness of the cortical bone in which the anchor is placed.<sup>23</sup> All-suture anchors allow for equivalent strength in repair while preserving bone, which is valuable for fixation in smaller bony areas and in the setting of revision surgery.

The most effective postoperative bracing after proximal hamstring repair is not well understood. One study described the high degree of variability in protocols across the United States.<sup>24</sup> The majority of protocols in this study used a brace postoperatively (71% total, 34% braced the knee, 23% braced the hip, 14% not specified). Bracing is most commonly prescribed with the knee flexed between 30 and 60°, with the goal of limiting hip flexion and knee extension. A cadaveric study assessed the biomechanical strength of 3 tendon proximal hamstring repairs at different degrees of hip flexion. They found that with cycling loading, the least amount of gap formation occurred at 0° of hip flexion (2.39 mm) and was highest at 90° of hip flexion (4.19 mm).<sup>25</sup> Based on these results, they recommended bracing to limit hip flexion. In contrast, Lazaro and Banffy<sup>16</sup> reported

on 57 patients (mean 32 months' follow-up) who underwent proximal hamstring repair without any bracing with one re-rupture requiring revision repair. Instead, they counseled patients to avoid concurrent hip flexion and knee extension. Our protocol uses a hinged knee brace locked in extension when upright, and with the knee flexed to 90° when seated. We feel this strikes a balance between protecting the proximal hamstring repair and allowing patients a more functional position of their hip and knee. Similar to knee immobilizer bracing after total hip prosthetic dislocations, use of a hinged knee brace limits hip motion but allows the knee to bend when the patient is seated. This allows for prolonged sitting activities and improved ability to perform functions such as desk work or traveling in a car. Further, the ability to bend and extend the knee during the first 6 weeks of recovery allows for improved venous circulation which may contribute to the lower rates of VTE with our protocol compared with previous studies.

Proximal hamstring injuries are challenging to rehabilitate. We found that patients undergoing primary repair instead of reconstruction both had minimal pain

**Table 3.** Outcomes by Primary Proximal Hamstring Repair Compared With Reconstruction

	Total N = 21	Primary N = 18	Reconstruction N = 3	P Value
Gender, n (%)				1
Male	7 (33%)	6 (33%)	1 (33%)	
Female	14 (67%)	12 (67%)	2 (67%)	
Age, y, mean (SD)	50.4 (9.5)	51.4 (8.6)	44.3 (14.2)	.24
Tear type, n (%)				.50
Complete	17 (81%)	15 (83%)	2 (67%)	
Partial	4 (19%)	3 (17%)	1 (33%)	
Injury type, n (%)				<b>.03</b>
Acute	12 (57%)	12 (67%)	0 (0%)	
Chronic	9 (43%)	6 (33%)	3 (100%)	
Repair technique, n (%)				.24
Open	15 (71%)	12 (67%)	3 (100%)	
Endoscopic	6 (29%)	6 (33%)	0 (0%)	
Retraction, cm, mean (SD)	4.9 (3.2)	3.8 (1.9)	11 (2.6)	<b>&lt;.001</b>
Sciatic neurolysis, n (%)				.07
Yes	11 (52%)	8 (44%)	3 (100%)	
No	10 (48%)	10 (56%)	0 (0%)	
LEFS score, mean (SD)	74.3 (7.5)	75.4 (7.4)	67.3 (4.7)	.09
Tegner Activity Scale, n (%)				<b>.02</b>
Score before injury = after injury	13 (62%)	13 (72%)	0 (0%)	
Score before injury ≠ after injury	8 (38%)	5 (28%)	3 (100%)	
VAS Pain score, mean (SD)	2.1 (0.78)	2 (0.9)	2.3 (0.58)	.58
SANE ADL score, mean (SD)	94.4 (8.3)	95.7 (7.3)	86.3 (11)	.07
SANE Sports score, mean (SD)	82.3 (19)	86 (16.5)	60.3 (21.2)	<b>.03</b>
Patient satisfaction, n (%)				.68
Satisfied	20 (95%)	17 (94%)	3 (100%)	
Dissatisfied	1 (5%)	1 (6%)	0 (0%)	
SF-12V2 Physical Component Summary (PCS), mean (SD)	52.9 (6.8)	53 (7.4)	52.4 (0.8)	.89
SF-12V2 Mental Component Summary (MCS), mean (SD)	53.9 (9.7)	56 (6.5)	41.2 (17.5)	<b>.01</b>

NOTE. *P*-values > .05 are significant and are listed in bold.

ADL, activities of daily living; LEFS, Lower Extremity Functional Scale; SANE, Single Assessment Numeric Evaluation; SD, standard deviation; SF-12, 12-Item Short Form Survey; VAS, visual analog scale.

and similar ability to do ADLs. However, those undergoing primary repair were able to get back to their baseline level of sports more frequently based on the Tegner activity scale and had greater SANE Sports scores. Our results are consistent with the study by Rust et al.,<sup>26</sup> who showed that acute repair was superior to both chronic repair and reconstruction for return to sports. They found that all proximal hamstring surgeries (acute vs chronic, and repair vs reconstruction) enabled patients to return to their ADLs. They suggested that although acute repair is recommended in patients desiring return to sports, a delayed repair or reconstruction could be considered in lower demand patients or those with medical comorbidities.<sup>26</sup> Similarly, in a case series of 56 patients undergoing proximal hamstring repair, Cohen et al.<sup>27</sup> found that those undergoing acute repair had greater hamstring-specific and functional scores. The benefits of undergoing acute, primary repair for active individuals is clear. For chronic injuries, repair or reconstruction of chronic ruptures may allow patients to successfully perform ADLs. Our results are limited by small sample size of patients undergoing proximal hamstring reconstruction.

Interestingly, patients who underwent primary proximal hamstring repair and those who had acute repair had greater mental health scores compared with those undergoing reconstruction (of which, all were chronic injuries). Chronic musculoskeletal conditions are associated with impaired mental health and greater rates of anxiety, depression, insomnia, and fatigue.<sup>28</sup> Athletes of all levels seem to be particularly at risk for mental health issues after musculoskeletal injury. This may be due to high athletic identity, the concept that athletes define themselves based on their sport or activity, which then serves as a basis of their sense of self-worth.<sup>29</sup> A study by Furie et al.<sup>30</sup> found that injured athletes showed greater rates of anxiety and depression compared with the general population and those who had to involuntarily retire from their sport had increased psychological distress. These data suggest that earlier surgical intervention for injuries such as proximal hamstring ruptures, when properly indicated, may reduce impact on mental health. Future studies are required to further assess this. Our series included only 3 patients undergoing reconstruction; thus, further study on a larger cohort of this group of patients is

necessary. Unfortunately, there is limited research on interventions addressing mental health after musculoskeletal injury but an approach that holistically integrates both physical and psychological improvement is generally recommended.

### Limitations

Limitations of this study include its retrospective, noncontrolled, case series design and that it was performed at a single, tertiary-care, academic institution. This is a relatively small series of patients with varied tear types and therefore, a variety of surgical techniques included. Preoperative baseline scores were not available for all PRO measures, which limits comparison to postoperative scores. Only a few patients (n = 3) underwent proximal hamstring reconstruction; thus, interpretation of results and comparison is limited for this group of patients.

### Conclusions

All-suture anchors for proximal hamstring repair with an experimental, accelerated postoperative rehabilitation and bracing protocol result in good outcomes and patient satisfaction with minimal risk of complications.

### Disclosure

The authors declare the following financial interests/personal relationships which may be considered as potential competing interests: A.L.Z. reports personal fees from Stryker and DePuy Mitek, outside the submitted work. All other authors (S.E.W., K.R.J., J.G.C.) declare that they have no known competing financial interests or personal relationships that could have appeared to influence the work reported in this paper. Full ICMJE author disclosure forms are available for this article online, as [supplementary material](#).

### References

1. Fletcher AN, Cheah JW, Nho SJ, Mather RC 3rd. Proximal Hamstring Injuries. *Clin Sports Med* 2021;40(2):339-361.
2. Degen RM. Proximal Hamstring Injuries: Management of Tendinopathy and Avulsion Injuries. *Curr Rev Musculoskelet Med* 2019;12(2):138-146.
3. Bertiche P, Mohtadi N, Chan D, Hölmich P. Proximal hamstring tendon avulsion: State of the art. *J ISAKOS* 2021;6:237-246.
4. Laszlo S, Jonsson KB. Increasing incidence of surgically treated hamstring injuries: A nationwide registry study in Sweden between 2001 and 2020. *Acta Orthop* 2023;94:336-341.
5. Hassid BV, Warrick AE, Ray JW. Hamstring strain ultrasound case series: Semitendinosus injuries dominant in NCAA Division I athletes [published online September 1, 2023]. *J Athl Train*. <https://doi.org/10.4085/1062-6050-0064.23>.
6. Moatshe G, Chahla J, Vap AR, Ferrari M, Sanchez G, Mitchell JJ, LaPrade RF. Repair of proximal hamstring tears: A surgical technique. *Arthrosc Tech* 2017;6:e311-e317.
7. Sanderson B, Stumetz K, Jazayeri R. Repair of proximal hamstring tear utilizing a suture bridge knotless construct. *Case Rep Orthop* 2020;2020:8840418.
8. Otto A, DiCosmo AM, Baldino JB, et al. Biomechanical evaluation of proximal hamstring repair: All-Suture anchor versus titanium suture anchor. *Orthop J Sports Med* 2020;8:2325967119892925.
9. Gerhardt MB, Assenmacher BS, Chahla J. Proximal hamstring repair: A biomechanical analysis of variable suture anchor constructs. *Orthop J Sports Med* 2019;7:2325967118824149.
10. Lefevre N, Bohu Y, Klouche S, Herman S. Surgical technique for repair of acute proximal hamstring tears. *Orthop Traumatol Surg Res* 2013;99:235-240.
11. Van der Bracht H, Van den Langenbergh T, Pouillon M, Verhasselt S, Verniers P, Stoffelen D. Rotator cuff repair with all-suture anchors: A midterm magnetic resonance imaging evaluation of repair integrity and cyst formation. *J Shoulder Elbow Surg* 2018;27:2006-2012.
12. Ro K, Pancholi S, Son HS, Rhee YG. Perianchor cyst formation after arthroscopic rotator cuff repair using all-suture-type, bioabsorbable-type, and PEEK-type anchors. *Arthroscopy* 2019;35:2284-2292.
13. Bernardoni ED, Frank RM, Veera SS, et al. Biomechanical analysis of medial-row all-suture suture anchor fixation for rotator cuff repair in a pair-matched cadaveric model. *Arthroscopy* 2019;35:1370-1376.
14. Otto A, Mehl J, Obopilwe E, et al. Biomechanical comparison of onlay distal biceps tendon repair: All-suture anchors versus titanium suture anchors. *Am J Sports Med* 2019;47:2478-2483.
15. Engler ID, Bragg JT, Miller SL. Incidence of deep venous thrombosis associated with proximal hamstring rupture. *Orthop J Sports Med* 2019;20(7):2325967119888486.
16. Lazaro LE, Banffy MB. Is brace immobilization needed following surgical repair of proximal hamstring tears? *Orthop J Sports Med* 2019;7:2325967119S00418.
17. Léger-St-Jean B, Gorica Z, Magnussen RA, Vasileff WK, Kaeding CC. Accelerated rehabilitation results in good outcomes following acute repair of proximal hamstring ruptures. *Knee Surg Sports Traumatol Arthrosc* 2019;27:3121-3124.
18. Looney AM, Day HK, Comfort SM, Donaldson ST, Cohen SB. Proximal hamstring ruptures: Treatment, rehabilitation, and return to play. *Curr Rev Musculoskelet Med* 2023;16:103-113.
19. Mehta SP, Fulton A, Quach C, Thistle M, Toledo C, Evans NA. Measurement properties of the lower extremity functional scale: A systematic review. *J Orthop Sports Phys Ther* 2016;46:200-216.
20. Reza T, Hinkle AJ, Perez-Chaumont A, Brown SM, Mulcahey MK. Systematic review of outcome measures used after proximal hamstring repair. *Orthop J Sports Med* 2021;9:23259671211005101.
21. Forlizzi JM, Nacca CR, Shah SS, et al. Acute proximal hamstring tears can be defined using an imaged-based classification. *Arthrosc Sports Med Rehabil* 2022;4:e653-e659.



22. Asokan A, Plastow R, Chang JS, et al. Incidence of symptomatic venous thromboembolism in proximal hamstring repair: A prospective cohort study. *Orthop J Sports Med* 2021;9:23259671211012420.
23. Ntalos D, Huber G, Sellenschloh K, et al. All-suture anchor pullout results in decreased bone damage and depends on cortical thickness. *Knee Surg Sports Traumatol Arthrosc* 2021;29:2212-2219.
24. Lightsey HM, Kantrowitz DE, Swindell HW, Trofa DP, Ahmad CS, Lynch TS. Variability of United States online rehabilitation protocols for proximal hamstring tendon repair. *Orthop J Sports Med* 2018;6:2325967118755116.
25. Harvey MA, Singh H, Obopilwe E, Charette R, Miller S. Proximal hamstring repair strength: A biomechanical analysis at 3 hip flexion angles. *Orthop J Sports Med* 2015;3:2325967115576910.
26. Rust DA, Giveans MR, Stone RM, Samuelson KM, Larson CM. Functional outcomes and return to sports after acute repair, chronic repair, and allograft reconstruction for proximal hamstring ruptures. *Am J Sports Med* 2014;42:1377-1383.
27. Cohen SB, Rangavajjula A, Vyas D, Bradley JP. Functional results and outcomes after repair of proximal hamstring avulsions. *Am J Sports Med* 2012;40:2092-2098.
28. Garnæs KK, Mørkved S, Tønne T, Furan L, Vasseljen O, Johannessen HH. Mental health among patients with chronic musculoskeletal pain and its relation to number of pain sites and pain intensity: A cross-sectional study among primary health care patients. *BMC Musculoskelet Disord* 2022;22(23):1115.
29. Park AL, Furie K, Wong SE. Stronger athlete identity is a risk factor for more severe depressive symptoms after musculoskeletal injury in pediatric athletes: A systematic review. *Curr Rev Musculoskelet Med* 2023;16:220-228.
30. Furie K, Park AL, Wong SE. Mental health and involuntary retirement from sports post-musculoskeletal injury in adult athletes: A systematic review. *Curr Rev Musculoskelet Med* 2023;16:211-219.