

UCSF

UC San Francisco Previously Published Works

Title

De Novo Variants in the ATPase Module of MORC2 Cause a Neurodevelopmental Disorder with Growth Retardation and Variable Craniofacial Dysmorphism

Permalink

<https://escholarship.org/uc/item/6n82g05c>

Journal

American Journal of Human Genetics, 107(2)

ISSN

0002-9297

Authors

Sacoto, Maria J Guillen
Tchasovnikarova, Iva A
Torti, Erin
et al.

Publication Date

2020-08-01

DOI

10.1016/j.ajhg.2020.06.013

Peer reviewed

De Novo Variants in the ATPase Module of MORC2 Cause a Neurodevelopmental Disorder with Growth Retardation and Variable Craniofacial Dysmorphism

Maria J. Guillen Sacoto,^{1,*} Iva A. Tchasovnikarova,^{2,3} Erin Torti,¹ Cara Forster,¹ E. Hallie Andrew,⁴ Irina Anselm,⁵ Kristin W. Baranano,⁶ Lauren C. Briere,⁷ Julie S. Cohen,^{6,8,9} William J. Craigen,¹⁰ Cheryl Cytrynbaum,^{11,12} Nina Ekhilevitch,¹³ Matthew J. Elrick,⁶ Ali Fatemi,^{6,8,14} Jamie L. Fraser,⁴ Renata C. Gallagher,¹⁵ Andrea Guerin,¹⁶ Devon Haynes,¹⁷ Frances A. High,⁷ Cara N. Inglese,¹² Courtney Kiss,¹⁶ Mary Kay Koenig,¹⁸ Joel Krier,¹⁹ Kristin Lindstrom,²⁰ Michael Marble,²¹ Hannah Meddaugh,²² Ellen S. Moran,²³ Chantal F. Morel,^{24,25} Weiyi Mu,²⁶ Eric A. Muller II,²⁷ Jessica Nance,^{6,9} Marvin R. Natowicz,²⁸ Adam L. Numis,²⁹ Bridget Ostrem,³⁰ John Pappas,³¹ Carl E. Stafstrom,⁶ Haley Streff,¹⁰ David A. Sweetser,⁷ Marta Szybowska,²⁴ Undiagnosed Diseases Network, Melissa A. Walker,³² Wei Wang,¹ Karin Weiss,¹³ Rosanna Weksberg,^{11,12,33} Patricia G. Wheeler,¹⁷ Grace Yoon,¹² Robert E. Kingston,^{2,3} and Jane Juusola¹

MORC2 encodes an ATPase that plays a role in chromatin remodeling, DNA repair, and transcriptional regulation. Heterozygous variants in *MORC2* have been reported in individuals with autosomal-dominant Charcot-Marie-Tooth disease type 2Z and spinal muscular atrophy, and the onset of symptoms ranges from infancy to the second decade of life. Here, we present a cohort of 20 individuals referred for exome sequencing who harbor pathogenic variants in the ATPase module of *MORC2*. Individuals presented with a similar phenotype consisting of developmental delay, intellectual disability, growth retardation, microcephaly, and variable craniofacial dysmorphism. Weakness, hyporeflexia, and electrophysiologic abnormalities suggestive of neuropathy were frequently observed but were not the predominant feature. Five of 18 individuals for whom brain imaging was available had lesions reminiscent of those observed in Leigh syndrome, and five of six individuals who had dilated eye exams had retinal pigmentary abnormalities. Functional assays revealed that these *MORC2* variants result in hyperactivation of epigenetic silencing by the HUSH complex, supporting their pathogenicity. The described set of morphological, growth, developmental, and neurological findings and medical concerns expands the spectrum of genetic disorders resulting from pathogenic variants in *MORC2*.

Microrchidia CW-type zinc finger protein 2 (*MORC2*, MIM: 616661) is a member of a family of ATPases fundamental for epigenetic silencing through chromatin modification.^{1–3} It has most commonly been associated with autosomal-dominant Charcot-Marie-Tooth (CMT) disease type 2Z (MIM: 616688), a form of axonal neuropathy with progressive weakness, muscle cramps, and sensory impair-

ment presenting in childhood or early adulthood.^{4–7} However, some reported individuals presented with hypotonia, generalized muscle weakness, and delayed milestones,⁴ or occasionally with spinal muscular atrophy, intellectual disability, hearing loss, pyramidal signs, microcephaly, and brain atrophy, in infancy.^{4,5,8–10} The association of *MORC2* variants with human disease has only recently

¹GeneDx, Inc., Gaithersburg, MD 20877, USA; ²Department of Molecular Biology, Massachusetts General Hospital, Boston, MA 02114, USA; ³Department of Genetics, Harvard Medical School, Boston, MA 02114, USA; ⁴Myelin Disorders Program, Rare Disease Institute, Children's National Hospital, Washington, DC 20010, USA; ⁵Department of Neurology, Boston Children's Hospital, Boston, MA 02115, USA; ⁶Department of Neurology, Johns Hopkins School of Medicine, Baltimore, MD 21287, USA; ⁷Department of Medical Genetics and Metabolism, Massachusetts General Hospital, Boston, MA 02114, USA; ⁸Department of Neurology and Developmental Medicine, Division of Neurogenetics, Kennedy Krieger Institute, Baltimore, MD 21205, USA; ⁹Center for Genetic Muscle Disorders, Kennedy Krieger Institute, Baltimore, MD 21205, USA; ¹⁰Department of Molecular and Human Genetics, Baylor College of Medicine, Houston, TX 77030, USA; ¹¹Program in Genetics and Genome Biology, The Hospital for Sick Children, Toronto, ON M5G 1X8, Canada; ¹²Division of Clinical and Metabolic Genetics, The Hospital for Sick Children, Toronto, ON M5G 1X8, Canada; ¹³The Genetics Institute, Rambam Health Care Campus, Haifa 3109601, Israel; ¹⁴Department of Pediatrics, Johns Hopkins University School of Medicine, Baltimore, MD 21287, USA; ¹⁵Department of Pediatrics, Division of Medical Genetics, University of California, San Francisco, CA 94158, USA; ¹⁶Division of Medical Genetics, Department of Pediatrics, Queen's University, Kingston, ON K7L 2V7, Canada; ¹⁷Division of Genetics, Arnold Palmer Hospital for Children, Orlando Health, Orlando, FL 32806, USA; ¹⁸Department of Pediatrics, University of Texas McGovern Medical School, Houston, TX 77030, USA; ¹⁹Division of Genetics, Department of Medicine, Brigham and Women's Hospital, Boston, MA 02115, USA; ²⁰Division of Genetics and Metabolism, Phoenix Children's Hospital, Phoenix, AZ 85016, USA; ²¹Department of Pediatrics, Division of Clinical Genetics and Metabolism, LSU Health Sciences Center and Children's Hospital, New Orleans, LA 70112, USA; ²²Department of Clinical Genetics and Metabolism, Children's Hospital New Orleans, New Orleans, LA 70118, USA; ²³Hassenfeld Children's Hospital at New York University Langone, New York University Langone Orthopedic Hospital, New York, NY 10003, USA; ²⁴Fred A. Litwin Family Center in Genetic Medicine, University Health Network, Toronto, ON M5T 3L9, Canada; ²⁵Department of Medicine, University of Toronto, Toronto, ON M5S 1A8, Canada; ²⁶McKusick-Nathans Institute of Genetic Medicine, Johns Hopkins University School of Medicine, Baltimore, MD 21287, USA; ²⁷Clinical Genetics, Stanford Children's Health, San Francisco, CA 94109, USA; ²⁸Institutes of Pathology and Laboratory Medicine and Genomic Medicine, Cleveland Clinic, Cleveland, OH 44195, USA; ²⁹Department of Neurology and Pediatrics, University of California, San Francisco, San Francisco, CA 94158, USA; ³⁰Department of Neurology, Massachusetts General Hospital, Boston, MA 02114, USA; ³¹Clinical Genetic Services, Pediatrics, NYU Grossman School of Medicine, New York, NY 10016, USA; ³²Department of Neurology, Division of Neurogenetics, Massachusetts General Hospital, Boston, MA 02114, USA; ³³Department of Pediatrics and Institute of Medical Science, University of Toronto, Toronto, ON M5G 1X8, Canada

*Correspondence: mguillen@genedx.com

<https://doi.org/10.1016/j.ajhg.2020.06.013>

© 2020 American Society of Human Genetics.



been noted, and most of the individuals were ascertained through studies of neuropathies. We used a hypothesis-free approach to assess common characteristics in individuals with *de novo* variants in *MORC2* who were referred for exome sequencing at a clinical laboratory.

We identified 15 individuals with *de novo* variants in *MORC2*. In addition we included an affected mother-daughter pair harboring a novel variant in *MORC2* (subjects 19 and 20) and three individuals heterozygous for recurrent variants for whom parental studies could not be completed (subjects 5, 13, and 16), bringing our total to 20 individuals. Clinical data were obtained from the referring providers or via provider completion of a questionnaire. This study was conducted under GeneDx's research protocol "Research to Expand the Understanding of Genetic Variants: Clinical and Genetic Correlations," approved by the Western Institutional Review Board (IRB) (protocol 20171030). All research subjects provided written consent to participate through either GeneDx's research protocol or as required by their clinical institution. Where applicable, informed written consent was obtained for the use of photographs.

For all subjects except subject 9, we used genomic DNA from the proband and parents (when available) to capture the exonic regions and flanking splice junctions of the genome via the SureSelect Human All Exon V4 (50 Mb), the Clinical Research Exome kit (Agilent Technologies), or the IDT xGen Exome Research Panel v1.0. Massively parallel (NextGen) sequencing was done on an Illumina system with 100 bp or greater paired-end reads. Reads were aligned to human genome build GRCh37/UCSC hg19 and analyzed for sequence variants via a custom-developed analysis tool. Additional sequencing technology and the variant interpretation protocol have been previously described.¹¹ The general assertion criteria for variant classification can be found in Table S1. For subject 9, identified by communication with another testing laboratory (K.W., unpublished data), trio exome sequencing was performed on a Novaseq6500 platform (Illumina) in a CLIA certified laboratory (Gene by Gene) via the Agilent SureSelect Clinical Research Exome Capture Enrichment kit (Agilent Technologies) to capture the protein-coding regions. Mapping of the obtained reads to the reference genome (build GRCh37/hg19), variant calling, annotation, and data analysis were done with the Genoox data analysis platform. Variants were prioritized on the basis of their effect on the protein (missense, nonsense, frameshift, splice-site) and their having a minor allele frequency below 1% in general population databases, such as gnomAD,¹² the Greater Middle East Variome, and the Rambam Genetics Institute internal database of over 1,500 Israeli exomes. All variants were confirmed by Sanger sequencing and reported with the NM_001303256.1 transcript of *MORC2* (Figure S1).

We identified nine missense variants clustering in the ATPase module of *MORC2* (Tables 1 and S1, Figure 1). None of these variants are reported in gnomAD,¹² and all

were considered to be pathogenic or likely pathogenic in the context of the 2015 American College of Medical Genetics and Genomics (ACMG) standards and guidelines for the interpretation of sequence variants (Table S1).¹³ To our knowledge, five (55.6%) of the variants were previously unreported. Published individuals for whom clinical information was available were included in Table 1 for comparison.

Our cohort includes a diverse group of individuals; 12/20 (60%) were female, and the average age at the time of last examination was 14.2 years (range 1.3–49 years). The primary indication for genetic testing was developmental delay or growth failure, with the exception of the oldest individual (Subject 18) who presented with a diagnosis of sensorimotor neuropathy. The most commonly described features include gross motor delay (19/20, 95%), short stature (height < 2 SDs from the mean for age, 18/20, 90%), intellectual disability (18/20, 90%), and microcephaly (head circumference < 2 SDs from the mean for age, 15/20, 75%) (Tables 1 and 2). Facial dysmorphism was reported in 16/20 (80%) individuals, but the features were subtle and variable. Facial characteristics often consist of a long face with a narrow jaw, deep set eyes, broad nasal tip, thin upper lip, dental crowding, and high palate (Figure 2). Gait abnormalities were reported in 15/16 (94%) individuals; hypotonia (11/16, 69%) and decreased or absent deep tendon reflexes (DTRs; 9/18, 50%) were also commonly noted. Ten individuals had nerve conduction studies (NCSs); four of them reportedly had normal testing, whereas six showed sensorimotor peripheral neuropathy. Hearing loss was reported in 11/19 (58%) and was progressive; two individuals received cochlear implants (subjects 4 and 15) and two more use hearing aids (subjects 5 and 13). Pigmentary retinopathy was reported in 5/6 (83%) individuals who had dilated eye exams. Eighteen individuals had a magnetic resonance imaging (MRI) of the brain, which was abnormal in 12 individuals (66%). Reported changes included Leigh syndrome-like lesions (symmetric abnormalities in the brainstem, basal ganglia, or cerebellum) in five of those 18 individuals. A diagnosis of mitochondrial disease was suspected in seven individuals (subjects 1, 3, 4, 5, 7, 10, and 12).

The recurrent variants present in our cohort, c.79G>A (p.Glu27Lys), c.260C>T (p.Ser87Leu), c.394C>T (p.Arg132Cys), and c.1181A>G (p.Tyr394Cys), have been previously reported in the medical literature.^{4,5,14,16} Clinical findings among individuals harboring the same variant were assessed (Table 1). Five subjects (subjects 2–6) were heterozygous for c.79G>A (p.Glu27Lys). This variant was previously reported *de novo* in a child with developmental delay by the Deciphering Developmental Disorders Study group,¹⁶ but detailed clinical information was not available. Developmental delay, intellectual disability, and microcephaly were reported in four individuals. Subject 6 was referred for evaluation of declining growth parameters, but at the time of her last assessment, her head circumference was in the normal range (1.35 SDs below the mean) and she was too young to

Table 1. Detailed Clinical Description of Individuals with Variants in the ATPase module of *MORC2*

Affected Individual	Mutation	Inheritance	Sex	Age at Examination	Growth Parameters (Z Scores)*			Cognitive and Development				Hearing Loss	Endocrine	Neuromuscular Features	EMG/NCS	Brain MRI	Other Features	Additional Variants Reported
					Height	Weight	HC	Motor Delay	Speech Delay	Intellectual Disability	Facial Dysmorphism							
Subject 1	Thr24Ile	<i>de novo</i>	female	4.2 years	-3.41	-2.95	-3.72	+	+	mild	+	-	precocious puberty	high arches, hyperreflexia, spasticity, ataxic and jerking movements of arms and legs, thoracic kyphosis; only walks with a walker	normal	abnormal T2 hyperintensity in right cerebral peduncle, cortical atrophy with ventriculomegaly, abnormal signal in right putamen and diffuse, ill-defined white matter hyperintensity	strabismus	N/A
Subject 2	Glu27Lys	<i>de novo</i>	male	17 years	-3.66	-5.6	-2.05	+	+	mild	-	-	delayed puberty, growth hormone deficiency, hypothyroidism	high arches, toe walking, spasticity, hyperreflexia	N/A	normal at age 14 years	N/A	N/A
Subject 3	Glu27Lys	<i>de novo</i>	female	4.8 years	-3.13	-2.36	-5.03	+	+	moderate	+	-	vitamin D deficiency	high arches, hyporeflexia in lower extremities	N/A	severe delay in myelination with T2 hyperintensity in the substantia nigra, mild cerebral atrophy	severe GERD, hyperopia, ptosis, capillary hemangioma	c.81dupG in <i>COX14</i> , heterozygous (LPATH); p.Leu368Arg in <i>DHTKD1</i> , heterozygous (VUS)
Subject 4	Glu27Lys	<i>de novo</i>	male	26.6 years	-3.28	-2.91	-0.94	+	+	mild	+	-	SNHL, severe, hearing aid in one ear and a cochlear implant in the other	hyporeflexia, reduced range of motion in large joints, knee contractures, crouched and stiff gait	normal	normal at age 12 years	salt and pepper maculopathy, strabismus, oromotor dyspraxia, constipation, autism	m.3397A>G, homoplasmic (VUS)
Subject 5	Glu27Lys	unknown	female	5.5 years	-2.89	0.4	-4.02	+	+	severe	-	-	mixed, moderate-profound, hearing aids	hypotonia, weakness, hyperreflexia	N/A	ventriculomegaly, supratentorial and infratentorial volume loss with diffusely abnormal white matter and prominent cavitary encephalomalacia in the putamina and caudate heads	retinal dystrophy on ERG, bilateral ptosis, esotropia, epilepsy, GERD, feeding difficulties, laryngomalacia, sialorrhea, history of acute respiratory failure with illness, neutropenia, lactic acidosis	N/A

(Continued on next page)

Table 1. Continued

Affected Individual	Mutation	Inheritance	Sex	Age at Examination	Growth Parameters (Z Scores) ^a				Cognitive and Development				EMG/NCS	Brain MRI	Other Features	Additional Variants Reported				
					Height	Weight	HC	Weight HC	Motor Delay	Speech Delay	Intellectual Disability	Facial Dysmorphism					Hearing Loss	Endocrine	Neuromuscular Features	
Subject 6	Glu27Lys	<i>de novo</i>	female	1.3 years	-1.58	-0.93	-1.35	N/A	+	+	+	+	-	-	N/A	axial hypotonia, appendicular hypertonía (more pronounced in the lower extremities), hyperreflexia and extensor plantar response	normal at 10 months	non-specific peripheral retinal deposits	N/A	
Subject 7	Ser87Leu	<i>de novo</i>	male	4.8 years	-2.32	-2.58	-0.4	severe	+	+	+	+	-	-	N/A	hypotonia, decreased muscle bulk, proximal weakness, areflexia, non-ambulatory	12 hyperintensities of the central tegmental tract and superior cerebral peduncles, globus palladi, subthalamic nucleus and substantia nigra	unprovoked episodic deterioration in neurologic symptoms, followed by gradual recovery, frequent respiratory infections	N/A	
Subject 8	Ser87Leu	<i>de novo</i>	male	5 years	-3.34	-4.08	-3.46	mild-to-moderate	-	+	+	-	-	-	N/A	weakness, decreased muscle bulk, mildly elevated creatine kinase, areflexia, wide based and waddling gait, uses a walker and braces for ambulation, mild kyphosis	axonal motor neuropathy	proximally placed thumbs, hirsutism	N/A	
Hyun et al. ^{1,4}	Ser87Leu	<i>de novo</i>	male	13 years	N/A	N/A	N/A	N/A	N/A	+	N/A	N/A	N/A	N/A	N/A	hypotonia, weakness, areflexia, scoliosis, wheelchair bound	sensory motor neuropathy	N/A	N/A	
	Ser87Leu	<i>de novo</i>	female	10 years	N/A	N/A	N/A	N/A	+	N/A	N/A	N/A	N/A	N/A	N/A	hypotonia, weakness, areflexia, motor scoliosis, wheelchair bound	sensory motor neuropathy	cataract	N/A	
Sevilla et al. ⁴	Ser87Leu	unknown	female	1.6 years	N/A	N/A	(<i><</i> third percentile) ^b	-	N/A	+	-	N/A	N/A	N/A	N/A	hypotonia, weakness, areflexia	sensory motor neuropathy	*mild dysmaturative features ^c	N/A	N/A
Subject 9	Ala88Val	<i>de novo</i>	female	23 years	-6.61	-3.9	-9.7	severe	+	+	+	+	N/A	N/A	N/A	hammer toes, spasticity, non-ambulatory	N/A	decreased vision, short and broad toes	N/A	

(Continued on next page)

Table 1. Continued

Affected Individual	Mutation	Inheritance	Sex	Age at Examination	Growth Parameters (Z Scores) ^a				Cognitive and Development				Additional Variants Reported						
					Height	Weight	HC	Weight HC	Motor Delay	Speech Delay	Intellectual Disability	Facial Dysmorphism		Hearing Loss	Endocrine	Neuromuscular Features	EMG/NCS	Brain MRI	Other Features
Subject 10	Arg132Cys	<i>de novo</i>	male	6 years	-2.12	-0.67	-2.24	-2.24	+	+	mild	+	-	-	mild diffuse hypotonia, hyporeflexia, possible mild muscle weakness, intention tremor of upper extremities, intermittent exotropia, slow gait with trace circumduction at left hip	normal at age 4 years	lesions of the periaqueductal gray matter, thalami, substantia nigra, and geniculocakarine tract at 17 months; periaqueductal gray matter lesions had resolved by age 4 years, whereas other lesions remained stable	pectus excavatum, fifth finger clinodactyly, broad great toes, cuts marmorata, subtle retinal pigmentary changes at age 7 years	N/A
Subject 11	Arg132Cys	<i>de novo</i>	male	8.3 years	-3.69	-3.32	-2.04	-2.04	+	+	mild	+	SNHL, mild-to-moderate	-	hypotonia, weakness, areflexia, hammetoes, pes cavus, intoeing gait	sensory motor polyneuropathy	hypomyelination	N/A	N/A
Subject 12	Arg132Cys	<i>de novo</i>	male	15 years	-2.5	-2.82	-2.12	-2.12	+	+	mild (non-verbal)	+	SNHL, moderate, unilateral	precocious puberty	mild hypotonia, patellar hyporeflexia, severe scoliosis	mild axonal neuropathy	normal at 9 years old; previous exams raised concern for possible mild periventricular gliosis	absence seizures, velopharyngeal insufficiency, eosinophilic esophagitis, chronic constipation, history of feeding difficulties	p.Met34Thr in <i>GJB2</i> , heterozygous (PATH); p.Arg603Gln in <i>TCF12</i> , heterozygous, <i>de novo</i> (VUS)
Subject 13	Arg132Cys	not maternal (father not tested)	female	34 years	-2.76	0.1	-2.64	-2.64	-	+	mild	+	SNHL, unilateral hearing aid	hypothyroidism, premature thelarche, PCOS	weakness, hypotonia, normal reflexes, poor balance and coordination, lordosis	N/A	cerebral and cerebellar volume loss, a couple of foci of T2 hyperintensity in cerebral white matter	narrow shoulders, brachydactyly, small hands, clinodactyly, myopia, possible macular degeneration, GERD, gallbladder disease, heterochromia	N/A
Hyun et al. ^{1,4}	Arg132Leu	unknown	male	30 years	N/A	N/A	N/A	N/A	N/A	N/A	N/A	+	N/A	weakness, high arches, areflexia	sensory motor neuropathy	N/A	N/A	N/A	
Subject 14	Arg266Ser	<i>de novo</i>	female	12 years	-3.3	-0.96	-3.5	-3.5	+	+	moderate	+	SNHL, mild-to-moderate, bilateral	-	hypotonia, hyperreflexia, mild hemiplegic gait, tremor, dystonia, scoliosis	N/A	cortical dysplasia	fetal finger pads, bilateral sandal gap, clinodactyly of toes 3, 4, and 5	N/A

(Continued on next page)

Table 1. Continued

Affected Individual	Mutation	Inheritance	Sex	Age at Examination	Growth Parameters (Z Scores) ^a			Cognitive and Development				Hearing Loss	Endocrine	Neuromuscular Features	EMG/NCS	Brain MRI	Other Features	Additional Variants Reported
					Height	Weight	HC	Motor Delay	Speech Delay	Intellectual Disability	Facial Dysmorphism							
Subject 15	Ser388Arg	<i>de novo</i>	female	9 years	-2.07	-0.82	-3.27	+	+	moderate	+	SNHL, progressive, bilateral, has cochlear implants	precocious puberty	hypotonia, difficulty with tandem gait, trips when running, mild intention tremor	normal at age 9 years	delayed myelination, mild cerebellar volume loss	linear hypopigmentation in extremities, progressive hyperopia, mild retinal changes with normal ERG	p.Glu510Gln in <i>HADHA</i> , heterozygous (PATH)
Subject 16	Ser388Arg	unknown	female	15 years	-2.07	-1.23	-2.05	+	+	mild	+	SNHL, moderate-to-severe, bilateral	–	severe spasticity (asymmetric), lower extremity hyperreflexia, unsteady, wide based gait, hammertoes and high arches not present on exam at age 12 years but significant at age 15 years	N/A	cerebellar atrophy	resting tremor and dysmetria, history of seizures and staring spells with normal EEG, Wolff-Parkinson-White syndrome, vision impairment	p.Gly145Arg in <i>HCN2</i> , heterozygous (VUS)
Subject 17	Tyr394Cys	<i>de novo</i>	female	8.6 years	-2.1	0.5	-2.1	+	+	mild	+	SNHL, bilateral, mild	–	hypotonia, weakness, high arches, intoeing gait, unilateral tremor, dystonic posturing, spasticity	sensory polyneuropathy	multiple foci stable chronic hemosiderin deposition within the supratentorial and infratentorial white matter	Tetralogy of Fallot	N/A
Subject 18	Tyr394Cys	<i>de novo</i>	male	49 years	-1.2	2.36	2.02	+	+	N/A	–	N/A	hypothyroidism	progressive, asymmetric limb weakness (left > right), muscle atrophy, foot drop, areflexia, ataxia, uses walker or wheelchair for ambulation	sensory motor neuropathy	generalized brain atrophy and scattered subcortical and deep white matter microangiopathic changes disproportionate to patient's age	essential thrombocytosis, grooved tongue, mildly elevated creatine kinase (500–900 U/L)	N/A
Ando et al. ⁵	Tyr394Cys	unknown	male	29 years	N/A	N/A	N/A	–	–	–	N/A	N/A	N/A	hyporeflexia, gait abnormalities, weakness, distal atrophy	sensory neuropathy	N/A	N/A	N/A
Subject 19	Val413Phe	maternal	female	5.6 years	-2.29	-2.35	0.09	+	+	mild	+	–	growth hormone deficiency	hypotonia, weakness, hyporeflexia, ataxia, action tremor	N/A	normal at age 3 years	duplicated collecting system	p.Leu2127Pro in <i>ASXL3</i> , heterozygous, maternal (VUS)
Subject 20	Val413Phe	unknown	female	29 years	-2.2	0.52	-2.33	+	+	mild	+	hearing loss, type unknown	growth hormone deficiency	tingling in extremities with onset in 20 s	N/A	N/A	N/A	p.Leu2127Pro in <i>ASXL3</i> , heterozygous (VUS)

Abbreviations are as follows: EMG, electromyogram; NCS, nerve conduction study; MRI, magnetic resonance imaging; SNHL, sensorineural hearing loss; ERG, electroretinography; GERD, gastroesophageal reflux; N/A, not available; LPATH, likely pathogenic; PATH, pathogenic; VUS, variant of uncertain significance.

^aReported as standard deviations (SDs) of the raw Z score from the mean based on CDC standards.

^bZ scores or raw numbers not available in the publication.

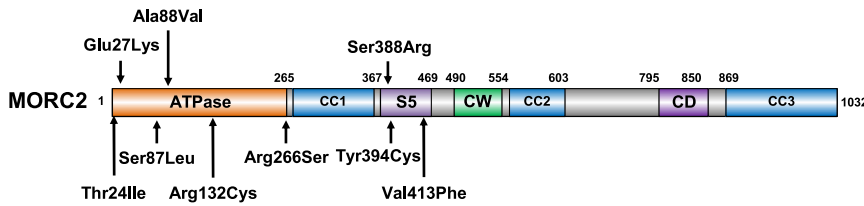


Figure 1. Neurodevelopmental Variants Cluster in the ATPase Module of MORC2
Schematic representation of the domain structure of MORC2. MORC2 binds ATP through its GHKL-type ATPase module,^{2,15} which consists of a GHKL-type ATPase domain (residues 1–265), a transducer S5-like domain ([S5], residues 266–494), and an 80 amino acid antiparallel

coiled-coil insertion within the transducer-like domain (coiled-coil 1 [CC1], residues 282–361) that projects out of the ATPase module.¹⁵ MORC2 also contains two putative chromatin-binding modules, a CW-type zinc finger (CW) and a chromo-like domain (CD), and two additional coiled-coils (CC2 and CC3). All variants described in this paper cluster in the ATPase module of MORC2.

have her intellectual abilities assessed. Two of our subjects required hearing aids at age 5 and 10 years, and further progression required a unilateral cochlear implant at age 13 years in one of them. Brain MRI shows abnormalities of the white matter, basal ganglia, and cerebral atrophy in two individuals, while three others were normal at ages 10 months, 12 years, and 14 years. NCSs were normal in one individual but were not performed in the others. In addition, subject 6 has non-specific peripheral retinal deposits at age 1 year, and two other individuals, the youngest at age 5 years, have clear pigmentary retinopathy. Subject 5 also harbors a pathogenic copy number gain of approximately 3 Mb at chromosome 22q11.21, a contiguous gene duplication (MIM: 608363) with a highly variable phenotype ranging from asymptomatic to severe developmental delay, short stature, hearing loss, and hypotonia, which could be contributing to her presentation. Characteristic brain MRI findings and retinal changes have not been described with this chromosomal abnormality.

Two subjects (subjects 7 and 8) harbored the c.260C>T (p.Ser87Leu) variant. Both have muscular weakness, areflexia, and gait impairment; neurophysiologic studies confirmed a sensorimotor neuropathy in each individual. Subject 7 experienced two apparently unprovoked regressions in symptoms, first with worsening hypotonia, weakness, and loss of babbling at age 9 months and again with worsening truncal hypotonia at 33 months; each time was followed by a plateau and slow improvement. He has developmental delay and severe intellectual disability, and his head circumference is normal (Z score = -0.40), but a brain MRI shows brain stem and basal ganglia abnormalities that did not change on repeat imaging at 10 months and 34 months. Subject 8 has decreased muscle bulk and mildly elevated serum creatine kinase activity; exome sequencing also showed a *de novo*, likely pathogenic variant in *MYH7* (MIM: 160760) associated with autosomal-dominant myopathies and cardiomyopathy that could be responsible for those features and contribute to the weakness and areflexia but would not explain the growth abnormalities or intellectual disability. The c.260C>T (p.Ser87Leu) variant in *MORC2* has been reported in several children considered to have infantile onset CMT disease type 2Z.^{4,14,16} Review of the published affected individuals for which clinical information was available revealed that the variant was confirmed *de novo* in 3/4 individuals, and at least one of them was reported

to be microcephalic and one was reported to be dysmorphic (Table 1).⁴

The c.394C>T (p.Arg132Cys) variant was identified in four subjects (subjects 10–13). Subjects 10–12 have gross motor delay; all have mild intellectual disability. All of them have microcephaly and brain abnormalities on MRIs; periaqueductal gray matter and basal ganglia lesions were reported in one (subject 10), and one individual had findings suggestive of periventricular gliosis that were not present on repeat imaging at age 9 years (subject 12). Three individuals had NCSs: one was normal at age 4 years, whereas the other two showed a sensorimotor neuropathy (ages 4 and 15 years). Subject 12 also harbored a *de novo* missense variant in *TCF12* (MIM: 600480), a gene for which loss-of-function variants are associated with Craniosynostosis 3 (MIM: 615314) and generally normal intelligence, which was not considered a good fit for this child. The c.394C>T (p.Arg132Cys) variant has been described in one individual with developmental delay for whom no additional information was available,¹⁶ and substitution of the Arg132 residue for a different amino acid (p.Arg132Leu) has also been reported in an individual who presented in childhood with classic CMT disease type 2Z with progressive weakness and hearing loss.¹⁴

We identified the previously unreported c.1164C>G (p.Ser388Arg) variant in two individuals (subjects 15 and 16). Both have developmental delay, intellectual disability, and microcephaly. Subject 15 has mild retinal pigmentary changes, less prominent neuromuscular symptoms, a normal NCS at age 9 years, and the brain MRI shows delayed myelination with mild cerebellar volume loss. Subject 16 has severe, asymmetric spasticity and lower extremity hyperreflexia as well as pes cavus and hammertoes, which were not present on the exam at age 12 years but were prominent at age 15 years. She has not had NCSs; the brain MRI shows cerebellar atrophy. Subject 16 also has a history of seizures and Wolff-Parkinson-White syndrome (MIM: 194200).

The c.1181A>G (p.Tyr394Cys) variant identified in two of our subjects (subjects 17 and 18) has been reported in an adult Japanese individual with a clinical diagnosis of CMT with onset at 6 years of age.⁵ No cognitive impairment was noted in the published individual, and no segregation data was provided. Our patients, in addition to polyneuropathy symptoms, have developmental delay and brain abnormalities. Subject 17 has facial dysmorphism, short stature (Z

Table 2. Summary of Clinical Characteristics of Individuals with Variants in the ATPase Module of MORC2

Clinical Characteristics	This Paper		All Individuals	
	Total	%	Total	%
Short stature ^a	18/20	90	18/20	90
Microcephaly ^a	15/20	75	16/21	76
Developmental Delay				
Motor delay	19/20	95	22/23	96
Intellectual disability	18/20	90	18/22	82
Facial dysmorphism	16/20	80	17/21	81
Hearing Loss	11/19	58	12/20	60
Pigmentary retinopathy	5/6	83	5/6	83
Neuromuscular				
Hypotonia	11/16	69	14/19	74
Hyporeflexia/areflexia	9/18	50	13/22	59
Hyperreflexia	6/18	33	6/22	27
Weakness	8/15	53	12/19	63
High arches	7/16	44	7/16	44
Gait abnormalities	15/16	94	18/19	95
EMG/NCS abnormalities	6/10	60	11/15	73
Brain MRI				
Any abnormality	12/18	66	12/21	57
Leigh-like lesions ^b	5/18	28	5/21	24
White matter abnormalities	9/18	50	9/21	43

Abbreviations are as follows: EMG, electromyogram; NCS, nerve conduction study; MRI, magnetic resonance imaging
^a2 standard deviations (SDs) below the mean for age by CDC standards.
^bBased on ClinGen panel Leigh syndrome curation guidelines.

score = -2.10), and microcephaly (Z score = -2.10), similar to the other individuals described in this report.

We also identified a mother-daughter pair (subjects 19 and 20) harboring a novel missense variant in *MORC2*, c.1237G>T (p.Val413Phe). The maternal grandparents were not tested. Subject 19 presented at age 5 years with ataxia and action tremor, growth retardation, and developmental delay. An MRI of the brain was normal at 3 years old. Her mother, subject 20, has short stature, microcephaly, global developmental delay, mild intellectual disability, and adult onset hearing loss. Both were growth hormone deficient; subject 19 had a normal bone age and skeletal survey. Exome sequencing also showed a shared variant of uncertain significance in *ASXL3* (MIM: 615115), a gene associated with autosomal-dominant Bainbridge-Ropers syndrome (MIM: 615485), consisting of severe-to-profound developmental delay with growth retardation and facial dysmorphism; this was not considered to be a good phenotypic fit for this family. In addition, pathogenic variants in *ASXL3* are usually loss-of-function as opposed to missense such as in this instance, further arguing against pathogenicity.

Chromatin remodeling by *MORC2* has recently been shown to play a critical role in the process of epigenetic silencing mediated by the Human Silencing Hub (HUSH) complex.^{2,15} Thus, we performed a genetic complementation experiment to assess the functional consequences of these *MORC2* variants in HUSH-mediated silencing (Figure 3A). *MORC2*-deficient cells harboring a HUSH-sensitive GFP reporter were transduced with lentiviral vectors encoding either wild-type *MORC2* or the p.Thr24Ile, p.Glu27Lys, p.Ser87Leu, p.Arg132Cys, p.Arg266Ser, and p.Val413Phe mutants, plus two additional variants previously associated with *MORC2*-neuropathies (p.Glu236Gly and p.Arg252Trp), and reporter repression was measured over 12 days by flow cytometry (Figure 3A and Figure S2). We found that the p.Thr24Ile, p.Glu27Lys, p.Ser87Leu, p.Arg132Cys, p.Arg266Ser, and p.Val413Phe mutants all hyperactivated HUSH-mediated silencing (Figure 3B); p.Arg132Cys and p.Glu27Lys exhibited the most extreme phenotypes (Figure 3C). These findings mirror the effects observed with the p.Glu236Gly and p.Arg252Trp mutants previously associated with *MORC2*-neuropathies (Figure 3B)² and support the notion that these variants in *MORC2* are pathogenic. The p.Ala88Val, p.Ser388Arg, and p.Tyr394Cys variants were identified after the functional assays were completed.

Phenotypic heterogeneity, the concept that variation in the same gene can cause more than one disorder, is not uncommon in the era of exome and genome sequencing. In recent years, several genes associated with neuropathies have also been found to be responsible for more severe neurodevelopmental disorders, sometimes representing the extremes of a spectrum¹⁷ and, in other cases, two completely different syndromes.¹⁸ Constitutional variants in *MORC2* were first reported in 2016 in association with a progressive axonal and sensory neuropathy frequently presenting in the first decade of life.⁸ There have been a few subsequent reports of more severely affected individuals, although with inconsistent features. Indeed, although some of the subjects reported here have characteristics of *MORC2*-related neuropathies, those features were considered part of a broader presentation, and hence, the subjects were referred for clinical exome sequencing. For this study, we used a genotype-first approach and selected individuals harboring *de novo* variants in *MORC2* in a large dataset. Analysis of their detailed phenotypic information then allowed us to define a new syndrome characterized by global developmental and growth delay with variable facial dysmorphism. Leigh syndrome (or subacute necrotizing encephalomyelopathy, MIM: 256000), characterized by developmental delay and/or regression, movement disorder, neuropathy, and bilateral symmetric abnormalities in the basal ganglia, brainstem, and/or cerebellum on brain MRIs, was considered in several individuals. The presence of hearing loss and pigmentary retinopathy further suggested the diagnosis of a mitochondrial disorder.




Figure 2. Facial Characteristics of Individuals Harboring *MORC2* Variants

MORC2 is involved in epigenetic silencing and expressed in neural tissues predominantly at early stages of development,^{2,19} providing a potential substrate for neurodevelopmental disability. *MORC2* has also been shown to bind ATP citrate lyase, the enzyme that catalyzes the formation of cytosolic acetyl-CoA, a critical building block for multiple biosynthetic pathways,²⁰ providing a potential mechanism for the presence of mitochondrial features in these individuals. Consistent with previous reports, all variants identified in our cohort cluster in the gyrase, Hsp90, histidine kinase, MutL (GHKL)-type ATP binding domain and the transducer-like domain, which together form the ATPase module of *MORC2*. Similar to other GHKL-type ATPases, ATP binding and hydrolysis by *MORC2* functions as a conformational switch.^{15,21} Upon ATP binding, the ATPase module dimerizes and becomes active, allowing for HUSH complex activity leading to transcriptional repression.¹⁵ Assessing the functional effects of different *MORC2* variants, Douse et al. showed that, in the setting of normal ATP-dependent dimerization, neuropathic mutations resulting in weaker ATPase activity hyperactivated HUSH-mediated silencing.¹⁵ All six of the *MORC2* variants that we tested hyperactivated silencing by the HUSH complex in cellular assays, and thus, it is likely that these variants also exert their pathogenic effects by diminishing the ATPase activity of *MORC2*.

The presence of several recurrent variants allowed us to make some initial genotype-phenotype correlations. Most features appear consistent between individuals sharing the same variants, although the degree of severity varies. In the case of the c.1237G>T (p.Val413Phe) variant, we were able to evaluate the expression of the disorder across two generations; although information was incomplete for the mother, there were enough common

findings to consider them similarly affected. All individuals harboring the c.260C>T (p.Ser87Leu) and the c.1181A>G (p.Tyr394Cys) variants have significant neuropathy symptoms, which can explain why they were identified in previous studies.^{4,5,14} In the case of the c.260C>T (p.Ser87Leu) variant, all published subjects were young and presented with gross motor delay, and at least one of them was also microcephalic.⁴ One subject heterozygous for the c.1181A>G (p.Tyr394Cys) variant in our cohort has mild facial features, hearing loss, and intellectual disability, and the other has normal growth parameters and no facial dysmorphism; however, they both presented with developmental delay and white matter abnormalities on brain MRIs, neither of which were reported in the published individual.⁵ On the other hand, individuals harboring the c.79G>A (p.Glu27Lys) and c.394C>T (p.Arg132Cys) variants are more likely to present with developmental delay, growth retardation, brain abnormalities, and inconsistent neuromuscular complaints. Indeed, among our nine patients with these variants, NCSs were reported for two subjects (ages 4 and 26 years) and were not performed in five others, suggesting that neuropathy was not a predominant concern, at least at that time. The lack of neuropathy in these patients might also explain why the c.79G>A (p.Glu27Lys) and c.394C>T (p.Arg132Cys) variants have not been identified in previous studies of *MORC2* mutations among cohorts of CMT-affected patients but were found in large cohorts of individuals with neurodevelopmental disorders.¹⁶ Furthermore, our functional assays demonstrate that the c.79G>A (p.Glu27Lys) and c.394C>T (p.Arg132Cys) variants exert the most strongly hyperactivating effects on HUSH-mediated silencing (Figure 3B), suggesting that the degree of HUSH hyperactivation in the cellular assays

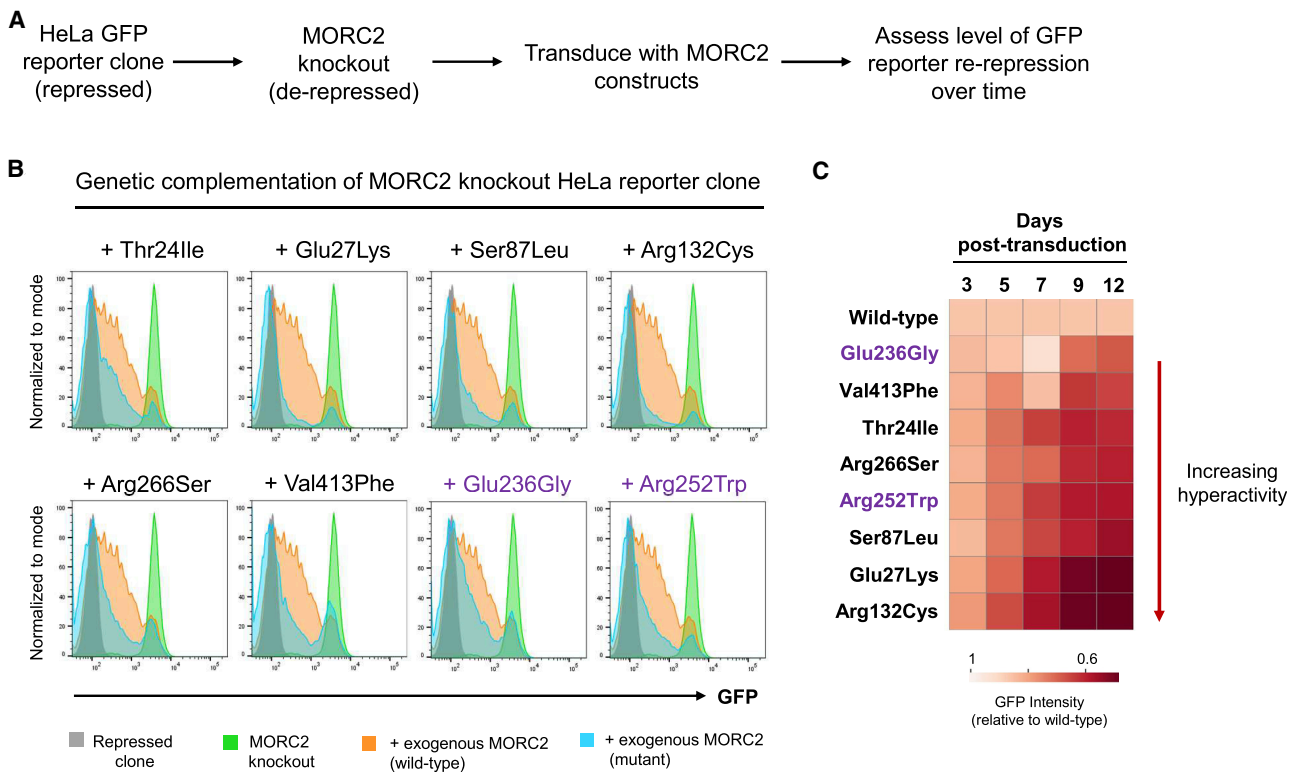


Figure 3. MORC2 Mutations Hyperactivate Epigenetic Silencing by the HUSH Complex

(A) Schematic representation of the complementation experiment in which the ability of MORC2 variants to restore repression of a HUSH-sensitive GFP reporter in MORC2 knockout cells was assessed.

(B and C) MORC2 variants hyperactivate HUSH repression. At day 12 (B), all MORC2 variants exhibit enhanced silencing of the GFP reporter construct (blue histograms) compared to wild-type MORC2 (orange histograms). The full results for the time-course are, which reveal that the c.79G > A (p.Glu27Lys) and c.394C > T (p.Arg132Cys) variants are the most hyperactivating, are shown in (C). The p.Glu236Gly and p.Arg252Trp variants (shown in purple) previously associated with CMT2Z were included as a reference.

might reflect, at least in part, the severity of the central nervous system phenotype.

Although more work is clearly necessary to delineate the specific mechanisms by which mutations in *MORC2* result in the types of multi-organ system involvement described here, we have shown that the *MORC2*-associated neurodevelopmental disorder is characterized by global developmental delay, short stature, microcephaly, and variable dysmorphic facies, with or without neuropathy. The striking presence of features of Leigh-like syndrome further broadens the spectrum of phenotypes associated with *MORC2* variants.

Data and Code Availability

Variant information for all variants described in this manuscript is publicly available through Clinvar under the following accession numbers: p.Thr24Ile (SCV001134972.1), p.Glu27Lys (SCV001134974.1), p.Ser87Leu (SCV000618293.2), p.Ala88Val (SCV000999384.1), p.Arg132Cys (SCV000571490.3), p.Arg266Ser (SCV000573276.4), p.Ser388Arg (SCV001134979.1), p.Tyr394Cys (SCV000589765.2), p.Val413Phe (SCV001134978.1).

Supplemental Data

Supplemental Data can be found online at <https://doi.org/10.1016/j.ajhg.2020.06.013>.

Consortia

The members of the Undiagnosed Diseases Network are Maria T. Acosta, Margaret Adam, David R. Adams, Pankaj B. Agrawal, Mercedes E. Alejandro, Justin Alvey, Laura Amendola, Ashley Andrews, Euan A. Ashley, Mahshid S. Azamian, Carlos A. Bacino, Guney Bademci, Eva Baker, Ashok Balasubramanyam, Dustin Baldrige, Jim Bale, Michael Bamshad, Deborah Barbouth, Gabriel F. Batzli, Pinar Bayrak-Toydemir, Anita Beck, Alan H. Beggs, Gill Bejerano, Jimmy Bennet, Beverly Berg-Rood, Raphael Bernier, Jonathan A. Bernstein, Gerard T. Berry, Anna Bican, Stephanie Bivona, Elizabeth Blue, John Bohnsack, Carsten Bonnenmann, Devon Bonner, Lorenzo Botto, Brenna Boyd, Lauren C. Briere, Elly Brokamp, Gabrielle Brown, Elizabeth A. Burke, Lindsay C. Burrage, Manish J. Butte, Peter Byers, William E. Byrd, John Carey, Olveen Carrasquillo, Ta Chen Peter Chang, Sirisak Chanprasert, Hsiao-Tuan Chao, Gary D. Clark, Terra R. Coakley, Laurel A. Cobban, Joy D. Cogan, F. Sessions Cole, Heather A. Colley, Cynthia M. Cooper, Heidi Cope, William J. Craigen, Andrew B. Crouse, Michael Cunningham, Precilla D'Souza, Hongzheng Dai, Surendra Dasari, Mariska Davids, Jyoti G. Dayal, Esteban C. Dell'Angelica, Shweta U. Dhar, Katrina Dipple, Daniel Doherty, Naghme Dorrani, Emilie

D. Douine, David D. Draper, Laura Duncan, Dawn Earl, David J. Eckstein, Lisa T. Emrick, Christine M. Eng, Cecilia Esteves, Tyra Estwick, Liliana Fernandez, Carlos Ferreira, Elizabeth L. Fieg, Paul G. Fisher, Brent L. Fogel, Irman Forghani, Laure Fresard, William A. Gahl, Ian Glass, Rena A. Godfrey, Katie Golden-Grant, Allica M. Goldman, David B. Goldstein, Alana Grajewski, Catherine A. Groden, Andrea L. Gropman, Irma Gutierrez, Sihoun Hahn, Rizwan Hamid, Neil A. Hanchard, Nichole Hayes, Frances High, Anne Hing, Fuki M. Hisama, Ingrid A. Holm, Jason Hom, Martha Horike-Pyne, Alden Huang, Yong Huang, Rosario Isasi, Fariha Jamal, Gail P. Jarvik, Jeffrey Jarvik, Suman Jayadev, Jean M. Johnston, Lefkothia Karaviti, Emily G. Kelley, Dana Kiley, Isaac S. Kohane, Jennifer N. Kohler, Deborah Krakow, Donna M. Krasnewich, Elijah Kravets, Susan Korrick, Mary Koziura, Joel B. Krier, Seema R. Lalani, Byron Lam, Christina Lam, Brendan C. Lanpher, Ian R. Lanza, C. Christopher Lau, Kimberly LeBlanc, Brendan H. Lee, Hane Lee, Roy Levitt, Richard A. Lewis, Sharyn A. Lincoln, Pengfei Liu, Xue Zhong Liu, Nicola Longo, Sandra K. Loo, Joseph Loscalzo, Richard L. Maas, Ellen F. Macnamara, Calum A. MacRae, Valerie V. Maduro, Marta M. Majcherska, May Christine V. Malicdan, Laura A. Mamonas, Teri A. Manolio, Rong Mao, Kenneth Maravilla, Thomas C. Markello, Ronit Marom, Gabor Marth, Beth A. Martin, Martin G. Martin, Julian A. Martínez-Agosto, Shruti Marwaha, Jacob McCauley, Allyn McConkie-Rosell, Colleen E. McCormack, Alexa T. McCray, Elisabeth McGee, Heather Mefford, J. Lawrence Merritt, Matthew Might, Ghayda Mirzaa, Eva Morava-Kozicz, Paolo M. Moretti, Marie Morimoto, John J. Mulvihill, David R. Murdock, Mariko Nakano-Okuno, Avi Nath, Stan F. Nelson, John H. Newman, Sarah K. Nicholas, Deborah Nickerson, Donna Novacic, Devin Oglesbee, James P. Orengo, Laura Pace, Stephen Pak, J. Carl Palleis, Christina G.S. Palmer, Jeanette C. Papp, Neil H. Parker, John A. Phillips III, Jennifer E. Posey, Lorraine Potocki, Barbara N. Pusey, Aaron Quinlan, Wendy Raskind, Archana N. Raja, Genecee Renteria, Chloe M. Reuter, Lynette Rives, Amy K. Robertson, Lance H. Rodan, Jill A. Rosenfeld, Natalie Rosenwasser, Robb K. Rowley, Maura Ruzhnikov, Ralph Sacco, Jacinda B. Sampson, Susan L. Samson, Mario Saporta, C. Ron Scott, Judy Schaechter, Timothy Schedl, Kelly Schoch, Daryl A. Scott, Lisa Shakachite, Prashant Sharma, Vandana Shashi, Jimann Shin, Rebecca Signer, Catherine H. Sillari, Edwin K. Silverman, Janet S. Sinsheimer, Kathy Sisco, Edward C. Smith, Kevin S. Smith, Lilianna Solnica-Krezel, Rebecca C. Spillmann, Joan M. Stoler, Nicholas Stong, Jennifer A. Sullivan, Angela Sun, Shirley Sutton, David A. Sweetser, Virginia Sybert, Holly K. Tabor, Cecelia P. Tamburro, Queenie K.-G. Tan, Mustafa Tekin, Fred Telischi, Willa Thorson, Cynthia J. Tifft, Camilo Toro, Alyssa A. Tran, Brianna M. Tucker, Tiina K. Urv, Matt Velinder, Dave Viskochil, Tiphonie P. Vogel, Colleen E. Wahl, Stephanie Wallace, Nicole M. Walley, Chris A. Walsh, Melissa Walker, Jennifer Wambach, Jijun Wan, Lee-kai Wang, Michael F. Wangler, Patricia A. Ward, Daniel Wegner, Mark Wener, Tara Wenger, Katherine Wesseling Perry, Monte Westerfield, Matthew T. Wheeler, Jordan Whitlock, Lynne A. Wolfe, Jeremy D. Woods, Shinya Yamamoto, John Yang, Guoyun Yu, Diane B. Zastrow, Chunli Zhao, and Stephan Zuchner.

Acknowledgments

I.A.T. is a postdoctoral fellow of the Damon Runyon Cancer Research Foundation. Research reported in this manuscript was supported by the NIH Common Fund through the Office of Strategic Coordination, Office of the NIH Director under award number U01HG007690. The content is solely the responsibility of the

authors and does not necessarily represent the official views of the National Institutes of Health.

Declaration of Interests

M.J.G.S., C.F., E.T., W.W., and J.J. are employees of GeneDx, Inc. J.S.C. is a consultant to Invitae. A.F. is a consultant to Calico Labs and a paid Data and Safety Monitoring Board (DSMB) member of Bluebirdbio, Inc. and Stealth Therapeutics. M.K.K. is a paid member of the DSMB for Modis and is on the Speakers Bureau for Novartis.

Received: February 13, 2020

Accepted: June 17, 2020

Published: July 20, 2020

Web Resources

Exome Variant Server, NHLBI GO Exome Sequencing Project (ESP), <https://evs.gs.washington.edu/EVS/>
GeneDx ClinVar, <https://www.ncbi.nlm.nih.gov/clinvar/>
gnomAD, <https://gnomad.broadinstitute.org/>
Greater Middle East Variome, <http://igm.ucsd.edu/gme/OMIM>, <https://www.omim.org>

References

1. Moissiard, G., Cokus, S.J., Cary, J., Feng, S., Billi, A.C., Stroud, H., Husmann, D., Zhan, Y., Lajoie, B.R., McCord, R.P., et al. (2012). MORC family ATPases required for heterochromatin condensation and gene silencing. *Science* 336, 1448–1451.
2. Tchasovnikarova, I.A., Timms, R.T., Douse, C.H., Roberts, R.C., Dougan, G., Kingston, R.E., Modis, Y., and Lehner, P.J. (2017). Hyperactivation of HUSH complex function by Charcot-Marie-Tooth disease mutation in MORC2. *Nat. Genet.* 49, 1035–1044.
3. Li, D.Q., Nair, S.S., Ohshiro, K., Kumar, A., Nair, V.S., Pakala, S.B., Reddy, S.D., Gajula, R.P., Eswaran, J., Aravind, L., and Kumar, R. (2012). MORC2 signaling integrates phosphorylation-dependent, ATPase-coupled chromatin remodeling during the DNA damage response. *Cell Rep.* 2, 1657–1669.
4. Sevilla, T., Lupo, V., Martínez-Rubio, D., Sancho, P., Sivera, R., Chumillas, M.J., García-Romero, M., Pascual-Pascual, S.I., Muelas, N., Dopazo, J., et al. (2016). Mutations in the MORC2 gene cause axonal Charcot-Marie-Tooth disease. *Brain* 139, 62–72.
5. Ando, M., Okamoto, Y., Yoshimura, A., Yuan, J.H., Hiramatsu, Y., Higuchi, Y., Hashiguchi, A., Mitsui, J., Ishiura, H., Fukumura, S., et al. (2017). Clinical and mutational spectrum of Charcot-Marie-Tooth disease type 2Z caused by MORC2 variants in Japan. *Eur. J. Neurol.* 24, 1274–1282.
6. Laššuthová, P., Šafka Brožková, D., Krůtová, M., Mazanec, R., Züchner, S., Gonzalez, M.A., and Seeman, P. (2016). Severe axonal Charcot-Marie-Tooth disease with proximal weakness caused by de novo mutation in the MORC2 gene. *Brain* 139, e26.
7. Semplicini, C., Ollagnon-Roman, E., Leonard-Louis, S., Piguët-Lacroix, G., Silvestre, M., Latour, P., and Stojkovic, T. (2017). High intra-familial clinical variability in MORC2 mutated CMT2 patients. *Brain* 140, e21.
8. Albulym, O.M., Kennerson, M.L., Harms, M.B., Drew, A.P., Siddell, A.H., Auer-Grumbach, M., Pestronk, A., Connolly, A., Baloh, R.H., Zuchner, S., et al. (2016). MORC2 mutations cause

- axonal Charcot-Marie-Tooth disease with pyramidal signs. *Ann. Neurol.* 79, 419–427.
9. Zanni, G., Nardella, M., Barresi, S., Bellacchio, E., Niceta, M., Ciolfi, A., Pro, S., D'Arrigo, S., Tartaglia, M., and Bertini, E. (2017). De novo p.T362R mutation in MORC2 causes early onset cerebellar ataxia, axonal polyneuropathy and nocturnal hypoventilation. *Brain* 140, e34.
 10. Schottmann, G., Wagner, C., Seifert, F., Stenzel, W., and Schuelke, M. (2016). MORC2 mutation causes severe spinal muscular atrophy-phenotype, cerebellar atrophy, and diaphragmatic paralysis. *Brain* 139, e70.
 11. Retterer, K., Juusola, J., Cho, M.T., Vitazka, P., Millan, F., Gibellini, F., Vertino-Bell, A., Smaoui, N., Neidich, J., Monaghan, K.G., et al. (2016). Clinical application of whole-exome sequencing across clinical indications. *Genet. Med.* 18, 696–704.
 12. Lek, M., Karczewski, K.J., Minikel, E.V., Samocha, K.E., Banks, E., Fennell, T., O'Donnell-Luria, A.H., Ware, J.S., Hill, A.J., Cummings, B.B., et al.; Exome Aggregation Consortium (2016). Analysis of protein-coding genetic variation in 60,706 humans. *Nature* 536, 285–291.
 13. Richards, S., Aziz, N., Bale, S., Bick, D., Das, S., Gastier-Foster, J., Grody, W.W., Hegde, M., Lyon, E., Spector, E., et al.; ACMG Laboratory Quality Assurance Committee (2015). Standards and guidelines for the interpretation of sequence variants: a joint consensus recommendation of the American College of Medical Genetics and Genomics and the Association for Molecular Pathology. *Genet. Med.* 17, 405–424.
 14. Hyun, Y.S., Hong, Y.B., Choi, B.O., and Chung, K.W. (2016). Clinico-genetics in Korean Charcot-Marie-Tooth disease type 2Z with MORC2 mutations. *Brain* 139, e40.
 15. Douse, C.H., Bloor, S., Liu, Y., Shamin, M., Tchasovnikarova, I.A., Timms, R.T., Lehner, P.J., and Modis, Y. (2018). Neuro-pathic MORC2 mutations perturb GHKL ATPase dimerization dynamics and epigenetic silencing by multiple structural mechanisms. *Nat. Commun.* 9, 651.
 16. Deciphering Developmental Disorders Study (2017). Prevalence and architecture of de novo mutations in developmental disorders. *Nature* 542, 433–438.
 17. Shy, M.E. (2006). Peripheral neuropathies caused by mutations in the myelin protein zero. *J. Neurol. Sci.* 242, 55–66.
 18. Verma, P., Kumar, A., and Goswami, C. (2010). TRPV4-mediated channelopathies. *Channels (Austin)* 4, 319–328.
 19. Sancho, P., Bartesaghi, L., Miossec, O., García-García, F., Ramírez-Jiménez, L., Siddell, A., Åkesson, E., Hedlund, E., Laššuthová, P., Pascual-Pascual, S.I., et al. (2019). Characterization of molecular mechanisms underlying the axonal Charcot-Marie-Tooth neuropathy caused by MORC2 mutations. *Hum. Mol. Genet.* 28, 1629–1644.
 20. Sánchez-Solana, B., Li, D.Q., and Kumar, R. (2014). Cytosolic functions of MORC2 in lipogenesis and adipogenesis. *Biochim. Biophys. Acta* 1843, 316–326.
 21. Pearl, L.H., and Prodromou, C. (2006). Structure and mechanism of the Hsp90 molecular chaperone machinery. *Annu. Rev. Biochem.* 75, 271–294.