

UC San Diego

UC San Diego Previously Published Works

Title

What Is the Role of Transcarotid Artery Revascularization?

Permalink

<https://escholarship.org/uc/item/6n34r067>

Journal

Advances in Surgery, 57(1)

ISSN

0065-3411

Authors

Zarrintan, Sina

Malas, Mahmoud B

Publication Date

2023-09-01

DOI

10.1016/j.yasu.2023.04.010

Peer reviewed

What Is the Role of Transcarotid Artery Revascularization?



Sina Zarrintan, MD, MS, MPH^{a,b,c},
Mahmoud B. Malas, MD, MHS, FACS^{a,b,c,*}

^aDepartment of Surgery, Division of Vascular and Endovascular Surgery, UC San Diego, San Diego, CA, USA; ^bCenter for Learning and Excellence in Vascular & Endovascular Research (CLEVER), UC San Diego, San Diego, CA, USA; ^cAltman Center for Clinical and Translational Research, 9452 Medical Center Drive - LL2W 502A, La Jolla, CA 92037, USA

Keywords

- Ischemic stroke • Carotid artery stenosis • Carotid endarterectomy
- Carotid artery stenting

Key points

- Carotid revascularization is indicated in symptomatic patients with $\geq 50\%$ and in asymptomatic patients with $\geq 70\%$ stenosis.
- CEA is the gold-standard carotid artery revascularization method in both symptomatic and asymptomatic patients.
- TCAR is preferred to TFCAS in patients with symptomatic carotid artery stenosis who are deemed to be high-risk for surgery.
- The decision to perform carotid revascularization in patients with asymptomatic stenosis who are deemed high-risk for surgery should be individualized based on multiple factors.

INTRODUCTION

Cerebrovascular accident (CVA) is generally defined as an acute neurologic deficit resulting from compromised intracranial blood supply. The CVA is called stroke if it lasts for more than 24 hours. On the other hand, transient ischemic attack (TIA) is defined as an acute onset neurologic deficit with symptoms lasting less than 24 hours [1]. Stroke is among the major causes of disability and mortality in the United States and worldwide. The majority of

*Corresponding author. Altman Center for Clinical and Translational Research, 9452 Medical Center Drive - LL2W 502A, La Jolla, CA 92037. *E-mail address:* mmalas@ucsd.edu

strokes are ischemic [2]. Ischemic strokes are classified into further categories including cardioembolic, large vessel disease, small vessel disease, and unusual or undetermined etiologies. One of the major preventable causes of primary and recurrent ischemic strokes is extracranial carotid artery disease (ECAD) resulting from atherosclerotic lesions of cervical carotid artery [3,4]. Thus, carotid revascularization with carotid endarterectomy (CEA) or carotid artery stenting (CAS) plays a key role in the prevention of stroke.

Patients with a prior cerebrovascular episode are at significantly increased risk of recurrent events and the risk of recurrent stroke is associated with the degree of carotid stenosis. Patients with asymptomatic atherosclerotic carotid plaque have also a substantial risk of cerebrovascular events but the association between the degree of stenosis and subsequent stroke is less clear in asymptomatic lesions [5–7]. The main purpose of carotid revascularization is the prevention of recurrent and new neurologic events in patients with symptomatic and asymptomatic carotid artery stenosis, respectively [8].

INDICATIONS OF CAROTID ARTERY REVASCLARIZATION

Management of extracranial carotid artery disease

All patients with cerebrovascular diseases should first undergo risk factor modification by best medical therapy (BMT). BMT includes antiplatelet therapy, lipid profile management (mostly statins), antihypertensive therapy, and other risk factor managements (eg, smoking cessation and glycemic control) [9–11]. Carotid revascularization (CEA or CAS) is considered in certain patients with ECAD and the indications are determined based on the symptomatic status, the degree of stenosis and a number of other factors (eg, high-risk morphology of the carotid plaque) [12–15].

After considering a patient with ECAD for carotid revascularization, the next important decision is the choice between CEA and CAS. CAS has been traditionally performed through transfemoral access (TFCAS) [16]. However, CAS through transcarotid access has been introduced in recent years. This novel technique is called transcarotid artery revascularization (TCAR) [17]. The technical details and outcomes following TCAR in comparison with CEA and TFCAS are the main scope of this article.

Societal guidelines

American Heart Association (AHA) [9,10,18] and Society for Vascular Surgery (SVS) [11,19,20] have published guidelines describing the indications of CEA and CAS in patients with symptomatic and asymptomatic carotid stenosis.

Symptomatic carotid artery stenosis

Symptomatic carotid stenosis predisposes the patients to the substantial risk of recurrent ipsilateral neurologic event. The severity of stenosis is also associated with increased risk of ipsilateral stroke if appropriate revascularization is not considered. Multiple landmark clinical trials have confirmed the benefit of carotid revascularization, namely CEA, over medical therapy alone for symptomatic carotid stenosis [21–23]. CEA is currently recommended for symptomatic

patients with greater than 50% stenosis. CAS is a less invasive alternative treatment when high-risk anatomic or medical factors prohibit a safe CEA (Table 1) [9–11,19,20,24].

Asymptomatic carotid artery stenosis

Carotid revascularization for asymptomatic disease is more controversial. Evidence from several clinical trials support the performance of CEA in asymptomatic patients with high-grade stenosis to prevent de novo neurologic events; however, it is essential to consider that when these studies were performed, optimal BMT consisted primarily of aspirin therapy [25–27]. According to most recent recommendations from SVS, CEA is recommended over BMT alone in asymptomatic patients with greater than 70% stenosis with low surgical risk. CAS might be an alternative to CEA in asymptomatic patients with severe carotid stenosis who are at high risk for CEA based on anatomic or medical risk factors, provided that the procedure-related risk is less than 3%. It has been also recommended that both CEA and CAS be performed in asymptomatic patients with greater than 5-year life expectancy and only in centers where the procedure-related risks are less than 3% (see Table 1) [9–11,19,20,24].

CAROTID ENDARTERECTOMY VERSUS CAROTID ARTERY STENTING: THE ROLE OF TRANSCAROTID ARTERY REVASCULARIZATION

Carotid endarterectomy is considered the standard method of carotid revascularization and is favored over TFCAS in most patients with symptomatic or asymptomatic carotid stenosis. Several multi-institutional randomized clinical trials in North America and Europe have revealed that TFCAS is associated with unfavorable outcomes mostly due to higher risks of procedural stroke and death compared to CEA. However, a number of trials have shown that CEA and TFCAS have comparable results in long-term follow-up [28–31]. There are certain medical and anatomic conditions that are considered high-risk factors for CEA and TFCAS (Tables 2 and 3). Generally, in patients with one of the high-risk criteria for CEA, CAS is considered [32]. The most important considerations when selecting a patient who might be appropriate for CEA, TFCAS or TCAR are as follows.

Age

Age is one of the most important factors in deciding the best method of carotid revascularization. According to recommendations of AHA and SVS, CEA may be associated with more favorable outcomes compared with TFCAS for patients older than 70 years, particularly when anatomic factors limit the performance of a safe minimally-invasive procedure [9,10,33,34]. In older patients, TCAR is an appropriate alternative technique particularly when the patients are considered high-risk for CEA [35]. Severe atherosclerosis including the atherosclerotic plaques in the aortic arch is associated with advanced age. This results in higher stroke risk with TFCAS in the elderly compared to

Table 1

Indications of CEA and CAS in symptomatic and asymptomatic carotid stenosis based on societal guidelines

Society	American Heart Association [9,10,18]	Evidence	Society for Vascular Surgery [11,19,20]	Evidence	
Symptomatic	CEA	CEA is recommended for patients with severe stenosis (70% to 99%) if the perioperative morbidity and mortality risk is estimated to be <6%. CEA is recommended for patients with moderate stenosis (50% to 69%) depending on patient-specific factors, such as age, sex, and comorbidities, if the perioperative morbidity and mortality risk is estimated to be <6%.	Class I, LOE: A Class I, LOE: B	CEA is preferred over trans-femoral CAS in low/standard risk patients with a >50% symptomatic carotid artery stenosis.	Grade 1, LOE: A
	CAS	CAS is indicated as an alternative to CEA for symptomatic patients at average or low risk of complications associated with endovascular intervention when stenosis is >70% by noninvasive imaging or >50% by catheter angiography, CTA or MRA and the anticipated rate of procedure-related stroke or mortality is <6%.	Class IIa, LOE: B	CAS is preferred over CEA in symptomatic patients with more than 50% stenosis and hostile neck, or lesions that extend proximal to the clavicle or distal to the C2 vertebral body.	Grade 2, LOE: B
	CAS	CAS is reasonable in patients with >70% stenosis when CEA is high risk due to anatomic or medical factors or in cases of radiation-induced stenosis or restenosis after CEA and the anticipated rate of procedure-related stroke or mortality is <6%.	Class IIa, LOE: B	CAS is also preferred over CEA in symptomatic patients with >50% stenosis and severe uncorrectable CAD, CHF, or COPD.	Grade 2, LOE: C

Asymptomatic	CEA	CEA is reasonable in asymptomatic patients who have >70% stenosis if the risk of perioperative stroke, MI, and death is low.	Class IIa, LOE: A	CEA is recommended in low surgical risk asymptomatic patients with a stenosis of >70% (documented by validated duplex ultrasound or CTA/angiography).	GRADE 1, LOE: B
				In asymptomatic patients with high risk for CEA, BMT is recommended. CEA can be considered in these patients only with evidence that perioperative morbidity and mortality is <3%.	GRADE 1, LOE: B
	CAS	Prophylactic CAS might be considered in highly selected patients (minimum 60% by angiography, 70% by validated Doppler ultrasound), but its effectiveness compared with BMT alone in this situation is not well established.	Class IIb, LOE: B	There are insufficient data to recommend CAS as primary therapy for neurologically asymptomatic patients with 70% to 99% diameter stenosis. In highly selected patients, CAS is equivalent to CEA in the hands of experienced interventionists provided that the combined stroke and death rate be <3%.	GRADE 2, LOE: B
				In asymptomatic patients with high risk for CEA, CAS should not be performed except as part of an ongoing clinical trial.	GRADE 1, LOE: B

Abbreviations: BMT, best medical therapy; CAD, coronary artery disease; CAS, carotid artery stenting; CEA, carotid endarterectomy; CHF, congestive heart failure; COPD, chronic obstructive pulmonary disease; CTA, computed tomography angiography; LOE, level of evidence; MRA, magnetic resonance angiography.

Table 2

High-risk anatomic factors for CEA and TFCAS

CEA	TFCAS
Prior neck surgery or irradiation	Stenosis >90%
Contralateral carotid occlusion	Ulcerated plaques
Contralateral recurrent laryngeal nerve palsy	Fresh thrombus
Restenosis after CEA	>10 mm target lesion length
High (Above C2) or low (Below clavicle) lesions	Circumferential severe calcification
Severe tandem lesions	Innominate artery or left CCA severe stenosis, occlusion, or tortuosity
Esophagostomy or Tracheostomy	Severe kinking of ICA
Bilateral stenosis requiring treatment	Eggshell or shaggy aorta
Cervical immobility	Type III aortic arch
	Suboptimal arterial access for sheath placement

Abbreviations: CCA, common carotid artery; CEA, carotid endarterectomy; ICA, internal carotid artery; TFCAS, transfemoral carotid artery stenting.

CEA. TCAR avoids the manipulation of the atherosclerotic aortic arch and have shown promising results in older patients [36]. In the largest Vascular Quality Initiative (VQI) study on the association of age and outcomes of carotid revascularization performed by our team, comparison of TCAR to CEA across different age groups showed no significant differences in outcomes, and no interaction was noted between treatment and age in predicting in-hospital stroke/death. Moreover, TCAR was associated with decreased odds of in-hospital stroke (OR = 0.28 [95% CI: 0.12–0.65]; $P < .01$), and in-

Table 3

High-risk medical factors for CEA and TFCAS

CEA	TFCAS
New York Heart Association class III/IV CHF	Symptomatic stenosis
LVEF < 30%	Procedures within 14 d of neurologic deficit
Abnormal stress test	Severe allergy to contrast media
Unstable angina or recent myocardial infarction	Advanced age (>70 y)
Need for CABG	Chronic Kidney Disease
Severe COPD	
Uncontrolled diabetes	
Uncontrolled hypertension	
Liver failure with elevated PT	
Chronic Kidney Disease	

Abbreviations: CABG, coronary artery bypass graft; CEA, carotid endarterectomy; CHF, congestive heart failure; COPD, chronic obstructive pulmonary disease; LVEF, left ventricular ejection fraction; PT, prothrombin time; TFCAS, transfemoral carotid artery stenting.

hospital stroke/death (OR = 0.35 [95% CI: 0.20–0.62]; $P < .001$) compared with TFCAS in patients ≥ 80 years [37].

Sex

The impact of sex on outcomes of CEA and CAS are conflicting with several studies demonstrating that females may benefit less from CEA and CAS compared to their male counterparts [38,39]. The most important concern in women is greater stroke rates following carotid revascularization due to higher restenosis rates [40]. A recent multi-institutional study from our team assessed the outcomes of CEA, TFCAS, and TCAR in two separate cohorts of males and females. Interestingly, stroke/death rate in 1-year for TCAR was similar to CEA in both sexes; however, TFCAS was associated with higher risks of 1-year stroke/death compared with CEA in both sexes [41].

Cardiac morbidity

Carotid endarterectomy is associated with a higher risk of cardiac complications compared to CAS and most surgeons favor CAS over CEA in a patient with advanced congestive heart failure, unstable angina and recent myocardial infarction (MI) [42–44]. Consequently, major cardiac risk factors are a relative indication for CAS in patients with symptomatic carotid artery disease. TCAR is the safer approach in these patients with lower risk of stroke and death compared to TFCAS [45].

Chronic kidney disease and dialysis

Among medical factors, severe chronic kidney disease (CKD) is considered a high-risk factor for all types of carotid revascularization [46]. The intravenous contrast dye during TFCAS and TCAR may precipitate renal failure and cause end-stage renal disease in patients with severe CKD [47]. Therefore, the decision to perform carotid revascularization and the type of revascularization should be individualized in patients with severe CKD. The risk of CEA in hemodialysis patients with asymptomatic and symptomatic carotid stenosis is also high. In asymptomatic patients undergoing hemodialysis, the risks of CEA may outweigh the benefits and should only be offered to highly selected patients [48]. CAS has been shown to be associated with relatively poor long-term survival and prohibitive operative stroke and death risk in hemodialysis patients [49]. However, in a recent national study from our team, in patients undergoing TCAR, no difference in the risk of in-hospital stroke or death between the dialysis and non-dialysis patients was found [50].

Technical pitfalls of transfemoral carotid artery stenting

Several technical drawbacks in TFCAS make it unsuitable in certain anatomic features and increase the procedure-related risks. TFCAS necessitates advancing a catheter through the atherosclerotic (shaggy aorta, eggshell aorta, and so forth) and often tortuous aortic arch to cannulate the innominate or left common carotid artery (CCA) [51]. Moreover, navigating the lesion before established neuroprotection and incomplete protection due to misaligned distal embolic protection device (EPD) make TFCAS more challenging (Fig. 1).

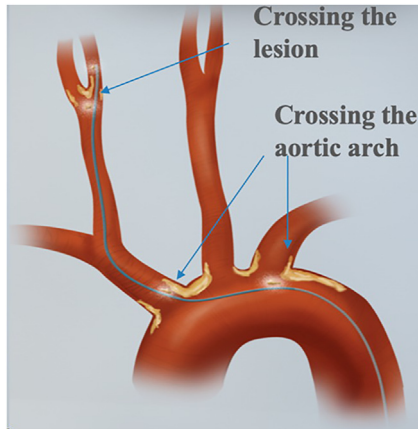


Fig. 1. Anatomic embolic risk factors of transfemoral carotid artery stenting. Both advancing a catheter through the aortic arch and navigating the lesion before the establishment of neuroprotection increase the risk of embolization. (Courtesy of Silk Road Medical, Inc.; Silk Road Medical, Inc. retains and reserves all rights, including copyrights.)

TCAR has the attractive advantage of avoiding the aortic arch and establishing neuroprotection prior to any manipulation of the carotid bulb [52,53]. Furthermore, the technique of neuroprotection with flow reversal in TCAR seems to provide more protection. Flow reversal provides a reverse flow in the ipsilateral carotid and therefore, prevents distal embolization of the detached atheroembolic particles [54]. Prospective studies have shown that TFCAS is associated with more new ischemic lesions on diffusion-weighted magnetic resonance imaging (MRI) in posttreatment scans compared to CEA [55]. We have shown that TCAR has better outcomes compared to transcervical CAS with distal EPD [54].

High-risk factors for transcarotid artery revascularization

Anatomic and medical factors considered high risk for TCAR have also been defined (Table 4). Certain anatomic conditions that relate to the carotid artery itself, for example, severe kinking of the internal carotid artery (ICA) or thick circumferential calcifications, are deemed to be high-risk anatomic factors for both TFCAS and TCAR. However, severe kinking of ICA at the planned distal EPD deployment location is a high-risk anatomic factor for TFCAS only because TCAR is performed by flow reversal without the need for distal EPD deployment. Significant tortuosity of the ICA at the stenting site would be considered high-risk for both TFCAS and TCAR [19,56,57].

In a study of the VQI database by our team, TCAR demonstrated favorable outcomes compared with TFCAS among patients with calcification greater than 50% of the carotid circumference. Compared with TFCAS in patients with heavy calcification, TCAR was associated with decreased odds of

Table 4

High-risk anatomic and medical factors in patients undergoing transcrotid artery revascularization

Anatomic	Medical
ICA diameter < 4 mm	Nickel allergy
Clavicle to carotid bifurcation distance < 5 cm	Bleeding disorder
CCA diameter < 6 mm	Contraindication to aspirin
Severe ICA tortuosity	Contraindication to P2Y12 inhibitors
Severe circumferential calcification	Contraindication to anticoagulation
Moderate to severe puncture site plaque at the proximal CCA	Severe CKD

Abbreviations: CCA, common carotid artery; CKD, chronic kidney disease; ICA, internal carotid artery.

stroke/death (OR = 0.50 [95% CI: 0.32–0.8]; $P = .004$), and stroke/death/MI (OR = 0.58 [95% CI: 0.39–0.87]; $P = .008$) [58]. In another study, we showed that carotid lesion length negatively impacts in-hospital outcomes for both TCAR and TFCAS. However, for lesions longer than 25 mm, TCAR appears to be safer than TFCAS with regard to the risk of in-hospital stroke (aOR = 0.7 [95% CI: 0.5–0.9]; $P = .009$) and death (aOR = 0.3 [95% CI: 0.2–0.4]; $P < .001$) [59].

In patients at high risk for CEA and unfavorable anatomical factors for both TFCAS and TCAR, the decision to perform carotid revascularization and the type of intervention should be individualized based on multiple patient factors. BMT might be the safest option in asymptomatic high-risk patients.

Contralateral carotid occlusion

Outcomes of CEA in patients with contralateral carotid occlusion (CCO) has been controversial [60,61]. In a recent analysis from the VQI database in patients by CCO by our team, TCAR was associated with a significant reduction in the odds of in-hospital stroke or death regardless of symptomatic status compared to TFCAS. There was no significant difference between TCAR and CEA in odds of in-hospital stroke or death. However, in asymptomatic patients, TCAR was associated with a 54% reduction in the odds of stroke (OR = 0.46 [95% CI = 0.21–0.97]; $P = .04$) but no significant differences were observed in symptomatic patients [62].

Hostile neck

History of prior neck irradiation, tracheostomy, esophagostomy, or other neck surgeries such as prior CEA or radical neck dissection can result in significant tissue scarring around the carotid artery territory and create a hostile neck. Hostile neck is considered a high-risk anatomic factor for CEA with a significant increase in the risk of cranial nerve injury (CNI) and wound complications. CAS is generally preferred in these patients [63,64]. In an analysis of VQI database by our team, TFCAS showed an almost four-fold increase in risk of in-

hospital death (aOR = 3.77 [95% CI: 1.49–9.53]; $P = .005$) and technical failure (aOR = 3.69 [95% CI: 1.82–7.47]; $P < .001$) among patients with hostile neck anatomy compared with TCAR [65].

Early carotid revascularization in symptomatic patients

Carotid revascularization, preferably CEA, is recommended 2 to 14 days following the onset of symptoms (early phase) in patients with recent stroke and carotid stenosis $\geq 50\%$ [19,66,67]. In an analysis of the VQI database in symptomatic patients undergoing TCAR, our team found that the best timing of intervention by TCAR is also between 2 and 14 days following the neurologic event [68]. In another analysis of the VQI database, we showed that the outcomes of TCAR are comparable to CEA in symptomatic patients undergoing carotid revascularization between 2 and 14 days following the neurologic event (in-hospital stroke/death, aOR = 1.1 [95% CI: 0.7–1.7]; $P = .66$), while TFCAS had higher risk of stroke/death in all time periods compared to CEA [69].

TRANSCAROTID ARTERY REVASCLARIZATION: TECHNIQUE, PERIOPERATIVE COURSE AND SURVEILLANCE

Transcarotid artery revascularization technique

Anesthesia, neuro-monitoring, and positioning

Transcarotid artery revascularization may be performed under general or loco-regional anesthesia. Using loco-regional anesthesia permits intraoperative neurologic examination. If TCAR is being performed under general anesthesia, we recommend a neuro-monitoring method chosen by the operator. It is preferable to perform TCAR in a standard hybrid operating room. Blood pressure monitoring is essential during TCAR and is utilized through an arterial line. Patients are positioned similar to CEA, supine on the operating room table and a shoulder roll is placed. The neck is turned to the contralateral side [70–72].

Access and flow reversal

The arterial access in TCAR is the CCA. Cut-down by a 2 cm longitudinal or transverse incision in the triangle between the superior border of the clavicle and the sternal and clavicular heads of the sternocleidomastoid muscle is performed (Fig. 2). We prefer a longitudinal incision to allow access for longer segment of the CCA. The proximal CCA is dissected circumferentially and a vessel loop is placed as proximally as possible under direct vision. A purse string or U stich with a 5-0 polypropylene suture is placed on the anterior adventitial surface of the CCA. This helps to close the arterial puncture site once the procedure is completed. In order to have an optimal access for TCAR, a CCA diameter ≥ 6 mm and clavicle-carotid bifurcation distance (landing zone) ≥ 5 cm is required (see Table 4) [72].

After the arterial dissection, femoral vein access is obtained by micropuncture technique under ultrasound guidance. The 8 French venous sheath is then placed over 0.035-inch stiff wire. Heparin is administered to keep

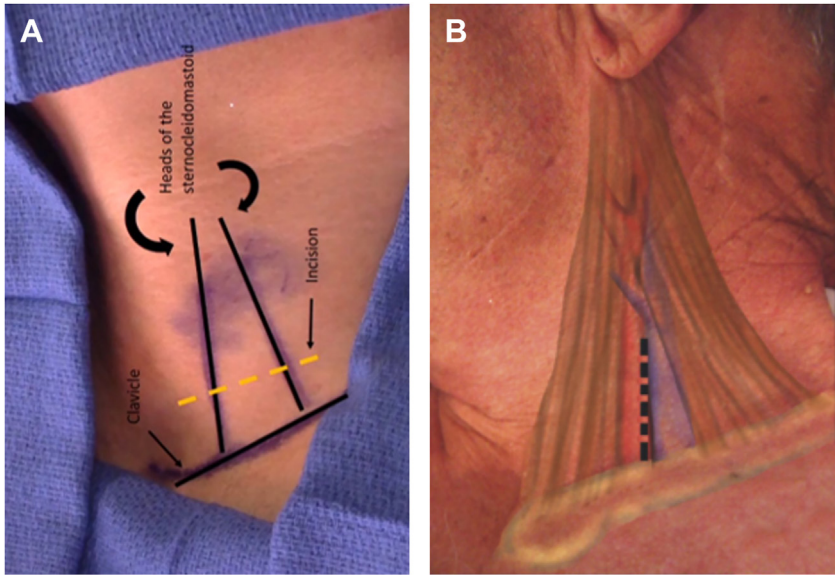


Fig. 2. (A) The anatomic landmarks for cut-down of common carotid artery during transcatheter artery revascularization. (B) Longitudinal incision. (Courtesy of Silk Road Medical, Inc.; Silk Road Medical, Inc. retains and reserves all rights, including copyrights.)

activated clotting time (ACT) >250 seconds. For arterial access, a micro-needle used in the center of pre-placed purse string polypropylene suture. Microwire (0.018-inch) is inserted only 3 to 5 cm. Microsheath is then inserted only 2 cm over the microwire. Angiogram is performed by gentle injection of 2 to 3 cc of contrast to help delineate the carotid bifurcation. If the external carotid artery (ECA) is healthy, we recommend engaging by advancing the microwire followed by the microsheath with dilator. The stiff 0.035-inch wire with floppy tip is then inserted into the microsheath with the distal tip into the ECA. If the ECA is severely diseased or if the lesion is in the distal CCA, we recommend “stop short technique” by placing the tip of the wire in the distal CCA (Fig. 3). Next, the 8 Fr arterial access sheath is inserted over the wire. We recommend at least two views for angiographic confirmation of true lumen position of the sheath. Having better purchase with the wire and possibly dilating the opening of the CCA by inserting the tip venous sheath dilator over the stiff wire only $\frac{1}{2}$ cm into the CCA are techniques that can reduce the risk of accidental CCA dissection during access placement. After obtaining arterial and venous accesses, the flow controller is connected to the arterial access sheath and a column of arterial blood is allowed to fill the line held upward passively prior to connecting it to the venous sheath initiating passive flow reversal. TCAR time out is then performed (Table 5). Then the CCA is clamped under direct vision proximal to the arterial puncture site to initiate active flow reversal (Fig. 4) [72,73].

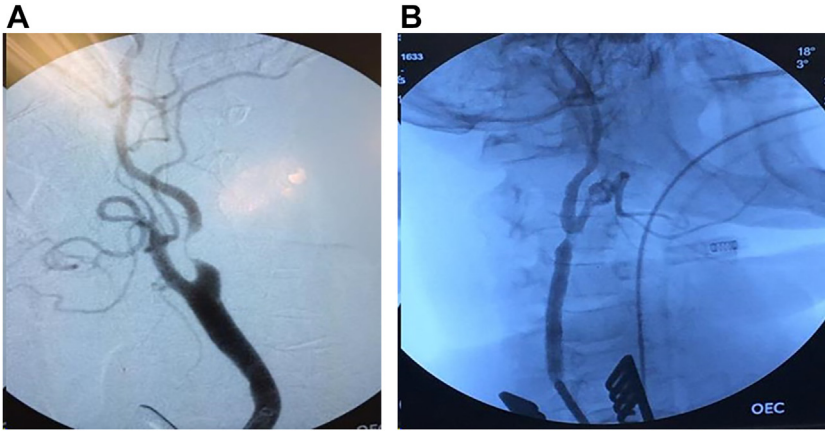


Fig. 3. (A) When common carotid artery (CCA) is less than 5 cm and proximal external carotid artery (ECA) is free of disease, the engage the ECA technique is used. (B) When disease is present in distal CCA or bifurcation, stop short technique is used. (Courtesy of Silk Road Medical, Inc.; Silk Road Medical, Inc. retains and reserves all rights, including copyrights.)

Stenting of the carotid

First, predilation is performed with a 2 to 4 mm diameter, 15 to 20 mm length balloon. The balloon is inflated slowly and then gradual deflation is started immediately. In authors' experience, predilation with larger diameter balloons is not required and a smaller balloon is usually adequate to prepare the lesion for stenting. Second, the ENROUTE self-expanding nitinol stent is deployed on 57 cm delivery system (Fig. 5). This is specifically designed for TCAR and the stents are available in 20, 30, or 40 mm lengths and diameters between 5 and 10 mm. The stent is oversized 1 to 2 mm larger in diameter than the CCA and self-tapers into the ICA. In addition to the ENROUTE self-

Table 5

Time-out for transcarotid artery revascularization

TCAR time-out	
Check devices	All wires, balloons and stent are open, flushed and ready to be used.
Maintain heart rate around 70 beats per minute	Patient received glycopyrrolate (a bolus dose of 0.2–0.4 mg)
Adequate anticoagulation	Confirm ACT > 250 s
Monitor SBP	SBP is maintained >160 mm Hg to allow appropriate delta to the venous pressure, which is essential for adequate flow reversal.

Abbreviations: ACT, activated clotting time; SBP, systolic blood pressure; TCAR, transcarotid artery revascularization.

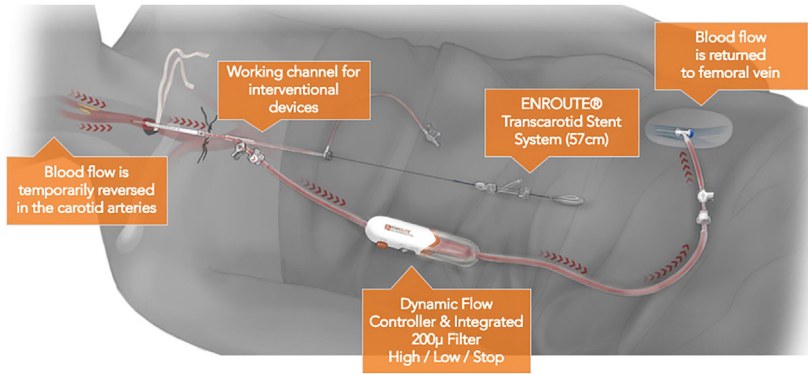


Fig. 4. ENROUTE TransCarotid Neuroprotection & Stent System. The flow controller and the reversal of flow from arterial sheath in transcarotid artery revascularization. The blood is returned to the circulation through the venous sheath. The flow controller has two flow settings and allow temporary cessation of flow via a flow stop button. (Courtesy of Silk Road Medical, Inc.; Silk Road Medical, Inc. retains and reserves all rights, including copyrights.)

expanding nitinol stent, other stent systems can be used in conjunction with ENROUTE cerebral protection device as well [72].

Data regarding the poststent ballooning is controversial and is recommended for significant residual stenosis (>40%). However, unlike TFCAS, we have found that poststent ballooning during TCAR is not associated with increased postoperative in-hospital stroke/death but is associated with a slight increase in TIA [74,75]. We recommend poststent ballooning only in lesions with significant circumferential calcification or residual stenosis greater than 50%. Like TFCAS, completion angiography is also performed to confirm proper stent placement and expansion. However, we have shown that routine performance of intracerebral angiography after TCAR is not beneficial [76].

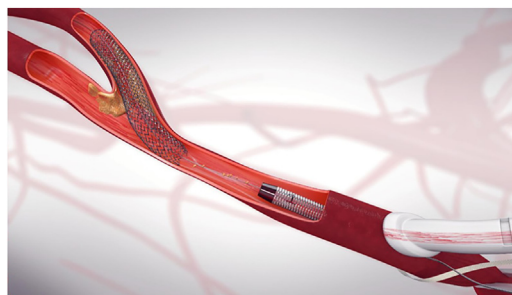

Fig. 5. The ENROUTE self-expanding nitinol stent is deployed through transcarotid access. (Courtesy of Silk Road Medical, Inc.; Silk Road Medical, Inc. retains and reserves all rights, including copyrights.)

Therefore, the completion angiography after TCAR should be limited to the ascertainment of the technical success and complete intracerebral views are not necessary.

Finally, CCA clamp is removed to restore the antegrade flow. The arterial access sheath is removed and the arteriotomy is closed by tying the sutures. The femoral vein sheath is removed as well [72]. Heparin reversal or drain placement may be considered [77].

Perioperative medications

Some surgeons prophylactically administer glycopyrrolate prior to predilation to prevent potential bradycardia and hypotension. Severe hypotension and bradycardia during the procedure is managed by aggressive volume expansion and intravenous atropine (0.4–1 mg). Moreover, phenylephrine and dopamine should be readily available to be used when necessary [18,78]. In our experience, avoiding poststent ballooning reduces the risk of hemodynamic instability.

Dual antiplatelet therapy (DAPT) with aspirin and clopidogrel is started at least 4 days prior to TCAR. Statin is also administered before and after the procedure. DAPT is continued for a minimum of 30 days after TCAR [79–81] but it is preferable to be continued for 12 months. Aspirin at 81 mg/d and statin therapy are continued indefinitely.

Postoperative care

Postoperative course

Following an uneventful TCAR, patients should be monitored for 24 hours, as an embolic stroke, hypotension with or without bradycardia or hypertension can occur during this early postoperative period [71,78]. It should be ascertained that the postoperative neurologic assessment continues to be normal or at baseline. In patients undergoing TCAR, a routine postoperative check should ensure that the incision site is clean, dry, and intact, that there is no evidence of a hematoma. Moreover, if a drain is present, it should be evaluated to ensure no active collection of bright red blood is present. The patients may be discharged 1 day after TCAR if there were no significant events overnight.

Postoperative surveillance

Surveillance duplex imaging should be initially obtained at first office visit and then 6 months after TCAR and annually thereafter [18].

COMPLICATIONS OF TRANSCAROTID ARTERY REVASCULARIZATION

Perioperative complications of transcarotid artery revascularization

The most significant procedural complication of CAS is stroke. TFCAS has been associated with increased risk of perioperative stroke compared with CEA due to the manipulation of the aortic arch and the carotid atherosclerotic plaque before the placement of EPD. However, the periprocedural risk of stroke after TCAR is significantly lower than TFCAS and comparable to

that of CEA in several non-randomized studies [45,82,83]. Like TFCAS, acute stent thrombosis following TCAR can occur and should be managed immediately. We have recently performed stent salvage procedures with TCAR under cerebral flow reversal to manage acute stent thrombosis.

Cervical hematoma is rare following TCAR. Reversal of heparin with protamine at the termination of the procedure may be helpful in preventing bleeding complications after TCAR [77]. MI is another serious complication following TFCAS and TCAR but the rates are significantly lower when compared to CEA [52,82,83]. CNI is very rare complication in patients undergoing TCAR because the dissection field is limited to proximal CCA in TCAR compared to CEA [83,84]. The vagus nerve is in the proximity of CCA and injury to this nerve can be avoided by meticulous dissection and careful clamping [72]. Patients undergoing CAS are at an increased risk of intracranial hemorrhage as compared to CEA, particularly in patients with hypertension or bilateral carotid stenoses. Cerebral hyperperfusion manifests by a severe headache and cerebral edema on brain imaging [85,86]. There is no specific study on intracranial hemorrhage following TCAR in the literature. CCA dissection is another rare complication of TCAR. Careful placement of the carotid sheath as described above and confirmation of true lumen by angiography prior to the placement of the main arterial sheath can minimize the risk of dissection. Dissection identified on angiogram should be treated by stenting [87].

Restenosis following carotid revascularization

There is no midterm or long-term data on restenosis rate after TCAR in the literature. Independent predictors of restenosis following carotid revascularization in Carotid Revascularization Endarterectomy versus Stenting Trial (*CREST*) were female sex, dyslipidemia, and diabetes. The rates of restenosis following TFCAS versus CEA did not differ significantly in the *CREST* trial at 2 years (6% vs 6.3%; $P = .58$) [40]. Likewise, a retrospective analysis of *VQI* data of 35,720 patients by our team also found no difference in restenosis rates between CEA and TFCAS in 2 years (7.7% vs 9.4%; HR = 0.99 [95% CI: 0.79–1.25]; $P = .97$) [88]. Since the mechanism of restenosis in CAS is related to patient factors and vessel-stent interactions rather than the access site used, it can be predicted that the restenosis rate following TCAR would be similar to TFCAS.

Most surgeons prefer CAS over CEA in patients with restenosis following CEA to avoid redo surgery in the neck and prevent CNI [89,90]. In fact, prior neck surgery is considered as a high-risk anatomic factor for CEA [65,91]. On the other hand, in-stent restenosis following CAS may be treated either by a redo-CAS or by CEA. CEA may be indicated in the cases of stent kinking or fracture [92–95].

The role of TCAR in the treatment of restenosis after prior CEA has been studied by our team. Analysis of 4425 patients with restenosis after CEA in *VQI* demonstrated that TCAR was associated with lower odds of in-hospital stroke/death (OR = 0.41 [95% CI: 0.24–0.70]; $P = .021$), and MI

(OR = 0.32 [95% CI: 0.14–0.73]; $P = .007$), when compared with redo-CEA. TCAR was also associated with lower odds of stroke/TIA (OR = 0.37 [95% CI: 0.18–0.74]; $P = .005$) when compared with TFCAS [96]. In another national study from our team, CEA and CAS following prior CAS were compared. There was no significant difference in 30-day stroke (OR = 0.82 [95% CI: 0.15–4.48; $P = .82$), 30-day mortality (OR = 2.21 [95% CI: 0.54–9.11]; $P = .27$), as well as 1-year stroke (HR = 0.60 [95% CI: 0.13–2.85]; $P = .52$) and 1-year mortality (HR = 0.83 [95% CI: 0.42–1.65]; $P = .60$), comparing CEA with redo-CAS [97]. The role of TCAR in the treatment of in-stent restenosis has not been studied in the literature. An ongoing VQI study by our team seeks to determine the role of TCAR following in-stent restenosis.

OUTCOMES

Two single-arm clinical trials have evaluated the safety and efficacy of ENROUTE (Silk Road Medical Inc., Sunnyvale, California) transcarotid neuroprotection system (NPS) during TCAR (Table 6). The Safety and Efficacy Study for Reverse Flow Used During Carotid Artery Stenting Procedure (ROADSTER 1) was performed in patients with increased risk for CEA (symptomatic patients with $\geq 50\%$ stenosis and asymptomatic patients with $\geq 70\%$ stenosis). The overall 30-day stroke rate was 1.4% and the use of the ENROUTE transcarotid NPS was safe and effective [98].

At 1 year, there was 96% stroke-free survival [99]. Moreover, early outcomes of ROADSTER 2 (Postapproval multicenter trial) in patients at high risk for CEA with symptomatic stenosis $\geq 50\%$ or asymptomatic stenosis $\geq 80\%$ revealed high technical success combined with low rates of postprocedure stroke and death after TCAR. The composite 30-day stroke/death rate was 2.3%, and stroke/death/MI rate was 3.2% in intention to treat analysis [100].

The Society of Vascular Surgery VQI TCAR Surveillance Project (TSP) was designed to evaluate the safety and effectiveness of TCAR in real-world practice. In this project, data of 638 TCAR patients were compared to 10,136 TFCAS patients. In multivariate analysis with 1:1 coarsened matching, TFCAS was associated with twice the odds of adverse in-hospital neurologic events and TIA/stroke/death compared with TCAR (OR = 2.10; [95% CI: 1.08–4.08]; $P = .03$), regardless of symptomatic status [45]. In another analysis of TSP-VQI data by propensity score matching (PSM), we compared two groups of TCAR and CEA ($n = 6384$) and found no significant differences between TCAR and CEA in terms of in-hospital stroke/death. Compared to CEA, TCAR was associated with 47% decreased risk of in-hospital MI (RR = 0.53; [95% CI: 0.35–0.83]; $P = .005$) and 86% decreased risk of CNI (RR = 0.14; [95% CI: 0.08–0.23]; $P < .001$) [83].

Several other PSM analyses have compared TCAR versus TFCAS and TCAR versus CEA. Using data of TSP-VQI from 2016 to 2019, 3286 matched pairs of TCAR and TFCAS were compared. TCAR was associated with a lower risk of in-hospital stroke or death (1.6% vs 3.1%; $P < .001$), stroke (1.3% vs 2.4; $P = .001$), and death (0.4% vs 1.0%; $P = .008$) compared with

Table 6

Single-arm trials on transcarotid artery revascularization

Name of the study	Type of the study	No. of patients (analyzed)	Patient characteristics	Outcomes
ROADSTER 1 [104]	Single-arm, multicenter, clinical trial	141	High risk for CEA, symptomatic with $\geq 50\%$ stenosis and asymptomatic with ≥ 70 stenosis	30-d all stroke = 1.4%; 30-d death = 1.4%; 30-d MI = 0.7%
ROADSTER 1; 1-year follow-up [105]	Single-arm, multicenter, clinical trial	165	High risk for CEA, symptomatic with $\geq 50\%$ stenosis and asymptomatic with ≥ 70 stenosis	1-y ipsilateral stroke = 0.6%, 1-y death = 4.2% (None was neurologic)
ROADSTER 2 [106]	Prospective, open label, single arm, multicenter, post-approval registry	692 (ITT) and 632 (PP)	High risk for CEA, symptomatic with $\geq 50\%$ stenosis and asymptomatic with ≥ 80 stenosis	ITT: 30-d stroke = 1.9%; 30-d death = 0.4%; 30-d MI = 0.9% PP: 30-d stroke = 0.6%; 30-d death = 0.2%; 30-d MI = 0.9%

Abbreviations: ITT, intention to treat; MI, myocardial infraction; PP, per-protocol.

TFCAS but the rates of in-hospital MI was not different. At 1 year, TCAR was associated with a lower risk of ipsilateral stroke or death (5.1% vs 9.6%; $P < .001$) [82]. Another PSM analysis of TSP-VQI data by our team included the CEA arm as well. Two 4180 matched pairs of TCAR and CEA were compared. There were no significant differences in 30-day stroke, death, and stroke/death rates. However, TCAR was associated with lower risks of perioperative MI (0.55% vs 1.12%; $P = .004$) and 30-day stroke/death/MI (2.30% vs 3.25%; $P = .008$). At 1 year, no significant difference was observed in the risk of ipsilateral stroke or death (6.49% vs 5.68%; $P = .157$) [101].

A systematic review and meta-analysis investigating the available literature on TCAR was conducted by our team recently. We evaluated 4012 patients and found that the overall 30-day risks following TCAR are stroke/death, 1.89% (95% CI: 1.50–2.37), stroke, 1.34% (95% CI: 1.02–1.75), death, 0.76% (95% CI: 0.56–1.08), MI, 0.60% (95% CI: 0.23–1.59), stroke/death/MI, 2.20% (95% CI: 1.31–3.69), and CNI, 0.31% (95% CI: 0.12–0.83). Two nonrandomized studies of this systematic review suggested that TCAR was associated with lower risk of stroke (1.33% vs 2.55%, OR = 0.52, [95% CI: 0.36–0.74]) and death (0.76% vs 1.46%, OR = 0.52, [95% CI: 0.32, 0.84]) compared to TFCAS. Furthermore, 4 nonrandomized studies suggested that TCAR was associated with a lower risk of CNI than CEA (0.54% vs 1.84%, OR = 0.52, [95% CI: 0.36–0.74]), but no statistically significant difference in the 30-day risk of stroke, stroke/death, or stroke/death/MI was observed [102].

It is important to emphasize that both ROADSTER 1 and 2 included only the patients who had either a high-risk anatomic or medical criterion for CEA. Silk Road Medical, Inc. received food and drug administration (FDA) approval for expanded indications for the ENROUTE stent to include patients at standard-risk for adverse events from CEA on April 28, 2022 (P140026-S016) [103]. Following this approval, the ROADSTER 3 trial has started and is currently recruiting patients deemed standard-risk for CEA. The ROADSTER 3 is a single-arm study as well and will enroll 400 patients. Symptomatic patients with $\geq 70\%$ stenosis by ultrasound or $\geq 50\%$ stenosis by angiogram or asymptomatic patients with $\geq 70\%$ stenosis by ultrasound or $\geq 60\%$ stenosis by angiogram will be included. The primary outcomes will be a composite of any death, stroke, or MI within 30 days of the index procedure and ipsilateral stroke within 31 to 365 days following the index procedure [104].

Analysis of VQI data for patients considered to be standard-risk by the Medicare & Medicaid Services (CMS) and undergoing carotid revascularization has been performed by Zhang and colleagues. Interestingly, they found that TFCAS was associated with an increased risk of perioperative stroke compared to CEA in standard-risk patients (aOR = 1.60 [95% CI: 1.37–1.86]; $P < .001$) but TCAR was not (aOR = 1.05 [95% CI: 0.84–1.31]; $P = .659$). Both TFCAS and TCAR were associated with significantly lesser risk of perioperative MI than CEA (aOR = 0.61 [95% CI: 0.49–0.77]; $P < .001$ and aOR = 0.68 [95% CI: 0.55–0.85]; $P = .001$, respectively) [105].

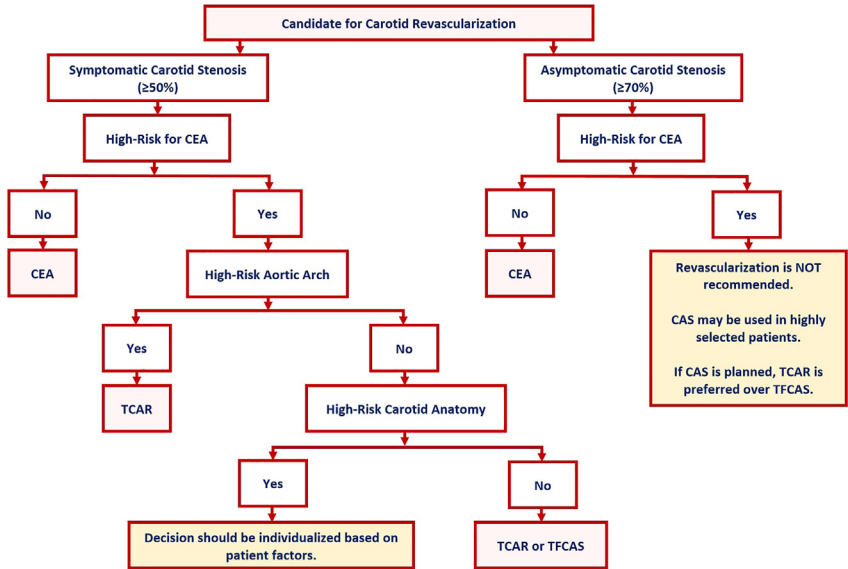


Fig. 6. Algorithm for the best method of carotid revascularization in patients with symptomatic and asymptomatic carotid artery stenosis. CAS, carotid artery stenting; CEA, carotid endarterectomy; TCAR, transcarotid artery revascularization; TFCAS, transfemoral carotid artery stenting.

COSTS

In a cost-effectiveness analysis of TCAR versus CEA in patients with symptomatic carotid stenosis, we found that CEA cost \$7821 for 2.85 quality-adjusted life years (QALY), whereas TCAR cost \$19,154 for 2.92 QALYs, leading to an incremental cost-effectiveness ratio of \$152,229 per QALY gained in TCAR [106]. CEA is still considered the most cost-effective method of carotid revascularization whereas TFCAS is the least cost-effective one [107,108].

SUMMARY

Based on the latest evidence and recommendations from AHA and SVS, carotid artery revascularization is indicated in symptomatic patients with $\geq 50\%$ stenosis and in asymptomatic patients with $\geq 70\%$ stenosis. CEA is the ideal method of carotid revascularization and remains the gold standard. However, CAS is preferred in certain high-surgical risk patients. TCAR has become an increasingly popular hybrid procedure that has outperformed TFCAS in patients who are considered high risk for surgery. There is increasing data that supports TCAR as a safe and efficient technique with outcomes similar to those of CEA, but additional studies are necessary to evaluate the long-term outcomes of TCAR in high- and standard-risk patients. RCT comparing CEA with TCAR particularly in standard-risk patients is needed to further determine the role of TCAR in the management of carotid stenosis. Fig. 6 illustrates an algorithm of decision making for patients undergoing carotid revascularization.

CLINICS CARE POINTS

- In a patient with $\geq 50\%$ symptomatic carotid artery stenosis, assess the risk of CEA. If the patient is standard risk for surgery, CEA is recommended. If the patient is high risk for surgery, consider CAS. TCAR is preferred over TFCAS in high-surgical risk patients.
- In a patient with $\geq 70\%$ asymptomatic carotid artery stenosis, assess the risk of CEA. If the patient is standard risk, CEA is recommended.
- In a patient with asymptomatic carotid artery stenosis $\geq 70\%$ and high risk for surgery, consider patient factors. Stent or aggressive medical therapy may be preferred based on multiple patient factors.

DISCLAIMER STATEMENT

S. Zarrintan has nothing to disclose. M.B. Malas was the principal investigator for ROADSTER 1 and ROADSTER 2 trial. He is a member of the steering committee of the Society for Vascular Surgery (SVS) Vascular Quality Initiative (VQI) Transcarotid Artery Revascularization (TCAR) Surveillance Project. He is also the national principal investigator for the ongoing ROADSTER 1 long-term follow-up trial.

References

- [1] Fisher M. Stroke and TIA: epidemiology, risk factors, and the need for early intervention. *Am J Manag Care* 2008;14(6 Suppl 2):S204–11.
- [2] Grysiewicz RA, Thomas K, Pandey DK. Epidemiology of ischemic and hemorrhagic stroke: incidence, prevalence, mortality, and risk factors. *Neurol Clin* 2008;26(4):871–95, vii.
- [3] Petty GW, Brown RD, Whisnant JP, et al. Ischemic stroke subtypes : a population-based study of functional outcome, survival, and recurrence. *Stroke* 2000;31(5):1062–8.
- [4] Kolominsky-Rabas PL, Weber M, Gefeller O, et al. Epidemiology of ischemic stroke subtypes according to TOAST criteria: incidence, recurrence, and long-term survival in ischemic stroke subtypes: a population-based study. *Stroke* 2001;32(12):2735–40.
- [5] Conrad MF, Boulom V, Baloum V, et al. Progression of asymptomatic carotid stenosis despite optimal medical therapy. *J Vasc Surg* 2013;58(1):128–35.e1.
- [6] Conrad MF, Michalczyk MJ, Opalacz A, et al. The natural history of asymptomatic severe carotid artery stenosis. *J Vasc Surg* 2014;60(5):1218–26.
- [7] Kakkos SK, Nicolaides AN, Charalambous I, et al. Predictors and clinical significance of progression or regression of asymptomatic carotid stenosis. *J Vasc Surg* 2014;59(4):956–67.e1.
- [8] Li B, Rizkallah P, Eisenberg N, et al. Symptom Status of Patients Undergoing Carotid Endarterectomy in Canada and United States. *Ann Vasc Surg* 2022;81:183–95.
- [9] Kernan WN, Ovbiagele B, Black HR, et al. Guidelines for the prevention of stroke in patients with stroke and transient ischemic attack: a guideline for healthcare professionals from the American Heart Association/American Stroke Association. *Stroke* 2014;45(7):2160–236.
- [10] Powers WJ, Rabinstein AA, Ackerson T, et al. 2018 Guidelines for the Early Management of Patients With Acute Ischemic Stroke: A Guideline for Healthcare Professionals From the American Heart Association/American Stroke Association. *Stroke* 2018;49(3):e46–110.

- [11] Ricotta JJ, Aburhama A, Ascher E, et al. Updated Society for Vascular Surgery guidelines for management of extracranial carotid disease. *J Vasc Surg* 2011;54(3):e1–31.
- [12] Reiff T, Eckstein HH, Mansmann U, et al. Contralateral Stenosis and Echolucent Plaque Morphology are Associated with Elevated Stroke Risk in Patients Treated with Asymptomatic Carotid Artery Stenosis within a Controlled Clinical Trial (SPACE-2). *J Stroke Cerebrovasc Dis* 2021;30(9):105940.
- [13] Kamtchum-Tatuene J, Wilman A, Saqqur M, et al. Carotid Plaque With High-Risk Features in Embolic Stroke of Undetermined Source: Systematic Review and Meta-Analysis. *Stroke* 2020;51(1):311–4.
- [14] Nicolaidis AN, Kakkos SK, Griffin M, et al. Severity of asymptomatic carotid stenosis and risk of ipsilateral hemispheric ischaemic events: results from the ACSRS study. *Eur J Vasc Endovasc Surg* 2005;30(3):275–84.
- [15] Hirt LS. Progression rate and ipsilateral neurological events in asymptomatic carotid stenosis. *Stroke* 2014;45(3):702–6.
- [16] Veith FJ, Amor M, Ohki T, et al. Current status of carotid bifurcation angioplasty and stenting based on a consensus of opinion leaders. *J Vasc Surg* 2001;33(2 Suppl):S111–6.
- [17] Liang P, Schermerhorn ML. Transcarotid Artery Revascularization: Is It Better than Carotid Endarterectomy? *Adv Surg* 2022;56(1):111–27.
- [18] Brott TG, Halperin JL, Abbara S, et al. 2011 ASA/ACCF/AHA/AANN/AANS/ACR/ASNR/CNS/SAIP/SCAI/SIR/SNIS/SVM/SVS guideline on the management of patients with extracranial carotid and vertebral artery disease: executive summary: a report of the American College of Cardiology Foundation/American Heart Association Task Force on Practice Guidelines, and the American Stroke Association, American Association of Neuroscience Nurses, American Association of Neurological Surgeons, American College of Radiology, American Society of Neuroradiology, Congress of Neurological Surgeons, Society of Atherosclerosis Imaging and Prevention, Society for Cardiovascular Angiography and Interventions, Society of Interventional Radiology, Society of NeuroInterventional Surgery, Society for Vascular Medicine, and Society for Vascular Surgery. Developed in collaboration with the American Academy of Neurology and Society of Cardiovascular Computed Tomography. *Catheter Cardiovasc Interv* 2013;81(1):E76–123.
- [19] AbuRahma AF, Avgerinos ED, Chang RW, et al. Society for Vascular Surgery clinical practice guidelines for management of extracranial cerebrovascular disease. *J Vasc Surg* 2022;75(1S):4S–22S.
- [20] AbuRahma AF, Avgerinos ED, Chang RW, et al. The Society for Vascular Surgery implementation document for management of extracranial cerebrovascular disease. *J Vasc Surg* 2022;75(1S):26S–98S.
- [21] Barnett HJ, Taylor DW, Eliasziw M, et al. Benefit of carotid endarterectomy in patients with symptomatic moderate or severe stenosis. North American Symptomatic Carotid Endarterectomy Trial Collaborators. *N Engl J Med* 1998;339(20):1415–25.
- [22] North American Symptomatic Carotid Endarterectomy Trial Collaborators, Barnett HJM, Taylor DW, Haynes RB, et al. Beneficial effect of carotid endarterectomy in symptomatic patients with high-grade carotid stenosis. *N Engl J Med* 1991;325(7):445–53.
- [23] Rothwell PM, Gutnikov SA, Warlow CP. European Carotid Surgery Trialists' Collaboration. Reanalysis of the final results of the European Carotid Surgery Trial. *Stroke* 2003;34(2):514–23.
- [24] Paraskevas KI, Mikhailidis DP, Veith FJ. Comparison of the five 2011 guidelines for the treatment of carotid stenosis. *J Vasc Surg* 2012;55(5):1504–8.
- [25] Young B, Moore WS, Robertson JT, et al. An analysis of perioperative surgical mortality and morbidity in the asymptomatic carotid atherosclerosis study. ACAS Investigators. Asymptomatic Carotid Atherosclerosis Study. *Stroke* 1996;27(12):2216–24.

- [26] Halliday A, Mansfield A, Marro J, et al. Prevention of disabling and fatal strokes by successful carotid endarterectomy in patients without recent neurological symptoms: randomised controlled trial. *Lancet* 2004;363(9420):1491–502.
- [27] Walker MD, Marler JR, Goldstein M, et al. Endarterectomy for Asymptomatic Carotid Artery Stenosis. *JAMA* 1995;273(18):1421–8.
- [28] Brott TG, Hobson RW, Howard G, et al. Stenting versus endarterectomy for treatment of carotid-artery stenosis. *N Engl J Med* 2010;363(1):11–23.
- [29] Brott TG, Howard G, Roubin GS, et al. Long-Term Results of Stenting versus Endarterectomy for Carotid-Artery Stenosis. *N Engl J Med* 2016;374(11):1021–31.
- [30] Rosenfield K, Matsumura JS, Chaturvedi S, et al. Randomized Trial of Stent versus Surgery for Asymptomatic Carotid Stenosis. *N Engl J Med* 2016;374(11):1011–20.
- [31] Mas JL, Chatellier G, Beyssen B, et al. Endarterectomy versus stenting in patients with symptomatic severe carotid stenosis. *N Engl J Med* 2006;355(16):1660–71.
- [32] Stonko DP, Goldsborough E, Kibrik P, et al. Use of Transcarotid Artery Revascularization, Transfemoral Carotid Artery Stenting, and Carotid Endarterectomy in the US From 2015 to 2019. *JAMA Netw Open* 2022;5(9):e2231944.
- [33] Voeks JH, Howard G, Roubin GS, et al. Age and outcomes after carotid stenting and endarterectomy: the carotid revascularization endarterectomy versus stenting trial. *Stroke* 2011;42(12):3484–90.
- [34] Nejim B, Alshwaily W, Dakour-Aridi H, et al. Age modifies the efficacy and safety of carotid artery revascularization procedures. *J Vasc Surg* 2019;69(5):1490–503.e3.
- [35] Mehta A, Patel PB, Bajkian D, et al. Transcarotid artery revascularization versus carotid endarterectomy and transfemoral stenting in octogenarians. *J Vasc Surg* 2021;74(5):1602–8.
- [36] Dias CG, Fajardo A, Martin GH, et al. Transcarotid Revascularization Results in Patients Over 70 Years of Age. *Vasc Endovascular Surg* 2023;57(2):114–8.
- [37] Dakour-Aridi H, Kashyap VS, Wang GJ, et al. The impact of age on in-hospital outcomes after transcarotid artery revascularization, transfemoral carotid artery stenting, and carotid endarterectomy. *J Vasc Surg* 2020;72(3):931–42.e2.
- [38] Dansey KD, Pothof AB, Zettervall SL, et al. Clinical impact of sex on carotid revascularization. *J Vasc Surg* 2020;71(5):1587–94.e2.
- [39] Howard VJ, Algra A, Howard G, et al. Absence of Consistent Sex Differences in Outcomes From Symptomatic Carotid Endarterectomy and Stenting Randomized Trials. *Stroke* 2021;52(2):416–23.
- [40] Lal BK, Beach KW, Roubin GS, et al. Restenosis after carotid artery stenting and endarterectomy: a secondary analysis of CREST, a randomised controlled trial. *Lancet Neurol* 2012;11(9):755–63.
- [41] Cui CL, Zarrintan S, Marmor RA, et al. Performance of Carotid Revascularization Procedures as Modified by Sex. *Ann Vasc Surg* 2022;81:171–82.
- [42] Jácome F, Nóbrega L, Pereira-Neves A, et al. Revised cardiac score index is a predictor of long-term outcomes after carotid endarterectomy. *Vasa* 2022;51(2):93–8.
- [43] Vernooij LM, van Klei WA, Moons KG, et al. The comparative and added prognostic value of biomarkers to the Revised Cardiac Risk Index for preoperative prediction of major adverse cardiac events and all-cause mortality in patients who undergo noncardiac surgery. *Cochrane Database Syst Rev* 2021;12:CD013139.
- [44] Squizzato F, Antonello M, Tagliavaloro J, et al. Clinical Impact of Routine Cardiology Consultation Prior to Elective Carotid Endarterectomy in Neurologically Asymptomatic Patients. *Eur J Vasc Endovasc Surg* 2020;59(4):536–44.
- [45] Malas MB, Dakour-Aridi H, Wang GJ, et al. Transcarotid artery revascularization versus transfemoral carotid artery stenting in the Society for Vascular Surgery Vascular Quality Initiative. *J Vasc Surg* 2019;69(1):92–103.e2.

- [46] Patel AR, Dombrovskiy VY, Vogel TR. A contemporary evaluation of carotid endarterectomy outcomes in patients with chronic kidney disease in the United States. *Vascular* 2017;25(5):459–65.
- [47] Pucciarelli A, Arcari A, Popusoi G, et al. Incidence and predictors of acute kidney injury in patients undergoing proximal protected carotid artery stenting. *EuroIntervention* 2018;14(3):e360–6.
- [48] Cooper M, Arhuidese IJ, Obeid T, et al. Perioperative and Long-term Outcomes After Carotid Endarterectomy in Hemodialysis Patients. *JAMA Surg* 2016;151(10):947–52.
- [49] Arhuidese IJ, Obeid T, Hicks CW, et al. Outcomes after carotid artery stenting in hemodialysis patients. *J Vasc Surg* 2016;63(6):1511–6.
- [50] Elsayed N, Moacdieh MP, Patel RJ, et al. Transcarotid Artery Revascularization Can Be Safely Performed in Patients Undergoing Dialysis. *J Vasc Surg* 2022;75(6):e109–10.
- [51] Conway AM, Nguyen Tran NT, Qato K, et al. Complexity of Aortic Arch Anatomy Affects the Outcomes of Transcarotid Artery Revascularization Versus Transfemoral Carotid Artery Stenting. *Ann Vasc Surg* 2020;67:78–89.
- [52] Dakour-Aridi H, Ramakrishnan G, Zarrintan S, et al. Outcomes of transcarotid revascularization with dynamic flow reversal versus carotid endarterectomy in the TCAR Surveillance Project. *Semin Vasc Surg* 2020;33(1–2):24–30.
- [53] Moacdieh MP, Khan MA, Layman P, et al. Innovation in the open and endovascular treatment of carotid artery stenosis. *Semin Vasc Surg* 2021;34(4):163–71.
- [54] Naazie IN, Magee GA, Mathlouthi A, et al. Primary mechanism of stroke reduction in transcarotid artery revascularization is dynamic flow reversal. *J Vasc Surg* 2021;74(1):187–94.
- [55] Bonati LH, Jongen LM, Haller S, et al. New ischaemic brain lesions on MRI after stenting or endarterectomy for symptomatic carotid stenosis: a substudy of the International Carotid Stenting Study (ICSS). *Lancet Neurol* 2010;9(4):353–62.
- [56] Blears E, Patel S, Doyle M, et al. Predicting Transcarotid Artery Revascularization Adverse Outcomes by Imaging Characteristics. *Ann Vasc Surg* 2022;87:388–401.
- [57] Wu WW, Liang P, O'Donnell TFX, et al. Anatomic eligibility for transcarotid artery revascularization and transfemoral carotid artery stenting. *J Vasc Surg* 2019;69(5):1452–60.
- [58] Elsayed N, Yei KS, Naazie I, et al. The impact of carotid lesion calcification on outcomes of carotid artery stenting. *J Vasc Surg* 2022;75(3):921–9.
- [59] Elsayed N, Khan MA, Moacdieh MP, et al. Carotid lesion length independently predicts stroke and death after transcarotid artery revascularization and transfemoral carotid artery stenting. *J Vasc Surg* 2022;76(6):1615–23.e2.
- [60] Nejjim B, Dakour-Aridi H, Locham S, et al. Carotid artery revascularization in patients with contralateral carotid artery occlusion: Stent or endarterectomy? *J Vasc Surg* 2017;66(6):1735–48.e1.
- [61] Kokkinidis DG, Chaitidis N, Giannopoulos S, et al. Presence of Contralateral Carotid Occlusion Is Associated With Increased Periprocedural Stroke Risk Following CEA but Not CAS: A Meta-analysis and Meta-regression Analysis of 43 Studies and 96,658 Patients. *J Endovasc Ther* 2020;27(2):334–44.
- [62] Dakour-Aridi H, Elsayed N, Malas M. Outcomes of Carotid Revascularization in Patients with Contralateral Carotid Artery Occlusion. *J Am Coll Surg* 2021;232(5):699–708.e1.
- [63] Batarseh P, Parides M, Carnevale M, et al. Perioperative outcomes of carotid endarterectomy and transfemoral and transcervical carotid artery stenting in radiation-induced carotid lesions. *J Vasc Surg* 2022;75(3):915–20.
- [64] Kang J, Woo SY, Yang SS, et al. Treatment results of carotid endarterectomy and carotid artery stenting for patients with radiation-induced carotid stenosis. *Ann Surg Treat Res* 2022;103(2):112–8.
- [65] Khan MA, Abdelkarim A, Elsayed N, et al. Evaluating postoperative outcomes in patients with hostile neck anatomy undergoing transcarotid artery revascularization versus transfemoral carotid artery stenting. *J Vasc Surg* 2022;77(1):191–200.

- [66] Cui CL, Yei KS, Ramachandran M, et al. In-hospital complications and long-term outcomes associated with timing of carotid endarterectomy. *J Vasc Surg* 2022;76(1):222–31.e1.
- [67] Tanious A, Pothof AB, Boitano LT, et al. Timing of Carotid Endarterectomy After Stroke: Retrospective Review of Prospectively Collected National Database. *Ann Surg* 2018;268(3):449–56.
- [68] Cui CL, Dakour-Aridi H, Eldrup-Jorgensen J, et al. Effects of timing on in-hospital and one-year outcomes after transcarotid artery revascularization. *J Vasc Surg* 2021;73(5):1649–57.e1.
- [69] Cui CL, Dakour-Aridi H, Lu JJ, et al. In-Hospital Outcomes of Urgent, Early, or Late Revascularization for Symptomatic Carotid Artery Stenosis. *Stroke* 2022;53(1):100–7.
- [70] Marmor RA, Dakour-Aridi H, Chen ZG, et al. Anesthetic choice during transcarotid artery revascularization and carotid endarterectomy affects the risk of myocardial infarction. *J Vasc Surg* 2021;74(4):1281–9.
- [71] Mehta V, Tharp P, Caruthers C, et al. TCAR can safely be performed with regional anesthesia and no ICU stay. *J Vasc Surg* 2023;77(2):555–8.
- [72] Malas MB, Leal J, Kashyap V, et al. Technical aspects of transcarotid artery revascularization using the ENROUTE transcarotid neuroprotection and stent system. *J Vasc Surg* 2017;65(3):916–20.
- [73] Kumins NH, Kashyap VS. Learning curve and proficiency of transcarotid artery revascularization compared to transfemoral carotid artery stenting. *Semin Vasc Surg* 2020;33(1–2):16–23.
- [74] Dakour-Aridi H, Cui CL, Barleben A, et al. Poststent ballooning during transcarotid artery revascularization. *J Vasc Surg* 2021;73(6):2041–9.e1.
- [75] Obeid T, Arnaoutakis DJ, Arhuidese I, et al. Poststent ballooning is associated with increased periprocedural stroke and death rate in carotid artery stenting. *J Vasc Surg* 2015;62(3):616–23.e1.
- [76] Elsayed N, Locham S, Janssen C, et al. Effect of routine intracerebral completion angiography on outcomes after transcarotid artery revascularization. *J Vasc Surg* 2022;75(6):1958–65.
- [77] Liang P, Motaganahalli RL, Malas MB, et al. Protamine use in transcarotid artery revascularization is associated with lower risk of bleeding complications without higher risk of thromboembolic events. *J Vasc Surg* 2020;72(6):2079–87.
- [78] Kania TA, Noorani A, Juneja A, et al. Hemodynamic instability in the immediate postoperative setting after transcarotid artery revascularization. *Vascular* 2022; <https://doi.org/10.1177/17085381221105178> 17085381221105178.
- [79] Rizwan M, Faateh M, Dakour-Aridi H, et al. Statins reduce mortality and failure to rescue after carotid artery stenting. *J Vasc Surg* 2019;69(1):112–9.
- [80] McKeivitt FM, Randall MS, Cleveland TJ, et al. The benefits of combined anti-platelet treatment in carotid artery stenting. *Eur J Vasc Endovasc Surg* 2005;29(5):522–7.
- [81] Paraskevas KI, Glocviczki P, Mikhailidis DP, et al. Optimal periprocedural antithrombotic treatment in carotid interventions: An international, multispecialty, expert review and position statement. *Prog Cardiovasc Dis* 2022;74:28–37.
- [82] Schermerhorn ML, Liang P, Eldrup-Jorgensen J, et al. Association of Transcarotid Artery Revascularization vs Transfemoral Carotid Artery Stenting With Stroke or Death Among Patients With Carotid Artery Stenosis. *JAMA* 2019;322(23):2313–22.
- [83] Malas MB, Dakour-Aridi H, Kashyap VS, et al. TransCarotid Revascularization With Dynamic Flow Reversal Versus Carotid Endarterectomy in the Vascular Quality Initiative Surveillance Project. *Ann Surg* 2022;276(2):398–403.
- [84] Galyfos GC, Tsoutsas I, Konstantopoulos T, et al. Editor's Choice - Early and Late Outcomes after Transcarotid Revascularisation for Internal Carotid Artery Stenosis: A Systematic Review and Meta-Analysis. *Eur J Vasc Endovasc Surg* 2021;61(5):725–38.

- [85] Abou-Chebl A, Yadav JS, Reginelli JP, et al. Intracranial hemorrhage and hyperperfusion syndrome following carotid artery stenting: risk factors, prevention, and treatment. *J Am Coll Cardiol* 2004;43(9):1596–601.
- [86] McDonald RJ, Cloft HJ, Kallmes DF. Intracranial hemorrhage is much more common after carotid stenting than after endarterectomy: evidence from the National Inpatient Sample. *Stroke* 2011;42(10):2782–7.
- [87] Liapis CD, Bell PRF, Mikhailidis D, et al. ESVS guidelines. Invasive treatment for carotid stenosis: indications, techniques. *Eur J Vasc Endovasc Surg* 2009;37(4 Suppl):1–19.
- [88] Dakour-Arudi H, Mathlouthi A, Locham S, et al. Predictors of midterm high-grade restenosis after carotid revascularization in a multicenter national database. *J Vasc Surg* 2020;71(6):1972–81.
- [89] Arhuidese I, Obeid T, Nejjim B, et al. Stenting versus endarterectomy after prior ipsilateral carotid endarterectomy. *J Vasc Surg* 2017;65(1):1–11.
- [90] Arhuidese U, Faateh M, Nejjim BJ, et al. Risks Associated With Primary and Redo Carotid Endarterectomy in the Endovascular Era. *JAMA Surg* 2018;153(3):252–9.
- [91] AbuRahma AF, Abu-Halimah S, Bensenhaver J, et al. Primary carotid artery stenting versus carotid artery stenting for postcarotid endarterectomy stenosis. *J Vasc Surg* 2009;50(5):1031–9.
- [92] Zhou W, Lin PH, Bush RL, et al. Management of in-stent restenosis after carotid artery stenting in high-risk patients. *J Vasc Surg* 2006;43(2):305–12.
- [93] Guo Z, Liu C, Huang K, et al. Meta-analysis of redo stenting versus endarterectomy for in-stent stenosis after carotid artery stenting. *J Vasc Surg* 2021;73(4):1282–9.
- [94] Huang H, Wu L, Guo Y, et al. Treatment of the Carotid In-stent Restenosis: A Systematic Review. *Front Neurol* 2021;12:748304.
- [95] Reichmann BL, van Laanen JHH, de Vries JPPM, et al. Carotid endarterectomy for treatment of in-stent restenosis after carotid angioplasty and stenting. *J Vasc Surg* 2011;54(1):87–92.
- [96] Elsayed N, Ramakrishnan G, Naazie I, et al. Outcomes of Carotid Revascularization in the Treatment of Restenosis After Prior Carotid Endarterectomy. *Stroke* 2021;52(10):3199–208.
- [97] Arhuidese U, Nejjim B, Chavali S, et al. Endarterectomy versus stenting in patients with prior ipsilateral carotid artery stenting. *J Vasc Surg* 2017;65(5):1418–28.
- [98] Kwolek CJ, Jaff MR, Leal JJ, et al. Results of the ROADSTER multicenter trial of transcrotid stenting with dynamic flow reversal. *J Vasc Surg* 2015;62(5):1227–34.
- [99] Malas MB, Leal Lorenzo JJ, Nejjim B, et al. Analysis of the ROADSTER pivotal and extended-access cohorts shows excellent 1-year durability of transcrotid stenting with dynamic flow reversal. *J Vasc Surg* 2019;69(6):1786–96.
- [100] Kashyap VS, Schneider PA, Foteh M, et al. Early Outcomes in the ROADSTER 2 Study of Transcarotid Artery Revascularization in Patients With Significant Carotid Artery Disease. *Stroke* 2020;51(9):2620–9.
- [101] Malas MB, Elsayed N, Naazie I, et al. Propensity score-matched analysis of 1-year outcomes of transcrotid revascularization with dynamic flow reversal, carotid endarterectomy, and transfemoral carotid artery stenting. *J Vasc Surg* 2022;75(1):213–22.e1.
- [102] Naazie IN, Cui CL, Osaghae I, et al. A Systematic Review and Meta-Analysis of Transcarotid Artery Revascularization with Dynamic Flow Reversal Versus Transfemoral Carotid Artery Stenting and Carotid Endarterectomy. *Ann Vasc Surg* 2020;69:426–36.
- [103] ENROUTE Transcarotid Stent System – P140026/S016. FDA Internet. 2022 Jun 3; Available at: <https://www.fda.gov/medical-devices/recently-approved-devices/enroute-transcarotid-stent-system-p140026s016>. Accessed October 28, 2022.
- [104] Post-approval Study of Transcarotid Artery Revascularization in Standard Risk Patients With Significant Carotid Artery Disease. The ROADSTER 3 Study Internet. clinicaltrials.gov; 2022. Report No.: NCT05365490. Available at: <https://clinicaltrials.gov/ct2/show/NCT05365490>. Accessed October 27, 2022.

- [105] Zhang GQ, Bose S, Stonko DP, et al. Transcarotid artery revascularization is associated with similar outcomes to carotid endarterectomy regardless of patient risk status. *J Vasc Surg* 2022;76(2):474–81. e3.
- [106] Cui C, Ramakrishnan G, Murphy J, et al. Cost-effectiveness of transcarotid artery revascularization versus carotid endarterectomy. *J Vasc Surg* 2021;74(6):1910–8. e3.
- [107] Kanitra JJ, Graham IA, Hayward RD, et al. Estimated Cost of Transcarotid Arterial Revascularization Compared With Carotid Endarterectomy and Transfemoral Carotid Stenting. *Cureus* 2022;14(3):e23539.
- [108] Sridharan ND, Chaer RA, Smith K, et al. Carotid endarterectomy remains cost-effective for the surgical management of carotid stenosis. *J Vasc Surg* 2022;75(4):1304–10.