

# **UCLA**

## **Proceedings of UCLA Health**

### **Title**

Metastatic Breast Cancer: A Rare Cause of Chronic Diarrhea

### **Permalink**

<https://escholarship.org/uc/item/6mt773x3>

### **Journal**

Proceedings of UCLA Health, 21(1)

### **Authors**

Lin, Lisa

Farid, Mary

### **Publication Date**

2017-06-27

## CLINICAL VIGNETTE

# Metastatic Breast Cancer: A Rare Cause of Chronic Diarrhea

Lisa Lin, M.D. and Mary Farid, M.D.

### Introduction

Breast cancer is the most common cancer in women worldwide.<sup>1</sup> Breast cancer often metastasizes to bones (85%), lung (15-25%), liver (40-50%), and brain (6-16%), but rarely the gastrointestinal tract (0.5%).<sup>2,3</sup> Lobular breast carcinoma is more likely to metastasize to the gastrointestinal tract than ductal carcinoma.<sup>2</sup> Breast cancer metastasis can affect any part of the gastrointestinal tract, ranging from mouth to anus. Among the possible gastrointestinal sites, stomach is most commonly affected while colon is involved in only about 8% of cases. On colonoscopy, breast cancer metastasis may manifest as stricture, mass, polypoid lesions, linitis plastica or non-specific edematous folds and superficial erosions.<sup>3,4</sup>

### Case Report

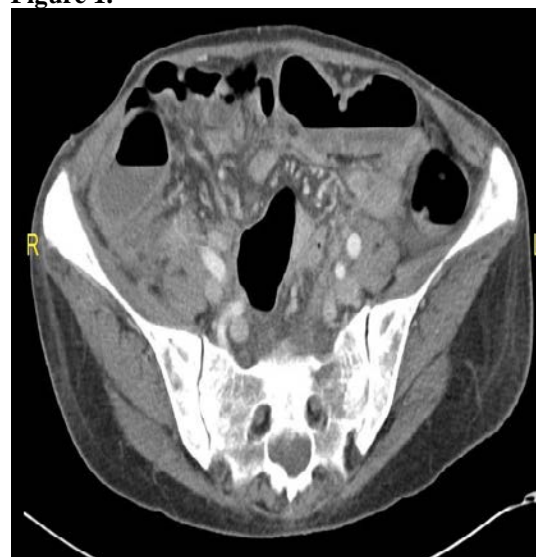A 64-year-old woman presented with 10 months of watery diarrhea. Her past medical history included hemolytic anemia, monoclonal gammopathy, beta thalassemia trait, Hashimoto's thyroiditis complicated by Hashimoto's encephalopathy, hepatitis C cured by Simeprevir and Sofosbuvir, and metastatic breast cancer. Her breast cancer was diagnosed on a screening colonoscopy 16 months prior that showed three 2mm sessile polyps in the left colon. All were poorly differentiated adenocarcinoma consistent with metastatic breast cancer (ER+, PR-, HER2+). Positron emission tomography-computed tomography (PET/CT) of head, chest, abdomen and pelvis showed an FDG-avid right breast nodule and FDG-avid right subpectoral axillary lymphadenopathy.

No FDG-avid metastases were seen in the abdomen or pelvis. The patient underwent core needle biopsy of both the right breast nodule and axillary lymph node. Breast biopsy showed grade 2 intraductal carcinoma with lobular features and pleomorphic lobular carcinoma in situ (ER-, PR-, HER2-), while the axillary biopsy showed lobular breast carcinoma (ER+, PR-, HER2+). She was started on Letrozole and Palbociclib for the ER+ lobular breast carcinoma, and underwent right modified radical mastectomy for the triple-negative intraductal carcinoma, along with left prophylactic mastectomy, which on pathology demonstrated invasive lobular carcinoma as well.

In the same year of the patient's breast cancer diagnosis, the patient developed recurrent episodes of *Streptococcus viridans* bacteremia that was thought to be due to gastrointestinal translocation in the setting of known gastrointestinal metastasis. She required chronic suppressive antibiotic therapy with cephalexin, which initially controlled the bacteremic episodes but after a few months, she was re-admitted for recurrent *Streptococcus viridans* bacteremia. After 10 months on suppressive antibiotic, she developed intermittent watery non-bloody diarrhea that alternated with constipation, which continued despite holding chemotherapy in setting of neutropenia. Initial stool studies were negative for infectious etiologies including *Clostridium difficile*, bacterial pathogens, ova and parasites, giardia, and cryptosporidium. Her intermittent diarrhea continued and a repeat colonoscopy was planned but deferred when she tested positive for *Clostridium difficile* on a repeat test.

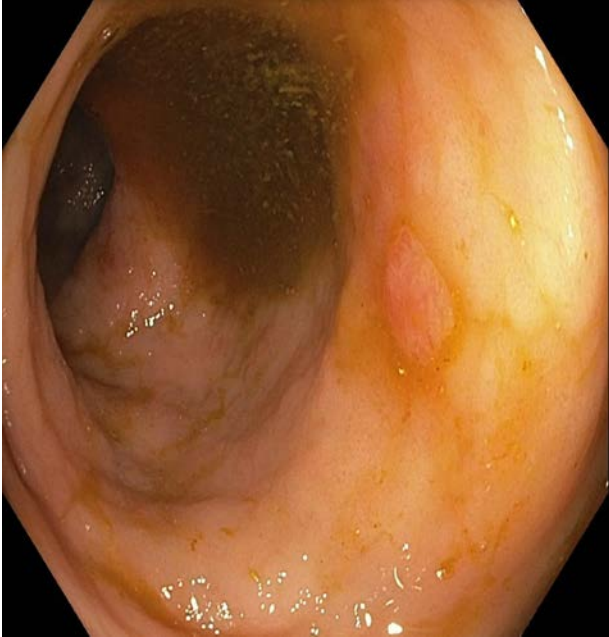She was treated with Vancomycin for more than 2 months due to persistent *Clostridium difficile* positivity in stool. Ultimately, her *Clostridium difficile* stool test became negative, but her diarrhea did not improve. CT of the abdomen and pelvis showed pan-colonic circumferential mural thickening.

Figure 1.



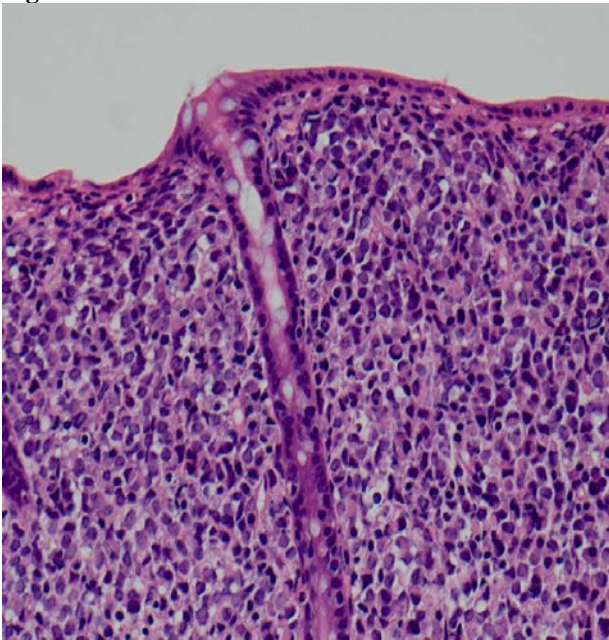
Colonoscopy demonstrated diffusely edematous and nodular-appearing mucosa with loss of vascular pattern throughout the entire colon.

**Figure 2.**



Multiple random biopsies taken throughout the colon all demonstrated metastatic breast carcinoma (ER+, PR-, HER2+), consistent with the pathology from her lobular breast carcinoma. Diarrhea was controlled with tincture of opium.

**Figure 3.**



The patient subsequently had continued disease progression despite multiple different chemotherapy regimens, and

ultimately died 4 months later with septic shock and liver failure.

### **Discussion**

Breast cancer is the most common cancer in women and rarely metastasizes to the gastrointestinal tract, but can metastasize to anywhere from mouth to anus. The most common site of gastrointestinal metastasis is the stomach, followed by the esophagus, small intestine, colon and rectum.<sup>3</sup> Compared to ductal carcinoma, infiltrating lobular breast cancer has an increased tendency to involve the gastrointestinal tract<sup>4</sup>. Metastasis to the gastrointestinal tract can manifest as a wide range of clinical symptoms including bowel obstruction, abdominal mass, anemia, nausea and vomiting, diarrhea and abdominal pain. Many of these symptoms can also be seen as side effects of chemotherapeutic agents used to treat breast cancer, such as docetaxel-based agents used to treat metastatic breast cancer, which is associated with colitis.<sup>4</sup> Therefore, it is important to have a high index of suspicion in patients with a history of breast cancer who present with non-specific gastrointestinal symptoms.

The median time from diagnosis of primary breast cancer to colonic metastasis is 6 to 8 years, however it has been reported as early as 4 months and as late as 28 years after initial diagnosis.<sup>4</sup> Colonic metastasis can even precede the diagnosis of primary breast cancer, as occurred in our patient.<sup>5</sup>

In the colon or the rectum, breast cancer metastasis usually presents as an obstructive mass or stenosis, rarely as a diffusely infiltrative process involving the entire colon such as in this case. Although our patient's course was complicated by *Clostridium difficile* infection, her chronic diarrhea of 10 months was most likely due to the infiltrative tumor impairing the colon's ability to absorb fluids. Her diarrhea started many months before her *Clostridium difficile* diagnosis, and persisted despite negative *Clostridium difficile* testing and Vancomycin treatment. Her recurrent streptococcus viridans bacteremia may also have been related to progressive tumor infiltration of the colon.

It was also interesting that she had two separate breast carcinomas, one intraductal and one lobular, and it was the lobular carcinoma that metastasized to the colon, further supporting the reported increased propensity for lobular carcinomas to metastasize to the gastrointestinal tract.

In conclusion, in patients with breast cancer, especially of lobular histology, presenting with chronic diarrhea with negative infectious studies, it is important to consider colonic metastases. Abdominal computed tomography imaging may be helpful in elucidating site and extent of involvement. Early colonoscopy evaluation with biopsies could help in establishing a timely diagnosis and aid oncologists in prognosis discussions and treatment planning.

## Figure Legends

Figure 1: CT of the abdomen and pelvis showed diffusely fluid-filled colon with pan-colonic circumferential mural thickening.

Figure 2: Colonoscopy demonstrated diffusely edematous and nodular-appearing mucosa with loss of vascular pattern throughout the entire colon.

Figure 3: Hematoxylin and eosin stain (high power – 400X) of colon biopsy showed expanded lamina propria due to infiltrating tumor cells.

## REFERENCES

1. **Global Burden of Disease Cancer Collaboration, Fitzmaurice C, Dicker D, Pain A, Hamavid H, Moradi-Lakeh M, MacIntyre MF, Allen C, Hansen G, Woodbrook R, Wolfe C, Hamadeh RR, Moore A, Werdecker A, Gessner BD, Te Ao B, McMahon B, Karimkhani C, Yu C, Cooke GS, Schwebel DC, Carpenter DO, Pereira DM, Nash D, Kazi DS, De Leo D, Plass D, Ukwaja KN, Thurston GD, Yun Jin K, Simard EP, Mills E, Park EK, Catalá-López F, deVeber G, Gotay C, Khan G, Hosgood HD 3rd, Santos IS, Leasher JL, Singh J, Leigh J, Jonas JB, Sanabria J, Beardsley J, Jacobsen KH, Takahashi K, Franklin RC, Ronfani L, Montico M, Naldi L, Tonelli M, Geleijnse J, Petzold M, Shrimo MG, Younis M, Yonemoto N, Breitborde N, Yip P, Pourmalek F, Lotufo PA, Esteghamati A, Hankey GJ, Ali R, Lunevicius R, Malekzadeh R, Dellavalle R, Weintraub R, Lucas R, Hay R, Rojas-Rueda D, Westerman R, Sepanlou SG, Nolte S, Patten S, Weichenthal S, Abera SF, Fereshtehnejad SM, Shiue I, Driscoll T, Vasankari T, Alsharif U, Rahimi-Movaghar V, Vlassov VV, Marcenes WS, Mekonnen W, Melaku YA, Yano Y, Artaman A, Campos I, MacLachlan J, Mueller U, Kim D, Trillini M, Eshrati B, Williams HC, Shibuya K, Dandona R, Murthy K, Cowie B, Amare AT, Antonio CA, Castañeda-Orjuela C, van Gool CH, Violante F, Oh IH, Deribe K, Soreide K, Knibbs L, Kereselidze M, Green M, Cardenas R, Roy N, Tillmann T, Li Y, Krueger H, Monasta L, Dey S, Sheikhbahaei S, Hafezi-Nejad N, Kumar GA, Sreeramareddy CT, Dandona L, Wang H, Vollset SE, Mokdad A, Salomon JA, Lozano R, Vos T, Forouzanfar M, Lopez A, Murray C, Naghavi M.** The Global Burden of Cancer 2013. *JAMA Oncol.* 2015 Jul;1(4):505-27. doi: 10.1001/jamaoncol.2015.0735. Erratum in: *JAMA Oncol.* 2015 Aug;1(5):690. Jonas, Jost [corrected to Jonas, Jost B]; Tillman, Taavi [corrected to Tillmann, Taavi]. PubMed PMID: 26181261; PubMed Central PMCID: PMC4500822.
2. **Borst MJ, Ingold JA.** Metastatic patterns of invasive lobular versus invasive ductal carcinoma of the breast. *Surgery.* 1993 Oct;114(4):637-41; discussion 641-2. PubMed PMID: 8211676.
3. **Ambroggi M, Stroppa EM, Mordenti P, Biasini C, Zangrandi A, Michieletti E, Belloni E, Cavanna L.** Metastatic breast cancer to the gastrointestinal tract: report of five cases and review of the literature. *Int J Breast Cancer.* 2012;2012:439023. doi: 10.1155/2012/439023. Epub 2012 Oct 4. PubMed PMID:23091732; PubMed Central PMCID: PMC3471430.
4. **Murukutla S, Vivekanandaraja A, Paramanathan K, Kong F, Varma S.** Isolated colonic metastasis from primary invasive ductal breast carcinoma: role of tumor marker in early diagnosis. *J Med Cases.* 2012;3:49-53.
5. **Wiisanen J, Kaur J.** Gastrointestinal metastases from breast cancer, a diagnostic dilemma. *MOJ Clin Med Case.* 2015;2(2):00014

Submitted June 27, 2017