

UC Irvine

Western Journal of Emergency Medicine: Integrating Emergency Care with Population Health

Title

Pericardial Cyst: Unexpected Finding on a Chest Radiograph

Permalink

<https://escholarship.org/uc/item/6m53w3dc>

Journal

Western Journal of Emergency Medicine: Integrating Emergency Care with Population Health, 12(4)

ISSN

1936-900X

Authors

Schmitt, Eric R
Burg, Michael D

Publication Date

2011

DOI

10.5811/westjem.2011.4.2275

Copyright Information

Copyright 2011 by the author(s). This work is made available under the terms of a Creative Commons Attribution-NonCommercial License, available at <https://creativecommons.org/licenses/by-nc/4.0/>

Peer reviewed

Pericardial Cyst: Unexpected Finding on a Chest Radiograph

Eric R. Schmitt, MD, MPH*
Michael D. Burg, MD†

* Harbor-UCLA Medical Center, Department of Emergency Medicine, Torrance, California

† Kaweah Delta Medical Center, Department of Emergency Medicine, Visalia, California

Supervising Section Editor: Sean Henderson, MD

Submission history: Submitted April 4, 2011; Accepted April 11, 2011

Reprints available through open access at http://escholarship.org/uc/uciem_westjem

DOI: 10.5811/westjem.2011.4.2275

[West J Emerg Med. 2011;12(4):579–580.]

A 32-year-old female presented to the emergency department after a motor vehicle collision with complaints of thoracic back pain. Further history was not obtainable owing to marked ethanol intoxication. Vital signs and physical examination were unremarkable except for a mild tachycardia, which resolved with intravenous fluids. A chest radiograph was obtained (Figure 1). Medical records' review revealed that the same abnormality had been noted 17 months earlier (Figure 2).

DIAGNOSIS

Most pericardial cysts are congenital, forming during embryogenesis from a persistent parietal recess.¹ They are uncommon, with an estimated prevalence of 1 in 100,000 population.^{1,2} Approximately 1 in 6 patients are symptomatic with complaints of chest pain or dyspnea.² Pericardial cysts may cause cardiac compression and may enlarge over time.¹ They are easily seen on routine chest radiographs and may be an incidental finding as in our case. Diagnosis is confirmed

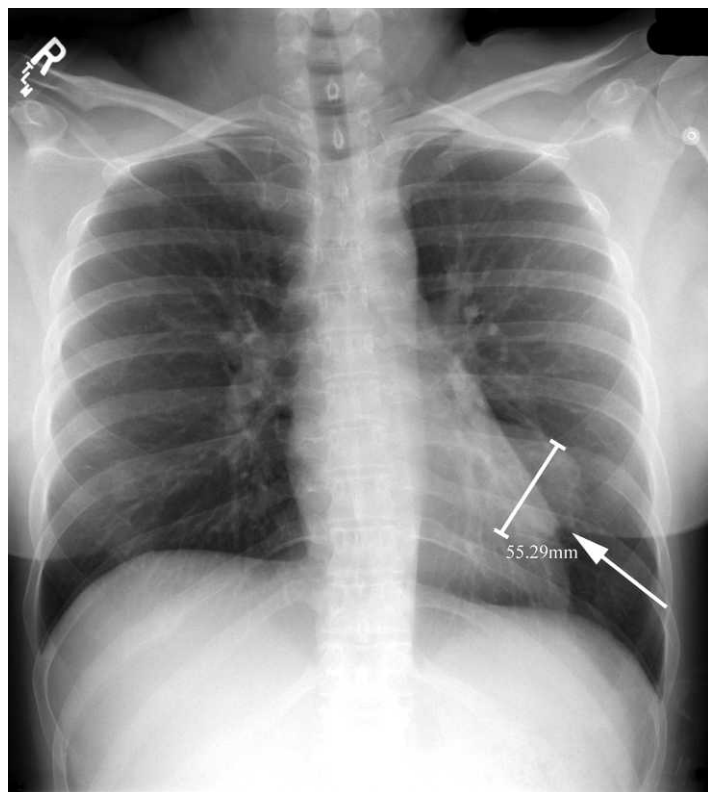


Figure 1. Supine anteroposterior chest radiograph showing (arrow) a 6 × 8-cm focal mass in the left lung base.

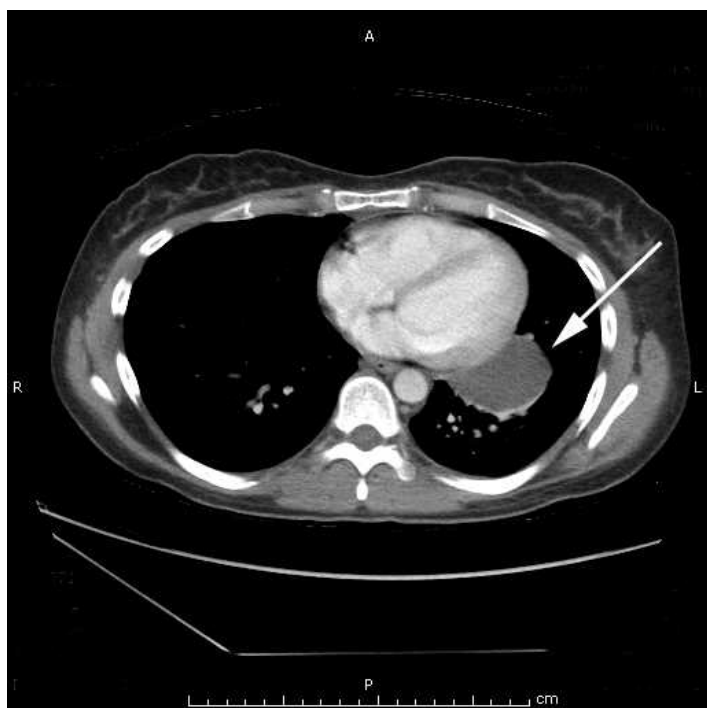

Figure 2. Chest computed tomographic scan with intravenous contrast obtained 17 months previously and showing (arrow) a 4.5 × 2.8-cm, well-defined, encapsulated fluid collection contiguous with the left heart border.

with computed tomography or magnetic resonance imaging, and surgical treatment is indicated for symptomatic patients.^{1,2} Watchful observation may be feasible for asymptomatic patients, but outcome data are lacking and thus preventive resection may be preferred.²

Address for Correspondence: Eric R. Schmitt, MD, MPH, Harbor–UCLA Medical Center, Department of Emergency Medicine, 1000 W Carson St, Box 21, Torrance, CA 90509. E-mail ericrschmitt@yahoo.com.

Conflicts of Interest: By the *WestJEM* article submission agreement, all authors are required to disclose all affiliations, funding sources, and financial or management relationships that could be perceived as potential sources of bias. The authors disclosed none.

REFERENCES

1. Duwe BV, Sterman DH, Musani AI. Tumors of the mediastinum. *Chest*. 2005;128:2893–2909.
2. Takeda S, Miyoshi S, Minami M, et al. Clinical spectrum of mediastinal cysts. *Chest*. 2003;124:125–132.