

# UC Davis

## Dermatology Online Journal

### Title

Lupus miliaris disseminatus faciei: A unique presentation with extrafacial involvement

### Permalink

<https://escholarship.org/uc/item/6m073615>

### Journal

Dermatology Online Journal, 31(1)

### Authors

Fields, Alicia B

Margheim, Ashlee M

Callen, Jeffrey P

et al.

### Publication Date

2025

### DOI

10.5070/D331164979

### Copyright Information

Copyright 2025 by the author(s). This work is made available under the terms of a Creative Commons Attribution-NonCommercial-NoDerivatives License, available at

<https://creativecommons.org/licenses/by-nc-nd/4.0/>

Peer reviewed

# Lupus miliaris disseminatus faciei: A unique presentation with extrafacial involvement

Alicia B. Fields<sup>1</sup> DNP, Ashlee M. Margheim<sup>2</sup> MD, Jeffrey P. Callen<sup>2</sup> MD, John D. Strickley<sup>2</sup> MD, Janine C. Malone<sup>2</sup> MD

Affiliations: <sup>1</sup>University of Kentucky College of Medicine, Bowling Green, Kentucky, USA, <sup>2</sup>Division of Dermatology, University of Louisville, Louisville, Kentucky, USA

Corresponding Author: John D. Strickley MD, 3810 Springhurst Boulevard, Suite 200 Louisville, KY 40241, Tel: 502-583-1749, Email: [jdstri02@gmail.com](mailto:jdstri02@gmail.com)

## Abstract

Lupus miliaris disseminatus faciei is a rare papular eruption primarily affecting the face, but extrafacial involvement can occur, which poses diagnostic challenges. We present a young woman with both facial and axillary involvement of lupus miliaris disseminatus faciei and review the literature to highlight less common extrafacial locations. Despite its rarity, lupus miliaris disseminatus faciei should be considered in the differential diagnosis of persistent papular eruptions. Histopathologic confirmation is essential, particularly in cases lacking facial involvement. Early recognition and treatment can minimize scarring, but a uniformly successful treatment option is lacking. Our report emphasizes the importance of biopsy to establish a diagnosis, especially in the absence of facial involvement given the misleading nature of the current nomenclature.

*Keywords: granulomatous dermatitis, histopathology, LMDF*

## Introduction

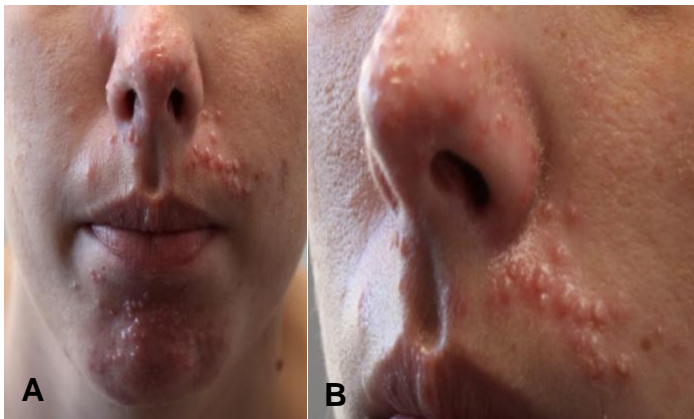A woman in her early thirties with no significant past medical history presented with a three-month history of a persistent, papular eruption on her face and axillae. Application of a topical corticosteroid following onset of the eruption led to no improvement. She denied taking any new medications, utilizing any new personal care

products, or having any recent infections prior to onset. She was otherwise asymptomatic.

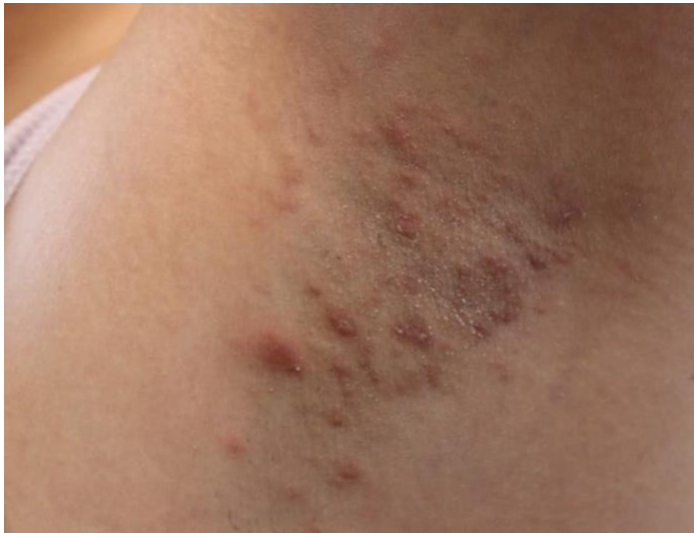## Case Synopsis

On examination, numerous erythematous to yellow-brown papules were noted involving the central face (**Figures 1A, B**) as well as the axillae (**Figure 2**). A punch biopsy of a lesion in the left axilla was performed which demonstrated well-delimited dermal nodules composed of degenerate collagen rimmed by histiocytic cells subjacent to an unremarkable epidermis (**Figures 3A, B**). No significant increase in neutrophils and dermal mucin was noted; Periodic acid-Schiff, Fite, and gram stains were negative for fungal forms, mycobacteria, and bacteria, respectively. The histopathologic findings were consistent with lupus miliaris disseminatus faciei (LMDF) involving the axilla. Laboratory evaluations, including C-reactive protein, erythrocyte sedimentation rate, antinuclear antibodies, extractable nuclear antigen panel, hepatitis B panel, lipid panel, and serum protein electrophoresis with immunofixation were all unremarkable. Our patient was started on tretinoin 0.1% cream without any appreciable benefit. She was subsequently prescribed minocycline 100mg twice daily, pimecrolimus 1% topical cream twice daily, and prednisone in a one-month taper. Despite this course of treatment, the patient continued to

develop new lesions and was ultimately lost to follow-up.



**Figure 1.** **A)** Numerous erythematous to yellow-brown papules noted involving the central face. **B)** Closer view of A.

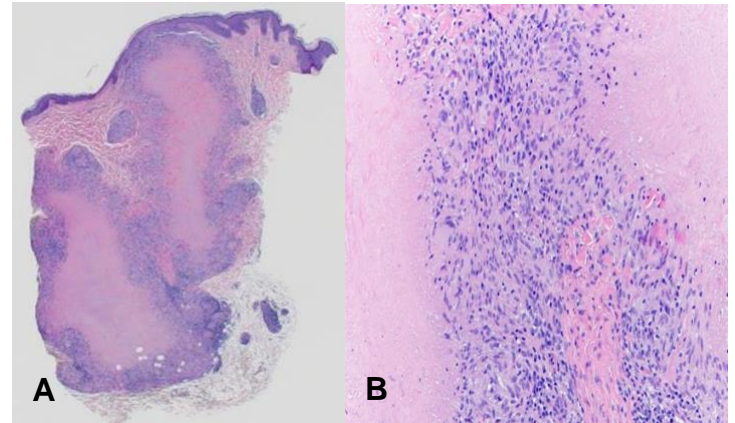


**Figure 2.** Additional inflammatory papules of left axilla.

## Case Discussion

Lupus miliaris disseminatus faciei is a relatively rare papular eruption of the face most often affecting young adults. The pathogenesis of LMDF is uncertain [1]. Lupus miliaris disseminatus faciei was first reported as disseminated follicular lupus in 1878 and acne agminata in 1903 [2,3,4]. Although previously thought to be related to tuberculosis or a variant of sarcoidosis, mycobacterium tuberculosis is not present within lesions and there is a lack of systemic disease [2]. Although there are some reports of using antitubercular medications for treatment, LMDF generally does not respond to this approach [4]. Another theory is that LMDF is a

granulomatous subtype of rosacea, but patients lack the more classic cutaneous signs of rosacea, including flushing and telangiectasias [3]. The current consensus is that LMDF is its own unique entity [4]. Therapies with variable therapeutic response include topical corticosteroids, topical retinoids, topical tacrolimus ointment, intralesional injection of corticosteroids, oral prednisone, tetracyclines, erythromycin, dapsone, and isotretinoin [2].

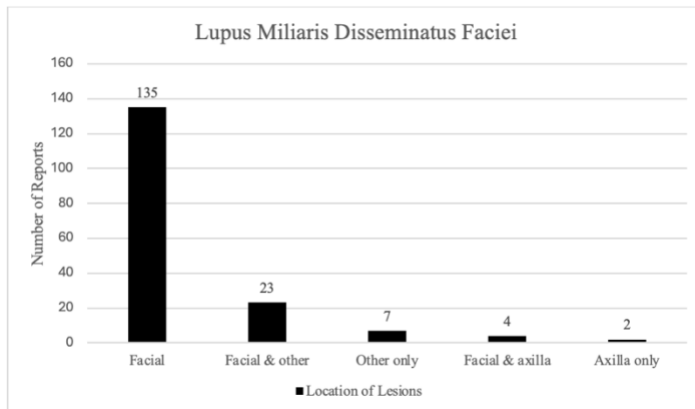


**Figure 3.** **A)** Low power view demonstrates well-delineated dermal nodules composed of degenerate collagen rimmed by histiocytic cells. **B)** Higher power view demonstrates a primarily lymphohistiocytic infiltrate. No significant increase in neutrophils or dermal mucin was noted.

This case is notable for the bilateral axillary involvement along with the characteristic facial findings. Lupus miliaris disseminatus faciei is uncommon and infrequently causes extrafacial lesions of the neck, torso, and/or axillae, as seen in our patient. Isolated axillary involvement without facial lesions has also been reported, highlighting the importance of histopathologic evaluation in establishing the diagnosis and emphasizing the misleading nature of the current nomenclature [5]. A review of the literature using PubMed found 171 cases of LMDF is evidenced in (**Figure 4**). Of the 7 cases lacking facial involvement, affected locations included the neck, chest, trunk, and/or upper extremity. Only four cases of axillary and facial involvement were found. Although the disease course is self-limiting with spontaneous resolution occurring between 12 to 24 months, patients are often left with disfiguring scars [1]. Early recognition and treatment can prevent or minimize scarring [4].

Given the increasing number of LMDF cases reported in extrafacial sites, some recent authors have suggested a more suitable name to be *lupus miliaris disseminatus* [2].

5. Kim WB, Mistry N. Lupus miliaris disseminatus faciei with isolated axillary involvement. *Journal of Cutaneous Medicine and Surgery*. 2016;20:153-154. [PMID: 26471742].



**Figure 4.** Number and location of lupus miliaris disseminatus faciei lesions.

## Conclusion

The nearly 200 cases of LMDF reported in the literature convey lack of a uniformly successful treatment for LMDF in addition to lack of controlled studies for the condition, both likely impacted by the tendency of LMDF to spontaneously resolve. Our report emphasizes nonfacial cutaneous involvement by LMDF and the importance of biopsy in establishing the diagnosis, especially if facial involvement is lacking. Early diagnosis of this potentially scarring condition would require a high index of clinical suspicion and subsequent histopathologic confirmation.

## Potential conflicts of interest

The authors declare no conflicts of interest.

## References

1. Gosch M, Larrondo J. Lupus miliaris disseminatus faciei. *JAMA Dermatology*. 2022;158:314. [PMID: 35044421].
2. Nemer KM, McGirt LY. Extrafacial lupus miliaris disseminatus. *JAAD Case Reports*. 2016;2:363-5. [PMID: 27699199].
3. Pruitt LG, Fowler, CO, Page RN, Coleman NM, King R. Extrafacial nuchal lupus miliaris disseminatus faciei. *JAAD Case Reports*. 2017;3:319-21. [PMID: 28752120].
4. Slater N, Sathe NC, Rapini RP. Lupus miliaris disseminatus faciei. In: *StatPearls*. StatPearls Publishing; 2024. [PMID: 32644491].