

# UCSF

## UC San Francisco Previously Published Works

### Title

Do Outcomes of Arthroscopic Subscapularis Tendon Repairs Depend on Rotator Cuff Fatty Infiltration?

### Permalink

<https://escholarship.org/uc/item/6k91r4t0>

### Journal

Orthopaedic journal of sports medicine, 8(4)

### ISSN

2325-9671

### Authors

Monroe, Emily J

Flores, Sergio E

Zhang, Alan L

et al.

### Publication Date

2020-04-01

### DOI

10.1177/2325967120913036

### Copyright Information

This work is made available under the terms of a Creative Commons Attribution-NonCommercial-NoDerivatives License, available at

<https://creativecommons.org/licenses/by-nc-nd/4.0/>

Peer reviewed

# Do Outcomes of Arthroscopic Subscapularis Tendon Repairs Depend on Rotator Cuff Fatty Infiltration?

Emily J. Monroe,<sup>\*†</sup> MD, Sergio E. Flores,<sup>‡</sup> BS, Alan L. Zhang,<sup>‡</sup> MD, Brian T. Feeley,<sup>‡</sup> MD, Drew A. Lansdown,<sup>‡</sup> MD, and C. Benjamin Ma,<sup>‡</sup> MD

*Investigation performed at University of California, San Francisco, San Francisco, California, USA*

**Background:** Rotator cuff fatty infiltration has been correlated with poorer radiographic and clinical outcomes in supraspinatus and infraspinatus tendon repairs, but this has not been well-studied in subscapularis tendon repairs.

**Purpose:** To evaluate the influence of preoperative rotator cuff fatty infiltration on postoperative outcomes for patients undergoing arthroscopic subscapularis tendon repair.

**Study Design:** Cohort study; Level of evidence, 3.

**Methods:** Patients who underwent arthroscopic subscapularis repair between 2010 and 2016 were retrospectively identified, and demographic data and surgical findings were recorded. The extent of fatty infiltration was determined on preoperative magnetic resonance imaging by the Fuchs modification of the Goutallier classification. At the most recent follow-up, patients completed the Patient-Reported Outcomes Measurement Information System for Upper Extremity (PROMIS-UE) computer adaptive test and a postoperative visual analog scale for pain. The distribution of fatty infiltration was compared between patients undergoing subscapularis tendon repair versus subscapularis tendon repair combined with a posterior cuff repair. Outcomes were compared for patients using Goutallier grade 0-1 versus grade  $\geq 2$  changes in each rotator cuff muscle. Multivariate linear regression analysis was performed to evaluate the influence of muscle quality, as well as demographic factors, on PROMIS-UE scores. Significance was defined as  $P < .05$ .

**Results:** There were 140 shoulders included (mean age, 61.8 years; 42.1% female; mean follow-up, 51.7 months). The prevalence of Goutallier grade 2 changes or higher was significantly greater in patients with multitendon repair relative to isolated subscapularis tendon repair. For the overall group of all patients undergoing subscapularis tendon repair, whether in isolation or as part of a multitendon repair, PROMIS-UE scores were significantly lower for patients with infraspinatus muscle grade 2 or higher Goutallier changes relative to grade 0 or 1. After adjustment for age, body mass index, patient sex, and fatty infiltration in other rotator cuff muscles, poor infraspinatus muscle quality remained the only significant predictor for lower PROMIS-UE scores.

**Conclusion:** Patients undergoing arthroscopic subscapularis tendon repair with poor infraspinatus muscle quality had worse patient-reported outcomes. This was true whether subscapularis tendon repair was isolated or was performed in conjunction with supraspinatus and infraspinatus tendon repairs.

**Keywords:** rotator cuff; subscapularis; fatty infiltration; PROMIS

Subscapularis (SSc) tendon tears are increasingly recognized and are present in up to half of all arthroscopic rotator cuff operations.<sup>4,7,25</sup> As the largest rotator cuff muscle and anterior portion of the rotator cuff force couple, the SSc is vital for maintaining glenohumeral stability and active shoulder motion.<sup>12,23,36,40</sup> SSc tendon repair techniques are emerging with encouraging results; however, the factors that may predict inferior outcomes after SSc tendon repair remain largely unknown.<sup>32,41</sup> Specifically, data regarding the role of rotator cuff muscle quality in outcomes after SSc tendon repair remain limited.

Rotator cuff tears are often accompanied by degradation in muscle quality, including fatty infiltration and atrophy.<sup>19,26,28,29</sup> Development of these muscular changes may be due to detachment of the musculotendinous unit with loss of passive tension.<sup>28,29</sup> Furthermore, muscle retraction may contribute to a neural traction injury.<sup>8</sup> Poor muscle quality, particularly fatty infiltration, is a negative predictor of tendon healing and functional outcomes after rotator cuff repair.<sup>26</sup>

The majority of literature on fatty infiltration has focused on the supraspinatus (SS) and infraspinatus (IS) muscles. Advanced fatty infiltration has been correlated with higher retear rates and lower patient-reported outcomes even in the setting of successful repair.<sup>16,19</sup> Studies of patients undergoing SSc tendon repair have suggested

The Orthopaedic Journal of Sports Medicine, 8(4), 2325967120913036  
DOI: 10.1177/2325967120913036  
© The Author(s) 2020

This open-access article is published and distributed under the Creative Commons Attribution - NonCommercial - No Derivatives License (<https://creativecommons.org/licenses/by-nc-nd/4.0/>), which permits the noncommercial use, distribution, and reproduction of the article in any medium, provided the original author and source are credited. You may not alter, transform, or build upon this article without the permission of the Author(s). For article reuse guidelines, please visit SAGE's website at <http://www.sagepub.com/journals-permissions>.

higher rates of retear with observed SSc muscle fatty infiltration<sup>15,27,33</sup> without necessarily inferior clinical outcomes.<sup>13,41</sup> However, these studies had a limited number of patients, with the largest including 103 patients.<sup>8</sup> Limited evidence is available regarding the influence of adjacent rotator cuff muscle quality on the outcomes after SSc tendon repair.

The purpose of this study was to evaluate the prevalence of fatty infiltration based on preoperative tear characteristics and to investigate the influence of fatty infiltration on postoperative outcomes after arthroscopic SSc tendon repair. We hypothesized that SSc muscle fatty infiltration would increase with larger preoperative tear sizes and that patient-reported outcomes would be significantly worse for patients with greater degrees of fatty infiltration.

## METHODS

After receiving institutional review board approval from the University of California, San Francisco (reference No. 14-14116), we used Current Procedural Terminology codes for rotator cuff surgery (29827, 23410, 23412, and 23420) to retrospectively identify patients who underwent rotator cuff surgery by 1 of 3 sports medicine fellowship-trained surgeons at our institution (A.L.Z., B.T.F., C.B.M.) between January 2010 and April 2016. Patients were included in the study if they were 18 years or older and underwent SSc tendon repair either in isolation or concurrent with other rotator cuff procedures. Patients were excluded if they underwent open SSc tendon repair, underwent a previous rotator cuff repair, or did not have preoperative magnetic resonance imaging (MRI) scans available for review.

All patients underwent preoperative evaluation by their treating surgeon. A diagnostic shoulder arthroscopy in the beach-chair position was performed for visualization of the shoulder abnormality. On the basis of the arthroscopic findings, SSc tendon tears were considered partial or complete. Partial tears included upper-half border and intrasubstance tears, both of which are routinely repaired at our institution. SSc tendon repair was achieved with single-row fixation with a single double-loaded anchor for partial tears and 2 double-loaded anchors for complete tears via an intra-articular technique. Sutures were passed via tissue penetrator in mattress fashion through the lower portions of the tendon and as a simple suture to secure the leading

edge. All surgeons used this surgical technique and method of fixation of the SSc tendon. SS tendon tears were categorized as partial-thickness versus full-thickness in the medial to lateral direction and partial-width versus full-width in the anterior to posterior direction based on the operative appearance. The repair technique for the posterior-superior rotator cuff repair included either simple, single-row or double-row, transosseous equivalent. Involvement of the IS tendon and need for IS tendon repair were also recorded.

Postoperatively, patients were immobilized in a shoulder abduction sling for 6 weeks. Physical therapy began within 1 to 2 weeks of surgery with initial limitations of passive external rotation to 30° for the first 6 weeks after surgery. Active motion was started at 6 weeks postoperatively, followed by progressive strength training at 3 months postoperatively and return to activities, in general, at 6 months after surgery.

The medical records were reviewed to determine patient age, sex, preoperative visual analog scale (VAS) pain score, intraoperative assessment of location and size of rotator cuff tears, and operative procedures. The preoperative MRI scan was examined by a fellowship-trained sports medicine physician (E.J.M.) for fatty infiltration in each rotator cuff muscle as graded by the Fuchs modification of the Goutallier classification (GC).<sup>16,19</sup> After initial grading, the results were condensed to simplified groups consisting of grades 0 to 1 and grades 2 or higher in each rotator cuff muscle. Slabaugh et al<sup>38</sup> demonstrated improved intra- and inter-observer reliability with this modification. Because our study was performed at a tertiary referral center, some MRI scans were accepted from outside institutions; the location and field strength of each study were recorded.

At the latest follow-up, consenting patients completed postoperative VAS pain scores, as well as the Patient-Reported Outcomes Measurement Information System for Upper Extremity (PROMIS-UE). PROMIS-UE is a computer adaptive test designed to use patient answers to survey questions to guide subsequent questions, thus collecting data in an efficient manner. All PROMIS instruments are calibrated to a mean score of 50 for the normal population with a standard deviation of 10 to minimize floor and ceiling effects.<sup>9</sup> PROMIS-UE has been validated for use in evaluation of patients with rotator cuff tears and has demonstrated good correlation with legacy measures including American Shoulder and Elbow Surgeons and Simple Shoulder Test scores.<sup>1,35</sup>

<sup>8</sup>References 5, 6, 13, 15, 20, 21, 25, 27, 33, 37, 41.

\*Address correspondence to Emily J. Monroe, MD, Heartland Orthopedic Specialists, 111 17th Ave E, Suite 101, Alexandria, MN 56308, USA (email: bran0569@gmail.com).

<sup>†</sup>Heartland Orthopedic Specialists, Alexandria, Minnesota, USA.

<sup>‡</sup>Department of Orthopaedic Surgery, University of California, San Francisco, San Francisco, California, USA.

Final revision submitted August 15, 2019; accepted August 20, 2019

One or more of the authors has declared the following potential conflict of interest of source of funding: E.J.M. has received educational support from Arthrex and Gemini Medical and hospitality payments from Stryker. A.L.Z. has received consulting fees from Stryker and hospitality payments from Arthrex and Zimmer Biomet. B.T.F. has received hospitality payments from Zimmer Biomet. D.A.L. has received grant support from Arthrex; educational support from Arthrex, Smith & Nephew, and Medwest; and hospitality payments from Wright Medical. C.B.M. has received grant support from Zimmer Biomet, Histogenics, and Samumed; speaking fees from Zimmer Biomet; consulting fees from Zimmer Biomet, Linvatec, Wright Medical, Stryker, and Medacta; and hospitality payments from Arthrex. AOSSM checks author disclosures against the Open Payments Database (OPD). AOSSM has not conducted an independent investigation on the OPD and disclaims any liability or responsibility relating thereto.

Ethical approval for this study was obtained from the University of California, San Francisco, Institutional Review Board (reference No. 14-14116).

TABLE 1  
Overall Cohort Demographics, Outcome Scores, and Rotator Cuff Tear Characteristics (N = 140)<sup>a</sup>

Parameter	Finding
Age, y, mean ± SD	61.8 ± 9.9
Follow-up, mo, mean ± SD	51.7 ± 19.5
Female, n (%)	59 (42.1)
PROMIS-UE score (95% CI)	50.7 (49.4-52.0)
Preoperative VAS pain score (95% CI)	4.8 (4.4-5.2)
Postoperative VAS pain score (95% CI)	0.8 (0.6-1.1)
Complete SSc tendon tear, n (%)	34 (24.3)
Tendon tear pattern, n (%)	
Partial SSc tear with SS and/or IS repair	65 (46.4)
Partial isolated SSc tear	41 (29.3)
Complete SSc tear with SS and/or IS repair	25 (17.9)
Complete isolated SSc tear	9 (6.4)

<sup>a</sup>IS, infraspinatus; PROMIS-UE, Patient-Reported Outcomes Measurement Information System for Upper Extremity; SS, supraspinatus; SSc, subscapularis; VAS, visual analog scale.

For statistical analysis, we compared preoperative variables and outcomes between isolated SSc tendon repair and SSc tendon combined with posterior cuff repairs. Categorical variables were compared with Fisher exact tests. Outcome scores were found to be nonnormally distributed using the Shapiro-Wilk test. The Wilcoxon signed rank test was used to compare preoperative and postoperative VAS pain scores. Mann-Whitney *U* tests were used to compare PROMIS-UE scores between the simplified GC (grade 0-1 vs grade ≥2). A multivariate linear regression model was performed to predict PROMIS-UE scores as a function of patient demographic factors and individual muscle quality. Statistical analysis was performed using Stata software (v 14.2; StataCorp). Significance was defined as *P* < .05.

## RESULTS

Of 237 qualifying patients, 145 patients consented to participate, 35 declined, 4 were deceased, and 53 were unreachable. Of the 145 participants who provided consent, a preoperative MRI scan was not available for 5 patients; thus, a total of 140 patients (140 shoulders) were included in the analysis for a 59.1% response rate. The majority (65%) of imaging studies were performed at our institution. Regarding field strength, 67% of imaging studies were performed with a 3.0-T magnet; 28%, with a 1.5-T magnet; and 5%, with a < 1.0-T magnet. Demographics, overall outcomes, SSc tendon tear types, and prevalence of concomitant SS and/or IS tendon injury of the cohort are shown in Table 1. Patients with isolated SSc tendon repair were significantly younger compared with patients who had multitendon repairs (57.2 vs 64.3 years; *P* < .0001). Significant improvements were seen in VAS pain scores (*P* < .001) (Table 1). We found that 90 patients (64.3%) had concurrent SS tendon repair; of these, 14 patients (10.0% of the total cohort) underwent IS tendon repair.

The prevalence of GC grade 2 change or higher was significantly greater in patients with multitendon repair relative to isolated SSc tendon repair for the SSc (*P* = .008), SS

TABLE 2  
Preoperative Goutallier Classification Comparing Patients Undergoing Isolated Subscapularis Tendon Repair Versus Patients Undergoing Subscapularis Tendon Repair With a Concomitant Posterior Cuff Repair<sup>a</sup>

Muscle	Goutallier Classification	Isolated SSc Tendon Repair, % (n = 50)	SSc With SS and/or IS Tendon Repair, % (n = 90)	<i>P</i> Value
		Supraspinatus	0-1 ≥2	
Infraspinatus	0-1 ≥2	86.0 14.0	65.6 34.4	<b>.010</b>
Subscapularis	0-1 ≥2	82.0 18.0	60.0 40.0	<b>.008</b>
Teres minor	0-1 ≥2	82.0 18.0	78.9 21.1	.826

<sup>a</sup>Bolded values indicate statistical significance (*P* < .05). IS, infraspinatus; SS, supraspinatus; SSc, subscapularis.

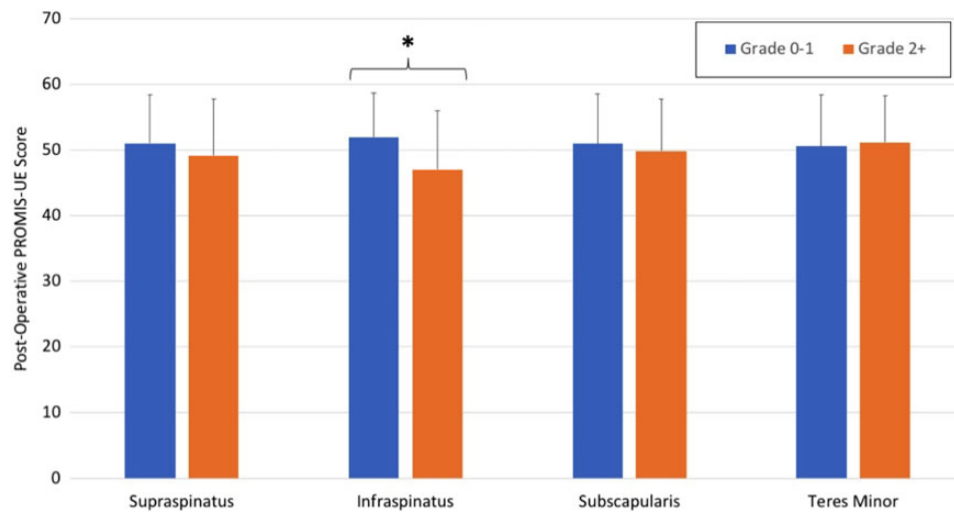
(*P* = .001), and IS (*P* = .01) muscles (Table 2). Interestingly, even in the group with isolated SSc tendon repair, 7 patients (14.0%) had GC grade ≥ 2 changes in the IS muscle. No difference in muscle quality was observed between shoulders with partial or complete SSc tendon tears for the SSc (*P* = .211), SS (*P* = .102), IS (*P* = .507), or teres minor (TM) muscle (*P* = .465).

For the overall cohort of patients undergoing SSc tendon repair with or without SS and/or IS tendon repair, the postoperative PROMIS-UE score was significantly lower for patients with IS muscle grade 2 or higher GC changes relative to grade 0 or 1 GC changes (*P* = .0015) (Figure 1). No difference was observed in postoperative PROMIS-UE scores for SSc (*P* = .35), SS (*P* = .24), or TM (*P* = .76) muscle quality.

Controlling for age, body mass index, patient sex, and fatty infiltration of other rotator cuff muscles, we found that IS muscle GC grade 2 or higher remained a significant negative predictor (*P* = .003) for postoperative PROMIS-UE score for patients undergoing rotator cuff repair involving the SSc tendon (Table 3). Patients with SSc muscle GC grade 2 or higher had higher levels of postoperative VAS pain (*P* = .0153), but no differences were observed between different grades of fatty infiltration in SS (*P* = .1758), IS (*P* = .3075), or TM (*P* = .6207) muscle.

## DISCUSSION

In patients undergoing SSc tendon repairs, the muscle quality of the IS had the greatest influence on postoperative patient-reported outcome scores. Specifically, the presence of grade 2 or higher GC changes in the IS muscle was independently associated with an inferior PROMIS-UE score after rotator cuff repair. This finding was also true for patients with isolated SSc tendon tears and no involvement of the posterosuperior rotator cuff. More advanced fatty infiltration (GC grade ≥2) was seen more frequently with



**Figure 1.** Postoperative scores for the Patient-Reported Outcomes Measurement Information System for Upper Extremity (PROMIS-UE) are shown for each muscle of the rotator cuff and compared between patients with preoperative Goutallier grade 0-1 changes versus patients with preoperative Goutallier grade  $\geq 2$  changes. Patients with infraspinatus muscle changes of grade  $\geq 2$  had significantly inferior PROMIS-UE scores (asterisk indicates  $P = .0015$ ).

**TABLE 3**  
Goutallier Classification Grade  $\geq 2$  a Significant Negative Predictor for Postoperative PROMIS-UE Score<sup>a</sup>

Muscle	Beta Coefficient	95% CI	P Value
Supraspinatus GC $\geq 2$	0.9	-2.7 to 4.5	.620
Infraspinatus GC $\geq 2$	-5.1	-8.4 to -1.8	.003
Subscapularis GC $\geq 2$	-0.9	-3.8 to 1.9	.511
Teres minor GC $\geq 2$	1.3	-1.9 to 4.6	.432

<sup>a</sup>Relative to normal muscle (Goutallier classification [GC] 0-1) and in multivariate linear regression with age, body mass index, tendons repaired, and patient sex, an infraspinatus muscle GC grade  $\geq 2$  was a significant negative predictor for postoperative score on the Patient-Reported Outcomes Measurement Information System for Upper Extremity (PROMIS-UE).

more extensive rotator cuff tears; however, these advanced changes were evident in the IS muscle for 14% of patients with isolated SSc tendon tears.

In absence of tendon continuity, particularly within the rotator cuff, muscle degeneration can develop.<sup>24</sup> In the SS and IS, muscle atrophy and fatty infiltration have been linked to persistent muscle changes, higher rates of postoperative retear, and poorer subjective clinical outcomes.<sup>16,17,19</sup> Further, neighboring unrotated rotator cuff muscles may develop degenerative changes.<sup>3</sup> These findings have been less reliably demonstrated in the SSc muscle. The majority of studies have found no progression of fatty infiltration after repair of SSc tendon<sup>5,6,25</sup>; however, Grueninger et al<sup>20,21</sup> demonstrated significant improvements in SSc muscle fatty infiltration. After SSc tendon repair, higher retear rates have been correlated with higher grades of fatty infiltration<sup>15,27,33</sup> and, in some cases, larger tears.<sup>5</sup> In contrast, SSc muscle quality with worse

preoperative grade of fatty infiltration has not been correlated with poorer clinical outcomes.<sup>13,41</sup> However, many of these studies were limited by small numbers while examining multiple variables, and the role of muscle quality in SSc tendon repair remains undefined.

Similar to previous reports, the current study found that postoperative outcome scores were related to preoperative muscle quality. For example, Ohzono et al<sup>34</sup> examined a group of patients with intact tendons after rotator cuff repair and found that GC grade 2 or higher in SSc or IS muscle was associated with an unsatisfactory outcome after surgery. Godeneche et al<sup>18</sup> similarly found that patients with GC grade 1 or higher in the SS muscle preoperatively had lower Constant scores at 10-year follow-up. Specifically, however, the IS muscle quality had the greatest influence on outcomes in the present study. Although all patients in this cohort had SSc tendon tears, the SSc muscle quality was not associated with final outcome or with the size of the SSc tendon tear. In previous reports, SS and IS muscle fatty infiltration was worse with increasing tear size.<sup>10,28,29</sup> Interestingly, IS muscle fatty infiltration can occur in the absence of an IS tendon tear,<sup>10</sup> which we also found to be true in our group. Further, advanced changes in IS muscle quality were seen even in isolated SSc tendon tears.

The IS and SSc muscles are balancing forces across the shoulder that keep the humeral head compressed and centered on the glenoid as part of a transverse force couple mechanism.<sup>14</sup> Even in the presence of an irreparable SS tendon tear, shoulder function can be maintained. A rat study examining the effect of SS and IS tendon detachment followed by no repair, full repair, or isolated IS tendon repair found similar kinetic abilities between animals with either a full repair or an isolated IS tendon repair.<sup>22</sup> Similarly, partial repair of rotator cuff tears in clinical series has shown some promise in restoring shoulder function.<sup>42</sup>

Although more commonly reported for the posterosuperior cuff involving massive tears of the SS and IS tendons, restoration of shoulder function has similarly been demonstrated in a small series where isolated repair of the SSc tendon in the setting of irreparable posterosuperior tears led to significant improvement in subjective shoulder symptoms and ability to lift the arm above shoulder level.<sup>2</sup> With the important interplay between the IS and SSc muscles, it is perhaps unsurprising that poorer muscle quality of the IS negatively influences the force couple, thus affecting shoulder function after repair of the SSc tendon. Unexpectedly, however, worsening muscle quality of the SSc muscle itself was not statistically associated with inferior clinical outcomes. Although SSc muscle quality was not associated with worse outcomes, patients with poor IS muscle quality had worse patient-reported outcomes in the setting of SSc tendon repair whether isolated or in conjunction with SS and/or IS tendon repairs. This may be because of overall degeneration of the muscle about the shoulder or loss of the force couple. The results highlight the importance of evaluating the IS muscle quality, even for patients with an isolated SSc tendon tear. In cases of SS or SSc muscle fatty infiltration but preserved IS muscle quality, patients may still achieve acceptable postoperative outcomes after rotator cuff repair.

We were limited by the retrospective nature of the study, as we did not have preoperative functional outcome scores to compare with preoperative imaging studies or to provide comparison with our postoperative data. Additionally, although MRI quality was satisfactory overall, differences in reconstructions and techniques may have limited the ability to accurately measure fatty infiltration and thus may have influenced results. Postoperative imaging was not routinely obtained, so we were unable to determine retear rate or evaluate progression of muscle degeneration. Although a traditional classification system for SSc tendon tears was not used, the Lafosse and Lyons systems have demonstrated poor interobserver reliability, so we used a simplified description of tears.<sup>39</sup> Although the GC in its original description has moderate intra- and interobserver reliability, modifying it to group together more severe fatty infiltration may improve these measures.<sup>38</sup> IS tendon tears were not specifically separated in our analysis. Intraoperatively, these tendons are often difficult to distinguish, and anatomic studies defining their insertion points have acknowledged the interdigitation and overlap of the insertion points that can be separated only with meticulous dissection.<sup>11,30,31</sup> For these reasons, repairs of the SS and IS tendons were considered together in our analysis. We used a convenience sample of all available SSc tendon repairs to maximize our sample size and thus did not perform an a priori power analysis. Our study may be underpowered to detect statistical difference, although the nonsignificant difference between groups was not close to reaching clinical importance.

## CONCLUSION

We observed more advanced preoperative fatty infiltration in multitendon tears in a large cohort of patients

undergoing SSc tendon repair. This finding was not necessarily correlated with worse patient-reported outcomes, as only those patients with poor IS muscle quality experienced significantly worse outcomes after SSc repair whether isolated or in combination with a posterior cuff repair. Poor SSc muscle quality was not associated with worse postoperative patient-reported outcome scores. IS muscle quality seems to have the strongest influence on postoperative outcomes and should be carefully evaluated preoperatively even in the absence of SS or IS tendon tear.

## ACKNOWLEDGMENT

The authors acknowledge Mya Sandi Aung and Kristina R. Borak for their assistance with data acquisition.

## REFERENCES

1. Anthony CA, Glass NA, Hancock K, Bollier M, Wolf BR, Hettrich CM. Performance of PROMIS instruments in patients with shoulder instability. *Am J Sports Med.* 2017;45(2):449-453.
2. Austin L, Chang ES, Zmistowski B, Nydick J, Lazarus M. Isolated subscapularis repair for massive rotator cuff tear. *Orthopedics.* 2014;37(11):e962-e967.
3. Barry JJ, Lansdown DA, Cheung S, Feeley BT, Ma CB. The relationship between tear severity, fatty infiltration, and muscle atrophy in the supraspinatus. *J Shoulder Elbow Surg.* 2013;22(1):18-25.
4. Barth JR, Burkhart SS, De Beer JF. The bear-hug test: a new and sensitive test for diagnosing a subscapularis tear. *Arthroscopy.* 2006;22(10):1076-1084.
5. Bartl C, Salzmann GM, Seppel G, et al. Subscapularis function and structural integrity after arthroscopic repair of isolated subscapularis tears. *Am J Sports Med.* 2011;39(6):1255-1262.
6. Bartl C, Senftl M, Eichhorn S, Holzapfel K, Imhoff A, Salzmann G. Combined tears of the subscapularis and supraspinatus tendon: clinical outcome, rotator cuff strength and structural integrity following open repair. *Arch Orthop Trauma Surg.* 2012;132(1):41-50.
7. Bennett WF. Arthroscopic repair of isolated subscapularis tears: a prospective cohort with 2- to 4-year follow-up. *Arthroscopy.* 2003;19(2):131-143.
8. Boykin RE, Friedman DJ, Higgins LD, Warner JJ. Suprascapular neuropathy. *J Bone Joint Surg Am.* 2010;92(13):2348-2364.
9. Brodke DJ, Saltzman CL, Brodke DS. PROMIS for orthopaedic outcomes measurement. *J Am Acad Orthop Surg.* 2016;24(11):744-749.
10. Cheung S, Dillon E, Tham SC, et al. The presence of fatty infiltration in the infraspinatus: its relation with the condition of the supraspinatus tendon. *Arthroscopy.* 2011;27(4):463-470.
11. Clark JM, Harryman DT II. Tendons, ligaments, and capsule of the rotator cuff: gross and microscopic anatomy. *J Bone Joint Surg Am.* 1992;74(5):713-725.
12. Collin P, Matsumura N, Ladermann A, Denard PJ, Walch G. Relationship between massive chronic rotator cuff tear pattern and loss of active shoulder range of motion. *J Shoulder Elbow Surg.* 2014;23(8):1195-1202.
13. Edwards TB, Walch G, Sirveaux F, et al. Repair of tears of the subscapularis. *J Bone Joint Surg Am.* 2005;87(4):725-730.
14. Espinosa-Urbe AG, Negreros-Osuna AA, Gutiérrez-de la O J, et al. An age- and gender-related three-dimensional analysis of rotator cuff transverse force couple volume ratio in 304 shoulders. *Surg Radiol Anat.* 2017;39(2):127-134.
15. Flury MP, John M, Goldhahn J, Schwyzer HK, Simmen BR. Rupture of the subscapularis tendon (isolated or in combination with supraspinatus tear): when is a repair indicated? *J Shoulder Elbow Surg.* 2006;15(6):659-664.

16. Fuchs B, Weishaupt D, Zanetti M, Hodler J, Gerber C. Fatty degeneration of the muscles of the rotator cuff: assessment by computed tomography versus magnetic resonance imaging. *J Shoulder Elbow Surg.* 1999;8(6):599-605.
17. Gladstone JN, Bishop JY, Lo IK, Flatow EL. Fatty infiltration and atrophy of the rotator cuff do not improve after rotator cuff repair and correlate with poor functional outcome. *Am J Sports Med.* 2007;35(5):719-728.
18. Godeneche A, Elia F, Kempf JF, et al. Fatty infiltration of stage 1 or higher significantly compromises long-term healing of supraspinatus repairs. *J Shoulder Elbow Surg.* 2017;26(10):1818-1825.
19. Goutallier D, Postel JM, Bernageau J, Lavau L, Voisin MC. Fatty muscle degeneration in cuff ruptures: pre- and postoperative evaluation by CT scan. *Clin Orthop Relat Res.* 1994;304:78-83.
20. Grueninger P, Nikolic N, Schneider J, et al. Arthroscopic repair of traumatic isolated subscapularis tendon lesions (Lafosse type III or IV): a prospective magnetic resonance imaging-controlled case series with 1 year of follow-up. *Arthroscopy.* 2014;30(6):665-672.
21. Grueninger P, Nikolic N, Schneider J, et al. Arthroscopic repair of massive cuff tears with large subscapularis tendon ruptures (Lafosse III/IV): a prospective magnetic resonance imaging-controlled case series of 26 cases with a minimum follow-up of 1 year. *Arthroscopy.* 2015;31(11):2173-2182.
22. Hsu JE, Reuther KE, Sarver JJ, et al. Restoration of anterior-posterior rotator cuff force balance improves shoulder function in a rat model of chronic massive tears. *J Orthop Res.* 2011;29(7):1028-1033.
23. Keating JF, Waterworth P, Shaw-Dunn J, Crossan J. The relative strengths of the rotator cuff muscles: a cadaver study. *J Bone Joint Surg Br.* 1993;75(1):137-140.
24. Kim HM, Dahiya N, Teefey SA, Keener JD, Galatz LM, Yamaguchi K. Relationship of tear size and location to fatty degeneration of the rotator cuff. *J Bone Joint Surg Am.* 2010;92(4):829-839.
25. Lafosse L, Jost B, Reiland Y, Audebert S, Toussaint B, Gobezie R. Structural integrity and clinical outcomes after arthroscopic repair of isolated subscapularis tears. *J Bone Joint Surg Am.* 2007;89(6):1184-1193.
26. Lansdown DA, Lee S, Sam C, Krug R, Feeley BT, Ma CB. A prospective, quantitative evaluation of fatty infiltration before and after rotator cuff repair. *Orthop J Sports Med.* 2017;5(7):2325967117718537.
27. Lanz U, Fullick R, Bongiorno V, Saintmard B, Campens C, Lafosse L. Arthroscopic repair of large subscapularis tendon tears: 2- to 4-year clinical and radiographic outcomes. *Arthroscopy.* 2013;29(9):1471-1478.
28. Melis B, DeFranco MJ, Chuinard C, Walch G. Natural history of fatty infiltration and atrophy of the supraspinatus muscle in rotator cuff tears. *Clin Orthop Relat Res.* 2010;468(6):1498-1505.
29. Melis B, Wall B, Walch G. Natural history of infraspinatus fatty infiltration in rotator cuff tears. *J Shoulder Elbow Surg.* 2010;19(5):757-763.
30. Minagawa H, Itoi E, Konno N, et al. Humeral attachment of the supraspinatus and infraspinatus tendons: an anatomic study. *Arthroscopy.* 1998;14(3):302-306.
31. Mochizuki T, Sugaya H, Uomizu M, et al. Humeral insertion of the supraspinatus and infraspinatus: new anatomical findings regarding the footprint of the rotator cuff. *J Bone Joint Surg Am.* 2008;90(5):962-969.
32. Monroe EJ, Flores SE, Chambers CC, et al. Patient-reported outcomes after isolated and combined arthroscopic subscapularis tendon repairs. *Arthroscopy.* 2019;35(6):1779-1784.
33. Nove-Josserand L, Collin P, Godeneche A, et al. Ten-year clinical and anatomic follow-up after repair of anterosuperior rotator cuff tears: influence of the subscapularis. *J Shoulder Elbow Surg.* 2017;26(10):1826-1833.
34. Ohzono H, Gotoh M, Nakamura H, et al. Effect of preoperative fatty degeneration of the rotator cuff muscles on the clinical outcome of patients with intact tendons after arthroscopic rotator cuff repair of large/massive cuff tears. *Am J Sports Med.* 2017;45(13):2975-2981.
35. Patterson BM, Orvets ND, Aleem AW, et al. Correlation of Patient-Reported Outcomes Measurement Information System (PROMIS) scores with legacy patient-reported outcome scores in patients undergoing rotator cuff repair. *J Shoulder Elbow Surg.* 2018;27(6)(suppl):S17-S23.
36. Perry J. Anatomy and biomechanics of the shoulder in throwing, swimming, gymnastics, and tennis. *Clin Sports Med.* 1983;2(2):247-270.
37. Rhee YG, Lee YS, Park YB, Kim JY, Han KJ, Yoo JC. The outcomes and affecting factors after arthroscopic isolated subscapularis tendon repair. *J Shoulder Elbow Surg.* 2017;26(12):2143-2151.
38. Slabaugh MA, Friel NA, Karas V, Romeo AA, Verma NN, Cole BJ. Interobserver and intraobserver reliability of the Goutallier classification using magnetic resonance imaging: proposal of a simplified classification system to increase reliability. *Am J Sports Med.* 2012;40(8):1728-1734.
39. Smucny M, Shin EC, Zhang AL, et al. Poor agreement on classification and treatment of subscapularis tendon tears. *Arthroscopy.* 2016;32(2):246-251.e241.
40. Su WR, Budoff JE, Luo ZP. The effect of anterosuperior rotator cuff tears on glenohumeral translation. *Arthroscopy.* 2009;25(3):282-289.
41. Toussaint B, Audebert S, Barth J, et al. Arthroscopic repair of subscapularis tears: preliminary data from a prospective multicentre study. *Orthop Traumatol Surg Res.* 2012;98(8)(suppl):S193-S200.
42. Wellmann M, Lichtenberg S, da Silva G, Magosch P, Habermeyer P. Results of arthroscopic partial repair of large retracted rotator cuff tears. *Arthroscopy.* 2013;29(8):1275-1282.