

# UCLA

## UCLA Previously Published Works

### Title

Monkeypox in pregnancy: virology, clinical presentation, and obstetric management.

### Permalink

<https://escholarship.org/uc/item/6jv5q8qb>

### Journal

American Journal of Obstetrics & Gynecology, 227(6)

### Authors

Dashraath, Pradip

Nielsen-Saines, Karin

Rimoin, Anne

et al.

### Publication Date

2022-12-01

### DOI

10.1016/j.ajog.2022.08.017

Peer reviewed



Elsevier has created a [Monkeypox Information Center](#) in response to the declared public health emergency of international concern, with free information in English on the monkeypox virus. The Monkeypox Information Center is hosted on Elsevier Connect, the company's public news and information website.

Elsevier hereby grants permission to make all its monkeypox related research that is available on the Monkeypox Information Center - including this research content - immediately available in publicly funded repositories, with rights for unrestricted research re-use and analyses in any form or by any means with acknowledgement of the original source. These permissions are granted for free by Elsevier for as long as the Monkeypox Information Center remains active.

# Monkeypox in pregnancy: virology, clinical presentation, and obstetric management

Pradip Dashraath, MRCOG; Karin Nielsen-Saines, MD; Anne Rimoin, PhD; Citra N.Z. Mattar, PhD; Alice Panchaud, PhD; David Baud, PhD

## Introduction

The global outbreak of human monkeypox—caused by the double-stranded DNA monkeypox virus (MPXV)—was declared a public health emergency of international concern by the World Health Organization (WHO) on July 23, 2022. As of September 7, 2022, the outbreak has resulted in 56,026 laboratory-confirmed infections from 95 nonendemic countries.<sup>1</sup> Epidemiologic observations from the ongoing outbreak

From the Division of Maternal-Fetal Medicine, Department of Obstetrics and Gynecology, National University Hospital, Singapore (Drs Dashraath and Mattar); Yong Loo Lin School of Medicine, National University of Singapore, Singapore (Drs Dashraath and Mattar); Division of Pediatric Infectious Diseases, Department of Pediatrics, David Geffen School of Medicine, University of California Los Angeles, Los Angeles, CA (Dr Nielsen-Saines); Fielding School of Public Health, David Geffen School of Medicine, University of California Los Angeles, Los Angeles, CA (Dr Rimoin); University of California Los Angeles—Democratic Republic of the Congo Health Research and Training Program, Kinshasa, Democratic Republic of the Congo (Dr Rimoin); Institute of Primary Health Care (BIHAM), University of Bern, Bern, Switzerland (Dr Panchaud); and Materno-fetal and Obstetrics Research Unit, Department Woman-Mother-Child, Lausanne University Hospital, Lausanne, Switzerland (Dr Baud).

Received July 11, 2022; revised Aug. 11, 2022; accepted Aug. 11, 2022.

The authors report no conflict of interest.

A.R. is Director of the affiliated University of California, Los Angeles—Democratic Republic of the Congo (UCLA-DRC) Health Research and Training Program in the Democratic Republic of the Congo. This work did not receive any funding.

Corresponding author: Pradip Dashraath, MRCOG. [pradip\\_dashraath@nuhs.edu.sg](mailto:pradip_dashraath@nuhs.edu.sg)

0002-9378/\$36.00

© 2022 Elsevier Inc. All rights reserved.

<https://doi.org/10.1016/j.ajog.2022.08.017>

 Click Supplemental Materials and Video under article title in Contents at [ajog.org](https://ajog.org)

The 2022 monkeypox outbreak, caused by the zoonotic monkeypox virus, has spread across 6 World Health Organization regions (the Americas, Africa, Europe, Eastern Mediterranean, Western Pacific, and South-East Asia) and was declared a public health emergency of international concern on July 23, 2022. The global situation is especially concerning given the atypically high rate of person-to-person transmission, which suggests viral evolution to an established human pathogen. Pregnant women are at heightened risk of vertical transmission of the monkeypox virus because of immune vulnerability and natural depletion of population immunity to smallpox among reproductive-age women, and because orthopoxviral cell entry mechanisms can overcome the typically viral-resistant syncytiotrophoblast barrier within the placenta. Data on pregnancy outcomes following monkeypox infection are scarce but include reports of miscarriage, intrauterine demise, preterm birth, and congenital infection. This article forecasts the issues that maternity units might face and proposes guidelines to protect the health of pregnant women and fetuses exposed to the monkeypox virus. We review the pathophysiology and clinical features of monkeypox infection and discuss the obstetrical implications of the unusually high prevalence of anogenital lesions. We describe the use of real-time polymerase chain reaction tests from mucocutaneous and oropharyngeal sites to confirm infection, and share an algorithm for the antenatal management of pregnant women with monkeypox virus exposure. On the basis of the best available knowledge from prenatal orthopoxvirus infections, we discuss the sonographic features of congenital monkeypox and the role of invasive testing in establishing fetal infection. We suggest a protocol for cesarean delivery to avoid the horizontal transmission of the monkeypox virus at birth and address the controversy of mother—infant separation in the postpartum period. Obstetrical concerns related to antiviral therapy with tecovirimat and vaccinia immune globulin are highlighted, including the risks of heart rate—corrected QT-interval prolongation, inaccuracies in blood glucose monitoring, and the predisposition to iatrogenic venous thromboembolism. The possibility of monkeypox vaccine hesitancy during pregnancy is discussed, and strategies are offered to mitigate these risks. Finally, we conclude with a research proposal to address knowledge gaps related to the impact of monkeypox infection on maternal, fetal, and neonatal health.

**Key words:** ACAM2000, antiviral, chickenpox, cidofovir, COVID-19, cowpox, emerging pathogen, miscarriage, monkeypox, MVA-BN, obstetrical management, orthopoxvirus, outbreak, pregnancy, rash, sexual transmission, smallpox, tecovirimat, vaccine, vaccinia immune globulin, vaccinia virus, varicella-zoster, vertical transmission, World Health Organization, zoonosis

suggest a high rate of person-to-person transmission of MPXV clade IIb (the formerly designated “West African” clade)<sup>2,3</sup> through close physical contact, including during oral, anal, and vaginal intercourse.<sup>4</sup>

Although the outbreak has disproportionately affected gay and bisexual men, MPXV infection is neither confined by gender nor sexual orientation and will likely be reported in

pregnancies with time and heightened disease surveillance. We believe pregnant women and their fetuses are especially vulnerable for 3 reasons.

First, the attenuation of cell-mediated immunity by T-helper 1 (Th1) cells because of the physiological shift to a Th2-dominant environment in pregnancy increases maternal susceptibility to viral infections.<sup>5</sup> Th1 cytokines, including type 1 interferon (IFN), inhibit viral replication

through direct antiviral and indirect immunoregulatory activities by binding to widely expressed heterodimeric receptors on cell surfaces.<sup>6</sup> MPXV, however, expresses soluble IFN $\alpha$ / $\beta$ -binding proteins, which interfere with IFN signaling pathways and broadly inhibit antiviral responses in the host.<sup>6</sup> We therefore hypothesize that the combination of a gestational bias toward Th2 dominance and IFN evasion by MPXV-induced binding proteins could mediate both susceptibility and enhanced virulence from monkeypox infection in pregnancy.

Second, the eradication of smallpox (a closely related *Orthopoxvirus*) and cessation of the global smallpox vaccination program in 1980 created a niche for monkeypox because of waning population immunity: MPXV infections in Africa have increased at least 10-fold since 1970.<sup>7</sup> The median age at diagnosis has also increased since vaccinations ended, from young children (4 years) in 1970 to young adults (21 years) from 2010 to 2019.<sup>7</sup> This trend is reflected in the current 2022 outbreak, with men with a median age of 36 (interquartile range, 31–43 years) comprising the group with the highest number of infections.<sup>8</sup> Taken together, women presently of reproductive age—defined as 15 to 49 years by WHO<sup>9</sup>—and who are thus unimmunized are at considerable risk of acquiring monkeypox because they lack cross-protective immunity.

Third, vertical transmission and pregnancy loss have been described following MPXV infection.<sup>10,11</sup> Cross-border transmission of monkeypox within populations with no previous immunity and among immunocompromised individuals (at least 41% of cases in the current outbreak are HIV-positive<sup>8</sup>) may allow MPXV to acquire mutations that increase virulence and the chance of sustained spread. Monkeypox could thus evolve from a regionally limited zoonosis to a globally endemic infectious disease.<sup>8,12</sup> Pregnancies, particularly in low- and middle-income countries, could then be at risk, aggravated by the reality that 89% of the estimated 213 million pregnancies yearly occur in resource-limited settings with the highest probability of poor obstetrical and perinatal outcomes.<sup>13</sup>

This article describes the virology and clinical characteristics of monkeypox infection and discusses the disease's vertical transmission potential and management in pregnant women. Where gaps exist, we compare the similarities between monkeypox and other infections and draw on lessons learned from past epidemics. We believe this analysis is essential for developing the principles of obstetrical care for pregnant women at risk of MPXV exposure.

### Pathogen

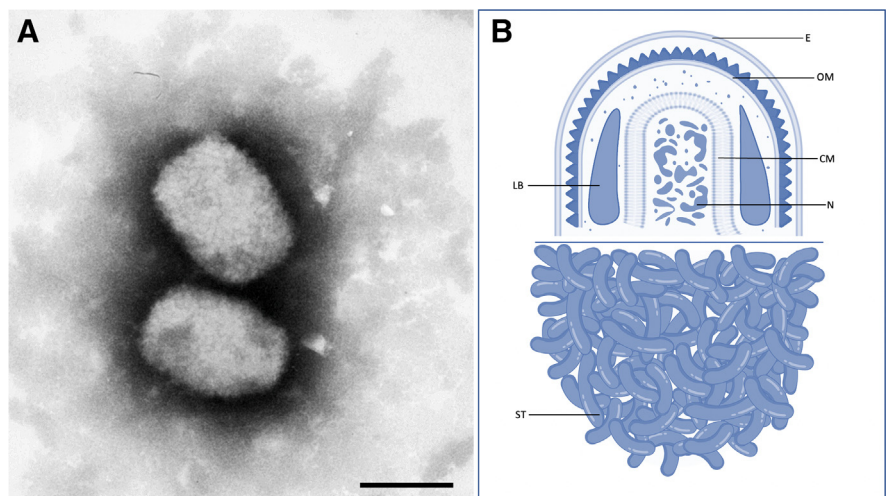
MPXV is a brick-shaped, enveloped, 200 to 250 nm—sized, double-stranded DNA, zoonotic virus (Figure 1) of the *Orthopoxvirus* genus in the *Poxviridae* family, which includes smallpox (variola), cowpox, and vaccinia viruses.<sup>14</sup>

The 2 viral clades of monkeypox<sup>3</sup>—MPXV clade I (corresponding to the previous “Congo Basin” clade) and MPXV clade II (corresponding to the previous “West African” clade, which is further divided into subclades IIa and IIb)—are clinically relevant. Clade I is associated with severe disease and a case

fatality rate (CFR) approximately 3 times that of clade II (clade I CFR, 10.6%; 95% confidence interval [CI], 8.4–13.3 vs clade II CFR, 3.6%; 95% CI, 1.7–6.8).<sup>7,15</sup> Clade IIb comprises the group of variants largely circulating in the 2022 global outbreak.<sup>3</sup>

Person-to-person transmission of MPXV classically occurs through large respiratory droplets, close contact with skin lesion exudates, and contaminated fomites. Pooled estimates suggest a secondary attack rate of approximately 8% (range, 0%–11%) among household contacts who are unvaccinated against smallpox.<sup>16</sup> Sexual transmission might be possible given the detection of MPXV DNA in seminal fluid and the high rate of primary genital and anal mucosal lesions following condomless sexual activity in the 2022 outbreak.<sup>17</sup> The caveat, however, is that isolating MPXV in seminal fluid is not necessarily evidence of infectivity because viremia is known to seed the reproductive tract.<sup>18</sup> The basic reproduction number (R0) for monkeypox is estimated to be 0.8 but >1 among men who have sex with men.<sup>19</sup>

**FIGURE 1**  
Monkeypox virus



**A**, Monkeypox virus on transmission electron microscopy, negative staining (bar=200 nm). **B**, cutaway line drawing of the monkeypox virus. Tecovirimat targets the VP37 protein and inhibits formation of the viral envelope (E). Cidofovir targets DNA polymerase within the viral nucleosome (N) but is teratogenic, unlike tecovirimat. Image credit: Panel A — Andrea Männel 2001/ RKI Robert Koch Institute; Panel B — Authors' original illustration using Biorender.

CM, core membrane; E, envelope; LB, lateral body; N, nucleosome; OM, outer membrane; ST, surface tubules.

Dashraath. Monkeypox and pregnancy. *Am J Obstet Gynecol* 2022.

For context, SARS-CoV-2 has a strain-dependent R0 of 2.5 (original strain), 7 (Delta variant B.1.617.2), and 10 (Omicron variant), respectively,<sup>20</sup> whereas smallpox had an R0 between 3.5 and 6.<sup>21</sup>

Because of their large DNA (~197 kb), orthopoxviruses are better at detecting and repairing mutations than RNA viruses (eg, SARS-CoV-2). Consequently, this has previously resulted in only 1 to 2 substitutions per genome per year, which made MPXV a virus with presumably low epidemic potential.<sup>22,23</sup> However, genomic sequencing studies have revealed that the 2022 MPXV strain contains 6 to 12 times the expected number of single-nucleotide polymorphisms, suggesting accelerated evolution and increased human adaptation.<sup>2</sup> These might have contributed to cryptic human transmission of monkeypox for years before the global outbreak was amplified by super-spreading events in 2022.

### Pathophysiology

The phases of MPXV viremia correlate with the signs and symptoms of monkeypox infection.<sup>24,25</sup> Following exposure to MPXV from any route (eg, oropharynx, nasopharynx, intradermal, and possibly anogenital [as seen in the 2022 outbreak]), the virus replicates at the site of infection before spreading to locoregional lymph nodes. From there, MPXV enters the bloodstream, producing a primary viremia that seeds the hematopoietic system. The duration of primary viremia corresponds to the incubation period of monkeypox infection (7–14 days, with an upper limit of 21 days). Further replication of MPXV produces a secondary viremia, which results in a prodrome lasting approximately 2 days, characterized by fever, headache, myalgia, and tender lymphadenopathy. The latter may be cervical or inguinal (1–4 cm in diameter) and is typical of monkeypox infection. Approximately 1 to 3 days following the onset of fever, MPXV seeds the skin and mucous membranes with virions at various stages of assembly within the cytoplasm of keratinocytes. This causes an enanthem (oral cavity lesions) and a skin exanthem because of ballooning

degeneration of basal keratinocytes and full-thickness necrosis of the epidermis.<sup>26</sup>

### Clinical features of monkeypox in nonpregnant individuals

The rash, which is typically centrifugal over the face and extremities, progresses from macules, papules, vesicles, pustules, and finally to crusts (Figure 2), and is the most common symptom seen in >90% of patients in the present outbreak.<sup>8</sup> Patients are infectious from the onset of fever until the vesicles have scabbed. Extracutaneous manifestations include pneumonia, ocular complications, encephalitis and secondary soft-tissue infections.

Atypical features of the ongoing outbreak, however, are a high rate of genital, perianal, and oral lesions and rash that does not evolve synchronously, including erythematous maculopapular rash of rapid onset separate from areas of vesicles or pustules (Appendix).<sup>27</sup> Among 528 laboratory-confirmed MPXV infections between April and June 2022, 73% had anogenital lesions and 10% presented with only a solitary

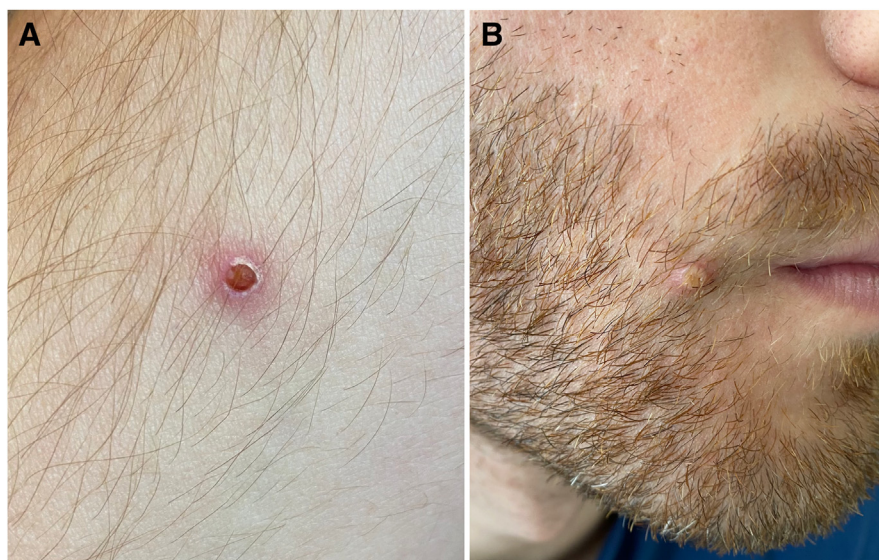
genital ulcer, which could be easily misdiagnosed as a sexually-transmitted infection and exacerbate community transmission of monkeypox until the correct diagnosis is established.<sup>17</sup> It is unclear if MPXV within the anorectum and external genitalia is the consequence of mucosal seeding during viremia or the virus propagating at the site of initial exposure. In addition, lymphadenopathy, although characteristic of monkeypox, was only present in one-third of all cases reported to WHO as of July 22, 2022.<sup>8</sup>

### Clinical features of monkeypox in pregnancy

Information about clinical characteristics, vertical transmission potential, maternal complications, and fetal outcomes of monkeypox infection in pregnancy is limited.

Among 4 pregnant women from the Democratic Republic of the Congo (DRC) with laboratory-confirmed MPXV between March 2007 and July 2011, 1 woman with mild disease delivered a neonate at term with no clinical features of monkeypox infection.<sup>10</sup>

**FIGURE 2**  
Monkeypox rash



**A**, Characteristic vesicular and **B**, pustular lesions in a person with polymerase chain reaction-confirmed human monkeypox infection.

Dashraath. Monkeypox and pregnancy. *Am J Obstet Gynecol* 2022.

However, 3 women with moderate-to-severe maternal infection had adverse obstetrical outcomes: 2 had spontaneous first-trimester miscarriages at 6 weeks' gestation (with a maternal MPXV viral load of  $3.5 \times 10^3$  and  $7.9 \times 10^5$  gene copies/mL, respectively) and 1 had a second-trimester loss at 18 weeks' gestation (viral load of  $8.9 \times 10^5$  gene copies/mL). The stillborn fetus had a vesicular rash, hepatomegaly, and hydrops with a high viral load ( $>10^7$  genome copies/mL) detected in fetal tissue, umbilical cord, and placenta, confirming vertical transmission of MPXV. Another woman with maternal infection at 24 weeks' gestation had a preterm delivery at 30 weeks' gestation; that neonate had a generalized rash at birth resembling monkeypox.<sup>11</sup> Although not reported, we make the assumption that all 5 of these women were probably infected with MPXV clade I given that they were from the DRC. However, the risk factors associated with adverse pregnancy outcomes in monkeypox infection are presently unknown.

### How did smallpox compare?

Monkeypox and smallpox (caused by the variola virus) are orthopoxviruses with striking similarities: the clinical features of both infections include an incubation period of approximately 14 days, a 2-day prodrome with fever, and a centrifugal vesiculopustular rash.<sup>28</sup> At the molecular level, the central genomic region of MPXV is 96.3% identical to the variola virus, and the amino acid sequences of the virion proteins encoded in this region are up to 99.2% homologous.<sup>29</sup> In addition, like MPXV, there are 2 distinct strains of smallpox with varying mortality risks: variola major with a CFR of 30% to 50% and variola minor with a CFR of  $<2\%$ .<sup>30</sup>

The overall maternal CFR from smallpox infection in pregnancy was 34.3% (95% CI, 31.4–37.1), and the crude proportion of miscarriage and preterm birth was 39.9% (95% CI, 36.5–43.2).<sup>31</sup> In the largest series of 389 pregnant women with smallpox, 75% miscarried before 24 weeks' gestation, 55% delivered preterm, and 10% suffered stillbirths at term.<sup>32</sup> Congenital

smallpox occurred in 9% of fetuses and resulted in a neonatal mortality rate of 100%. Maternal mortality from smallpox was the highest in the third trimester of pregnancy; expectant mothers were 2 to 4 times more likely than nonpregnant women to die from the infection, and vaccinated pregnant women were approximately 3 times less likely to succumb than those who were unvaccinated.<sup>32</sup> Hemorrhagic smallpox—characterized by petechiae, ecchymoses, profound thrombocytopenia, and multiorgan failure—occurred 7 times more frequently in pregnant women than in men and nonpregnant women regardless of vaccination status and carried a CFR of 100%.<sup>33</sup> It is likely that smallpox represented the extreme end of the disease-severity spectrum from orthopox infection during pregnancy.

Importantly, however, monkeypox and smallpox differ in the regions encoding virulence factors (eg, IFN resistance genes and interleukin- $1\beta$  inhibitors) at the terminal ends of the viral genome, which might explain the variation in clinical presentation and disease severity between the 2 infections.<sup>6</sup> In addition, no hemorrhagic form of monkeypox has been described in humans, although MPXV clade I has demonstrated the potential for pulmonary hemorrhage, epistaxis, and impaired coagulation parameters in animal studies.<sup>34</sup>

### What about monkeypox and varicella-zoster coinfection?

The possibility of monkeypox and varicella-zoster virus (VZV) coinfection, seen in 10% to 13% of individuals in the DRC,<sup>35,36</sup> is an epidemiologic observation worth highlighting because women from tropical and subtropical regions are more likely to be nonimmune to VZV. For example, only 80.9% of pregnant women in Tunisia<sup>37</sup> have VZV IgG antibodies vs 96.1% and 98.8% of pregnant women in Spain and France, respectively.<sup>38,39</sup> Coinfection carries important implications for similarly susceptible groups because both viruses carry a risk of vertical transmission. Given that coinfection also modifies the severity of the skin rash, delayed diagnoses and

treatment could result in worse perinatal outcomes, particularly in resource-limited settings.<sup>4,35,36</sup>

### Possible mechanisms and risk of in-utero transmission of monkeypox

There are currently no data demonstrating the mechanisms by which MPXV traverses the maternal-placental-fetal barrier and infects fetal tissues. Multiple pathways are possibly involved in the ability of MPXV to invade placental trophoblast cells. This is especially because MPXV does not express cell-specific receptors facilitating cell tropism, unlike most other viruses that have evolved distinct cell-specific strategies for cell entry and replication within host cells.<sup>40</sup> MPXV may reach the fetus via the hematogenous route, arriving at the intervillous space from maternal uterine spiral arteries, binding to trophoblast cells, and consecutively infecting syncytiotrophoblasts, cytotrophoblasts, fetal endothelial cells within the floating or anchored villi, and eventually fetal blood cells. MPXV may also ascend directly from genital lesions via cervical and uterine tissue, directly colonizing the chorionic membranes and decidua.<sup>41</sup> In murine models of vaccinia virus infection during pregnancy via intravenous and intraperitoneal routes, harvested placenta initially amplified vaccinia-specific viral messenger RNA (mRNA) only in cells adjacent to maternal blood vessels but not on the fetal side, and only amplified viral mRNA in fetal vessels a few days later, demonstrating the time required for contiguous spread from mother to fetus.<sup>42</sup> Cytopathic effects in human syncytiotrophoblasts observed in placenta infected with vaccinia virus include cytoplasmic condensation and cell rounding.<sup>43,44</sup>

Fetal and placental damage following vertical transmission can be additionally inferred from a report of early pregnancy fetal loss in a woman infected with cowpox virus (CPXV), an orthopoxvirus sharing a close genetic relationship with MPXV, and similarly capable of causing zoonotic infections in humans.<sup>45</sup> Pregnancy loss in a dairy worker with cowpox occurred at 11

weeks' gestation as a consequence of viremia<sup>46</sup>; DNA extracted from maternal blood, pustular areas, and from fetal and placental tissues confirmed CPXV infection by amplification of the A27L (for orthopoxvirus) and D8L/D11L genes (specific to CPXV), and viral cytopathic effects were observed on electron microscopy.<sup>47</sup> In vertical transmission of smallpox, still-born fetuses showed dermal pox signs, and viral particles were isolated from fetal skin and other organs. Placental pathology demonstrated necrotic villi, fibrin deposition, cytopathic effects (inflammatory infiltrates, necrosis), and virions at various stages of assembly on electron microscopy.<sup>26,41</sup>

Taken together, we speculate that MPXV might breach the maternal-

placental-fetal barrier via viral fusion with trophoblasts, a process by which viral capsid proteins adhere to target cell-surface receptors initiating configurational changes in the viral capsid, enabling internalization of viral DNA

**BOX 1****Differential diagnoses of monkeypox-type dermatoses in pregnancy**

Appearance of monkeypox lesion	Possible pregnancy-related causes
Maculopapular rash	<ul style="list-style-type: none"> <li>• Measles</li> <li>• Rubella</li> <li>• Cytomegalovirus and toxoplasmosis</li> <li>• Secondary syphilis</li> <li>• Atopic eruption of pregnancy</li> <li>• Pruritic urticarial papules and plaques of pregnancy</li> </ul>
Vesiculopustular rash	<ul style="list-style-type: none"> <li>• Varicella zoster</li> <li>• Pemphigoid gestationis</li> <li>• Hand-foot-and-mouth disease</li> </ul>
Anogenital ulcer	<ul style="list-style-type: none"> <li>• Herpes simplex</li> <li>• Lymphogranuloma venereum</li> </ul>

*Dashraath. Monkeypox and pregnancy. Am J Obstet Gynecol 2022.*

**TABLE 1****Infection prevention and control recommendations for staff attending to a pregnant patient with suspected monkeypox infection**

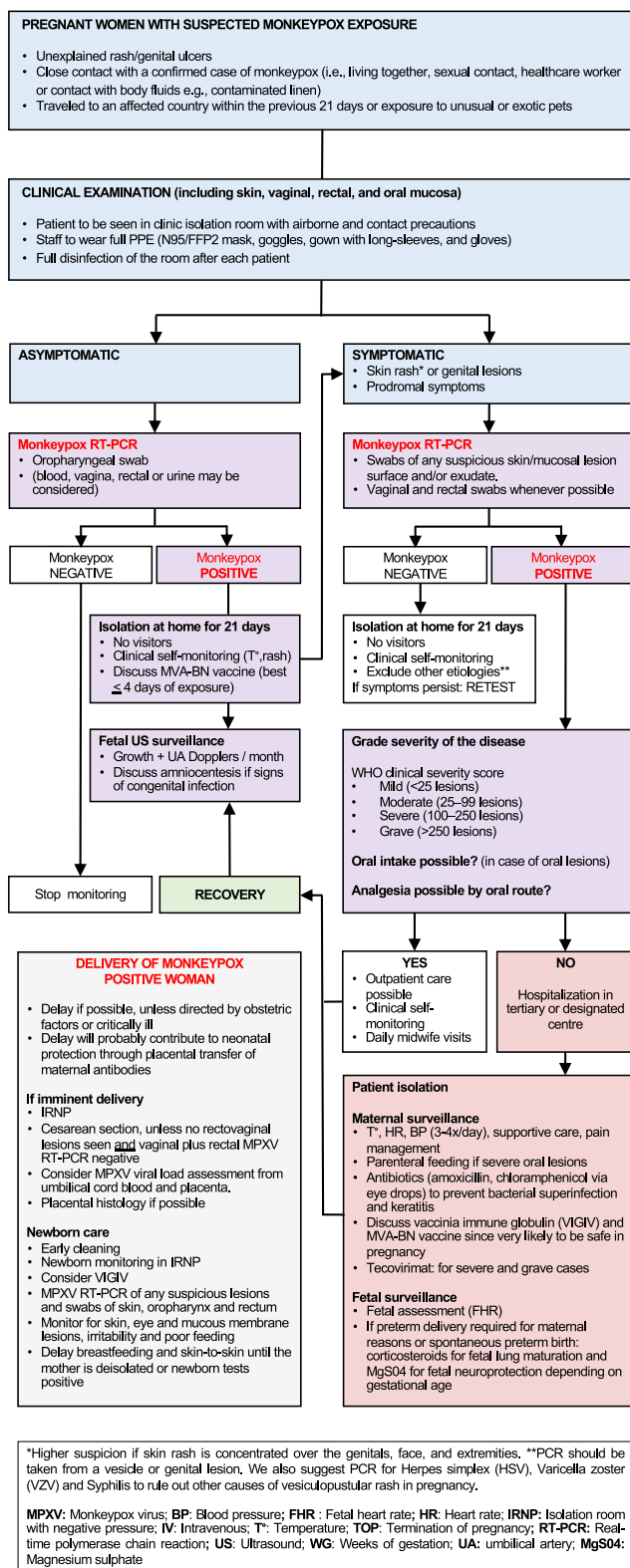
Examples of clinical encounters in obstetrics	Recommended PPE and other IPC measures
Healthcare staff with direct patient contact, eg:	
• Patient transport (including paramedic staff)	• Gloves
• Obstetrical (including vaginal) examination	• Surgical cap
• Ultrasonography (including vaginal scans)	• N95/FFP2 respirator
• Delivery	• Gowns with long sleeves <sup>a</sup>
• Pathology (for placenta/fetal tissue examination)	• Goggles or disposable face shields
Housekeeping staff with high-risk exposure, eg:	
• Cleaning operating room after delivery	• Gloves
• Handling potentially infected waste (including placental tissue and soiled linen)	• Surgical cap
	• N95/FFP2 respirator
	• Gowns with long sleeves <sup>a</sup>
	• Goggles or disposable face shields
	• Boots or shoe covers should be considered
	Other IPC measures
	• All waste and soiled linen should be considered infectious and double-bagged with an inner water-soluble layer.
	• Labor and operating rooms occupied by pregnant women with confirmed monkeypox should be terminally cleaned with bleach-based disinfectants (ie, 1000 ppm).
	• Adjunct use of UV-C disinfection systems or HPV systems would be prudent. Patients' own clothing (if not discarded) may be bagged and brought home for laundering in a standard washing machine using 60°C hot water and detergent.
	• We recommend that units consult their IPC teams on the management of items that cannot be adequately disinfected.

*HPV*, hydrogen peroxide vaporization; *IPC*, infection prevention and control; *PPE*, personal protective equipment; *UV-C*, ultraviolet C.

<sup>a</sup> Gowns should be fluid-impermeable or Association for the Advancement of Medical Instrumentation level 4-equivalent.

*Dashraath. Monkeypox and pregnancy. Am J Obstet Gynecol 2022.*

**FIGURE 3**  
**Management of monkeypox during pregnancy**



Dashraath. Monkeypox and pregnancy. Am J Obstet Gynecol 2022.

through fusion with syncytiotrophoblast membrane or via transcytosis.<sup>48</sup> Internalized viruses can then replicate and cause host cell damage directly (cytopathic effects) or secondarily to local inflammatory and immune reactions from the host. Once the placental barrier is breached, MPXV might be able to infect multiple placental cells, enabling it to reach the fetal bloodstream eventually. Fetal hydrops and hepatomegaly observed in MPXV-infected fetuses may reflect the extent of placental damage and resultant hypoxia from similar effects. It is also unknown whether maternal viral infection with MPXV (particularly in the third trimester) and maternal immune activation during pregnancy—as seen in HIV<sup>49</sup> and more recently with SARS-CoV-2<sup>50</sup>—might affect childhood neurodevelopmental milestones in fetuses exposed to monkeypox in-utero.

### Approach to the management of monkeypox in pregnancy

#### Diagnosis

Taking all the above features of monkeypox into consideration, monkeypox infection should be suspected in any pregnant woman who presents with:

1. Unexplained skin rash or genital ulcer (Box 1 contains differential diagnoses) OR
2. One or more symptoms of fever, headache, myalgia, asthenia, or lymphadenopathy AND
3. Within the last 21 days:
  - a. A travel history to countries with recently reported cases of monkeypox; OR
  - b. A history of close contact with an infected person; OR
  - c. A history of casual sexual contact during travel.

Because of the atypical features of monkeypox infection in the current outbreak, clinicians must maintain a high index of suspicion and conduct a thorough physical examination with personal protective equipment (PPE) (Table 1), including an assessment of oral, vaginal, and perianal regions.



Furthermore, given that the monkeypox rash can coexist with sexually transmitted infections<sup>17</sup> or be confused with other dermatoses, we suggest broadly excluding common causes of vesiculopustular rash in pregnancy with polymerase chain reaction (PCR) tests, including herpes simplex, varicella zoster, and syphilis.

Real-time PCR (RT-PCR) from swabs of vesicle fluid or scabs from at least 2 sites placed in viral transport media is the gold standard for the diagnosis of monkeypox<sup>51</sup> because viral DNA will be present within cutaneous lesions because of seeding from secondary viremia. False-negative results might occur because of poor specimen quality, improper handling, or DNA extraction failure. Patients reporting high-risk exposure and experiencing a febrile prodrome before the onset of skin rash can undergo a PCR throat swab. Monkeypox viral load in the upper respiratory tract peaks early in the infection, and thus oropharyngeal sampling in this context demonstrates high detection rates, second only to cutaneous lesions.<sup>52,53</sup> In contrast, PCR of ethylenediaminetetraacetic acid (EDTA) blood samples may aid, but not replace, mucocutaneous sampling because the duration of monkeypox viremia is short (ie, corresponding with the prodrome, which lasts approximately 2 days), and plasma may thereafter not contain high levels of

<b>TABLE 2</b>	
<b>Delivery protocol for a pregnant patient with monkeypox</b>	
Mode of delivery	<ul style="list-style-type: none"> <li>• Cesarean delivery (unless vaginal and anorectal lesions are absent AND vaginal and rectal MPXV-PCR swabs are negative)</li> <li>• PPE and IPC measures (Table 1)</li> </ul>
Site of delivery	<ul style="list-style-type: none"> <li>• Negative-pressure operating theater</li> </ul>
Anesthesia and surgical considerations	<ul style="list-style-type: none"> <li>• Regional anesthesia preferred depending on clinical condition AND absence of suspected lesions on the back</li> <li>• Extended-spectrum antibiotics with cefazolin plus azithromycin</li> <li>• Preoperative skin antisepsis with povidone-iodine is probably safer than chlorhexidine-alcohol</li> <li>• Nonadhesive surgical drapes if extensive abdominal rash present</li> <li>• Patient consent for placental histology</li> <li>• Patient consent for MPXV-PCR of the following specimens (collected at delivery): amniotic fluid, cord blood, placenta, vaginal swab, and rectal swab</li> </ul>
Postpartum care	<ul style="list-style-type: none"> <li>• Management of neonate (Table 3)</li> <li>• LMWH not contraindicated for postpartum thromboprophylaxis in monkeypox</li> <li>• Patient consent for MPXV-PCR of expressed breast milk</li> <li>• Complete WHO monkeypox case report form (available at: <a href="https://www.who.int/publications/i/item/WHO-MPX-Clinical_CRF-2022.3">https://www.who.int/publications/i/item/WHO-MPX-Clinical_CRF-2022.3</a>)</li> </ul>

*IPC, infection prevention and control; LMWH, low molecular weight heparin; MPXV, monkeypox virus; PCR, polymerase chain reaction; PPE, personal protective equipment; WHO, World Health Organization.*

*Dashraath. Monkeypox and pregnancy. Am J Obstet Gynecol 2022.*

MPXV. In the current outbreak, a positive PCR result was most commonly obtained from skin or anogenital lesions.<sup>17</sup>

#### **Antenatal care and fetal surveillance**

Given the possibility of vertical transmission of MPXV, serial ultrasound surveillance for signs of congenital

infection is justified in symptomatic pregnant women with PCR-confirmed disease (Figure 3). In addition, we are of the opinion that paucisymptomatic and asymptomatic pregnant women with high-risk monkeypox exposure who test positive on oropharyngeal RT-PCR should also undergo ultrasound

**TABLE 3**

#### **Management of the neonate**

General management	<ul style="list-style-type: none"> <li>• Neonatology team should be informed of all cases</li> </ul>
Management of neonates delivered by cesarean delivery	<ul style="list-style-type: none"> <li>• Low risk of vertically transmitted monkeypox infection</li> <li>• No active treatment required</li> <li>• Monitor for skin, eye, and mucous membrane lesions, irritability, and poor feeding</li> <li>• Delay breastfeeding and skin-to-skin until the mother is deisolated</li> </ul>
Management of neonates delivered vaginally (eg, birth before arrival or precipitate labor in mothers with active or suspected monkeypox infection)	<ul style="list-style-type: none"> <li>• High risk of vertically transmitted monkeypox infection</li> <li>• Swabs of skin, oropharynx, and rectum for MPXV-PCR</li> <li>• Consider empirical treatment with intravenous vaccinia immune globulin in consultation with neonatal and infectious disease specialists</li> <li>• Monitor for skin, eye, and mucous membrane lesions, irritability, and poor feeding</li> <li>• Consider reuniting mother and infant if both are positive for monkeypox and encourage breastfeeding unless the mother has a monkeypox rash around the nipples</li> </ul>

*MPXV, monkeypox virus; PCR, polymerase chain reaction.*

*Dashraath. Monkeypox and pregnancy. Am J Obstet Gynecol 2022.*

TABLE 4

## Practical prescribing considerations for monkeypox therapy in pregnancy

Therapy	Dose	Obstetrical precautions																				
Tecovirimat	600-mg oral, twice daily for 2 wk	<p>Beware the risk of QTc prolongation in pregnancy</p> <ul style="list-style-type: none"> <li>• Obtain an ECG before starting tecovirimat in pregnancy</li> <li>• Tecovirimat can cause prolongation of the QTc interval—this may trigger torsade de pointes (TdP)</li> <li>• TdP may be asymptomatic or fatal (ventricular fibrillation)</li> <li>• Women are at higher risk because the baseline QTc interval is longer in women than men (470 vs 450 ms)</li> <li>• Macrolides—specifically erythromycin—are a well-known drug-induced cause of prolonged QTc</li> <li>• Beware the possibility of TdP in pregnant women with monkeypox and PPROM receiving both tecovirimat and erythromycin</li> </ul>																				
Vaccinia immune globulin intravenous (VIGIV)	<p>6000 units/kg IV infusion</p> <p>For patients &gt;50 kg</p> <table border="1"> <thead> <tr> <th>Time</th> <th>Infusion rate</th> </tr> </thead> <tbody> <tr> <td>0 min</td> <td>0.5 ml/min</td> </tr> <tr> <td>30 min</td> <td>1.0 ml/min</td> </tr> <tr> <td>45 min</td> <td>1.5 ml/min</td> </tr> <tr> <td>60 min</td> <td>2.0 ml/min (max)</td> </tr> </tbody> </table> <p>For patients &lt;50 kg</p> <table border="1"> <thead> <tr> <th>Time</th> <th>Infusion rate</th> </tr> </thead> <tbody> <tr> <td>0 min</td> <td>0.01 ml/kg/min</td> </tr> <tr> <td>30 min</td> <td>0.02 ml/kg/min</td> </tr> <tr> <td>45 min</td> <td>0.03 ml/kg/min</td> </tr> <tr> <td>60 min</td> <td>0.04 ml/kg/min (max)</td> </tr> </tbody> </table>	Time	Infusion rate	0 min	0.5 ml/min	30 min	1.0 ml/min	45 min	1.5 ml/min	60 min	2.0 ml/min (max)	Time	Infusion rate	0 min	0.01 ml/kg/min	30 min	0.02 ml/kg/min	45 min	0.03 ml/kg/min	60 min	0.04 ml/kg/min (max)	<p>Beware the patient with gestational or preexisting diabetes mellitus</p> <ul style="list-style-type: none"> <li>• Maltose in VIGIV can interact with glucose monitoring systems resulting in falsely high readings and inappropriate insulin administration</li> <li>• Glucose monitors and test strips using glucose dehydrogenase pyrroloquinoline quinone (GDH-PQQ) or glucose-dye-oxidoreductase methods <u>must not</u> be used for blood glucose monitoring (eg, 7-point BSP) in pregnant women receiving VIGIV</li> </ul> <p>Beware the risk of venous thromboembolism (VTE)</p> <ul style="list-style-type: none"> <li>• VIGIV is associated with a risk of VTE in nonpregnant patients—this iatrogenic risk is likely higher in pregnant women</li> <li>• Slow down the VIGIV infusion rates in pregnant women</li> <li>• Do not exceed 12,000 units/kg in patients with VTE risk</li> <li>• Consider concurrent LMWH in pregnant women with additional risk factors for VTE who are receiving VIGIV (personal opinion)</li> </ul> <p>Beware the patient with allergies</p> <ul style="list-style-type: none"> <li>• VIGIV is a blood product and can cause potentially life-threatening hypersensitivity reactions (anaphylactic shock)</li> <li>• Check baseline BP, HR, and temperature in <u>all</u> patients before starting VIGIV infusion</li> <li>• Consider CTG monitoring (depending on gestational age) in pregnant women receiving VIGIV or if a severe allergic reaction occurs</li> </ul>
Time	Infusion rate																					
0 min	0.5 ml/min																					
30 min	1.0 ml/min																					
45 min	1.5 ml/min																					
60 min	2.0 ml/min (max)																					
Time	Infusion rate																					
0 min	0.01 ml/kg/min																					
30 min	0.02 ml/kg/min																					
45 min	0.03 ml/kg/min																					
60 min	0.04 ml/kg/min (max)																					

BP, blood pressure; BSP, blood sugar profile; CTG, cardiotocogram; ECG, electrocardiogram; HR, heart rate; IV, intravenous; LMWH, low molecular weight heparin; PPROM, preterm prelabor rupture of membranes; QTc, heart rate—corrected QT-interval.

Dashraath. Monkeypox and pregnancy. *Am J Obstet Gynecol* 2022.

screening given the currently unquantifiable risk to the fetus. By extrapolating the known obstetrical outcomes of monkeypox infection, the sonographic features of fetal infection might include hepatomegaly, ascites, hydrops, placental calcifications, and fetal growth restriction.<sup>54</sup>

In the presence of these features, amniocentesis with RT-PCR could establish the diagnosis of fetal infection. However, the sensitivity of molecular detection of MPXV in amniotic fluid is

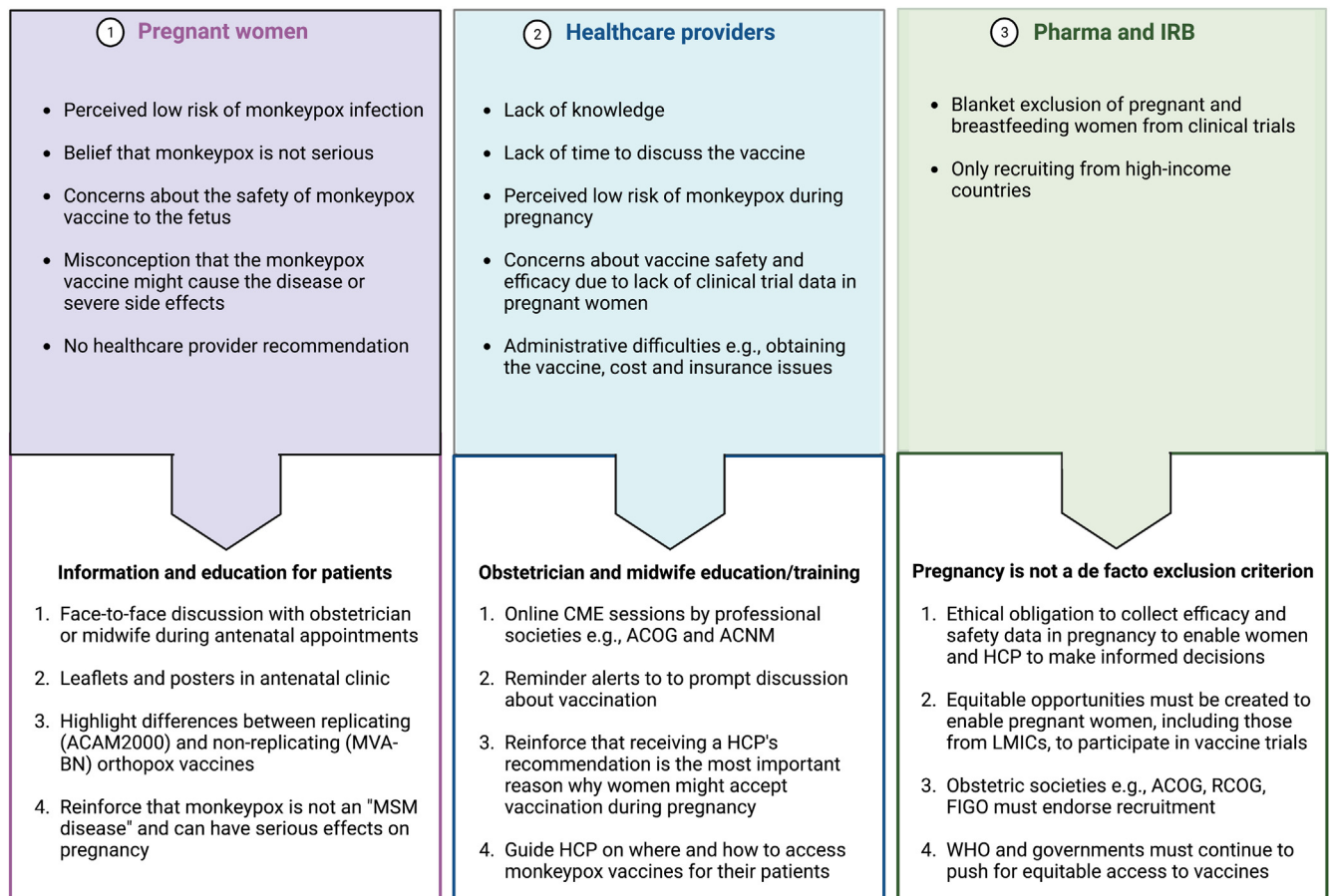
presently unknown. By analogy with other TORCH (toxoplasmosis, other agents, rubella, cytomegalovirus, and herpes simplex) infections, MPXV is likely shed in the amniotic fluid once sufficient time has elapsed for the virus to breach the placental barrier (typically 6–8 weeks after infection), once the fetal kidneys produce sufficient urine (ie, after 16–18 weeks' gestation), or fetal skin lesions have developed.<sup>55</sup> It is theoretically possible that MPXV might only be transiently detected in-utero (similar to

Zika virus in amniotic fluid, placenta, or fetal tissues<sup>56</sup>), despite a progressive risk of fetal anomalies throughout pregnancy; the kinetics of MPXV within the fetal compartment is an area that warrants further study.

### Labor and delivery

Monkeypox infection in the third trimester or during the last 4 weeks of pregnancy should not indicate expediting delivery unless directed by obstetrical factors or clinical urgency in

**FIGURE 4**  
Possible barriers to monkeypox vaccination during pregnancy



ACNM, American College of Nurse-Midwives; ACOG, American College of Obstetricians and Gynecologists; FIGO, International Federation of Gynecology and Obstetrics; HCP, healthcare provider; IRB, institutional review board; LMIC, low- and middle-income countries; RCOG, Royal College of Obstetricians and Gynaecologists.

Dashraath. Monkeypox and pregnancy. *Am J Obstet Gynecol* 2022.

critically ill women. Characterization of acute-phase humoral immunity to monkeypox suggests seroconversion for both IgG and IgM approximately 4 days after the onset of rash in unvaccinated individuals.<sup>57</sup> Thus, by additional analogy with varicella-zoster, deferring delivery for at least 7 days after the onset of monkeypox rash might permit the transplacental transfer of maternal IgG antibodies against MPXV.

Cesarean delivery with PPE would be the most reasonable delivery strategy in women with monkeypox infection (Table 2). Like neonatal varicella<sup>58</sup> (50% risk of transmission, 20% CFR) and neonatal herpes simplex<sup>59</sup> (85% risk of transmission, 60% CFR), exposure to

anogenital MPXV during vaginal delivery may carry a high risk of fulminant neonatal sepsis, including encephalitis, sight-threatening keratitis, and necrotizing skin infections.<sup>28</sup>

Maternal anesthetic concerns include complications from neuraxial anesthesia (given the risk of transmitting cutaneous MPXV from the trunk into the central nervous system) and intubation (if oropharyngeal lesions are present). In women with widespread rash, extended-spectrum antibiotic cover with cefazolin and azithromycin before skin incision is likely to reduce the risk of postcesarean endometritis and surgical site infection (SSI) to a greater extent than cefazolin alone. Anaphylaxis is an

underrecognized but potentially fatal complication following topical exposure to chlorhexidine via broken skin and mucosa.<sup>60</sup> Therefore, in women with extensive mucocutaneous involvement in monkeypox, we opine that povidone-iodine for antiseptic skin and vaginal preparation is probably safer, although chlorhexidine-alcohol is more effective in lowering SSI risk after cesarean delivery.<sup>61</sup>

Management of the newborn depends on the likelihood of vertical transmission, and intravenous vaccinia immune globulin (VIGIV) could be considered in neonates with a high risk of perinatally acquired monkeypox (Table 3). Although it is unknown if

**BOX 2****Knowledge gaps and research priorities for monkeypox in pregnancy****Clinical features**

- What is the impact of the timing of maternal monkeypox infection in each trimester of pregnancy on the rate of obstetrical outcomes in a geographically diverse cohort?
  - Miscarriage
  - Stillbirth
  - Preterm births
  - Birthweight
  - Fetal growth restriction
  - Maternal morbidity (including psychological) and mortality
- What is the rate of severe maternal infection (based on WHO clinical severity score or MPXV viral load assessment) and the impact of the severity of maternal infection on obstetrical outcomes?
  - What is the rate of asymptomatic or paucisymptomatic infection?
  - Do asymptomatic or paucisymptomatic infections carry risks to the pregnancy?

**Maternal–fetal and neonatal transmission**

- What is the risk of congenital infection?
  - What is the rate of vertical transmission?
  - In the event of fetal infection, what is the proportion of asymptomatic and symptomatic fetuses?
  - Does the risk of congenital monkeypox correlate with the severity of maternal disease?
  - Does MPXV detected in semen carry any risk to the pregnancy?
- What is the mechanism of vertical transmission of monkeypox?
  - Can MPXV be isolated from the placenta or other fetal tissues?
  - What is the sensitivity for the molecular detection of MPXV from amniotic fluid?
  - Is the detection of MPXV from amniotic fluid or fetal tissues only transient (as seen in Zika)?
- What is the risk of transmission during breastfeeding?
  - Can MPXV be isolated from breast milk?

**Therapeutics and vaccines**

- What are the issues from the use of tecovirimat (and other new antivirals) in pregnancy?
  - Are there iatrogenic risks to mother and fetus?
  - Does tecovirimat shorten the duration of illness and MPXV viral shedding in pregnancy?
  - Does tecovirimat reduce the risk of severe disease and mortality in pregnancy?
- What are the issues from the use of vaccinia immune globulin in pregnancy?
- What are the issues from the use of nonreplicating (MVA-BN) and minimally replicating (LC16) orthopox vaccines in pregnancy?
  - Effectiveness in preventing infection
  - Maternal adverse reactions
  - Immunogenicity of the orthopox vaccine in pregnancy
  - Fetal risks from vaccine exposure (eg, miscarriage and birth defects)
  - Transplacental transfer of maternal antibodies derived from vaccination and protection of the fetus and neonate
  - Breastfeeding concerns (eg, are the vaccine components detected in breast milk and in the neonate?)

MPXV, monkeypox virus; WHO, World Health Organization.

Dashraath. Monkeypox and pregnancy. *Am J Obstet Gynecol* 2022.

MPXV is present in breast milk, the infection might be transmitted to the newborn through close contact during breastfeeding. It would therefore be prudent to delay breastfeeding until the mother's rashes have scabbed over. If, however, the patient chooses to breastfeed, the nipple–areolar complex should be free of lesions, the neonate should be fully swaddled to reduce skin-to-skin

contact, and the patient should wear a face mask to reduce droplet transmission because of the close proximity between mother and child. Given the currently unquantifiable and unknown long-term risks to the neonate, we also propose that pediatricians consider neurocognitive phenotyping of the infant to detect developmental disorders of motor function, speech, language, and other

deficits related to possible maternal immune activation by MPXV in-utero.

**Antiviral treatment and vaccines**

Tecovirimat, which inhibits the orthopoxvirus VP37 envelope wrapping protein, is the first-line antiviral recommended by the US Centers for Disease Control and Prevention for the treatment of monkeypox in critically ill

pregnant and breastfeeding women.<sup>62</sup> Although tecovirimat is not authorized for use during pregnancy, animal studies have shown no embryotoxic or teratogenic effects. VIGIV is also likely to be safe given that immunoglobulins, as a class, have been used widely in pregnancy without adverse outcomes. Given that tecovirimat and VIGIV will feature prominently in the pharmacologic management of monkeypox, clinicians must be aware of the unique obstetrical issues when using these agents (Table 4).

For pre- and postexposure prophylaxis in pregnancy, WHO recommends the nonreplicating smallpox vaccine (MVA-BN), which confers 85% cross-protective immunity against monkeypox infection.<sup>63</sup> To date, 300 pregnant women have received the MVA-BN vaccine without incident.<sup>64</sup> In contrast, ACAM2000 is a live, replicating smallpox vaccine that is more heavily stockpiled but carries a risk of fetal vaccinia, which can result in preterm delivery, stillbirth, neonatal death, and adverse maternal reactions.<sup>65</sup> Pregnant health-care workers and others with substantial exposure (eg, pregnant household contacts) must therefore be prioritized for the MVA-BN vaccine when indicated.

However, as with influenza, pertussis, and COVID-19 vaccination,<sup>66–68</sup> we anticipate barriers to vaccine acceptance, and so we propose strategies aimed at the pregnant woman, healthcare provider, and institutional review board to improve the uptake of monkeypox vaccination during pregnancy (Figure 4). The Monitored Emergency Use of Unregistered and Experimental Interventions (MEURI) framework from the WHO<sup>69</sup> and the PREVENT Working Group<sup>70</sup> roadmap should be used by healthcare systems to guide the ethical use of expanded-access drugs and facilitate the deployment of vaccines in pregnancy.

### Conclusions and recommendations

For years, the scientific community has warned that monkeypox could emerge as the most crucial orthopoxvirus infection in humans.<sup>7,12</sup> The disease will be a challenge for pregnant individuals, who represent a vulnerable population during any public health emergency of

### Glossary of terms

- Centrifugal: concentrated on the face and extremities rather than over the trunk
- Clade: group of organisms believed to comprise all the evolutionary descendants of a common ancestor
- MPXV: monkeypox virus—the pathogen that causes human monkeypox infection, first identified in the Democratic Republic of the Congo in 1970 and largely confined to Central and Western Africa before 2022
- MPXV clade 1: previously designated as the “Congo Basin” clade
- MPXV clade 2: previously designated as the “West African” clade
- Negative pressure room: room that maintains lower air pressure inside the treatment area than that of the surrounding environment, thus preventing internal air from circulating back out
- Public health emergency of international concern: an extraordinary event that is determined to constitute a public health risk to other states through the international spread of disease and to potentially require a coordinated international response
- R0: average number of people that a single infected person can be expected to transmit a disease to in a population where all individuals are susceptible to that infection
- TORCH: Toxoplasmosis, Others (including parvovirus B19, syphilis, varicella-zoster virus, HIV, hepatitis B and C, Chikungunya, and Zika virus), rubella, cytomegalovirus (CMV), and herpes simplex virus
- WHO: World Health Organization
- Zoonosis: an infectious disease that has jumped from an animal to humans; zoonotic pathogens may be bacterial, viral, or parasitic, and can be transmitted to humans through direct contact or through food, water, or the environment

international concern. For now, much of the obstetrical management will be based on consensus and best-practice recommendations. We propose the following research priorities for clinicians and health systems (Box 2) to supplement WHO’s recommendations to guide the global effort to tackle monkeypox—now and in the future.<sup>71</sup> ■

### REFERENCES

1. Centers for Disease Control and Prevention. 2022 monkeypox and orthopox virus outbreak global map. 2022. Available at, <https://www.cdc.gov/poxvirus/monkeypox/response/2022/world-map.html>. Accessed July 27, 2022.
2. Isidro J, Borges V, Pinto M, et al. Phylogenomic characterization and signs of microevolution in the 2022 multi-country outbreak of monkeypox virus. *Nat Med* 2022;28:1569–72.
3. World Health Organization. Monkeypox: experts give virus variants new names. 2022. Available at, <https://www.who.int/news/item/12-08-2022-monkeypox-experts-give-virus-variants-new-names>. Accessed August 12, 2022.
4. World Health Organization. Clinical management and infection prevention and control for monkeypox. Interim rapid response guidance.

2022. Available at, <https://www.who.int/publications/i/item/WHO-MPX-Clinical-and-IPC-2022.1>. Accessed June 11, 2022.

5. Randall RE, Goodbourn S. Interferons and viruses: an interplay between induction, signalling, antiviral responses and virus countermeasures. *J Gen Virol* 2008;89:1–47.

6. Fernández de Marco Mdel M, Alejo A, Hudson P, Damon IK, Alcami A. The highly virulent variola and monkeypox viruses express secreted inhibitors of type I interferon. *FASEB J* 2010;24:1479–88.

7. Bunge EM, Hoet B, Chen L, et al. The changing epidemiology of human monkeypox—a potential threat? A systematic review. *PLoS Negl Trop Dis* 2022;16:e0010141.

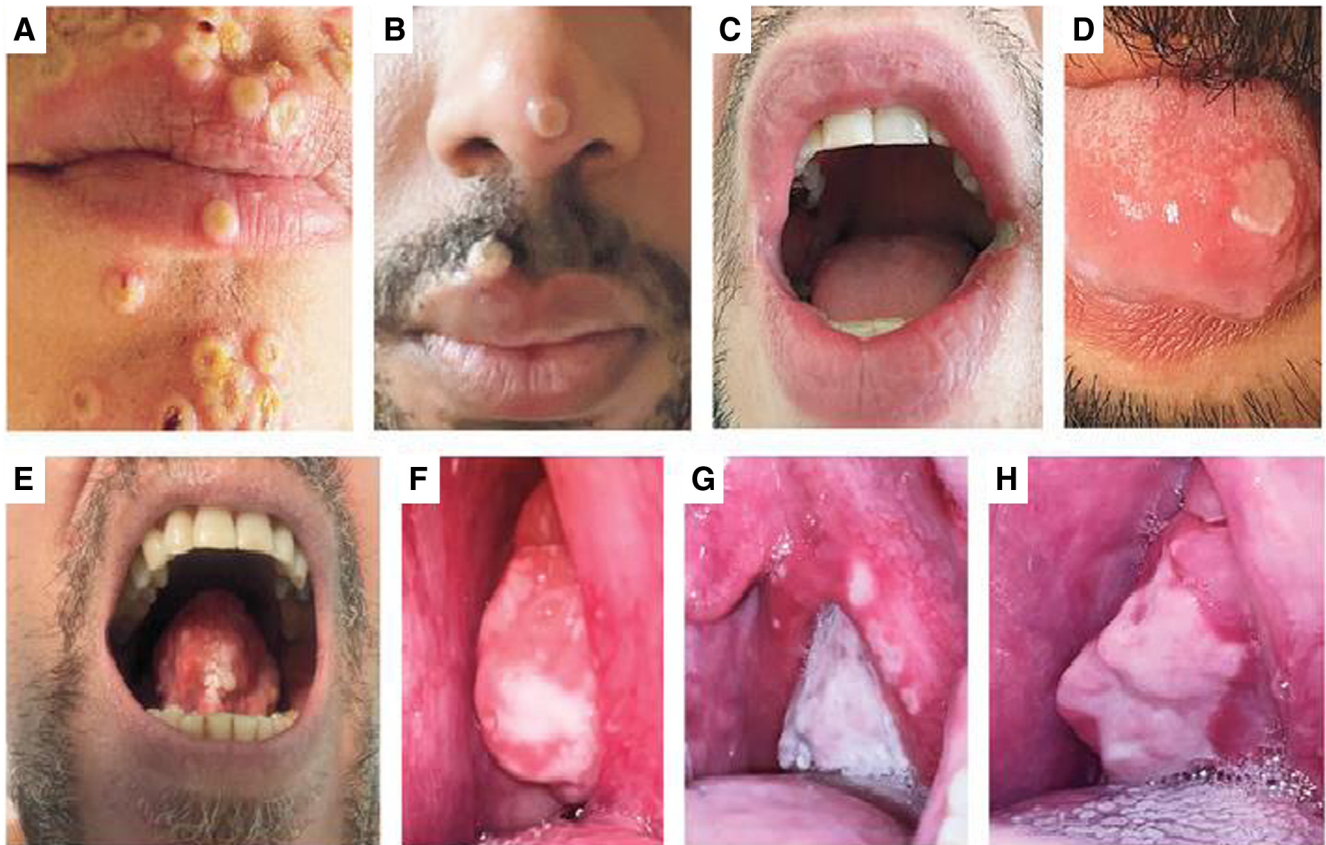
8. World Health Organization. Multi-country outbreak of monkeypox, External situation Report #2. 2022. Available at, <https://www.who.int/publications/m/item/multi-country-outbreak-of-monkeypox-external-situation-report-2-25-july-2022>. Accessed July 27, 2022.

9. World Health Organization. Maternal, newborn, child and adolescent health and ageing. 2022. Available at, [https://www.who.int/data/maternal-newborn-child-adolescent-ageing/indicator-explorer-new/mca/women-of-reproductive-age-\(15-49-years\)-population-\(thousands\)](https://www.who.int/data/maternal-newborn-child-adolescent-ageing/indicator-explorer-new/mca/women-of-reproductive-age-(15-49-years)-population-(thousands)). Accessed July 27, 2022.

10. Mbala PK, Huggins JW, Riu-Rovira T, et al. Maternal and fetal outcomes among pregnant women with human monkeypox infection in the Democratic Republic of Congo. *J Infect Dis* 2017;216:824–8.
11. Kisalu NK, Mokili JL. Toward understanding the outcomes of monkeypox infection in human pregnancy. *J Infect Dis* 2017;216:795–7.
12. Sklenovská N, Van Ranst M. Emergence of monkeypox as the most important Orthopoxvirus infection in humans. *Front Public Health* 2018;6:241.
13. Bardají A, Sevens E, Cutland C, et al. The need for a global COVID-19 maternal immunisation research plan. *Lancet* 2021;397:e17–8.
14. Parker S, Nuara A, Buller RML, Schultz DA. Human monkeypox: an emerging zoonotic disease. *Future Microbiol* 2007;2:17–34.
15. Otu A, Ebenso B, Walley J, Barceló JM, Ochu CL. Global human monkeypox outbreak: atypical presentation demanding urgent public health action. *Lancet Microbe* 2022;3:e554–5.
16. Beer EM, Rao VB. A systematic review of the epidemiology of human monkeypox outbreaks and implications for outbreak strategy. *PLoS Negl Trop Dis* 2019;13:e0007791.
17. Thornhill JP, Barkati S, Walmsley S, et al. Monkeypox virus infection in humans across 16 countries - April-June 2022. *N Engl J Med* 2022 [Epub ahead of print].
18. Le Tortorec A, Matusali G, Mahé D, et al. DM. From ancient to emerging infections: the odyssey of viruses in the male genital tract. *Physiol Rev* 2020;100:1349–414.
19. World Health Organization. Second meeting of the International Health Regulations (2005) (IHR) Emergency Committee regarding the multi-country outbreak of monkeypox. 2022. Available at, [https://www.who.int/news/item/23-07-2022-second-meeting-of-the-international-health-regulations-\(2005\)-\(ihr\)-emergency-committee-regarding-the-multi-country-outbreak-of-monkeypox](https://www.who.int/news/item/23-07-2022-second-meeting-of-the-international-health-regulations-(2005)-(ihr)-emergency-committee-regarding-the-multi-country-outbreak-of-monkeypox). Accessed July 27, 2022.
20. Burki TK. Omicron variant and booster COVID-19 vaccines. *Lancet Respir Med* 2022;10:e17.
21. Gani R, Leach S. Transmission potential of smallpox in contemporary populations. *Nature* 2001;414:748–51.
22. Firth C, Kitchen A, Shapiro B, Suchard MA, Holmes EC, Rambaut A. Using time-structured data to estimate evolutionary rates of double-stranded DNA viruses. *Mol Biol Evol* 2010;27:2038–51.
23. Reynolds MG, Carroll DS, Karem KL. Factors affecting the likelihood of monkeypox's emergence and spread in the post-smallpox era. *Curr Opin Virol* 2012;2:335–43.
24. Goff AJ, Chapman J, Foster C, et al. A novel respiratory model of infection with monkeypox virus in cynomolgus macaques. *J Virol* 2011;85:4898–909.
25. Mucker EM, Wollen-Roberts SE, Kimmel A, Shamblin J, Sampay D, Hooper JW. Intranasal monkeypox marmoset model: prophylactic antibody treatment provides benefit against severe monkeypox virus disease. *PLoS Negl Trop Dis* 2018;12:e0006581.
26. Bayer-Garner IB. Monkeypox virus: histologic, immunohistochemical and electron-microscopic findings. *J Cutan Pathol* 2005;32:28–34.
27. Patel A, Bilinska J, Tam JCH, et al. Clinical features and novel presentations of human monkeypox in a central London centre during the 2022 outbreak: descriptive case series. *BMJ* 2022;378:e072410.
28. McCollum AM, Damon IK. Human monkeypox. *Clin Infect Dis* 2014;58:260–7.
29. Shchelkunov SN, Totmenin AV, Babkin IV, et al. Human monkeypox and smallpox viruses: genomic comparison. *FEBS Lett* 2001;509:66–70.
30. Shchelkunov SN, Totmenin AV, Loparev VN, et al. Alastrim smallpox variola minor virus genome DNA sequences. *Virology* 2000;266:361–86.
31. Nishiura H. Smallpox during pregnancy and maternal outcomes. *Emerg Infect Dis* 2006;12:1119–21.
32. Rao AR, Prahlad I, Swaminathan M, Lakshmi A. Pregnancy and smallpox. *J Indian Med Assoc* 1963;40:353–63.
33. Suarez VR, Hankins GDV. Smallpox and pregnancy: from eradicated disease to bioterrorist threat. *Obstet Gynecol* 2002;100:87–93.
34. Sbrana E, Xiao SY, Newman PC, Tesh RB. Comparative pathology of North American and Central African strains of monkeypox virus in a ground squirrel model of the disease. *Am J Trop Med Hyg* 2007;76:155–64.
35. Hughes CM, Liu L, Davidson WB, et al. A tale of two viruses: coinfections of monkeypox and varicella zoster virus in the Democratic Republic of Congo. *Am J Trop Med Hyg* 2021;104:604–11.
36. Hoff NA, Morier DS, Kisalu NK, et al. Varicella coinfection in patients with active monkeypox in the Democratic Republic of the Congo. *EcoHealth* 2017;14:564–74.
37. Hussey H, Abdullahi L, Collins J, Muloiwana R, Hussey G, Kagina B. Varicella zoster virus-associated morbidity and mortality in Africa - a systematic review. *BMC Infect Dis* 2017;17:717.
38. Plans P, Costa J, Espuñes J, Plasencia A, Salleras L. Prevalence of varicella-zoster antibodies in pregnant women in Catalonia (Spain). Rationale for varicella vaccination of women of childbearing age. *BJOG* 2007;114:1122–7.
39. Saadatian-Elahi M, Mekki Y, Del Signore C, et al. Seroprevalence of varicella antibodies among pregnant women in Lyon-France. *Eur J Epidemiol* 2007;22:405–9.
40. Zaga-Clavellina V, Diaz L, Olmos-Ortiz A, Godínez-Rubí M, Rojas-Mayorquín AE, Ortuño-Sahagún D. Central role of the placenta during viral infection: immuno-competences and miRNA defensive responses. *Biochim Biophys Acta Mol Basis Dis* 2021;1867:166182.
41. Fuentes-Zacarias P, Murrieta-Coxca JM, Gutiérrez-Samudic RN, et al. Pregnancy and pandemics: interaction of viral surface proteins and placenta cells. *Biochim Biophys Acta Mol Basis Dis* 2021;1867:166218.
42. Benning N, Hassett DE. Vaccinia virus infection during murine pregnancy: a new pathogenesis model for vaccinia fetal. *J Virol* 2004;78:3133–9.
43. Nørskov-Lauritsen N, Zachar V, Petersen PM, Hager H, Aboagye-Mathiesen G, Ebbesen P. In vitro infection of human placental trophoblast by wild-type vaccinia virus and recombinant virus expressing HIV envelope glycoprotein. *Res Virol* 1992;143:321–8.
44. Schmidt FI, Bleck OKE, Helenius A, Mercer J. Vaccinia extracellular virions enter cells by macropinocytosis and acid-activated membrane rupture. *EMBO J* 2011;30:3647–61.
45. Bourquain D, Dabrowski PW, Nitsche A. Comparison of host cell gene expression in cowpox, monkeypox or vaccinia virus-infected cells reveals virus-specific regulation of immune response genes. *Virol J* 2013;10:61.
46. Ferrier A, Frenois-Veyrat G, Schvoerer E, et al. Fatal cowpox virus infection in human fetus, France, 2017. *Emerg Infect Dis* 2021;27:2570–7.
47. Maksyutov RA, Gavrilova EV, Meyer H, Shchelkunov SN. Real-time PCR assay for specific detection of cowpox virus. *J Virol Methods* 2015;211:8–11.
48. León-Juárez M, Martínez-Castillo M, González-García LD, et al. Cellular and molecular mechanisms of viral infection in the human placenta. *Pathog Dis* 2017;75:ftx093.
49. Wedderburn CJ, Weldon E, Bertran-Cobo C, et al. Early neurodevelopment of HIV-exposed uninfected children in the era of antiretroviral therapy: a systematic review and meta-analysis. *Lancet Child Adolesc Health* 2022;6:393–408.
50. Edlow AG, Castro VM, Shook LL, Kaimal AJ, Perlis RH. Neurodevelopmental outcomes at 1 year in infants of mothers who tested positive for SARS-CoV-2 during pregnancy. *JAMA Netw Open* 2022;5:e2215787.
51. World Health Organization. WHO Laboratory testing for the monkeypox virus: interim guidance. 2022. Available at <https://www.who.int/publications/i/item/WHO-MPX-laboratory-2022.1>. Accessed August 1, 2022.
52. Adler H, Gould S, Hine P, et al. Clinical features and management of human monkeypox: a retrospective observational study in the UK. *Lancet Infect Dis* 2022;22:1153–62.
53. Noe S, Zange S, Seilmaier M, et al. Clinical and virological features of first human monkeypox cases in Germany. *Infection* 2022 [Epub ahead of print].
54. Dashraath P, Nielsen-Saines K, Mattar C, Musso D, Tambyah P, Baud D. Guidelines for pregnant individuals with monkeypox virus exposure. *Lancet* 2022;400:21–2.
55. Khalil A, Sotiriadis A, Chaoui R, et al. ISUOG practice guidelines: role of ultrasound in congenital infection. *Ultrasound Obstet Gynecol* 2020;56:128–51.
56. Schaub B, Vouga M, Najjoulah F, et al. Analysis of blood from Zika virus-infected

- fetuses: a prospective case series. *Lancet Infect Dis* 2017;17:520–7.
- 57.** Karem KL, Reynolds M, Braden Z, et al. Characterization of acute-phase humoral immunity to monkeypox: use of immunoglobulin M enzyme-linked immunosorbent assay for detection of monkeypox infection during the 2003 North American outbreak. *Clin Diagn Lab Immunol* 2005;12:867–72.
- 58.** Sauerbrei A, Wutzler P. Neonatal varicella. *J Perinatol* 2001;21:545–9.
- 59.** Looker KJ, Magaret AS, May MT, et al. M. First estimates of the global and regional incidence of neonatal herpes infection. *Lancet Glob Health* 2017;5:e300–9.
- 60.** Rose MA, Garcez T, Savic S, Garvey LH. Chlorhexidine allergy in the perioperative setting: a narrative review. *Br J Anaesth* 2019;123:e95–103.
- 61.** Tuuli MG, Liu J, Stout MJ, et al. A randomized trial comparing skin antiseptic agents at cesarean delivery. *N Engl J Med* 2016;374:647–55.
- 62.** Centers for Disease Control and Prevention. Clinical considerations for monkeypox in people who are pregnant or breastfeeding. 2022. Available at <https://www.cdc.gov/poxvirus/monkeypox/clinicians/pregnancy.html>. Accessed August 1, 2022.
- 63.** World Health Organization. Vaccines and immunisation for monkeypox. Interim guidance. 2022. Available at, <https://www.who.int/publications/i/item/WHO-MPX-Immunization-2022.2-eng>. Accessed August 24, 2022.
- 64.** European Medicines Agency. Summary of product characteristics - Imvanex. Available at, [https://www.ema.europa.eu/en/documents/product-information/imvanex-epar-product-information\\_en.pdf](https://www.ema.europa.eu/en/documents/product-information/imvanex-epar-product-information_en.pdf). Accessed June 11, 2022.
- 65.** Kozlov M. Monkeypox vaccination begins - can the global outbreaks be contained? *Nature* 2022;606:444–5.
- 66.** Qiu X, Bailey H, Thorne C. Barriers and facilitators associated with vaccine acceptance and uptake among pregnant women in high income countries: a mini-review. *Front Immunol* 2021;12:626717.
- 67.** Dashraath P, Nielsen-Saines K, Madhi SA, Baud D. COVID-19 vaccines and neglected pregnancy. *Lancet* 2020;396:e22.
- 68.** Stuckelberger S, Favre G, Ceulemans M, et al. SARS-CoV-2 vaccine willingness among pregnant and breastfeeding women during the first pandemic wave: a cross-sectional study in Switzerland. *Viruses* 2021;13:1199.
- 69.** World Health Organization. Emergency use of unproven clinical interventions outside clinical trials: ethical considerations. 2022. Available at <https://apps.who.int/iris/rest/bitstreams/1416840/retrieve>. Accessed June 11, 2022.
- 70.** Krubiner CB, Faden RR, Karron RA, et al. Pregnant women and vaccines against emerging epidemic threats: ethics guidance for preparedness, research, and response. *Vaccine* 2021;39:85–120.
- 71.** World Health Organization. Meeting on monkeypox research priorities. 2022. Available at [https://cdn.who.int/media/docs/default-source/blue-print/day-2\\_meeting-summary\\_monkeypox-meeting\\_03june2022.pdf?sfvrsn=f4ec1066\\_3](https://cdn.who.int/media/docs/default-source/blue-print/day-2_meeting-summary_monkeypox-meeting_03june2022.pdf?sfvrsn=f4ec1066_3). Accessed June 11, 2022.

## Appendix

**SUPPLEMENTAL FIGURE 1****Oral and perioral lesions in monkeypox**

**A**, Perioral umbilicated lesions. **B**, Perioral vesicular lesion on day 8, positive PCR test result. **C**, Ulcer on the left corner of the mouth on day 7, positive PCR test result. **D**, Tongue ulcer. **E**, Tongue lesion on day 5, positive PCR test result. **F**, **G**, and **H**, Pharyngeal lesions on days 0, 3, and 21, respectively, positive PCR test result on days 0 and 3 and negative PCR test result on day 21. Reproduced, with permission, from Thornhill et al.<sup>1</sup>

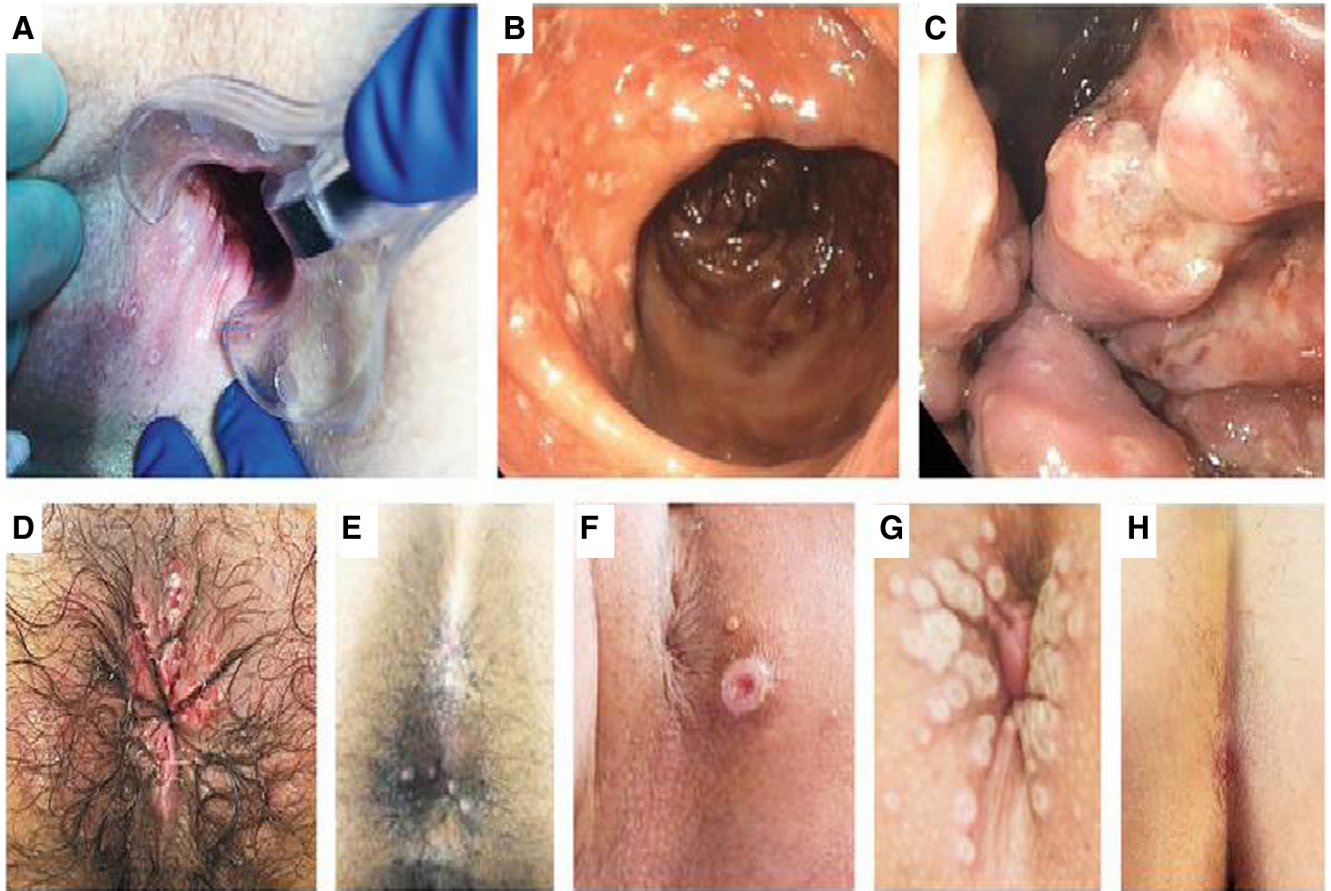
PCR, polymerase chain reaction.

Dashraath. Monkeypox and pregnancy. *Am J Obstet Gynecol* 2022.



## SUPPLEMENTAL FIGURE 2

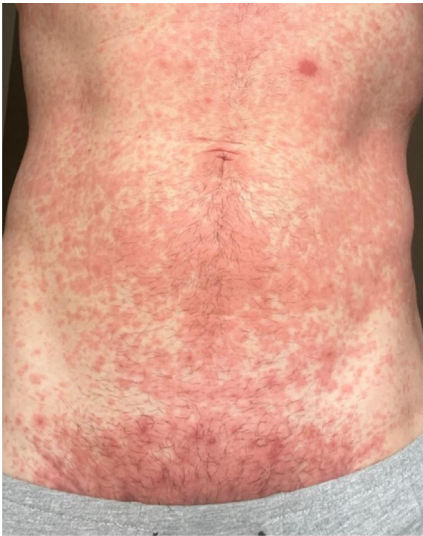## Perianal, anal, and rectal lesions in monkeypox



**A**, Anal and perianal lesions on day 6, positive PCR test result. **B and C**, Rectal and anal lesions in a single person, positive PCR test result. **D**, Perianal ulcers, positive PCR test result. **E**, Anal lesions. **F**, Umbilicated perianal lesion on day 3, positive PCR test result. **G**, Umbilicated perianal lesions on day 3, positive PCR test result. **H**, Perianal ulcer on day 2, positive PCR test result. In the context of pregnancy, these lesions might be confused with genital herpes, syphilis, or lymphogranuloma venereum. Reproduced, with permission, from Thornhill et al.<sup>1</sup>

PCR, polymerase chain reaction.

Dashraath. Monkeypox and pregnancy. *Am J Obstet Gynecol* 2022.

**SUPPLEMENTAL FIGURE 3**  
**Maculopapular rash in monkeypox**

In the context of pregnancy, a maculopapular rash such as this might be confused with pruritic urticarial papules and plaques of pregnancy. Reproduced, with permission, from Thornhill et al.<sup>1</sup>

*Dashraath. Monkeypox and pregnancy. Am J Obstet Gynecol 2022.*

## SUPPLEMENTAL TABLE

## Current and novel therapies for monkeypox and their safety in pregnancy

CDC and WHO options	Licensed indication	Effectiveness data against monkeypox in humans	Reproductive safety data in animals	Reproductive safety data in humans	Notes
Small molecules					
Tecovirimat	1. Authorization by the EMA for the treatment of orthopoxvirus infections (cowpox, monkeypox, and smallpox) and to treat complications because of replication of vaccinia virus after vaccination against smallpox in adults and children with a body weight of at least 13 kg 2. Authorization by the FDA is limited to human smallpox disease in adults and pediatric patients weighing at least 13 kg. Therefore, the CDC provides a nonresearch EA-IND protocol that allows its use for treatment of nonvariola orthopoxvirus infections, including monkeypox, in adults and children of all ages	None <sup>2</sup> ; effectiveness relies on animal studies	Reproductive risk assessment based on available animal reproductive toxicity studies are inconclusive as the chosen dosage margins were questionable <sup>3</sup>	None	May be safe in pregnancy Effectiveness data are required for a risk-benefit assessment
Cidofovir	1. Authorization by the EMA and the FDA for the treatment of CMV retinitis in adult patients with AIDS without renal impairment, when other therapies are considered inappropriate Medical countermeasure in case of smallpox or monkeypox bioterrorism attack by the US government	None <sup>2</sup> ; effectiveness relies on animal studies	Studies have shown that cidofovir is clastogenic in vitro and is embryotoxic in rats and rabbits at doses below the one used in human therapeutics <sup>4</sup>	None	Best avoided in pregnancy unless critically ill (teratogenic potential) Renal toxicity resulting in kidney damage is the major dose-limiting side effect of cidofovir
Brincidofovir	1. In 2016, orphan designation (EU/3/16/1697) was granted by the European Commission for the treatment of adenovirus infection in immunocompromised patients 2. Authorization in 2021 by the FDA for the treatment of smallpox in adult and pediatric patients, including neonates	None <sup>2</sup> ; effectiveness relies on animal studies	Studies have shown that brincidofovir is clastogenic in vitro and is embryotoxic in rats and rabbits at doses below the one used in human therapeutics <sup>5</sup>	None	Best avoided in pregnancy unless critically ill (teratogenic potential) Brincidofovir is a prodrug of cidofovir with a lipid conjugate that improves drug delivery to the target cells and greatly reduces nephrotoxicity

Dashraath. Monkeypox and pregnancy. *Am J Obstet Gynecol* 2022.

(continued)

## SUPPLEMENTAL TABLE

## Current and novel therapies for monkeypox and their safety in pregnancy (continued)

CDC and WHO options	Licensed indication	Effectiveness data against monkeypox in humans	Reproductive safety data in animals	Reproductive safety data in humans	Notes
Intravenous immunoglobulin					
VIGIV	Authorization by the FDA for the treatment of complications from vaccinia virus vaccination	None	Carcinogenicity, genotoxicity, and fertility studies have not been conducted with VIGIV <sup>5</sup>	None specific to VIGIV; evidence of relative safety of other intravenous immunoglobulin treatments therapies used in pregnancy (eg, anti-D immunoglobulin and varicella zoster immunoglobulin)	Very likely safe in pregnancy
Vaccines					
ACAM2000: second-generation smallpox vaccine	FDA approved live vaccinia virus vaccine to prevent smallpox May be used under nonresearch EA-IND protocol for the treatment of monkeypox	Smallpox effectiveness based on 2 pivotal clinical trials that demonstrated noninferiority to Dryvax (a first-generation vaccine used to eradicate smallpox) As MPXV is closely related to the smallpox virus, the smallpox vaccine is considered cross-protective against monkeypox with an 85% effectiveness rate <sup>7</sup>	None found	As a live vaccinia virus, it can cause fetal vaccinia, a rare (ranges from 1/10,000 to 1/100,000) but serious complication of exposure during pregnancy that often results in fetal or neonatal death <sup>8,9</sup> Data from a meta-analysis of 12,201 pregnant women showed that live smallpox vaccination was not associated with an increased risk of congenital defects (pooled RR, 1.25; 95% CI, 0.99–1.56) or fetal vaccinia in any trimester of pregnancy <sup>10</sup>	Best avoided in pregnancy Administered percutaneously using the multiple puncture technique and creating a lesion in case of successful inoculation (ie, called a “take”). Unvaccinated persons who have close contact with the inoculation site can be infected with the vaccinia virus More highly stockpiled by countries than the newer MVA-BN and LC16 vaccines <sup>11</sup>
MVA-BN (also called Imvanex, Jynneos, or Imvamune): third-generation smallpox vaccine	The FDA (2019) and the EMA (2013) approved a replication-deficient vaccine (Ankara vaccine) for the prevention of smallpox The FDA approved (2019) for the prevention of monkeypox as well	Effectiveness relies on comparative immunogenicity and protection studies in animal studies, but effectiveness rate is considered similar to ACAM2000	Studies assessing fertility and embryofetal and postnatal toxicity did not reveal any particular risk to humans	300 exposed pregnancies with follow-up without safety signal <sup>12</sup> Replication-deficient virus technology carries a low risk of fetal vaccinia	Likely safe in pregnancy Administered subcutaneously as 2 doses separated by 4 wk (1 dose at week 0 and a second dose at week 4) for primary vaccinees and 1 dose for individuals previously vaccinated against smallpox
LC16: third-generation smallpox vaccine	Japan (1975) approved live attenuated (minimally replicating) smallpox vaccine for the prevention of smallpox The FDA (2014) provided a nonresearch EA-IND protocol for smallpox <sup>13</sup>	Effectiveness relies on comparative immunogenicity and protection studies in animal studies <sup>14</sup>	None found	None found	Theoretically less risk of developing fetal vaccinia than ACAM2000 Administered similar to ACAM2000

## SUPPLEMENTAL TABLE

## Current and novel therapies for monkeypox and their safety in pregnancy (continued)

CDC and WHO options	Licensed indication	Effectiveness data against monkeypox in humans	Reproductive safety data in animals	Reproductive safety data in humans	Notes
Novel agents for repurposing or in the development stage					
Imatinib <sup>15</sup>	The FDA and the EMA approved for the treatment of cancer	None; antiviral activity against orthopoxvirus in in vitro infection models	Studies have shown that imatinib is clastogenic in vitro and is teratogenic in rats and rabbits at the maximal doses used in human therapeutics	Case reports showing normal and abnormal outcomes <sup>16</sup>	Best avoided in pregnancy (teratogenic)
Olomoucine <sup>15</sup>	Preclinical research stage	None; antiviral activity against orthopoxvirus in in vitro infection models	None found	None	NA
Terameprocol <sup>15</sup>	Clinical research phase 1	None; antiviral activity against orthopoxvirus in in vitro infection models	None found	None	NA
Mitoxantrone <sup>15</sup>	The FDA and the EMA approved for the treatment of cancer	None; antiviral activity against orthopoxvirus in in vitro infection models	Studies have shown that mitoxandrone is clastogenic and mutagenic in vitro and is fetotoxic in rats and rabbits at doses below the one used in human therapeutics <sup>17</sup>	Considered a potential human teratogen because of its mechanism of action	Best avoided in pregnancy (teratogenic)
Bisbenzimidazole derivatives <sup>15</sup>	Preclinical research stage	None; antiviral activity against orthopoxvirus in in vitro infection models	None found	None	NA
Resveratrol <sup>18</sup>	Preclinical research stage	None; antiviral activity against orthopoxvirus in in vitro infection models	None found	None	NA

CDC, Centers for Disease Control and Prevention; CI, confidence interval; CMV, cytomegalovirus; EA-IND, Expanded Access for an Investigational New Drug; EMA, European Medicines Agency; FDA, Food and Drug Administration; MPXV, monkeypox virus; NA, not available; RR, risk ratio; VIGIV, vaccinia immune globulin intravenous; WHO, World Health Organization.

Dashraath. Monkeypox and pregnancy. *Am J Obstet Gynecol* 2022.

## SUPPLEMENTAL REFERENCES

1. Thornhill JP, Barkati S, Walmsley S, et al. Monkeypox virus infection in humans across 16 countries - April-June 2022. *N Engl J Med* 2022;387:679–91.
2. Centers for Disease Control and Prevention. Treatment Information for Healthcare Professionals. 2022. Available at <https://www.cdc.gov/poxvirus/monkeypox/clinicians/treatment.html#Tecovirimat>. Accessed June 10, 2022.
3. European Medicines Agency. Assessment report — tecovirimat. Available at, [https://www.ema.europa.eu/en/documents/overview/tecovirimat-siga-epar-medicine-overview\\_en.pdf](https://www.ema.europa.eu/en/documents/overview/tecovirimat-siga-epar-medicine-overview_en.pdf). Accessed June 10, 2022.
4. Gilead Sciences. VISTIDE® (cidofovir injection). 2022. Available at [https://www.accessdata.fda.gov/drugsatfda\\_docs/label/1999/020638s003lbl.pdf](https://www.accessdata.fda.gov/drugsatfda_docs/label/1999/020638s003lbl.pdf). Accessed June 10, 2022.
5. Brincidofovir summary of product characteristics. 2022. Available at <https://www.chimerix.com/wp-content/uploads/2021/06/TEMBEXA-USPI-and-PPI-04.June2021.pdf>. Accessed June 10, 2022.
6. VIGIV prescribing information. 2022. Available at <https://www.fda.gov/media/77004/download>. Accessed June 10, 2022.
7. Centers for Disease Control and Prevention. Monkeypox and smallpox vaccine guidance. 2022. Available at <https://www.cdc.gov/poxvirus/monkeypox/clinicians/smallpox-vaccine.html>. Accessed June 10, 2022.
8. Suarez VR, Hankins GD. Smallpox and pregnancy: from eradicated disease to bioterrorist threat. *Obstet Gynecol* 2002;100:87–93.
9. Levine MM. Live-virus vaccines in pregnancy. Risks and recommendations. *Lancet* 1974;2:34–8.
10. Badell ML, Meaney-Delman D, Tuuli MG, et al. Risks associated with smallpox vaccination in pregnancy: a systematic review and meta-analysis. *Obstet Gynecol* 2015;125:1439–51.
11. Kozlov M. Monkeypox vaccination begins - can the global outbreaks be contained? *Nature* 2022;606:444–5.
12. European Medicines Agency. Summary of product characteristics — Imvanex. Available at, [https://www.ema.europa.eu/en/documents/product-information/imvanex-epar-product-information\\_en.pdf](https://www.ema.europa.eu/en/documents/product-information/imvanex-epar-product-information_en.pdf). Accessed June 10, 2022.
13. Otu A, Ebenso B, Walley J, Barceló JM, Ochu CL. Global human monkeypox outbreak: atypical presentation demanding urgent public health action. *Lancet Microbe* 2022;3:e554–5.
14. Kenner J, Cameron F, Empig C, Jobes DV, Gurwith M. LC16m8: an attenuated smallpox vaccine. *Vaccine* 2006;24:7009–22.
15. Bugert JJ, Huckle F, Zanetta P, Bassetto M, Brancale A. Antivirals in medical biodefense. *Virus Genes* 2020;56:150–67.
16. Dolai TK, Bhargava R, Mahapatra M, et al. Is imatinib safe during pregnancy? *Leuk Res* 2009;33:572–3.
17. European Medicines Agency. Summary of product characteristics — mitoxantrone. Available at, [https://www.ema.europa.eu/en/documents/referral/novantrone-article-30-referral-annex-iii\\_en.pdf](https://www.ema.europa.eu/en/documents/referral/novantrone-article-30-referral-annex-iii_en.pdf). Accessed June 10, 2022.
18. Cao S, Realegeno S, Pant A, Satheshkumar PS, Yang Z. Suppression of poxvirus replication by resveratrol. *Front Microbiol* 2017;8:2196.