

# UCSF

## UC San Francisco Previously Published Works

### Title

Management of infantile hemangiomas during the COVID pandemic

### Permalink

<https://escholarship.org/uc/item/6jn9x00t>

### Journal

Pediatric Dermatology, 37(3)

### ISSN

0736-8046

### Authors

Frieden, Ilona J  
Püttgen, Katherine B  
Drolet, Beth A  
[et al.](#)

### Publication Date

2020-05-01

### DOI

10.1111/pde.14196

Peer reviewed



DR ILONA J. FRIEDEN (Orcid ID : 0000-0001-7305-5940)

DR CHRISTINE T. LAUREN (Orcid ID : 0000-0002-7278-4831)

DR ANITA N. HAGGSTROM (Orcid ID : 0000-0002-9088-8079)

DR EULALIA BASELGA (Orcid ID : 0000-0003-1086-8439)

DR CATHERINE C. MCCUAIG (Orcid ID : 0000-0003-0792-6247)

DR DENISE W. METRY (Orcid ID : 0000-0003-1991-1683)

DR SHEILAGH MAGUINESS (Orcid ID : 0000-0002-0033-8285)

Article type : Arts, Humanities and Contemporary Social Issues in Pediatric Dermatology

#### TITLE PAGE:

### Management of Infantile Hemangiomas during the COVID Pandemic

Ilona J. Frieden MD<sup>1</sup>, Katherine B. Püttgen MD<sup>2</sup>, Beth A. Drolet MD<sup>3</sup>, Maria C. Garzon MD<sup>3</sup>, Sarah L. Chamlin MD<sup>5</sup>, Elena Pope MD<sup>6</sup>, Anthony J. Mancini MD<sup>5</sup>, Christine T. Lauren MD MHA<sup>4</sup>, Erin F. Mathes MD<sup>1</sup>, Dawn H. Siegel MD<sup>7</sup>, Deepti Gupta MD<sup>8</sup>, Anita N. Haggstrom MD<sup>9</sup>, Megha M. Tollefson MD<sup>10</sup>, Eulalia Baselga MD<sup>11</sup>, Kimberly D. Morel MD<sup>4</sup>, Sonal D. Shah MD<sup>1</sup>, Kristen E. Holland MD<sup>7</sup>, Denise M. Adams MD<sup>12</sup>, Kimberly A. Horii MD<sup>13</sup>, Brandon D. Newell MD<sup>13</sup>, Julie Powell MD<sup>14</sup>, Catherine C. McCuaig MD<sup>14</sup>, Amy J. Nopper MD<sup>13</sup>, Denise W. Metry MD<sup>15</sup>, Sheilagh Maguiness<sup>16</sup> for the Hemangioma Investigator Group

#### Affiliations:

<sup>1</sup>University of California San Francisco, San Francisco, California; <sup>2</sup>Intermountain Healthcare, Salt Lake City, Utah; <sup>3</sup>School of Medicine and Public Health, University of Wisconsin; <sup>4</sup> Columbia University Vagelos College of Physicians and Surgery, New York, New York; <sup>5</sup>Ann & Robert H. Lurie Children's Hospital of Chicago/Northwestern University Feinberg School of Medicine, Chicago, IL; <sup>6</sup>The Hospital for Sick Children and University of Toronto; <sup>7</sup>Medical College of Wisconsin, Milwaukee, Wisconsin; <sup>8</sup>Seattle Children's Hospital/University of Washington School of Medicine, Seattle, Washington; <sup>9</sup>Indiana University, Indianapolis, Indiana; <sup>10</sup>Mayo Clinic, Rochester, Minnesota; <sup>11</sup> Hospital Sant Joan de Deu, Barcelona; <sup>12</sup> Harvard Medical School, Boston, Massachusetts; <sup>13</sup>University of Missouri – Kansas City, Kansas City, Missouri; <sup>14</sup> Division of Pediatric Dermatology, Department of Pediatrics, Sainte-Justine

This article has been accepted for publication and undergone full peer review but has not been through the copyediting, typesetting, pagination and proofreading process, which may lead to differences between this version and the Version of Record. Please cite this article as doi:

10.1111/PDE.14196

This article is protected by copyright. All rights reserved

University Hospital Centre, University of Montreal, Montreal, Quebec, Canada, <sup>15</sup> Baylor College of Medicine, Houston, Texas, <sup>16</sup>University of Minnesota, Minneapolis, Minnesota.

**Corresponding author:**

Ilona J. Frieden MD

Ilona.frieden@ucsf.edu

**Funding Sources:** None

**Financial Disclosures:**

Ilona J. Frieden- Venthera Medical Advisory Board; Other: Pfizer (Data Safety Monitoring Board)

Katherine B. Püttgen No conflicts of interest to declare.

Beth A. Drolet- Investigator initiated trial funded by Pierre Fabre; Venthera Consultant and Medical Advisory, Founder Peds Derm Development, LLC

Maria C. Garzon MD No relevant conflicts of interest.

Sarah L. Chamlin MD No relevant conflicts of interest. Other: Regeneron (consultant), Sanofi (consultant)

Elena Pope MD Investigator Pierre Fabre

Anthony J. Mancini MD No conflicts of interest to declare

Christine T. Lauren MD No conflicts of interest to declare

Erin F. Mathes MD No conflicts of interest to declare

Dawn H. Siegel MD Arqule (expert reviewer)

Deepti Gupta MD No conflicts of interest to declare

Anita N. Haggstrom MD No conflicts of interest to declare

Megha M. Tollefson MD No conflicts of interest to declare

Eulalia Baselga MD Pierre Fabre advisory board and consultant; Venthera- Co-founder and Medical Advisor

Kimberly D. Morel MD No conflicts of interest to declare

Sonal D. Shah MD No conflicts of interest to declare

Kristen E. Holland MD No relevant conflicts of interest; Other: Pfizer (investigator, consultant), Regeneron (consultant), Celgene (investigator), Sanofi (investigator)

Denise M. Adams MD Venthera (Advisory Board), Novartis (Advisory Board)

Kimberly A. Horii MD No conflicts of interest to declare

Brandon D. Newell MD No conflicts of interest to declare

Julie Powell MD Pierre-Fabre Dermatology (Advisory Board, Speaker)

Catherine C. McCuaig No conflicts of interest to declare

Amy J. Nopper MD No conflicts of interest to declare

Denise W. Metry MD No conflicts of interest to declare

Sheilagh Maguiness No conflicts of interest to declare

## **ABSTRACT**

The COVID-19 pandemic has caused significant shifts in patient care including a steep decline in ambulatory visits and a marked increase in the use of telemedicine. Infantile hemangiomas can require urgent evaluation and risk stratification to determine which infants need treatment and which can be managed with continued observation. For those requiring treatment, prompt initiation decreases morbidity and improves long-term outcomes. The Hemangioma Investigator Group has created consensus recommendations for management of infantile hemangiomas via telemedicine. FDA/EMA approved monitoring guidelines, clinical practice guidelines and relevant, up-to-date publications regarding initiation and monitoring of beta-blocker therapy were used to inform the recommendations. Clinical decision-making guidelines about when telehealth is an appropriate alternative to in-office visits, including medication initiation, dosage changes, and ongoing evaluation are included. The importance of communication with caregivers in the context of telemedicine is discussed and online resources for both hemangioma education and for propranolol therapy provided.

## **Introduction:**

The novel coronavirus (COVID-19) pandemic has drastically altered healthcare delivery including widespread reductions in ambulatory visits to minimize exposure to and transmission of COVID-19 resulting in unprecedented adoption of virtual care via telemedicine platforms. In light of these significant shifts in patient care, the Hemangioma Investigator Group (HIG) met with the goal of creating consensus recommendations to provide timely care for infants with IH via telehealth. The use of beta-blockers in the treatment of infantile hemangiomas (IH) has revolutionized care and recent American Academy of Pediatrics (AAP) clinical practice guidelines (CPG) emphasize that early therapeutic intervention is critical for complicated IH to prevent medical complications or permanent disfigurement<sup>1</sup>. In this statement, we review FDA/EMA approved monitoring guidelines, information derived from several clinical practice guidelines, and other publications regarding initiation and monitoring of beta-blocker therapy, including newly published information which could help inform modification of these practices. We give recommendations to help guide decisions about when telehealth may be an alternative to in-office visits, including initiation, dosage changes, and continued evaluation for those patients requiring treatment. We also provide tools for patient communication in context of telemedicine. While these recommendations were prompted by the COVID-19 pandemic, we recognize that they might be relevant in analogous settings where there is a disruption of the normal delivery of medical care and potentially in settings with lack of access to practitioners with expertise in IH management.

## **Methods**

The Hemangioma Investigator Group (HIG) met via videoconferencing on March 22, 2020, and subdivided members into 3 groups: one to work on the introduction and discussion, one to create a table of inclusion and exclusion criteria for telemedicine use of beta-blockers, and one to curate available patient-education materials for practitioners and parents. Through an iterative process of review of these 3 components we were able to achieve unanimous consensus regarding the content of these recommendations.

### **Risk stratification and timing of therapeutic intervention, when needed:**

The most rapid IH growth occurs between 1 and 3 months of age and there is a “window of opportunity” to treat problematic IHs in order to prevent morbidities. Telemedicine has a critical role to play in facilitating early evaluation and risk stratification. In areas where access to specialists has long been challenging, telemedicine triage has the potential to improve care for high risk IH. Early consultation, ideally by 1 month of age or as soon as high-risk features are recognized is warranted. Table 1, from the AAP CPG, delineates risk categories of IH and potential associated morbidities.

### **Potential risks associated with beta-blocker treatment:**

Oral beta-blockers are the gold standard when systemic treatment is indicated for IH and propranolol solution is the only FDA/EMA-approved treatment. Methods for initiation of oral propranolol have evolved over time. Consensus recommendations prior to the FDA/EMA approval in 2014 included;<sup>10</sup> 1) screening for contraindications to propranolol, 2) performing or obtaining documentation of, a recent normal cardiovascular and pulmonary history and examination, 3) obtaining key historical data including poor feeding, dyspnea, tachypnea,

Accepted Article

diaphoresis, wheezing, heart murmur, or family history of heart block or arrhythmia, and 4) prolonged in-office monitoring. The FDA/EMA approved administration monitoring recommendations include in-office heart rate (HR) and blood pressure (BP) monitoring for 2 hours after the first dose of propranolol or for increasing the dose ( $>0.5$  mg/kg/day) for infants 5 weeks adjusted gestational age or older.<sup>10 11</sup> More recent consensus statements<sup>1, 12, 13, 14</sup> vary in specific recommendations for propranolol initiation. Both Australian and British guidelines<sup>13,14</sup> recommend full-term healthy infants without comorbidities may undergo outpatient initiation without in-office monitoring with initial doses of 1 mg/kg/day.<sup>13,14</sup> Both state that a thorough medical history and clinical examination including HR are prerequisites to initiation of systemic therapy. A recent study by Puttgen et al<sup>15</sup> of 783 patients with in-office monitoring during medication initiation found no symptomatic bradycardia or hypotension occurred during the in-office monitoring and minimal, clinically insignificant decrease in HR (mean decrease of 8 to 9 beats per minute). Many practitioners have moved away from in-office monitoring for those infants of gestationally corrected age of 5 weeks or older with normal birth-weight unless other risk factors exist.

While rare, hypoglycemia, seen primarily with intercurrent illness or decreased feeding, is a serious potentially life-threatening risk.<sup>16</sup> Other risks include bronchospasm and wheezing, usually in the context of a respiratory illness, cold hands and feet, gastrointestinal upset, and sleep disturbances. All of these potential adverse events require anticipatory guidance of parents, which should still be a part of clinical care, whether in person or via telemedicine.

### **Other orally administered beta blockers and topical beta blockers**

Other non-FDA approved beta-blocking agents, including oral atenolol and nadolol, have been used for the treatment of IH with several publications supporting their efficacy. However, the group was unable to reach consensus recommendation regarding telemedicine for initiation of either of these medications. Topical timolol has been widely used for treating IH with efficacy reported, particularly for small, superficial IH.<sup>9,15</sup> Systemic absorption is variable but does occur,<sup>17,18</sup> suggesting that similar prescreening should be performed to assure that infants are healthy and have had a normal cardiovascular and pulmonary examinations e.g. via recent history and physical exam (see discussion below).

### **RECOMMENDATIONS:**

Our recommendations regarding telemedicine initiation of beta-blocker therapy are summarized in Table 2 with an accompanying algorithm (Figure 1). They were developed after review of relative and absolute contraindications for propranolol, reported adverse events, FDA/EMA labelling recommendations, published guidelines, with group consensus. They are made with the goal of supporting practicing clinicians in delivering high quality care in a dramatically altered care delivery model. They apply primarily to new patients, but also for return patients who are being started on a systemic beta-blocker.

Group 1 patients have characteristics which confer a standard risk. These infants can be considered as appropriate candidates for telemedicine initiation of oral or topical beta-blocker therapy even in the absence of an in-person visit. Group 2 includes patients with higher risk characteristics, where the risk-benefit ratio favors in-person visit, not only for propranolol initiation but to discuss management, risk of extra-cutaneous disease, and to arrange for imaging



Accepted Article  
studies if needed. These characteristics might be considered relative or absolute exclusion criteria for initiation of medication via telemedicine, particularly systemic beta-blockers, and for these infants, telemedicine should be used only in exceptional circumstances.

There was broad consensus that in settings where there are not disruptions of ambulatory care delivery, in-person evaluation for new patients, particularly young infants, is the best approach.

Physical examination is more thorough and may provide a more accurate assessment of baseline status including subtle clues (such as duskiness) suggestive of impending ulceration, and the presence of deeper hemangioma not evident with photographs or video without palpation. Other advantages of in-person assessment include more accurate assessment of weight, confirmation of respiratory and cardiovascular status, and the opportunity for face-to-face counseling and establishing rapport with families, the latter being particularly important for infants who need treatment, since the medications used for IH are typically continued for many months or longer.

The most commonly used target doses of propranolol are between 2 and 3 mg/kg/day divided twice daily with FDA/EMA recommendations for starting with 1 mg/kg/day and increasing weekly by 1 mg/kg/day to target dose. However in the context of outpatient initiation via telemedicine, our group unanimously agreed that starting with a lower dose of 0.5 mg/kg/day divided twice daily, and increasing every 3 to 4 days by 0.5 mg/kg/day to the target dose was a preferred approach. A minority commented that in a typical standard risk infant, they would consider starting at 1 mg/kg/day divided twice, increasing in 0.5 mg/k/day increments every 3 to 4 days to target dosing.

There was uniform consensus that in most cases follow-up visits can be performed via telemedicine either via two-way synchronous video or asynchronous store-and-forward photos with telephone counseling as long as it is possible to examine the infant's hemangioma

adequately and to provide sufficient parental counseling . Even if video visits are used, having photographs of the IH uploaded shortly before a telemedicine visit is often necessary to be able to adequately evaluate the IH, given the variability of visualization with live-interactive portals.

Clinical situations which may be less optimal for follow-up telemedicine visits include diagnostic uncertainty, unexpected IH growth, functional impairment, or significant or worsening ulceration. If there is medication intolerance or lack of efficacy requiring consideration of another treatment modality (e.g. transition from topical to systemic therapy or addition of another systemic agent), then providers should consider whether a telemedicine visit is sufficient to address the clinical scenario or if an in-person visit is indicated.

### **Use of topical timolol**

Topical timolol is efficacious for smaller, thin IH.<sup>17,19,20</sup> Although rigorous safety studies have not been performed, if used in small amounts, the rate of adverse events is very low<sup>19</sup>. Systemic absorption occurs to varying degrees measurable in both urine and plasma; plasma concentrations demonstrated to have measurable systemic  $\beta$ -blocking activity in adults have been reported.<sup>17,18,21</sup> Based on this information, we recommend that timolol application should be limited to the dose for which safety data have been most often reported, 1 drop twice daily of timolol 0.5%. Timolol is not recommended for the treatment of thick or deep IH, both because it is less effective and systemic absorption may be greater.<sup>18</sup> Because of the potential for systemic exposure of topical application, pre-screening should be performed to assure that infants are healthy with normal cardiopulmonary examinations via recent history and physical exam. As with oral beta-blockers, temporary discontinuation is recommended if patients experience respiratory or gastrointestinal symptoms. Infants under 3 months of age, and those whose history suggests ongoing IH growth, should be monitored via frequent visits or photographs

submitted by parents to assure that therapy does not need to be switched from topical to oral.

Such follow-up visits can often be done via telemedicine.

## **DISCUSSION:**

The COVID-19 pandemic has caused an abrupt shift from ambulatory visits to telemedicine platforms. This consensus statement provides guidance on timely treatment for patients with IH requiring early intervention while prioritizing patient safety. While we acknowledge the benefits of in-person visits when health care systems are operating normally, there was group consensus that telehealth visits could provide an alternative method of evaluation and treatment *as long as safeguards are in place to minimize risks*. Our recommendations are based upon first ensuring that there are no contraindications for therapy, documentation of a recent normal physical examination, and no signs or symptoms of active illness (Table 2). We suggest that these patients are amenable to initiation of therapy through a process of limited physical examination coupled with virtual counseling and education about the natural history, treatment options, administration of medication and potential adverse reactions to therapy.

We recognize that there are other circumstances in which these recommendations may be applicable including natural disasters (e.g. earthquakes, hurricanes). In addition, there are patients whose access to specialty care is severely limited due to geographic constraints (e.g. living many hours away from a center with expertise in the evaluation and management of IH) where these recommendations may prove beneficial.

With or without telemedicine, all patients with IH require careful consideration of risks and benefits of any proposed treatment, discussion with families regarding treatment options, and recommendations and information about possible adverse events from prescribed medications

(Table 3). For IH still in the rapid growth phase, we recommend particularly close follow-up, ideally within 1-2 weeks. Telemedicine is particularly well-suited for these typically brief follow-up visits to assure that the IH is behaving as anticipated. Parents should be advised to reach out to practitioners in the context of changes in the IH (e.g. ulceration, ongoing growth, development/progression of functional impairment). If the patient develops respiratory symptoms (e.g. cough, wheezing, respiratory distress), gastrointestinal symptoms (e.g. vomiting, diarrhea, decreased intake) or lethargy, medication should be immediately discontinued and a physician notified.<sup>22</sup> Although infection with COVID-19 in young infants and toddlers most often does not result in severe symptoms, it can cause respiratory illness. Similar to other infections which can result in fever or respiratory symptoms, we recommend temporarily stopping propranolol in the setting of active infant COVID-19 infection until symptoms from the infection cease.<sup>2</sup> Comprehensive counseling and communication of potential risks and benefits of treatment are of paramount importance both for anticipatory guidance and to help minimize side effects. Online resources (Table 3) can be very helpful both in reinforcing education regarding the diagnosis of IH as well as specifics of treatment and possible side effects.

## References

1. Krowchuk DP, Frieden IJ, Mancini AJ, et al. Clinical Practice Guideline for the management of infantile hemangiomas. *Pediatrics*. 2019 Jan;143(1). pii: e20183475. doi: 10.1542/peds.2018-3475.
2. Dong Y, Mo X, Hu Y, Qi X, Jiang F, Jiang Z, et al. Epidemiological characteristics of 2143 pediatric patients with 2019 coronavirus disease in China. *Pediatrics*. 2020 Mar 16. pii: e20200702. doi: 10.1542/peds.2020-0702. [Epub ahead of print]
3. Garzon MC, Epstein LG, Heyer GL, et al. PHACE Syndrome: consensus-derived diagnosis and care recommendations. *J Pediatr*. 2016 Nov;178:24-33.e2.
4. de Graaf M, Knol MJ, Totté JE, et al. E-learning enables parents to assess an infantile hemangioma. *J Am Acad Dermatol*. 2014 May;70(5):893-8.
5. Léauté-Labrèze C, Baselga Torres E, Weibel L, et al. The infantile hemangioma referral score: a validated tool for physicians. *Pediatrics*. 2020 April; 145(4). pii: e20191628. ]
6. Agency for Healthcare Research and Quality. Effective health care program. Diagnosis and management of infantile hemangioma. Available at: <https://effectivehealthcare.ahrq.gov/products/infantile-hemangioma/research> Accessed March 30, 2020.
7. Léauté-Labrèze C, Hoeger P, Mazereeuw-Hautier J, et al. A randomized, controlled trial of oral propranolol in infantile hemangioma. *N Engl J Med*. 2015 Feb 19;372(8):735-46.
8. Hemangeol (propranolol hydrochloride oral solution [package insert]. Parsippany, NJ . Pierre Fabre Pharmaceuticals, Inc. March 2014
9. Robert J, Tavernier E, Boccara O, Mashiah J, Mazereeuw-Hautier J, Maruani A. Modalities of use of oral propranolol in proliferative infantile hemangiomas: an international survey among practitioners. *Br J Dermatol*. 2020 Mar 27. doi: 10.1111/bjd.19047. [Epub ahead of print] PubMed PMID: 32221977.
10. Drolet BA, Frommelt PC, Chamlin SL, et al. Initiation and use of propranolol for infantile hemangioma: report of a consensus conference. *Pediatrics*. 2013 Jan;131(1):128-40.
11. Putterman E, Wan J, Streicher JL, Yan AC. Evaluation of a modified outpatient model for using propranolol to treat infantile hemangiomas. *Pediatr Dermatol*. 2019 Jul;36(4):471-476. doi: 10.1111/pde.13843. Epub 2019 May 23. PMID: 31120143
12. Hoeger PH, Harper JI, Baselga E, et al. Treatment of infantile haemangiomas: recommendations of a European expert group. *Eur J Pediatr*. 2015;174(7):855–865
13. Solman L, Glover M, Beattie PE, et al. Oral propranolol in the treatment of proliferating infantile haemangiomas: British Society for Paediatric Dermatology consensus guidelines. *Br J Dermatol*. 2018 Sep;179(3):582-589.
14. Smithson SL, Rademaker M, Adams, S, et al. Consensus statement for the treatment of infantile haemangiomas with propranolol. *Australasian J Derm*. 2017 May;58(2):155-159.

- Accepted Article
15. Püttgen KB, Hansen LM, Lauren C, MD, et al. Utility of repeated vital sign monitoring during initiation of oral propranolol for complicated infantile hemangioma *J Am Acad Dermatol* 2020 In Press.
  16. Wedgeworth E, Glover M, Irvine AD, et al. Propranolol in the treatment of infantile haemangiomas: Lessons from the European Propranolol In the Treatment of Complicated Haemangiomas (PITCH) taskforce survey. *Br J Dermatol*. 2016 Mar;174(3):594-601.
  17. Borok J, Gangar P, Admani S, Proudfoot J, Friedlander SF. Safety and efficacy of topical timolol treatment of infantile haemangioma: A prospective trial. *Br J Dermatol*. 2018 Jan;178(1):e51-e52.
  18. Drolet BA, Boakye-Agyeman F, Harper B, et al. Systemic timolol exposure following topical application to infantile hemangiomas. *J Am Acad Dermatol*. 2020 Mar;82(3):733-736.
  19. Püttgen K, Lucky A, Adams D, et al. Hemangioma Investigator Group. Topical timolol maleate treatment of infantile hemangiomas. *Pediatrics*. 2016 Sep;138(3). pii: e20160355.
  20. Khan M, Boyce A, Prieto-Merino D, Svensson Å, Wedgeworth E, Flohr C. The role of topical timolol in the treatment of infantile hemangiomas: a systematic review and meta-analysis. *Acta Derm Venereol*. 2017 Nov 15;97(10):1167-1171.
  21. Weibel L, Barysch MJ, Scheer HS, et al. Topical timolol for infantile hemangiomas: evidence for efficacy and degree of systemic absorption. *Pediatr Dermatol*. 2016 Mar-Apr;33(2):184-90.
  22. Martin K, Blei F, Chamlin SL, Chiu YE, et al. Propranolol treatment of infantile hemangiomas: anticipatory guidance for parents and caretakers. *Pediatr Dermatol*. 2013 Jan-Feb;30(1):155-9.

**Table 1: Risk Level of IHs of Varying Types**

<b>Risk Level</b>	<b>Clinical Examples and Reason(s) for Concern</b>
<b>Highest</b>	<ul style="list-style-type: none"><li>● Large (&gt;5 cm) or segmental facial or scalp:<ul style="list-style-type: none"><li>○ higher risk of airway hemangiomas (if beard area),</li><li>○ may be associated with PHACE syndrome,</li><li>○ high risk of scarring and/or disfigurement.</li></ul></li><li>● Large or segmental lumbosacral or perineal:<ul style="list-style-type: none"><li>○ may be associated with LUMBAR syndrome,</li><li>○ high risk of ulceration and scarring.</li></ul></li><li>● Multifocal IHs (≥5) and abdominal ultrasonography reveals hemangiomas:<ul style="list-style-type: none"><li>○ may be associated with abdominal compartment syndrome, high-output congestive heart failure, and hypothyroidism.</li></ul></li><li>● Periocular IH causing eyelid asymmetry, lid closure or ptosis, proptosis, or other findings with potential impact on visual axis:<ul style="list-style-type: none"><li>○ risk of astigmatism, anisometropia, and amblyopia.</li></ul></li></ul>
<b>High</b>	<ul style="list-style-type: none"><li>● Large segmental IH on trunk or extremities:<ul style="list-style-type: none"><li>○ risk of scarring and/or disfigurement.</li></ul></li><li>● Any facial IH ≥2 cm (&gt; 1 cm if ≤ 3 mo of age):<ul style="list-style-type: none"><li>○ high risk of scarring and/or disfigurement.</li></ul></li><li>● Nasal tip or lip IH even if &lt;1 cm:<ul style="list-style-type: none"><li>○ high risk of scarring and/or permanent distortion of anatomic landmarks.</li></ul></li><li>● Oral<ul style="list-style-type: none"><li>○ risk of ulceration or bleeding, may interfere with feeding.</li></ul></li><li>● Neck or scalp IH &gt; 2 cm during growth phase:<ul style="list-style-type: none"><li>○ risk of ulceration (neck),</li><li>○ risk of ulceration, scarring, and/or hair loss (scalp).</li></ul></li><li>● Breast:<ul style="list-style-type: none"><li>○ risk of permanent changes in breast development (e.g. breast asymmetry) or nipple contour.</li></ul></li><li>● Ulcerated hemangioma (any site):<ul style="list-style-type: none"><li>○ risk of severe pain, scarring and/or disfigurement, and bleeding.</li></ul></li></ul>
<b>Intermediate</b>	<ul style="list-style-type: none"><li>● Perineal IH (localized) without ulceration:<ul style="list-style-type: none"><li>○ potential for ulceration in this location.</li></ul></li><li>● Trunk or extremity IH &gt;2 cm especially in growth phase or if abrupt transition from normal to affected skin (i.e., ledge effect):<ul style="list-style-type: none"><li>○ risk of scarring and/or disfigurement.</li></ul></li></ul>
<b>Low</b>	<ul style="list-style-type: none"><li>● IH &lt;2 cm on trunk or extremities in areas easily covered by clothing.</li><li>● IH on trunk or extremities &gt;2 cm if gradual transition from normal to affected skin.</li></ul>

(Reprinted with permission from: Krowchuk DP, Frieden IJ, Mancini AJ, et al. **Clinical Practice Guideline for the Management of Infantile Hemangiomas. Pediatrics. 2019 Jan;143: pii: e20183475. doi: 10.1542/peds.2018-3475.**)

**Table 2: Risk stratification when considering beta-blocker treatment**

**Group 1 (Standard risk):** May consider telemedicine initiation of oral or topical beta-blocker therapy\* as long as infant does not have additional features listed for Group 2

- Adjusted gestational age > 5 weeks
- Normal birth weight
- Recent documented weight (within 2 weeks)
- Normal cardiovascular exam within previous 4 weeks (including  $\geq 1$  documented HR after nursery discharge)
- Normal respiratory exam within previous 4 weeks
- Healthy in the 24-48 hours prior to scheduled telemedicine visit (especially, no respiratory and gastrointestinal signs and symptoms)
- IH pattern and distribution *does not* confer risk of PHACE or LUMBAR syndrome
- Lack of ulceration or minimal/superficial ulceration
- Caregiver is able to understand instructions and demonstrate comprehension (e.g. by repeating instructions provided during visit)
- Multiple IH with normal liver ultrasound and without cutaneous IH conferring risks noted in Group 2

**Group 2 (Higher risk):** Recommend in-person evaluation unless local circumstances make this impossible prior to initiation of systemic beta-blocker therapy\*\*

- Corrected gestational age <5 weeks
- Abnormal cardiovascular exam or investigations OR those who lack documentation of this in the post-natal period
- Medium to high risk of PHACE (i.e. large segmental facial or scalp IH in segments S1, S3, S4)
- Medium to high risk of LUMBAR syndrome (i.e. segmental perineal and/or lumbosacral body IH +/- visible associated anatomic abnormalities)
- Significant IH ulceration
- Ongoing poor oral feeding or poor weight gain
- IH with symptoms of airway compromise (e.g. stridor) or bilateral S3 (beard area IH at high risk for airway IH).
- Known pulmonary disease including ongoing respiratory compromise (e.g. dyspnea, frequent wheezing or history of bronchospasm)
- Persistent or ongoing hypoglycemia
- Known or suspected congenital heart disease or suggestive symptoms
  - Known or suspected aortic coarctation
  - History of pathologic heart murmur or abnormal echocardiogram
  - Ongoing diaphoresis
  - Ongoing tachypnea
  - Ongoing tachycardia
  - History of syncope



- Accepted Article
- Extensive hepatic hemangiomas including those resulting in consumptive hypothyroidism or congestive heart failure
  - Known brain malformation
  - Family history in first degree relative of:
    - Congenital heart disease
    - Sudden death or arrhythmia
  - Maternal history of connective tissue disorder (e.g. systemic lupus, Sjogren syndrome, polymyositis, or other)

\* In ordinary circumstances infants are being seen regularly for well-child visits by primary care providers, who weigh and measure infants and perform heart and lung examinations as a standard part of their care. If these examinations are not occurring due to disruptions in healthcare, it becomes much more difficult to ascertain whether there is a normal cardiovascular or pulmonary examination, if normal growth is occurring and other baseline characteristics. In such cases decisions about initiating therapy must be done on a case-by-case basis.

\*\*During this pandemic and other unusual circumstances, in-person visits may not be possible in a timely fashion. In these settings, triage and management decisions need to be made on a case by case basis, ideally in conjunction with relevant specialists as needed (e.g. ENT, cardiology, etc).

**Table 3 Online Infantile Hemangioma Resources\***

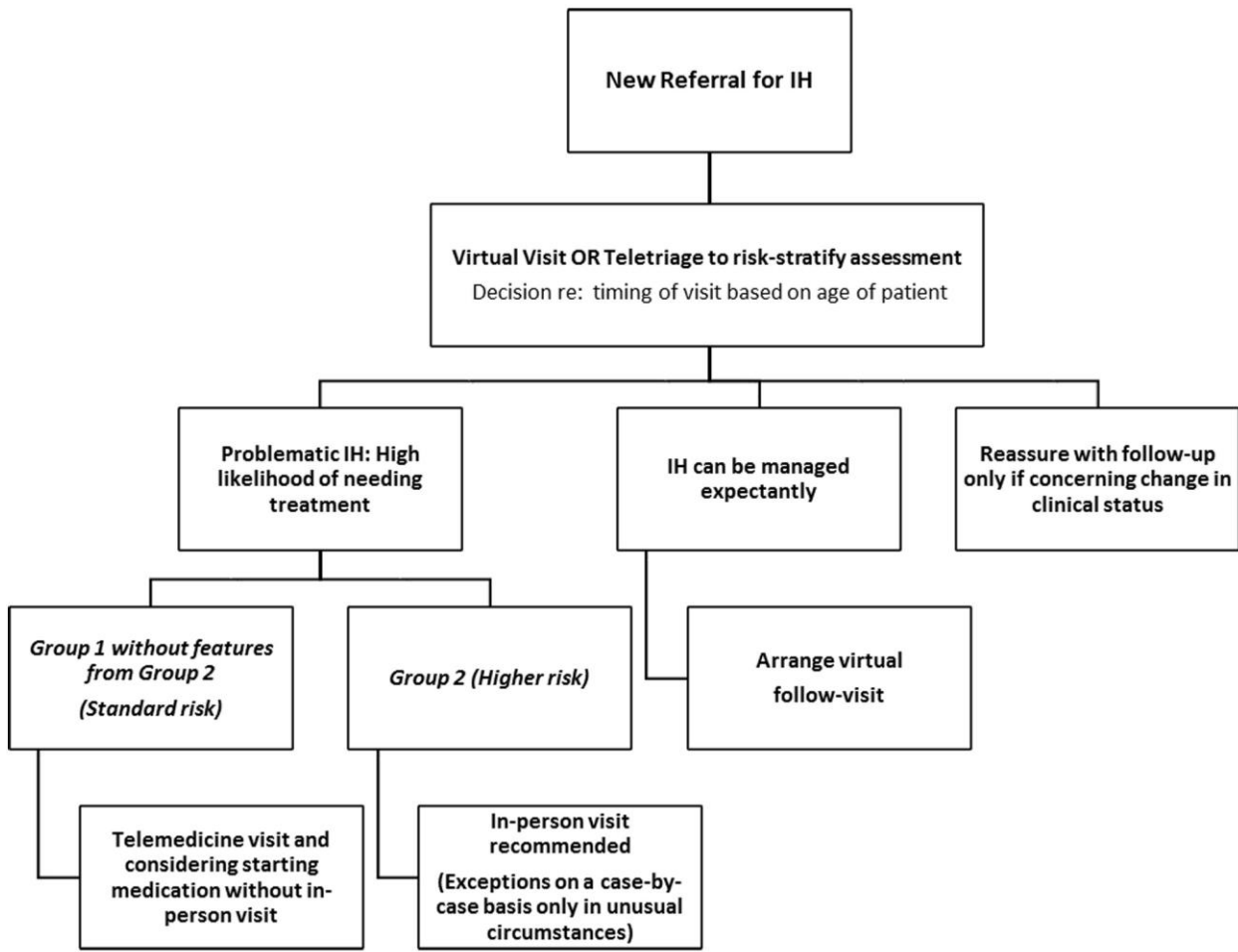
**General Hemangioma Information**

- [https://pedsderm.net/site/assets/files/1028/2\\_spd\\_infantile\\_hemangiomas\\_web\\_final.pdf](https://pedsderm.net/site/assets/files/1028/2_spd_infantile_hemangiomas_web_final.pdf)
- <https://hemangiomaeducation.org/infantile-hemangiomas/>
- <https://en.wikipedia.org/wiki/Hemangioma>
- <https://www.aap.org/en-us/advocacy-and-policy/aap-health-initiatives/Infantile-Hemangiomas/Pages/default.aspx>

**Beta-Blocker Therapy Information**

- [https://pedsderm.net/site/assets/files/1028/12\\_spd\\_propranolol\\_color\\_web-final.pdf](https://pedsderm.net/site/assets/files/1028/12_spd_propranolol_color_web-final.pdf)
- <https://hemangiomaeducation.org/systemic-treatment/>
- <https://hemangiomaeducation.org/topical-and-local-treatment/>
- <https://hemangiomaeducation.org/hemangioma-treatment/new-hig-propranolol-education-video-for-caregivers>

\*These links created or vetted by HIG members



Algorithm for Management