

UC Davis

UC Davis Previously Published Works

Title

Emerging Endovascular Therapies for Non-Compressible Torso Hemorrhage

Permalink

<https://escholarship.org/uc/item/6jd872s7>

Journal

Shock, 46(3S)

ISSN

1073-2322

Authors

Russo, Rachel M

Neff, Lucas P

Johnson, Michael Austin

et al.

Publication Date

2016-09-01

DOI

10.1097/shk.0000000000000641

Peer reviewed



Published in final edited form as:

Shock. 2016 September ; 46(3): 12–19. doi:10.1097/SHK.0000000000000641.

Emerging Endovascular Therapies for Non-compressible Torso Hemorrhage

Rachel Russo¹, Lucas P. Neff^{1,2,3}, M. Austin Johnson⁴, and Timothy K. Williams⁵

¹Department of Surgery, UC Davis Medical Center, 2315 Stockton Blvd. Sacramento, California 94535

²Department of General Surgery, David Grant USAF Medical Center, Travis Air Force Base, California 94533

³Department of Surgery, Uniformed Services University of the Health Sciences, 4301 Jones Bridge Road, Bethesda, Maryland 20814

⁴Department of Emergency Medicine, University of California Davis Medical Center, 2315 Stockton Blvd. Sacramento, CA 95917

⁵Department of Vascular and Endovascular Surgery, David Grant USAF Medical Center, Travis Air Force Base, California 94533

Abstract

Management of non-compressible torso hemorrhage (NCTH) remains a challenge despite continued advancements in trauma resuscitation. Resuscitative thoracotomy with aortic cross-clamping and recent advances in endovascular aortic occlusion, including resuscitative endovascular occlusion of the aorta (REBOA), have finite durations of therapy due to the inherent physiologic stressors that accompany complete occlusion. Here we attempt to illuminate the current state of aortic occlusion for trauma resuscitation including: 1) explanation of the deleterious consequences of complete occlusion, 2) potential methods and limitations of existing technology to overcome these consequences, 3) a description of innovative methods to improve the resuscitation of NCTH. By explaining the complexity and potential deleterious effects of resuscitation augmented with aortic occlusion, our goal is to provide practitioners with a real-world perspective on current endovascular technology and to encourage the continued innovation required to overcome existing obstacles.

Introduction

Hemorrhage is responsible for 40% of civilian trauma-related deaths and for more than 90% of military deaths from potentially survivable injuries (1, 2). While significant advancements for the treatment of extremity hemorrhage have led to improved clinical outcomes,

Address Correspondence to: Timothy K. Williams MD., Address: David Grant Medical Center., 101 Bodin Circle. Travis AFB, CA 94535., timothy.williams.72@us.af.mil, Phone: 302-562-1431.

Conflicts of Interest: None

Disclaimers: The views expressed in this material are those of the authors, and do not reflect the official policy or position of the U.S. Government, the Department of Defense, the Department of the Air Force, or the University of California Davis.

management of non-compressible torso hemorrhage (NCTH) remains a challenge. Definitive surgical management or salvage maneuvers such as resuscitative thoracotomy with aortic cross-clamping are frequently unavailable or impractical near the point of injury. Prolonged transport times delay intervention, allowing continued patient deterioration until the appropriate echelon of care is reached. When resources are available, performing resuscitative thoracotomy is often delayed until it is too late to result in meaningful survival. Thus, resuscitative thoracotomy is frequently relegated to a maneuver of “last resort”, employed when hemodynamic collapse is imminent or after vital signs are lost. As such, clinical outcomes following aortic cross-clamping remain dismal.

Less invasive endovascular therapies for control of hemorrhage, most notably resuscitative endovascular balloon occlusion of the aorta (REBOA), are gaining favor in the management of this challenging patient population. These technologies may pave the way for earlier intervention and more liberal management strategies for NCTH. Aortic occlusion by any method results in significant ischemic burden to tissue beds distal to the level of occlusion, while potentially subjecting proximal tissue beds to supraphysiologic blood pressure (3). These combined effects negate any potential benefit of sustained aortic occlusion when significant delay to definitive care is anticipated. While endovascular therapies likely represent the area for greatest potential growth, novel strategies aimed at preventing exsanguination while concurrently minimizing the negative impact of aortic occlusion are needed.

The focus of this communication will be to describe the undesirable effects of complete aortic occlusion in the setting of NCTH and outline current and emerging endovascular strategies to mitigate these effects.

EFFECTS OF AORTIC OCCLUSION

Morbidity and mortality from sustained aortic occlusion is attributed mainly to hypertension proximal to the point of occlusion, ischemia distal to the point of occlusion, and hemodynamic instability associated with the restoration of systemic circulation (Table 1) (4, 5). A dose-response relationship exists between the duration of aortic occlusion and the magnitude of these adverse effects (4). While the maximal duration of complete occlusion remains ill-defined, it is suggested that patient salvage is not possible after periods of occlusion in excess of 60 minutes (5). The critical threshold of survival for an individual patient is variable and represents the cumulative effects of the initial injury combined with the physiologic insult of sustained aortic occlusion.

Proximal Hypertension

The purpose of resuscitative aortic occlusion is to restore perfusion to the heart, lungs, and brain for short intervals until definitive hemorrhage control can be obtained (4). However sustained resuscitative aortic occlusion confers a significant cost to these vital organs. Even in the setting of hypovolemic shock, aortic occlusion produces supraphysiologic proximal blood pressure with dramatic increase in cardiac afterload and perfusion to proximal organs resulting in myocardial dysfunction, respiratory failure and cerebral edema (6–9).

Early diastolic dysfunction is quickly followed by systolic dysfunction that exacerbates the developing pulmonary venous congestion. This increase in pulmonary vascular pressure may precipitate acute respiratory decompensation, which is further exacerbated by the inflammatory injury from ischemia-reperfusion. This phenomenon can be seen in up to 26% of patients following aortic occlusion for thoraco-abdominal aneurysm repair and the incidence is even higher in trauma patients that survive resuscitative aortic occlusion (1, 9–11). Additionally, aortic occlusion has been hypothesized to worsen concomitant pulmonary contusion by inducing clot destabilization and promoting parenchymal hemorrhage, further contributing to respiratory failure (9).

The loss of cerebral autoregulation after traumatic brain injury makes the brain susceptible to increases in carotid blood flow and increased blood pressure that result from complete aortic occlusion (7). Even transient periods of central hypertension may exacerbate a TBI by preventing intracerebral clot stabilization, worsening hemorrhage, and increasing cerebral edema. To date, reported mortality rates in multi-injured patients with TBI requiring REBOA as a resuscitative adjunct approaches 50% (12, 13). These detrimental effects of supraphysiologic cerebral blood flow occur even in patients without brain injury, as evidenced by cerebral edema resulting from prolonged periods of extreme proximal hypertension (14).

Distal Ischemia

Complete aortic occlusion halts all aortic blood flow, resulting in a cumulative ischemic insult to distal tissue beds. When performed for a short duration, this ischemic insult is fully reversible, however there is a threshold of cumulative ischemia when injuries become irreversible. This can manifest with kidney and liver failure, intestinal ischemia, lower limb loss, and paralysis from spinal cord ischemia (5, 13).

Additionally, complete aortic occlusion induces anaerobic metabolism with resulting ischemia-reperfusion injury contributing to post-traumatic systemic inflammatory response syndrome (9). The dysregulation of the immune response in animal models of aortic occlusion leads to migration of leukocytes into ischemic distal tissue beds, principally the intestines, and profound leukopenia (9, 15). Similar leukocyte sequestration in the intestines of humans is associated with mesenteric ischemia, intestinal dysfunction, and an increased risk of sepsis (16).

Hemodynamic Instability

The eventual reintroduction of native aortic flow precipitates a rapid redistribution of total circulating blood volume to distal vascular beds that vasodilate in response to ischemia. The systemic release of anaerobic metabolites and potassium from ischemic tissue depresses myocardial contractility and inhibits compensatory responses. The cumulative effect is abrupt hemodynamic collapse following the release of aortic occlusion (17). The need for repeat aortic occlusion upon circulatory collapse is well described in clinical practice and in large animal models (12, 13, 18).

ENDOVASCULAR METHODS FOR ACHIEVING AORTIC OCCLUSION

REBOA

Endoluminal occlusion of the aorta as a clinical adjunct for hemorrhagic shock was originally described in 1954 in the care of injured warfighters, however clinical adoption of this technique was hampered by the widespread lack of endovascular technology and the infrastructure to support it. Over the subsequent decades, there has been an explosion of endovascular techniques and devices; this technology is now routinely applied in the management of ruptured aortic aneurysms. The application of endovascular control of aortic flow in the context of trauma continues to lag behind non-trauma uses, possibly due to high procedure related complication rates in the 1980s (19–21). This renewed focus was driven primarily by vascular surgeons improvising during trauma resuscitations during recent conflicts in the Middle East. As such, there has been a recent reappraisal for the role of endoluminal occlusion of the aorta for the management of incompressible torso hemorrhage. In 2011, Stannard et al outlined a clinic algorithm for this technique, now commonly known as REBOA, as a viable alternative to resuscitative thoracotomy.

REBOA is achieved by inflating a compliant balloon catheter within the lumen of the aorta to occlude the vessel and limit blood flow distal to the level of the balloon. This can be performed in various regions of the aorta depending on the perceived level of injury (Figure 1) (17). While occlusion in the descending thoracic aorta (Zone 1) is most common, more selective placement such as in the paravisceral (Zone 2) or infrarenal aorta (Zone 3) may be performed when the level of injury is well defined, as is the case for isolated pelvic fractures (22). This more selective approach limits distal organ ischemia caused by more proximal aortic occlusion and extends the potential duration of intervention.

Within the United States the specific combination of surgical skills and available resources needed to perform REBOA has localized this therapy exclusively to level 1 trauma centers as both surgical femoral arterial access and a capable provider with access to fluoroscopy are required (17). Currently, the continued progress in endovascular technology coupled with advanced focused training for REBOA providers has led to few reported complications during early U.S. experience with REBOA thus far (23). At present, utilization of REBOA still lags far behind open aortic cross-clamping, but continued advances in technique and catheter design will further reduce barriers to implementing REBOA more broadly (22).

Since REBOA is a relatively new technique for trauma resuscitation, patient selection remains an area of ongoing debate. The less invasive nature of REBOA and lower physiologic burden relative to open aortic cross-clamping give REBOA therapy the potential to be applied proactively prior to hemodynamic collapse, particularly with the advent of low profile balloons. Experts recommend REBOA for patients with isolated abdominal or pelvic injuries and MAP >60mmHg (24). However, REBOA cannot entirely supplant thoracotomy. Clear contraindications have yet to be established, but expert opinion suggests REBOA may be harmful in the setting of both blunt and penetrating thoracic injury, particularly when a thoracic aortic injury is suspected (24). It has been hypothesized that in the setting of thoracic trauma Zone I occlusion could lead to increased bleeding and rapid hemodynamic collapse, although recent clinical experience in a single patient with both thoraco-abdominal

penetrating trauma has demonstrated that REBOA can lead to successful resuscitations even in the setting of thoracic trauma as long as major vessel injury is not suspected (25). Patient selection may ultimately require consideration of the anatomic distribution of injuries and the mechanism of injury, as patients with penetrating injury tend to have higher survival following REBOA therapy than do patients with a similar degree of hemorrhagic shock from blunt injury (22).

Despite its potential for expanded application to a wider range of patients by a wider range of providers, REBOA as a form of complete aortic occlusion suffers from the same consequences as open aortic cross-clamping, including proximal hypertension, distal ischemia and systemic ischemia-reperfusion injury (4). Although not unique to REBOA, prolonged periods of complete aortic occlusion by any means results in significant distal ischemia and subsequent ischemia-reperfusion injury that together create a challenge at the time of balloon deflation (18). Independent of ongoing hemorrhage, overcoming the consequences of ischemia-reperfusion can be challenging and result in hemodynamic collapse. Emerging clinical data on the use of REBOA reports successful 30-day survival following *brief* periods of aortic occlusion (20–40 minutes); however longer periods of aortic occlusion are associated with significantly increased morbidity and mortality (5, 13, 17, 26, 27). The inability of REBOA to extend the duration of occlusion beyond the time afforded by aortic cross-clamping has resulted in REBOA, like aortic cross-clamping, to be relegated to a salvage maneuver of last resort confined to only a few select trauma centers.

The largest account of experience with REBOA, published by Norii et. al in 2015, found higher mortality in patients treated with REBOA compared to similarly injured patients treated without REBOA from 2004 to 2011 in Japan. However, the duration of complete occlusion in these patients remains unclear, as limited information regarding the application of REBOA is included in the dataset. Based on a reported mean time to definitive care of greater than three hours, it is likely that the duration of REBOA in this series exceeds what is physiologically tolerable. This precludes comparison to the US experience, where REBOA application is limited to less than one hour.

Although early U.S. clinical experience with REBOA has largely been favorable, there is still considerable opportunity to optimize resuscitations augmented with endovascular aortic occlusion (17). The detrimental consequences of prolonged complete aortic occlusion have led to a search for alternative methods of truncal hemorrhage control that preserve central mean arterial pressure while minimizing distal ischemia to improve survival and extend the potential duration of intervention (18) (Table 2).

Selective Aortic Arch Perfusion (SAAP)

Selective aortic arch perfusion (SAAP) is a technique wherein an aortic occlusion balloon with a large central lumen is deployed in the high thoracic aorta to allow retrograde instillation of a perfusate directly into the aortic arch to achieve return of spontaneous circulation after cardiac arrest (28). Variations of SAAP incorporating aortic cross-clamps and a cardiopulmonary bypass circuit have been successfully employed during elective operations requiring circulatory arrest (29). However, advances in catheter design now allow for this technique to be achieved endovascularly, with the administration of blood products

and medications directly into the aortic arch through a central lumen in an aortic occlusion balloon. Translational experiments of medical and traumatic cardiac arrest demonstrate endovascular SAAP may result in return of spontaneous circulation faster and more reliably than chest compressions combined with intravenous perfusate administration (28, 30).

Similar to REBOA and aortic cross-clamping, SAAP provides perfusion to the heart, lungs, and brain at the cost of distal ischemia. Injury to proximal organs from supraphysiologic blood pressure and flow, including pulmonary edema, cerebral edema, and elevated right heart pressures have been seen during periods of SAAP as short as 2 minutes (28). The more proximally positioned SAAP occlusion balloon may result in ischemia to the thoracic spinal cord and distal abdominal organs with prolonged balloon occlusion. Currently translational experiments have only tested short durations of SAAP (2–6 minutes) and minimally describe physiologic changes that follow cessation of therapy. It is therefore unclear if the benefits of SAAP will persist following balloon deflation in the setting of distal organ ischemia. While this variation on REBOA has been used to salvage swine who have exsanguinated, long-term survival with this technique has not been reported.

Advances in catheter design have overcome some of the limitations of SAAP as it is currently described. Initial experiments with this technique required large introducers (18F) to accommodate a catheter with a central lumen for rapid blood transfusion (28). Newer technology can accomplish this same task through percutaneously placed introducer sheaths (9F) that carry a lower risk of access site complications (30). This approach may be best combined with new catheters and novel approaches that reduce distal ischemia during aortic occlusion.

Intermittent REBOA (iREBOA)

Intermittent clamp release has long been a practice during the repair of aortic aneurysms in order to provide intermittent blood flow to distal organs and reduce the effects of ischemia-reperfusion injury (31). Similarly, clinical practice with REBOA over the last ten years in Japan frequently involves intermittent balloon deflation (5). A small trial in 6 patients suggests the ideal approach to intermittent REBOA (iREBOA) is balloon deflation every 20 minutes for a period of several minutes as physiologically tolerated (12). During angioembolization, using iREBOA in this manner has facilitated non-operative management of solid organ injuries and has extended the total duration of aortic occlusion to as long as 80 minutes with no reported complications from distal ischemia (12). However, hemodynamic instability and clot destabilization created by rapid changes in blood pressure and flow have been observed and resulted in the inability to wean from occlusion for one of the six patients that ultimately died (12). Clinically, abdominal organ injury from iREBOA-induced ischemia may be difficult to distinguish from injury resulting from trauma, embolization, prolonged contrast exposure, or hemorrhagic shock. Animal models of liver hemorrhage treated with 90 minutes of iREBOA or complete REBOA found equally severe distal organ ischemia and systemic inflammation in both groups (18).

Oscillating extremes in aortic blood pressure and flow may inhibit the body's compensatory mechanisms to hemorrhagic shock. Rapid changes in aortic afterload can result in cardiac instability and interfere with cerebral blood flow autoregulatory mechanisms. Ischemic

vasodilation may subject distal organs to excessively high blood flow during periods of reperfusion, contributing to cardiovascular collapse and clot destabilization.

Partial REBOA (P-REBOA)

Partial REBOA (P-REBOA) is an emerging technique to preserve titrated distal aortic flow through the partial inflation of an occlusion balloon catheter (32). Permissive distal flow has the potential to overcome several limitations of REBOA, including the limited duration total occlusion and the challenges associated with weaning from occlusion. By allowing partial distal aortic flow the supraphysiologic afterload and proximal blood pressure associated with complete REBOA can theoretically be avoided. Simultaneously, allowing titrated distal aortic flow has the potential to mitigate the ischemic burden accumulating in distal tissue beds.

Partial aortic occlusion to augment blood pressure was first described in acute stroke patients, in which an intra-aortic balloon was inflated to achieve a desired increase in proximal blood pressure to improve blood flow to the brain (33). The mild increase in blood pressure and carotid flow provided by partial aortic balloon occlusion increased cerebral perfusion in the penumbra without increasing the risk of expanding intracerebral hemorrhage, even in patients on thrombolytics (34). Furthermore, no cardiac, respiratory, renal, mesenteric, or spinal cord complications were reported during or after up to 60 minutes of treatment, suggesting a level of safety to P-REBOA (34).

While theoretical benefits of P-REBOA are supported by a small body of clinical data encompassing various disease states, the clinical benefits of this technique as applied to the trauma population, is limited to a single reported case. In a case report out of Sweden, an aortic occlusion balloon was partially inflated in an effort to augment proximal blood pressure, slow pelvic hemorrhage distally, and avoid exacerbation of a TBI in a multi-trauma patient with hemorrhagic shock (35). A recent second case not yet published has also demonstrated success of P-REBOA during the resuscitation of a multiply injured patient without a TBI, but together these individual case reports are only anecdotal (25). To address this knowledge gap, our group sought to explore the utility of P-REBOA in a simulated pre-hospital scenario of uncontrolled truncal hemorrhage. Utilizing a rapidly fatal porcine liver injury model, P-REBOA was able to extend survival nearly 3.5-fold over no intervention, but was unable to achieve satisfactory hemostasis over complete REBOA. Further translational investigation suggests that (15). P-REBOA may best be implemented following a brief period of complete aortic occlusion to achieve initial hemostasis prior to the re-introduction of distal blood flow.

The clinical application of this technique may be lacking partially due to current balloon technology not optimized to provide full-spectrum of aortic occlusion with fidelity to achieve initial complete occlusion followed by titrated distal flow to tissue beds. Our experience in animal models as well as in a single clinical case of P-REBOA has demonstrated small changes in balloon volume associated with exponential increases in distal flow, making titration with current technology difficult. The aortic diameter is, itself, influenced by changes in cardiac output, vascular tone, blood pressure, and intravascular volume status. As such, the relative degree of aortic occlusion created by a partially inflated

balloon is constantly in flux. This necessitates real-time manipulation of the balloon inflation volume by a dedicated provider in order maintain proximal blood pressure within a desired range. Given that small changes in the diameter of the flow lumen, which constitutes the difference between aortic and balloon diameters, result in large changes in flow (based on the Poiseuille's Law), precise control of aortic blood flow by manual adjustment of balloon diameter is extremely difficult.

A second technical challenge emerging from clinical experience are reports of potential balloon migration once P-REBOA is initiated. Upon partial deflation, a lack of frictional force between the balloon and the aortic wall while subjected to pulsatile flow can lead to balloon migration. In the aforementioned published case report, the balloon catheter prolapsed within the aorta necessitating replacement, which the authors attributed to a lack of a supportive stiff guide-wire. The replacement of catheters during ongoing resuscitation and hemorrhage is a significant risk for P-REBOA when utilizing current technology, and new stiffer catheter designs may reduce some of these problems.

In our experience conducting animal studies of P-REBOA we have found the gradient of blood pressure above and below the balloon to be an imprecise surrogate for quantifying aortic blood flow to distal organs, especially during active hemorrhage when there are dramatic changes in intravascular volume status, vascular tone and cardiac output. Existing technology does not provide direct measurement of aortic blood flow to allow the precise and dynamic regulation of proximal and distal organ perfusion to a degree that is necessary for prolonged intervention. Therefore, we have found that a dedicated provider focused on changing balloon volumes in response to ongoing physiology is required.

Endovascular Variable Aortic Control (EVAC)

While the techniques of intermittent and partial REBOA seek to mitigate the deleterious effects of complete REBOA, they are still constrained by limitations of current balloon catheter design. Reliably achieving controlled flow at the interface of a single balloon and the aorta is challenging given the dynamic variables encountered during the resuscitation of a severely injured trauma patient. The interplay of volume status, aortic diameter, systemic vascular resistance, cardiac output, and other physiologic responses to shock and injury create unpredictable aortic flow patterns that limit the real world implementation of P-REBOA. At this time, P-REBOA represents an initial step towards next generation technologies, but expanded application beyond resource-rich environments with experienced practitioners is not realistic. Therefore, a critical reappraisal to this management strategy is warranted.

Variable aortic control (VAC) is a novel management strategy for NCTH and represents a paradigm shift from current approaches to hemorrhage control. First, VAC is fundamentally based on the premise that aortic *flow* as opposed to *pressure* is the major determinant of organ viability, particularly with respect to tissue beds beyond the point of flow restriction. Building upon the well-established principle of permissive hypotension, VAC would provide "permissive regional hypoperfusion" where flow is used as a titration endpoint instead of blood pressure. Although blood flow and pressure are interrelated, they do not necessarily correlate in a predictable fashion. Based on our translational experience, we have observed

that proximal aortic pressure and pressure gradients across occlusion devices do not accurately predict aortic flow rates in the context of intravascular volume fluctuations. (Figure 2) In this light, a device capable of VAC would require the ability to precisely measure and regulate distal aortic blood flow in a very tight range in response to the dynamic physiology of resuscitation. Without this, aortic flow rates could quickly exceed what is physiologically tolerable leading to hemorrhage and hemodynamic instability. Achieving VAC will either require constant user interaction in order to modulate a device in or, preferably, automated computer-controlled modulation. As we envision this concept being applied potentially at the point of injury, there is a compelling argument to be made for the role of automation in VAC. In resource-constrained environments, it is unlikely that a provider could be allocated to exclusively manage this aspect of an ongoing resuscitation. Furthermore, experience with P-REBOA has suggested that manual titration in response to dynamic physiologic changes are exceedingly difficult. We envision automation of this therapy coupled with human decision support will serve as a means to “cognitively offload” the provider, allowing the team to focus on more global aspects of patient care.

Furthermore, automation of this therapy could allow for application in disaster scenarios when time to the operating room is delayed due to the large volume of patients in need of surgery. It may also ease the burden of maintaining a staff surgeon in remote locations, small military bases, or Navy ships where the operative case volume is low. Patients can be managed non-operatively while awaiting a surgeon to be flown in from the nearest facility, and surgeons can reside in busier locals that will better maintain their operative skills.

A point of emphasis is that VAC encompasses a specific therapy and not a device. While the principles of VAC have direct influence on device design, they do not necessitate a specific physical form. Hence, a device capable of VAC does not absolutely need to take the form of a balloon, although may be based in balloon technology. Currently, no commercially available device meets the design specifications necessary to perform VAC. The ideal device would have the following features: pressure and flow sensing capabilities, ability to modulate flow within a desired and stable range particularly in the low range of flow, automated modulation capabilities, and low profile design capable of being delivered through small percutaneously placed sheaths.

Current interventions for NCTH are frequently utilized late in the course of trauma resuscitation, often after the loss of vital signs, when meaningful recoveries are rare. The decision to intervene with aortic occlusion has been a large commitment given the potential downstream sequelae of the intervention itself. Utilization might increase if providers had the ability to simply reduce blood flow as opposed to completely interrupting it. Theoretically, this would lessen the physiologic burden attributable to the intervention and lower the threshold for more liberal application. VAC could be applied prior to hemodynamic collapse in an effort to arrest bleeding, limit resuscitation volumes, and prevent hemodynamic collapse. VAC may even have a role in the non-operative management of blunt solid organ or pelvic injury, where achieving hemostasis is the primary objective.

Clinical experience indicates that the duration of sustained complete aortic occlusion is finite and likely limited to less than one hour (5). Therefore, a new paradigm is needed to sustain

an individual and bridge the gap between injury and definitive hemorrhage control. VAC may offer a viable method to extend the time prior to definitive hemorrhage control for severe injuries that otherwise would be salvageable only with immediate and aggressive intervention in a well-resourced hospital. Our preliminary experience with an experimental model of VAC suggests that only 5–10% of baseline aortic flow may be all that is necessary to maintain organ viability for up to 90 minutes (in press). Experiments that better define titration parameters, ideal flow rates and maximal duration of therapy are ongoing.

The potential of VAC to provide early hemorrhage control and augmented central perfusion without irreversibly compromising distal organs may significantly improve survival for patients who are injured in geographically remote regions around the world(36). Even in specialized trauma centers, mortality increases by 7% for every additional 15 minutes without definitive hemorrhage control (37). In the U.S., resuscitation in facilities with limited access to trauma care carries a threefold-increase in risk of emergency room death compared to those injured near trauma centers (38). Likewise, in austere combat environments, evacuation time to appropriate echelons of care frequently exceeds an hour and may require indefinite periods of prolonged field care (36). As the time and distance separating the point of injury from surgical capabilities continues to increase, the need to extend resuscitation capabilities assumes a new urgency. VAC is ideally suited to address this ever-increasing need. Current ongoing translational efforts are focused extending the “golden hour” by utilizing novel resuscitative efforts that simulate the core tenants of VAC. Concurrently, innovative catheter designs are being developed and are poised to make endovascular variable aortic control (EVAC) a near-term reality (Figure 3).

Conclusion

Emerging endovascular technologies offer the greatest hope for preventing death from non-compressible torso hemorrhage. REBOA has shown great promise but is limited in its duration of application. I-REBOA and P-REBOA build on this concept in an effort to mitigate the negative consequences of sustained aortic occlusion, but may be limited by the risk of renewed hemorrhage resulting from the inability to carefully titrate blood flow. New methods and devices must be developed to bring physiologically tolerable and impactful interventions to the point of injury in an effort to extend the duration of the “golden hour” for military and civilian trauma populations alike.

Abbreviations

NCTH	non-compressible torso hemorrhage
TBI	traumatic brain injury
VAC	variable aortic control
REBOA	resuscitative endovascular balloon occlusion of the aorta
P-REBOA	partial resuscitative endovascular balloon occlusion of the aorta
I-REBOA	intermittent resuscitative endovascular balloon occlusion of the aorta

References

1. Kauvar DS, Lefering R, Wade CE. Impact of hemorrhage on trauma outcome: an overview of epidemiology, clinical presentations, and therapeutic considerations. *J Trauma*. 2006; 60(6 Suppl):S3–11. [PubMed: 16763478]
2. Eastridge BJ, Mabry RL, Seguin P, Cantrell J, Tops T, Uribe P, Mallett O, Zubko T, Oetjen-Gerdes L, Rasmussen TE, Butler FK, Kotwal RS, Holcomb JB, Wade C, Champion H, Lawnick M, Moores L, Blackbourne LH. Death on the battlefield (2001–2011): implications for the future of combat casualty care. *J Trauma Acute Care Surg*. 2012; 73(6 Suppl 5):S431–7. [PubMed: 23192066]
3. Rasmussen TE, Clouse WD, Peck MA, Bowser AN, Eliason JL, Cox MW, Woodward EB, Jones WT, Jenkins DH. Development and implementation of endovascular capabilities in wartime. *J Trauma*. 2008; 64(5):1169–76. discussion 76. [PubMed: 18469637]
4. Markov NP, Percival TJ, Morrison JJ, Ross JD, Scott DJ, Spencer JR, Rasmussen TE. Physiologic tolerance of descending thoracic aortic balloon occlusion in a swine model of hemorrhagic shock. *Surgery*. 2013; 153(6):848–56. [PubMed: 23453327]
5. Saito N, Matsumoto H, Yagi T, Hara Y, Hayashida K, Motomura T, Mashiko K, Iida H, Yokota H, Wagatsuma Y. Evaluation of the safety and feasibility of resuscitative endovascular balloon occlusion of the aorta. *J Trauma Acute Care Surg*. 2015; 78(5):897–903. discussion 4. [PubMed: 25909407]
6. Long KN, Houston Rt, Watson JD, Morrison JJ, Rasmussen TE, Propper BW, Arthurs ZM. Functional outcome after resuscitative endovascular balloon occlusion of the aorta of the proximal and distal thoracic aorta in a swine model of controlled hemorrhage. *Ann Vasc Surg*. 2015; 29(1): 114–21. [PubMed: 25449984]
7. Stokland O, Miller M, Ilebekk A, Kiil F. Mechanism of hemodynamic responses to occlusion of the descending thoracic aorta. *American Journal of Physiology-Heart and Circulatory Physiology*. 1980; 238(4):H423–H9.
8. Dunn E, Prager RL, Fry W, Kirsh MM. The effect of abdominal aortic cross-clamping on myocardial function. *J Surg Res*. 1977; 22(5):463–8. [PubMed: 859311]
9. Annecke T, Kubitz JC, Langer K, Hilberath JM, Kahr S, Krombach F, Bittmann I, Rehm M, Kemming GI, Conzen PF. Lung injury following thoracic aortic occlusion: comparison of sevoflurane and propofol anaesthesia. *Acta Anaesthesiol Scand*. 2008; 52(7):977–86. [PubMed: 18477071]
10. Golden MA, Donaldson MC, Whittemore AD, Mannick JA. Evolving experience with thoracoabdominal aortic aneurysm repair at a single institution. *J Vasc Surg*. 1991; 13(6):792–6. discussion 6–7. [PubMed: 2038102]
11. Napolitano LM, Ferrer T, McCarter RJ Jr, Scalea TM. Systemic inflammatory response syndrome score at admission independently predicts mortality and length of stay in trauma patients. *J Trauma*. 2000; 49(4):647–52. discussion 52–3. [PubMed: 11038081]
12. Ogura T, Lefor AT, Nakano M, Izawa Y, Morita H. Nonoperative management of hemodynamically unstable abdominal trauma patients with angioembolization and resuscitative endovascular balloon occlusion of the aorta. *J Trauma Acute Care Surg*. 2015; 78(1):132–5. [PubMed: 25539214]
13. Norii T, Crandall C, Terasaka Y. Survival of severe blunt trauma patients treated with resuscitative endovascular balloon occlusion of the aorta compared with propensity score-adjusted untreated patients. *J Trauma Acute Care Surg*. 2015; 78(4):721–8. [PubMed: 25742248]
14. Montero CG, Martinez AJ. Neuropathology of heart transplantation: 23 cases. *Neurology*. 1986; 36(9):1149–54. [PubMed: 3528916]
15. Russo RM, Williams TK, Grayson JK, Lamb CM, Cannon JW, Clement NF, Galante JM, Neff LP. Extending the golden hour: Partial resuscitative endovascular balloon occlusion of the aorta in a highly lethal swine liver injury model. *J Trauma Acute Care Surg*. 2016; 80(3):372–80. [PubMed: 26670114]
16. Bochicchio GV, Napolitano LM, Joshi M, McCarter RJ Jr, Scalea TM. Systemic inflammatory response syndrome score at admission independently predicts infection in blunt trauma patients. *J Trauma*. 2001; 50(5):817–20. [PubMed: 11379594]

17. Stannard A, Eliason JL, Rasmussen TE. Resuscitative endovascular balloon occlusion of the aorta (REBOA) as an adjunct for hemorrhagic shock. *J Trauma*. 2011; 71(6):1869–72. [PubMed: 22182896]
18. Morrison JJ, Ross JD, Houston R, Watson JD, Sokol KK, Rasmussen TE. Use of resuscitative endovascular balloon occlusion of the aorta in a highly lethal model of noncompressible torso hemorrhage. *Shock*. 2014; 41(2):130–7. [PubMed: 24430492]
19. Gupta BK, Khaneja SC, Flores L, Eastlick L, Longmore W, Shaftan GW. The role of intra-aortic balloon occlusion in penetrating abdominal trauma. *J Trauma*. 1989; 29(6):861–5. [PubMed: 2661845]
20. Arthurs Z, Starnes B, See C, Andersen C. Clamp before you cut: Proximal control of ruptured abdominal aortic aneurysms using endovascular balloon occlusion--Case reports. *Vasc Endovascular Surg*. 2006; 40(2):149–55. [PubMed: 16598364]
21. Malina M, Holst J. Balloon control for ruptured AAAs: when and when not to use? *J Cardiovasc Surg (Torino)*. 2014; 55(2):161–7.
22. DuBose J, Brenner ML, Cannon J, Rasmussen TE, Holcomb JB, TMS. RACST Center. Aortic occlusion for resuscitation in trauma and acute care surgery (AORTA): a prospective observational study of the Endovascular Skills in Trauma and Resuscitative Surgery. [Accessed March 14, 2016]
23. Brenner ML, Moore LJ, DuBose JJ, Tyson GH, McNutt MK, Albarado RP, Holcomb JB, Scalea TM, Rasmussen TE. A clinical series of resuscitative endovascular balloon occlusion of the aorta for hemorrhage control and resuscitation. *J Trauma Acute Care Surg*. 2013; 75(3):506–11. [PubMed: 24089121]
24. Biffl WL, Fox CJ, Moore EE. The role of REBOA in the control of exsanguinating torso hemorrhage. *J Trauma Acute Care Surg*. 2015; 78(5):1054–8. [PubMed: 25909430]
25. Davidson AJ, Russo RM, DuBose JJ, Roberts J, Jurkovich GJ, Galante JM. Early operative utilization of low profile, partial resuscitative endovascular balloon occlusion of the aorta (P-REBOA) in major traumatic hemorrhage. *Trauma Surgery and Acute Care Open*. in press.
26. Holcomb JB, Fox EE, Scalea TM, Napolitano LM, Albarado R, Gill B, Dunkin BJ, Kirkpatrick AW, Cotton BA, Inaba K, DuBose JJ, Cohen AM, Azizzadeh A, Brenner M, Cohen MJ, Wade CE, Lumsden AB, Andrassy R, Rhee PM, Bass BL, Mattox KL, Britt LD, Eastman AB, Hoyt DB, Rasmussen TE. Current opinion on catheter-based hemorrhage control in trauma patients. *J Trauma Acute Care Surg*. 2014; 76(3):888–93. [PubMed: 24553566]
27. Avaro JP, Mardelle V, Roch A, Gil C, de Biasi C, Oliver M, Fusai T, Thomas P. Forty-minute endovascular aortic occlusion increases survival in an experimental model of uncontrolled hemorrhagic shock caused by abdominal trauma. *J Trauma*. 2011; 71(3):720–5. discussion 5–6. [PubMed: 21909002]
28. Manning JE, Murphy CA Jr, Hertz CM, Perretta SG, Mueller RA, Norfleet EA. Selective aortic arch perfusion during cardiac arrest: a new resuscitation technique. *Ann Emerg Med*. 1992; 21(9): 1058–65. [PubMed: 1514716]
29. Zacek P, Dominik J, Brodak M, Louda M. Selective aortic arch perfusion enables to avoid deep hypothermic circulatory arrest for extirpation of renal cell carcinoma with tumour thrombus extension into the right atrium. *Interactive cardiovascular and thoracic surgery*. 2014; 18(4):411–4. [PubMed: 24384500]
30. Manning JE, Ross JD, McCurdy SL, True NA. Aortic Hemostasis and Resuscitation: Preliminary Experiments Using Selective Aortic Arch Perfusion With Oxygenated Blood and Intra-aortic Calcium Coadministration in a Model of Hemorrhage-induced Traumatic Cardiac Arrest. *Acad Emerg Med*. 2016; 23(2):208–12. [PubMed: 26766760]
31. Puchakayala MR, Lau WC. Descending thoracic aortic aneurysms. *Continuing Education in Anaesthesia, Critical Care & Pain*. 2006; 6(2):54–9.
32. Johnson MA, Neff LP, Williams TK, DuBose JJ, Cannon J, Brown I, Davidson AJ, Ferencz S-A, Galante J, Gerlach T, Hight R, Rasmussen TE, Russo RM, Sampson J. Partial Resuscitative Balloon Occlusion of the Aorta (P-REBOA): Clinical Technique and Rationale. *Journal of Trauma and Acute Care Surgery*. in press.

33. Hammer M, Jovin T, Wahr JA, Heiss WD. Partial occlusion of the descending aorta increases cerebral blood flow in a nonstroke porcine model. *Cerebrovasc Dis.* 2009; 28(4):406–10. [PubMed: 19713700]
34. Emery DJ, Schellinger PD, Selchen D, Douen AG, Chan R, Shuaib A, Butcher KS. Safety and feasibility of collateral blood flow augmentation after intravenous thrombolysis. *Stroke.* 2011; 42(4):1135–7. [PubMed: 21350210]
35. Horer TM, Cajander P, Jans A, Nilsson KF. A case of partial Aortic balloon occlusion in blunt trauma. *Trauma.* 2016:1–5.
36. NAEMT. *Phtls Prehospital Trauma Life Support: Military Version.* 6. Elsevier Science Health Science Division; 2006.
37. Alarhayem, A.; Myers, J.; Dent, D.; Eastridge, B. *No Time to Bleed: The Impact of Time from Injury to the Operating Room on Survival in Patients with Hemorrhage From Blunt Abdominal Trauma.* AAST; Las Vegas, NV: Sep. 2015
38. Gomez D, Berube M, Xiong W, Ahmed N, Haas B, Schuurman N, Nathens AB. Identifying targets for potential interventions to reduce rural trauma deaths: a population-based analysis. *Journal of Trauma and Acute Care Surgery.* 2010; 69(3):633–9.

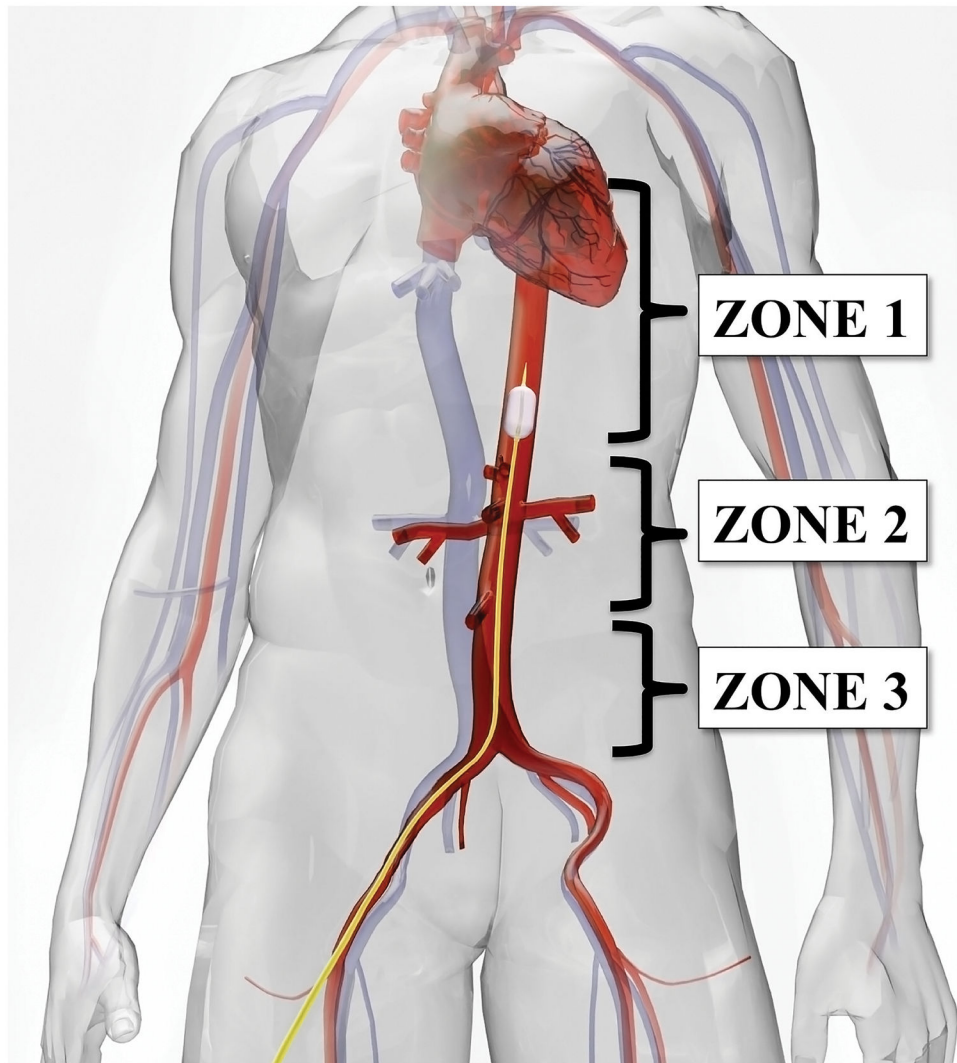


Figure 1. Zones of aortic occlusion. Zone I includes the descending thoracic aorta from the left subclavian artery to the level of the celiac artery. Zone I is the most common location of REBOA occlusion. Zone II extends from the celiac artery to the lowest renal artery. Occlusion in Zone II is rarely advisable. Zone III extends from the lowest renal artery to the aortic bifurcation. Zone III occlusion is suitable for pelvic and junctional hemorrhage of the lower extremities.

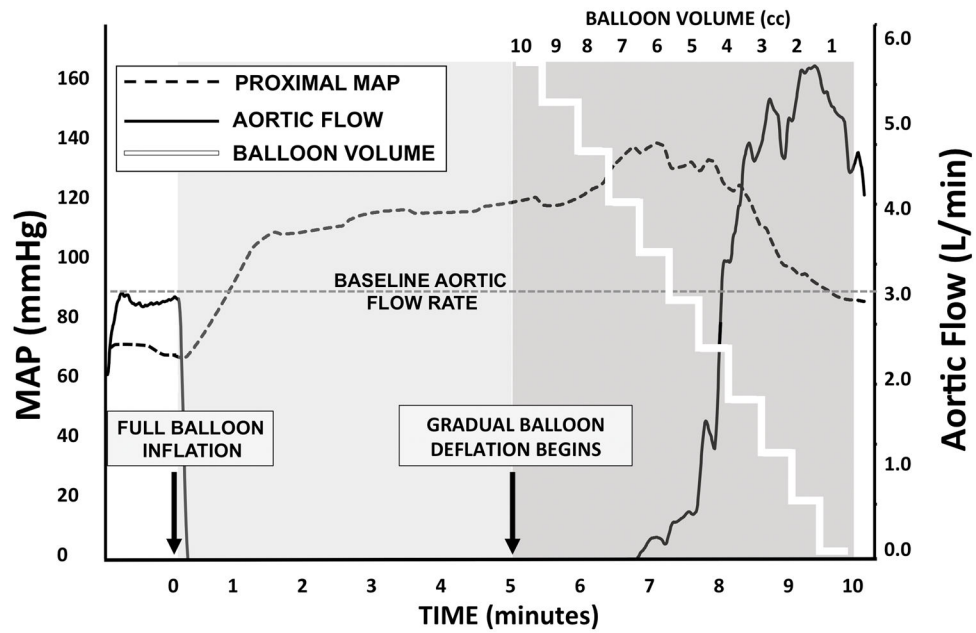


Figure 2. Aortic blood pressure and blood flow variation in response to inflation volume for an endoluminal aortic occlusion balloon. This graph depicts the relationship between CODA (Cook Medical, Bloomington, IN) balloon volume, mean arterial pressure in the proximal thoracic aorta, and distal aortic blood flow during 5 minutes of complete resuscitative endovascular balloon aortic occlusion followed by 5 minutes of incremental balloon deflation in a euvoletic Yorkshire-cross swine. MAP: Mean Arterial Pressure; REBOA: Resuscitative Endovascular Balloon Occlusion of the Aorta.

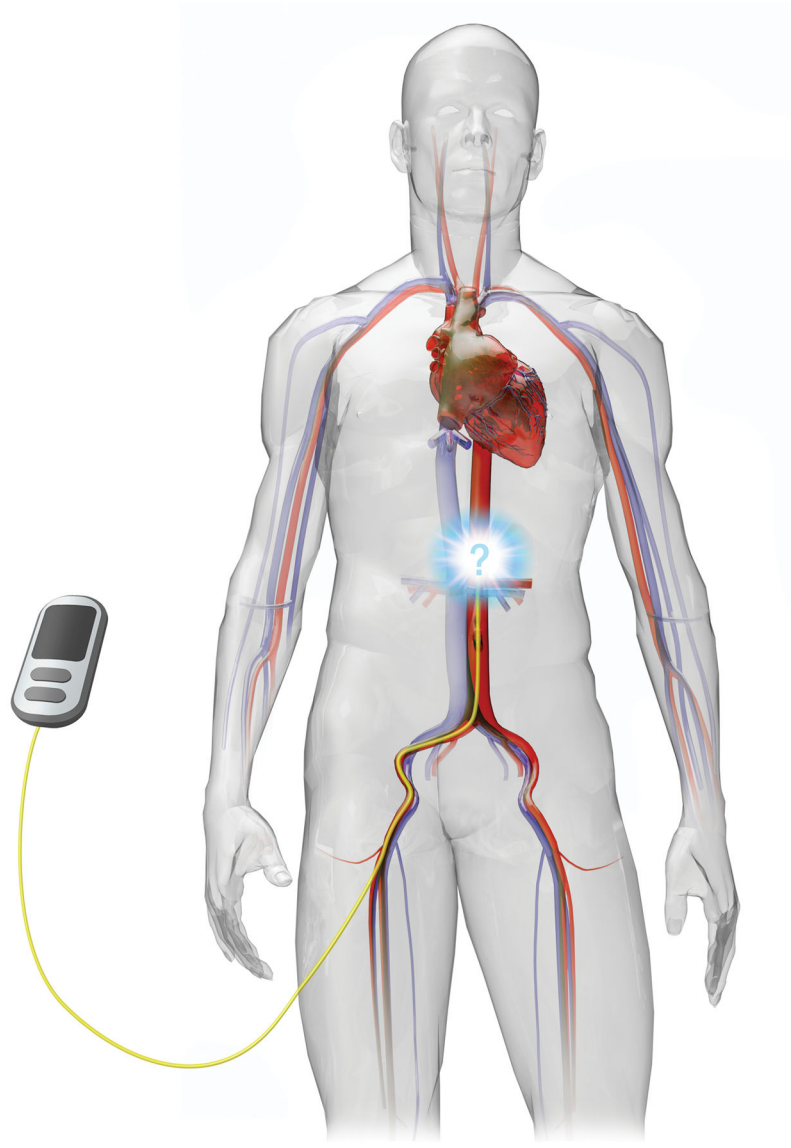


Figure 3. Endovascular Variable Aortic Control devices would rely on integrated physiologic monitoring equipment to sense the patient's hemodynamic changes and respond with real-time, dynamic regulation of distal aortic blood flow.

Table 1**CONSEQUENCES OF PROLONGED COMPLETE AORTIC OCCLUSION**

Proximal Effects	Distal Effects	Systemic Effects
↑ Aortic Afterload	↓ Cardiac Preload	Washout of Toxic Metabolites
↑ Blood Pressure	↓ Blood Pressure	Altered Vascular Tone
↑ Blood Flow	↓ Blood Flow	Hemodynamic Instability
End Organ Dysfunction	End Organ Dysfunction	Dysregulated Immune Response

Author Manuscript

Author Manuscript

Author Manuscript

Author Manuscript

Table 2

CUMULATIVE CLINICAL EXPERIENCE

Reference	Institution	Country	Technique	Number of Cases
Saito 2015	Nippon Medical School Chiba Hokusoh Hospital, Inzai	Japan	REBOA	24
Ogura 2015	Japan Red Cross Maebashi Hospital, Maebashi, Gunma	Japan	REBOA	28
Norri 2015	Multi-Center, Japanese Trauma Database	Japan	REBOA	452
Gupta 1989	Brookdale Hospital Medical Center, Brooklyn, New York	USA	REBOA	21
Brenner 2013	Adams Cowley Shock Trauma Center, Baltimore, Maryland, and Herman Memorial Hospital, The Texas Trauma Institute, Houston, Texas	USA	REBOA	6
Dubose, in press	Multi-Center, American Association for the Surgery of Trauma	USA	REBOA	104*
Ogura 2015	Japan Red Cross Maebashi Hospital, Maebashi, Gunma	Japan	I-REBOA	7
Horer 2016	Orebro University Hospital and Orebro University, Orebro	Sweden	P-REBOA	1
Davidson, in press	University of California Davis, Sacramento, California	USA	P-REBOA	1

REBOA, Resuscitative Endovascular Balloon Occlusion of the Aorta; I- REBOA, Intermittent REBOA; P-REBOA, Partial REBOA.

* as of March 2016.