

UC Irvine

UC Irvine Previously Published Works

Title

Extramammary Paget's Disease of the Vulva: Metastases to the Bone Marrow in the Absence of an Underlying Adenocarcinoma— Case Report and Literature Review

Permalink

<https://escholarship.org/uc/item/6hq0m3g5>

Journal

Gynecologic Oncology, 66(1)

ISSN

0090-8258

Authors

Cappuccini, Fabio
Tewari, Krishnansu
Rogers, Lowell W
et al.

Publication Date

1997-07-01

DOI

10.1006/gyno.1997.4735

Copyright Information

This work is made available under the terms of a Creative Commons Attribution License, available at <https://creativecommons.org/licenses/by/4.0/>

Peer reviewed

CASE REPORT

Extramammary Paget's Disease of the Vulva: Metastases to the Bone Marrow in the Absence of an Underlying Adenocarcinoma— Case Report and Literature Review

Fabio Cappuccini, M.D.,* Krishnansu Tewari, M.D.,* Lowell W. Rogers, M.D.,† and Philip J., DiSaia, M.D.*¹

*Division of Gynecologic Oncology, Department of Obstetrics & Gynecology, University of California, Irvine—Medical Center, 101 The City Drive, Orange, California 92868; and †Department of Pathology, Memorial Medical Center, 2801 Atlantic Avenue, Long Beach, California 90801

Received October 14, 1996

A case of Paget's disease of the vulva is presented which, over a period of 6 years, was characterized by local recurrences and metastases to the bone marrow. Detailed examination of multiple sections of the primary tumor and of the bone marrow biopsy specimen failed to demonstrate an underlying adenocarcinoma in any of the sites. The routine histologic staining and immunohistochemical staining demonstrated that the metastatic cells strongly correlated with cells from the vulvar lesion. Specifically, immunohistochemical staining of the specimens from the primary and metastatic sites was positive for the gross cystic disease fluid protein-15, which has been associated with extramammary Paget's disease uncomplicated by underlying malignancies. Finally, during several years of close follow-up, no other primary site of Paget's disease declared itself clinically or was found by radiographic studies or analysis of serum tumor markers.

© 1997 Academic Press

INTRODUCTION

Extramammary Paget's disease of the vulva (EMPD) was first described by Dubreuilh in 1901 as a variant of mammary Paget's carcinoma [1]. The lesion is found most commonly in postmenopausal Caucasian women, and when associated with an underlying adenocarcinoma (0–25% of cases), is very aggressive with metastases to the lymph nodes and other sites [2, 3]. The natural history of the disease involves multiple local recurrences over a period of many years, requiring multiple surgical procedures. We report a unique case of EMPD of the vulva with numerous recurrences, progression to invasive disease, and metastases to the bone marrow without evidence of an underlying adenocarcinoma.

CASE REPORT

Patient E.R. is a 70-year-old Caucasian gravida II, para II, who originally presented in November 1986 with complaints of vulvar irritation upon urination. A 6.5 × 2.3 cm raised dry lesion on the right labia majora was biopsied and revealed noninvasive extramammary Paget's disease. The patient was referred to Women's Hospital at Memorial Medical Center in Long Beach, California, where she underwent a partial vulvectomy and a split-thickness skin graft procedure. A superficial right inguinal lymphadenectomy was also performed. Figure 1 is a diagrammatic representation of the right vulvar surgical specimen. The pathology revealed intraepidermal Paget's disease of the vulva. The lesion was totally embedded for histology (34 blocks) and no invasion into the dermis or subcutaneous soft tissues was identified (Fig. 2). The margins of resection were free of tumor and seven of seven lymph nodes were without evidence of disease. She was without complaints until June 1990, when she presented with recurrent noninvasive disease in the right periclitoral region measuring 3 × 4 cm (23 tissue blocks examined). She underwent a skinning vulvectomy without a skin graft.

She was followed in the office periodically, and in November 1990 physical examination was notable for a 2 × 3 cm palpable, nontender left inguinal lymph node. A fine needle aspiration was performed and EMPD was demonstrated. She underwent a bilateral inguinal lymph node dissection with 3 of 11 lymph nodes in the left groin found to be positive for metastatic extramammary Paget's disease (Fig. 3); two of two nodes sampled on the right side were benign. The patient received whole pelvis external beam radiation therapy for a total dose of 50.4 Gy in 25 fractions. She was followed with serial examinations and carcinoembryonic an-

¹ To whom correspondence should be addressed.

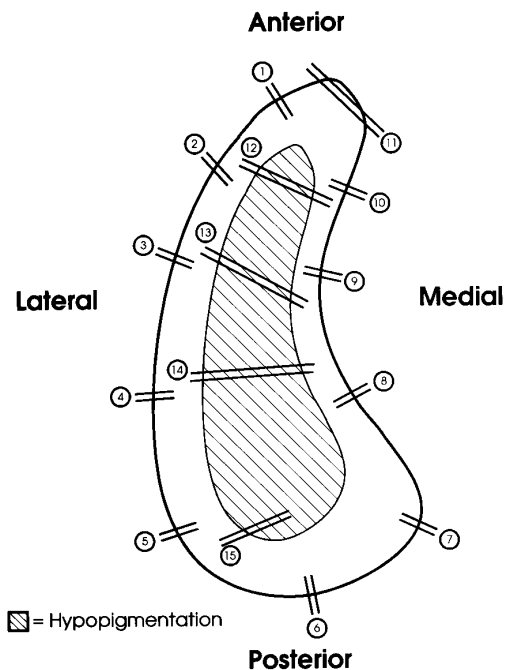


FIG. 1. Computer drawing based on the original surgical diagram of the right vulvar surgical specimen obtained at the time of partial vulvectomy in November 1986. The disease is depicted as the hypopigmented region measuring 6.5×2.3 cm. The entire specimen measured 11×3.2 cm.

tigen (CEA) levels, both of which remained within normal limits for nearly 1 year.

The patient presented in October 1991 with her second vulvar recurrence in the right periclitoral area, measuring approximately 0.5 cm^2 within the radiation field. In addition, she gave a history of 3 months of persistent and progressive low back pain without radiation. An initial series of lumbar-sacral radiologic films had revealed disk space narrowing and associated spondylosis with no blastic or lytic lesions. A bone scan was abnormal with increased uptake of radioactive tracer in the lumbar-sacral vertebral levels. Serum antinuclear antibody titer, rheumatoid factor, and treponemal antigen studies were negative and the sedimentation rate was only slightly elevated. The differential diagnosis at the time included sacral ileitis versus spondylosis, although a rare case of metastatic disease could not be ruled out.

A follow-up series of lumbar-sacral films demonstrated a compression fracture in the lumbar region and magnetic resonance imaging (MRI) of the spine showed diffuse replacement of the normal fatty marrow by foreign tissue (Fig. 4). An MRI of the abdomen and pelvis revealed mild left periaortic lymphadenopathy but no evidence of any ovarian or other pelvic or intra-abdominal masses.

During this period, the patient's complete blood count was notable for anemia (hematocrit, 22%) and leukopenia (white blood cell count, $3.8 \text{ K}/\mu\text{l}$) with a differential suggestive of bone marrow involvement (4% metamyelocytes, 2% myelocytes, target cells, and nucleated red blood cells). A

bone marrow biopsy of the left posterior iliac crest was performed with histologic findings consistent with metastatic extramammary Paget's disease (Fig. 5). Interestingly, no hematopoietic elements were identified in the specimen. A serum CEA level was obtained and found to be elevated at 115 ng/ml. The patient's serum electrophoresis study was within normal limits as were bilateral breast mammography and serum cancer antigen 125.

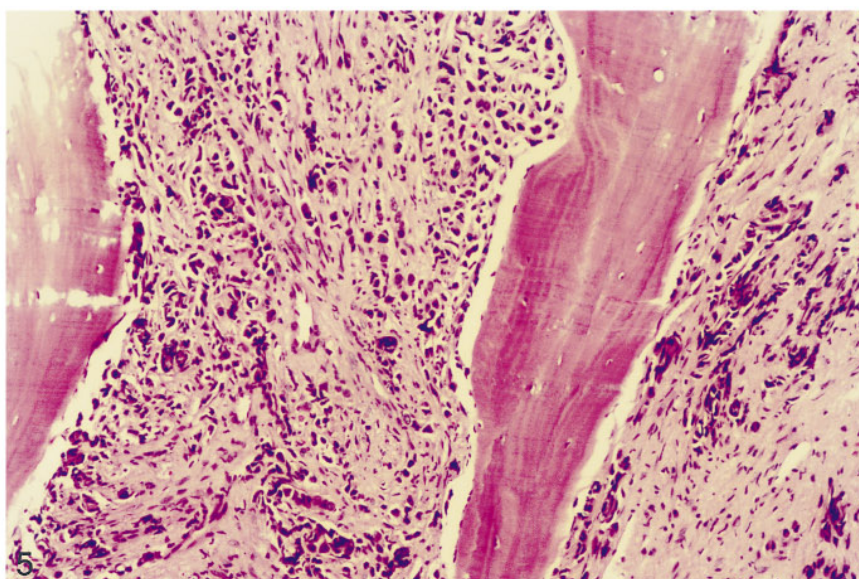
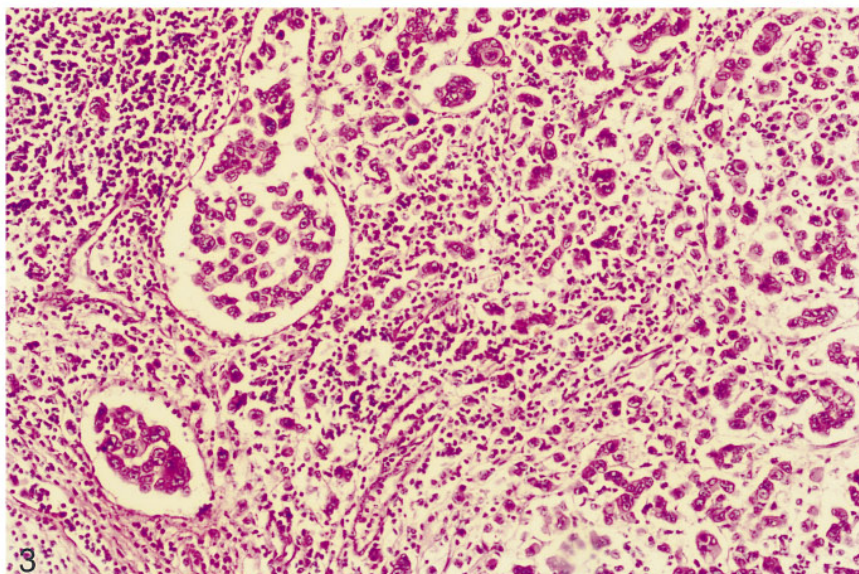
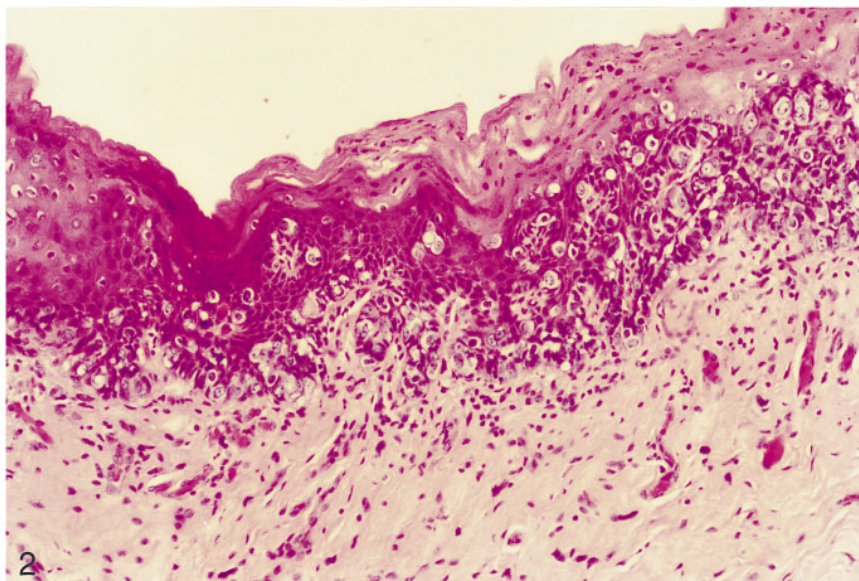
From October 1991 to January 1992, the patient completed four courses of vincristine ($1 \text{ mg}/\text{m}^2$, total dose $1.6 \text{ mg}/\text{course}$) and cisplatin chemotherapy ($75 \text{ mg}/\text{m}^2$, total dose $120 \text{ mg}/\text{course}$). Prior to each course the patient required blood transfusion for severe anemia. She tolerated this therapy well except for moderate nausea and vomiting. Although there was no evidence of progressive disease in the vulva, because of worsening metastases based on bone marrow metabolic assays and increasing serial serum CEA levels ($238\text{--}281 \text{ ng}/\text{ml}$), a decision was made to change chemotherapy to a second-line agent consisting of a continuous infusion of 5-fluorouracil (5FU) at $500 \text{ mg}/\text{m}^2/\text{day}$ for 5 days, totaling $3750 \text{ mg}/\text{cycle}$. The patient completed one cycle of 5FU in March 1992 and subsequently expired at home.

DISCUSSION

The clinical manifestations of EMPD are varied and without an observed pattern of progression. This has led some investigators to speculate that a disease spectrum exists which involves several separate pathologic entities. Extramammary Paget's disease may be confined to the epidermis (noninvasive Paget's disease) or it may be associated with a contiguous invasive adenocarcinoma considered to have a cutaneous adnexal gland nature (invasive Paget's disease). A third category of patients with EMPD has been reported showing a variety of types of carcinomas arising in nearby internal as well as distant organs (e.g., rectum, prostate, bladder, bile duct) [4, 5]. Cases in this third category of EMPD with noncutaneous "underlying carcinomas" are somewhat heterogeneous, with invasive malignancies sometimes only tenuously associated with the cutaneous Paget's disease phenomenon. Perhaps cases in this category should be considered separately from the first two groups in terms of pathogenesis, prognosis, and treatment.

The most striking feature which distinguishes Paget's disease of the vulva from Paget's disease arising in other sites is the low association with underlying adenocarcinoma. Indeed, in the majority of cases of nonvulvar Paget's disease, an adenocarcinoma is present. This association approaches 100% when the disease arises in the breast, while among the 200 cases of vulvar EMPD which exist in the literature, the incidence of underlying adenocarcinoma ranges from 0–25% [2].

In our patient, the opinion that the tumor cells in the



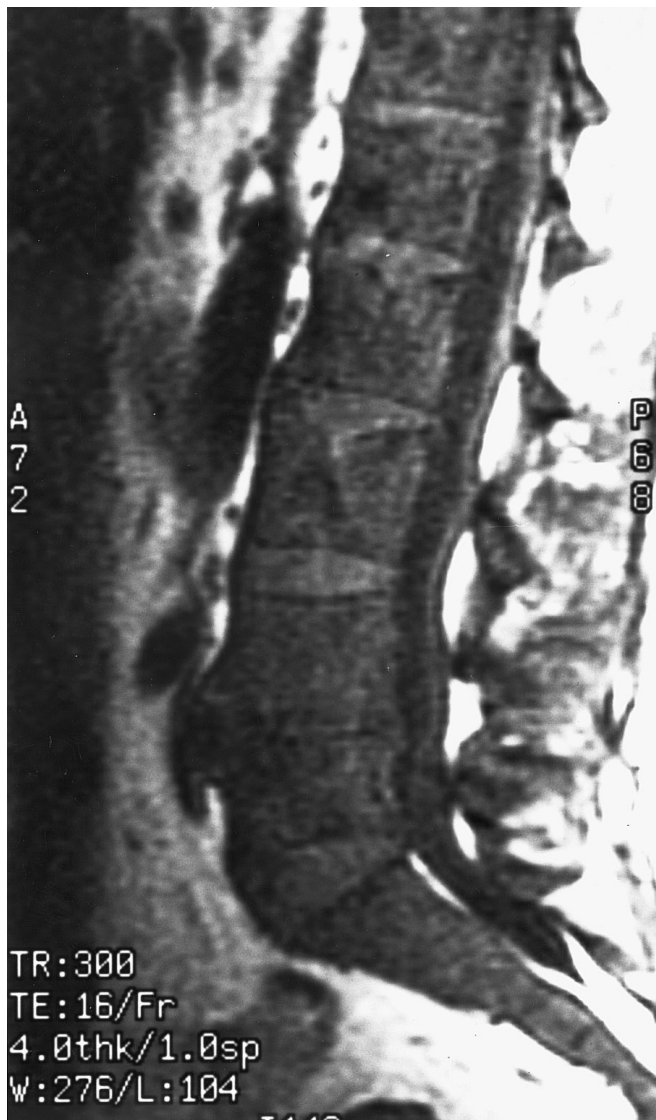


FIG. 4. Magnetic resonance image of the spine demonstrating diffuse replacement of the normal fatty marrow constituent by some other foreign tissue.

lymph nodes and bone marrow originated from the vulvar Paget's disease is based upon several lines of evidence. First, both the primary and metastatic tumor cells appeared similar at the H&E level of light microscopy. The tumor cells stained equivocally with mucicarmine. Additionally, the immunohistochemical findings demonstrated that both the intraepi-

thelial Paget's cells and the metastatic tumor cells were positive for CA 15-3, CAM 5.2, Her-2-neu, and gross cystic disease fluid protein-15 (GCDFP-15); both groups of cells were negative for Ca 19-9, CEA, S-100, and HMB-45. Interestingly, Kohler and Smoller reported 16 of 20 cases of extramammary Paget's disease without associated internal malignancies which were strongly reactive to GCDFP-15; only one of six cases with concomitant underlying carcinoma showed reactivity to GCDFP-15 [5]. Finally, despite careful clinical follow-up of up to 6 years, no other primary tumor site declared itself, either by symptomatology, clinical findings, or imaging studies. A few foci in the original excision site showed piling up of cells at the dermal-epidermal interface in the region of the clitoris. However, unequivocal dermal invasion was never documented despite histologic sectioning of the entire original lesion (34 tissue blocks) and of the recurrent lesion (23 tissue blocks).

It seems likely that subtle invasive tumor was, in fact, present and was not recognizable as such despite extensive histologic sectioning and repeated reviews on occasion of recurrences. This case, then, may be an example of minimally invasive Paget's disease, as described by Kodama *et al.* [6]. Another possibility that must be considered is that a few tumor cells were mechanically introduced into lymphatics at the time of surgical manipulation and that some of these cells were capable of growth at the site of ultimate vascular lodgment. Whatever the mechanism of metastasis, both the delayed presentation and the pattern of metastasis with ultimate spread to the bone are unusual.

Fine *et al.* reported a case of minimally invasive vulvar Paget's disease (1 mm depth of invasion) which developed extensive inguinofemoral lymph node metastases [7]. Hart and Millman described the sequential progression from intraepithelial Paget's disease, which had persisted after a simple vulvectomy, infiltrating the dermis and permeating the lymphatic channels with metastases to regional lymph nodes. No underlying primary adenocarcinoma had been present, thus establishing the invasive potential of the disease. Our case represents another report of vulvar EMPD, which over a 5-year interval progressed from an intraepithelial lesion to invasive disease with distant metastases. In addition, this is the first report of bone marrow metastases from what appeared to have originally been noninvasive intraepithelial disease.

Bone involvement by metastatic vulvar Paget's disease

FIG. 2. Partial vulvectomy specimen showing Paget's disease with no demonstrated stromal invasion. The epidermis consists of large cells with pale cytoplasm present singly and in small clusters within the epidermis. There was no underlying adenocarcinoma present and the margins of resection were free of Paget's disease.

FIG. 3. Metastatic carcinoma was found in the left inguinal lymph nodes. The cells were similar to the intraepidermal tumor cells from the partial vulvectomy specimen (Fig. 2) and were interpreted to represent metastatic carcinoma originating from extramammary Paget's disease of the vulva.

FIG. 5. Metastatic carcinoma was found in the left posterior iliac crest bone marrow. In this biopsy section, the bone marrow is entirely replaced by fibrosis with numerous large pleomorphic epithelial cells with prominent nucleoli; these malignant cells are surrounded by desmoplastic stroma. As in the inguinal lymph nodes (Fig. 3), the cells in the bone marrow were similar to the intraepidermal tumor cells and were interpreted to represent metastatic carcinoma originating from the Paget's disease of the vulva.

has been described previously, but such reports involved lesions known to be invasive and associated with underlying carcinoma. Parmley and colleagues reported seven cases of invasive extramammary Paget's disease of the vulva, three of which had metastases to the vertebrae, ribs, and bones of the pelvis [9]. Curtin *et al.* reviewed 36 cases of vulvar Paget's disease and found five patients with an associated invasive adenocarcinoma, one of whom died of widespread bony metastases [10]. Finally, of the 11 patients with EMPD of the vulva and underlying carcinoma reported recently by Kodama *et al.*, one had bone metastases and died 18 months after initial diagnosis [6].

An alternative explanation would be that the bone metastases represented either a new primary site for EMPD in the bone or that the bone was the site for metastases from a second primary EMPD from elsewhere in the body where there may have been an associated underlying carcinoma. Breast carcinoma is the malignancy most often occurring along with vulvar Paget's disease [11] and is known to develop metastases to the bone. In addition, the urogenital area has a strong potential for developing a second primary malignancy when vulvar Paget's disease exists. Degefu and colleagues reviewed the literature and noted several sites in the pelvis where malignancies were found in patients with EMPD of the vulva [12], including the vulva (melanoma and Bartholin gland carcinoma), the uterine cervix, the urinary bladder, and the ovary (3 to 10 cases per site); they noted one case each of a cancer involving the urethra, the vagina, and the uterine corpus in patients with vulvar Paget's disease.

Although an unknown carcinogenic stimulus may exist which could affect the epidermis of the vulva, the uterine cervix, and other structures in the pelvis, independently and concomitantly, accounting for multiple malignancies in one patient, in our case no other site of disease was identified. Papanicolaou specimens collected during follow-up office visits were within normal limits, as was a serum cancer antigen 125. In addition, imaging studies revealed no pelvic, ovarian, or intra-abdominal masses. The patient had neither postmenopausal vaginal bleeding nor urinary complaints. Finally, routine breast examination and screening mammography were also normal. The presence of noncontiguous disease in the bone marrow (the iliac crest and the spine) is consistent with metastatic Paget's disease.

It is our philosophy at the Division of Gynecologic Oncology at the University of California at Irvine that EMPD of the vulva is almost always a noninvasive intraepithelial lesion analogous in its behavior to squamous cell carcinoma *in situ* of the vulva and can be managed conservatively without loss of sexual function and cosmesis. Treatment at our institution consists of a skinning vulvectomy with split-thickness skin grafting as per Rutledge and Sinclair [13]. Intraoperative frozen-section analysis of proposed margins is essential to ensure resection of involved areas.

Because the disease is a multifocal entity, local recurrences are common even when the margins of resection are negative, as occurred in our case. In addition, our group has documented two cases of recurrent vulvar Paget's disease in a split-thickness skin graft with simultaneous occurrence of disease outside the grafted area; this may occur via "retrodissemination" or a migratory behavior of Paget's cells into the skin graft from a peripheral occult metastatic site [14].

The disease without underlying adenocarcinoma remains, for the most part, as an intraepithelial lesion and has only occasionally been reported to become invasive and metastasize. We believe that the development of low back pain in our patient heralded the development of bone marrow metastases. Patients with vulvar Paget's disease are at risk for the development of metastatic disease and second primary tumors. In every patient, close follow-up is prudent and all symptoms should be thoroughly investigated.

REFERENCES

1. Breen JL, Smith CI, Gregori CA: Extramammary Paget's disease. *Clin Obstet Gynecol* 21:1107-1115, 1978
2. Bergen S, DiSaia PJ, Liao SY, Berman ML: Conservative management of extramammary Paget's disease of the vulva. *Gynecol Oncol* 33:151-156, 1989
3. Lee SC, Roth LM, Ehrlich C, Hall JA: Extramammary Paget's disease of the vulva: A clinicopathologic study of 13 cases. *Cancer* 39:2540-2549, 1977
4. Nakano S, Narita R, Tabaru A, Ogami Y, Otsuki M: Bile duct cancer associated with extramammary Paget's disease. *Am J Gastroenterol* 90:507-508, 1995
5. Kohler S, Smoller BR: Gross cystic disease fluid protein-15 reactivity in extramammary Paget's disease with and without associated internal malignancy. *Am J Dermatopathol* 18:118-123, 1996
6. Kodama S, Kaneko T, Saito M, Yoshiya N, Honma S, Tanaka K: A clinicopathologic study of 30 patients with Paget's disease of the vulva. *Gynecol Oncol* 56:63-70, 1995
7. Fine BA, Fowler LJ, Valente PT, Gaudet T: Minimally invasive Paget's disease of the vulva with extensive lymph node metastases. *Gynecol Oncol* 57:262-265, 1995
8. Hart WR, Millman JB: Progression of intraepithelial Paget's disease of the vulva to invasive carcinoma. *Cancer* 40:2333-2337, 1977
9. Parmley TH, Woodruff JD, Julian CG: Invasive vulvar Paget's disease. *Obstet Gynecol* 46:341-346, 1975
10. Curtin JP, Rubin SC, Jones WB, Hoskins WJ, Lewis JL: Paget's disease of the vulva. *Gynecol Oncol* 39:374-377, 1990
11. Friedrich E, Wilkinson E, Steingraeber P, Lewis D: Paget's disease of the vulva and carcinoma of the breast. *Obstet Gynecol* 46:130-134, 1975
12. Degefu S, O'Quinn AG, Dhurandhar HN: Paget's disease of the vulva and urogenital malignancies: A case report and review of the literature. *Gynecol Oncol* 25:347-354, 1986
13. Rutledge F, Sinclair M: Treatment of intraepithelial carcinoma of the vulva by skin excision and graft. *Am J Obstet Gynecol* 102:806, 1986
14. DiSaia PJ, Dorion GE, Cappuccini F, Carpenter PM: A report of two cases of recurrent Paget's disease of the vulva in a split-thickness graft and its possible pathogenesis-labeled "retrodissemination". *Gynecol Oncol* 57:109-112, 1995