

UCSF

UC San Francisco Previously Published Works

Title

223 IMMUNE CELL PHENOTYPING IN BARRETT'S ESOPHAGUS IN PATIENTS PRIOR AND AT TIME OF PROGRESSION

Permalink

<https://escholarship.org/uc/item/6hh7q404>

Journal

Gastroenterology, 164(6)

ISSN

0016-5085

Authors

Lin, Meng-Lay

Hickey, John W

Schürch, Christian M

et al.

Publication Date

2023-05-01

DOI

10.1016/s0016-5085(23)01056-9

Copyright Information

This work is made available under the terms of a Creative Commons Attribution License, available at <https://creativecommons.org/licenses/by/4.0/>

Peer reviewed

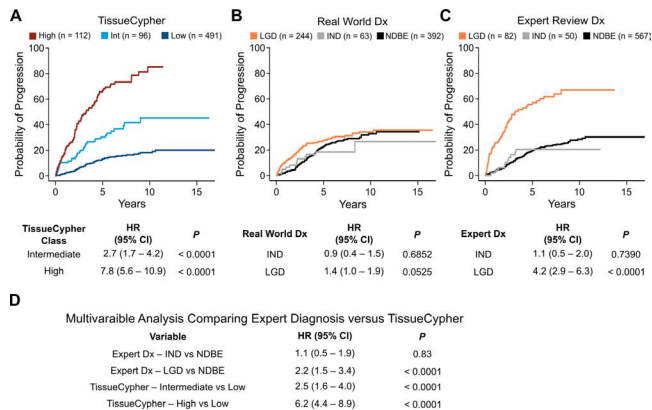


Figure 1. TissueCypher (TSP-9) provides significantly improved risk stratification versus pathology diagnosis. Kaplan-Meier (KM) analysis of probability of progression to HGD/EAC in patients with BE stratified into: (A) Low-, intermediate-, and high-risk classes by the TSP-9 test; (B) NDBE, IND, and LGD subsets by the original/real-world diagnoses abstracted from health records; (C) NDBE, IND, and LGD by expert review diagnoses provided as part of research studies. (D) Multivariable analysis comparing the prediction of progression by the TSP-9 test versus expert review diagnosis. n=699 BE patients in panels A-D. 5-year hazard ratios (HRs) with a 95% confidence interval (CI) were calculated from an accelerated time failure (AFT) regression model.

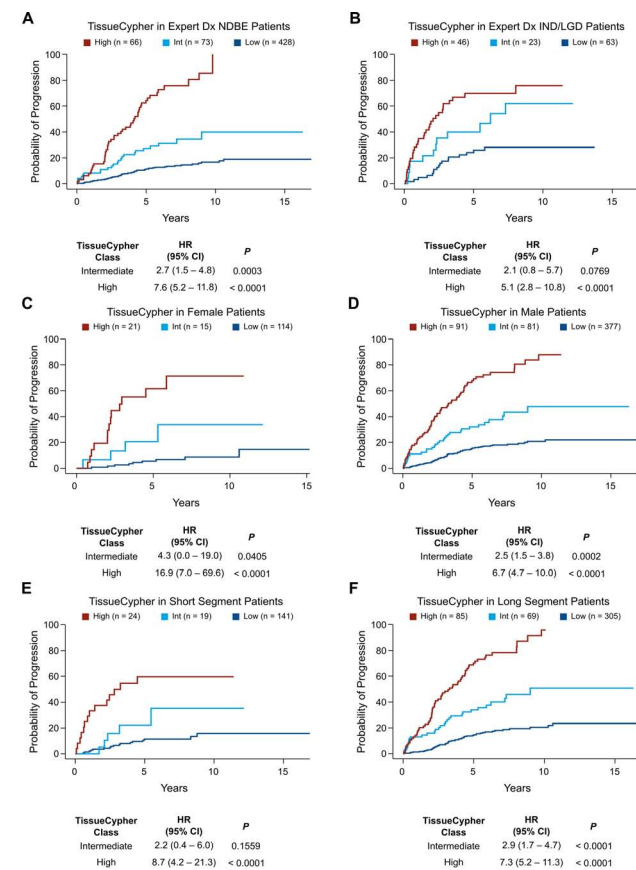


Figure 2. TSP-9 provides significant risk stratification in subsets of NDBE, IND/LGD, male, female, short-segment, and long-segment BE patients. KM analysis of probability of progression to HGD/EAC in patients stratified into low-, intermediate-, and high-risk classes by the TSP-9 test, in the following subsets: (A) Patients with expert review diagnosis of NDBE (n=567); (B) Patients with expert review diagnosis of IND/LGD (n=132); (C) Female patients with BE (n=150); (D) Male patients with BE (n=549); (E) Patients with short-segment BE (n=184); (F) Patients with long-segment BE (n=459). 5-year hazard ratios (HRs) with 95% confidence intervals (CI) were calculated from an accelerated time failure (AFT) regression model.

RNAseq to understand how immune cells interact with each other in metaplasia in patients that develop dysplasia. **Methods:** We set out to unveil spatial phenotyping of immune cells in the stromal compartments of non-dysplastic BE using a highly multiplexed imaging approach, termed co-detection by indexing (CODEX), with a panel of 56 antibody markers on Tissue Microarrays (TMA) that identify most cells within BE tissue. Our cohort consists of 26 BE patients (69 cores of non-dysplastic BE) who have never progressed to EAC and 6 BE patients (48 cores of non-dysplastic BE from patients that developed cancer). Only areas containing metaplasia were studied. The identification of cell types, spatial organization, and neighborhood-neighborhood interaction was performed using unsupervised, k-means clustering, and cross-type Ripley's K function respectively. The landscape of spatially resolved transcriptome of stroma was further profiled using LCM and RNAseq. **Results:** Overall, our data identified twelve different types of immune cells in BE microenvironment. M1 macrophages and plasma cells were the most abundant immune cell type, followed by CD4+ and CD8+ T cells irrespective of disease progression. Furthermore, progressors showed a significant elevation of immune cell concentrations, in particular CD4+ Treg cells, Neutrophils, and Nature killer cells (NKs), and a reduced population of B cells and dendritic cells. Interestingly, an NK cell subset (CD11b^{high}, CD56^{dim}, Annexin A1^{high}, and P63^{high}) was exclusively observed in progressors. We also identified seven unique immune cell neighborhoods (CNs), and CNs enriched with plasma, NKs, CD4 cells, and DCs were spatially associated with progressive metaplasia. These findings were concordant with the RNAseq data showing a set of highly expressed genes in the stroma of the progressors that were associated with long-lived plasma cells (CD38^{hi} CD38+), neutrophils, and inflammation-associated unfolded protein responses. **Conclusions:** We show for the first time that long-lived plasma cells at chronic inflammation sites may contribute to dysplasia progression. Together with a unique immune cell signature (CD4+ Treg, Neutrophils, NKs, and loss of DCs and B cells) in adjunct with CN/Cell interaction profiles may provide a novel strategy in developing models of cancer risk stratification in BE patients.

224

EXTERNAL VALIDATION OF A DEEP LEARNING MODEL FOR WHOLE SLIDE IMAGE ANALYSIS IN THE HISTOLOGIC DIAGNOSIS OF DYSPLASTIC BARRETT'S ESOPHAGUS

Don C. Codipilly, Shahriar Faghani, Karan Sachdeva, Erin Gibbons, Ramona Lansing, Melissa Passe, Cadman L. Leggett, David A. Katzka, Mana Moassefi, Pouria Rouzrokh, Bardia Khosravi, Catherine E. Hagen, Jason T. Lewis, Pallavi A. Patil, Vani Konda, Shajan Peter, Sameer Al Difalaha, Brian Brinkerhoff, Mary Wong, Fouad Otaki, Nicholas J. Shaheen, Bradley Erickson, Prasad G. Iyer

Introduction: Barrett's esophagus (BE) progresses to esophageal adenocarcinoma (EAC) via the development of low (LGD) and then high grade dysplasia (HGD). The histological diagnosis of BE dysplasia is challenging due to subjectivity and confounding by inflammatory artifact. This leads to misclassification of dysplasia grade and substantial interobserver variability even amongst expert pathologists. Hence, there is a critical need to improve diagnostic capabilities for BE dysplasia grade determination, currently the only criteria for endoscopic therapy. We have previously developed an ensemble machine learning BE dysplasia deep learning model (BEDDLM), leveraging whole slide images (WSI) of BE biopsies, from one academic institution, combining an object detection (You Look Only Once" (YOLO)) and classifier (ResNet 101) models. We aimed to externally validate BEDDLM on BE WSIs from three academic medical centers. **Methods:** We obtained non-dysplastic BE (NDBE), LGD, and HGD histology slides (hematoxylin and eosin stained) from two academic medical centers. All slides were reviewed by GI pathologists at the home academic institution, and by two additional expert GI study pathologists (CH and JL). The criterion standard was dysplasia grade as per agreement between at least two of three expert GI pathologists (2 study and 1 academic home institution). Slides were digitized using a high-resolution scanner (Aperio, Leica Biosystems, Buffalo Grove, IL). The object detection model identified regions of interest (ROI) providing first-pass dysplasia grade prediction, followed by feeding these ROIs into a ResNet101 classifier model. Dysplasia grade prediction was based on the highest grade of dysplasia agreement between the two models. **Results:** We included 274 WSIs from 165 patients from two external academic medical centers in this analysis. Baseline patient characteristics are shown in **Table 1**. 18% of WSIs were from endoscopic resection specimens, which had not been used for BEDDLM development. Almost 50% of samples had a consensus diagnosis of NDBE with LGD and HGD being approximately 25% each. Results (**Table 2**) showed high sensitivity, specificity and F1 score (measure of precision and recall) for the diagnosis of NDBE and HGD, with more moderate results for LGD. Comparable results were found based on a 2 class model prediction (dysplasia vs. no dysplasia). Additional WSIs from external site 3 (with NDBE, LGD and HGD WSIs) are currently being analyzed. **Conclusion:** We externally validated BEDDLM for the artificial intelligence powered prediction of BE dysplasia grade. This model, after additional optimization (particularly for LGD) and testing could be used in community and academic pathology practices to increase accuracy and decrease interobserver variability in BE dysplasia grade diagnosis.

223

IMMUNE CELL PHENOTYPING IN BARRETT'S ESOPHAGUS IN PATIENTS PRIOR AND AT TIME OF PROGRESSION

Meng-Lay Lin, John W. Hickey, Christian M. Schürch, Adam M. Passman, Emanuela Carlotti, Shruthi Devkumar, Richard J. Hackett, Manuel Rodriguez-Justo, Marco Novelli, Marnix Jansen, Philippe D. Gascard, Thea D. Tlsty, Stuart A. McDonald

Introduction: Barrett's Esophagus (BE) is characterised by the metaplastic replacement of squamous with columnar epithelium. However, BE is also an inflammatory condition and immune infiltration has been widely reported, little is known about the overall immune landscape at the cellular level, nor do we know much about the genes expressed. Furthermore, the role that immune cells play in progression to cancer is poorly understood. Here we use multiplex immunohistochemistry combined with laser-capture microdissection (LCM)