

## **UC Davis**

### **UC Davis Previously Published Works**

#### **Title**

Internal Acoustic Canal Stenosis Due to Hyperostosis

#### **Permalink**

<https://escholarship.org/uc/item/6g30z1sw>

#### **Journal**

Journal of Neurological Surgery Part B Skull Base, 81(03)

#### **ISSN**

1526-8012

#### **Authors**

Goodarzi, Amir  
Toussi, Atrin  
Garza, Nicholas  
[et al.](#)

#### **Publication Date**

2020-06-01

#### **DOI**

10.1055/s-0039-1685530

Peer reviewed

# Internal Acoustic Canal Stenosis Due to Hyperostosis

Amir Goodarzi<sup>1</sup> Atrin Toussi<sup>1</sup> Nicholas Garza<sup>1</sup> Mirna Lechpammer<sup>1,2</sup> Hilary Brodie<sup>3</sup>  
Rodney C. Diaz<sup>3</sup> Kiarash Shahlaie<sup>1</sup>

<sup>1</sup>Department of Neurological Surgery, Davis School of Medicine, University of California, Sacramento, California, United States

<sup>2</sup>Department of Pathology, Davis School of Medicine, University of California, Sacramento, California, United States

<sup>3</sup>Department of Otolaryngology/Head and Neck Surgery, Davis School of Medicine, University of California, Sacramento, California, United States

Address for correspondence Kiarash Shahlaie, MD, PhD, Department of Neurological Surgery, Davis School of Medicine, University of California, 4860 Y Street, Suite 3740, Sacramento, CA 95817, United States (e-mail: krshahlaie@ucdavis.edu).

J Neurol Surg B 2020;81:216–222.

## Abstract

**Background** Exostoses and osteomas are benign, insidious lesions of the bone involving the internal acoustic canal (IAC). We present two cases of IAC exostoses managed with surgical decompression and review the clinical outcomes of previously reported cases in the literature.

**Methods** A comprehensive search was conducted using PubMed Central, Web of Science Core Collection, and Google Scholar databases to identify previous reports of IAC exostoses and osteomas. A total of 26 reported cases were identified, and patient presenting symptoms, management strategies, and response to surgery was obtained when available.

**Results** Of the 13 patients who underwent surgical decompression, 8 patients had resolution of vertigo symptoms, 10 patients had improvement of tinnitus symptoms, and all patients maintained some level of serviceable hearing.

**Conclusion** IAC exostoses and osteomas are rare lesions that lead to insidious onset of debilitating symptoms from vestibulocochlear nerve dysfunction. Although the role of surgical decompression remains unclear, it appears that patients presenting with vertigo have more favorable response to surgical decompression as compared with those presenting with tinnitus and sensorineural hearing loss.

## Keywords

- ▶ internal acoustic canal
- ▶ osteoma
- ▶ exostosis
- ▶ decompression
- ▶ surgical

## Introduction

Exostoses and osteomas are benign lesions originating from the calvarium and facial bones.<sup>1</sup> Internal acoustic canal (IAC) osteomas and exostoses are exceedingly rare, with only a small number of reports existing in the literature.<sup>1–7</sup> Although histologically distinct, both lesions can present with hyperostotic growth adjacent to the IAC resulting in compression of neurovascular structures. These patients often present with sensorineural hearing loss, vertigo, and/

or tinnitus, caused by compression of neurovascular structures within the cerebellopontine angle.<sup>2,3</sup> Radiographic imaging is not consistently reliable in differentiating these two lesions, and frequently histopathology is necessary for the final diagnosis. Once radiographic evidence confirms a symptomatic lesion, surgical decompression of neurovascular structures is considered to prevent further progression of symptoms.<sup>2,4</sup>

To date, only 26 cases of exostoses and/or osteomas resulting in stenosis of the IAC have been reported.<sup>1–7</sup>

received

January 8, 2019

accepted after revision

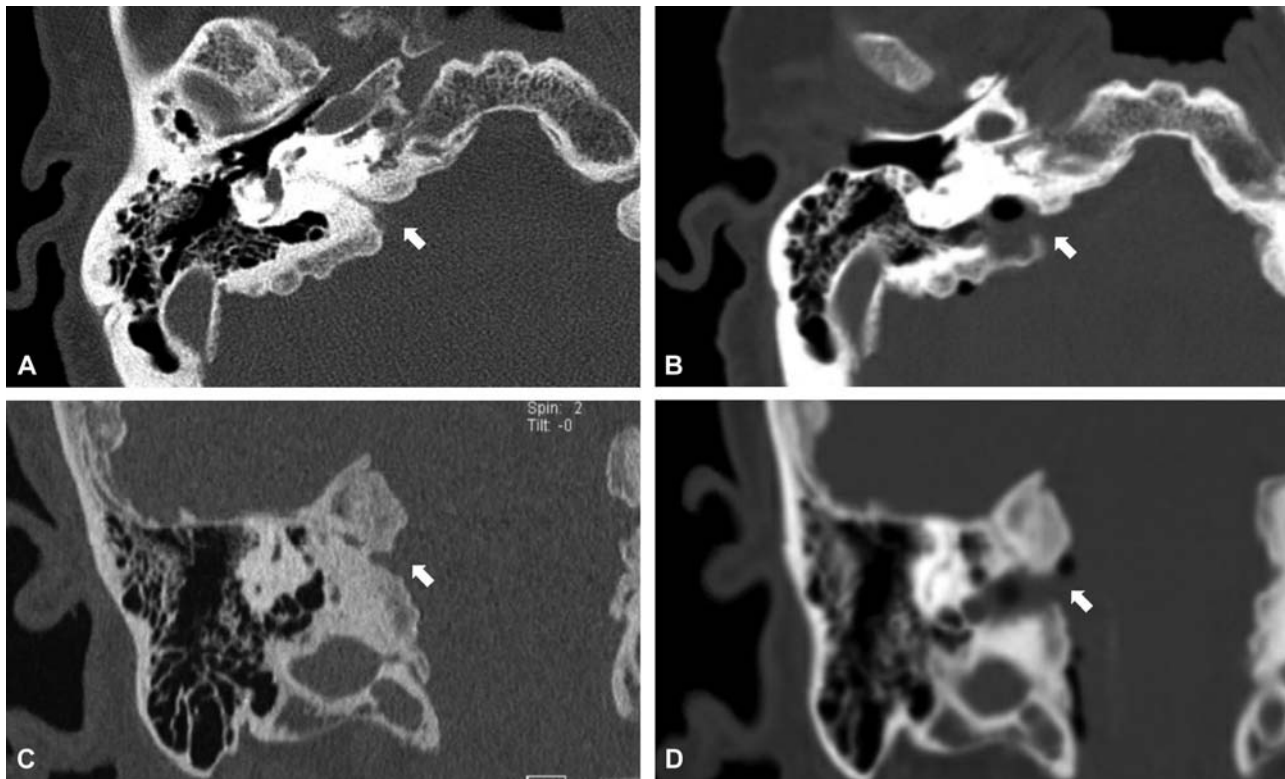
March 11, 2019

published online

April 22, 2019

© 2020 Georg Thieme Verlag KG  
Stuttgart · New York

DOI <https://doi.org/10.1055/s-0039-1685530>.  
ISSN 2193-6331.



**Fig. 1** Temporal bone computed tomography (CT) demonstrating preoperative IAC stenosis and postoperative IAC surgical decompression. (A) Preoperative axial plane CT of the temporal bone demonstrating stenosis of the IAC (white arrow). (B) Postoperative axial plane CT of the temporal bone demonstrating decompression of the IAC (white arrow). (C) Preoperative coronal plane CT of the temporal bone demonstrating stenosis of the IAC (white arrow). (D) Postoperative coronal plane CT of the temporal bone demonstrating decompression of the IAC (white arrow). IAC, internal acoustic canal.

Clinical outcomes following surgery are variable, and the likelihood of neurological stability or recovery have not been previously explored in this population. We present our institutional series treating two patients with bilateral IAC exostoses, and summarize the existing literature on the histopathology, radiographic characteristics, and treatment strategies for these rare lesions.

## Case Series

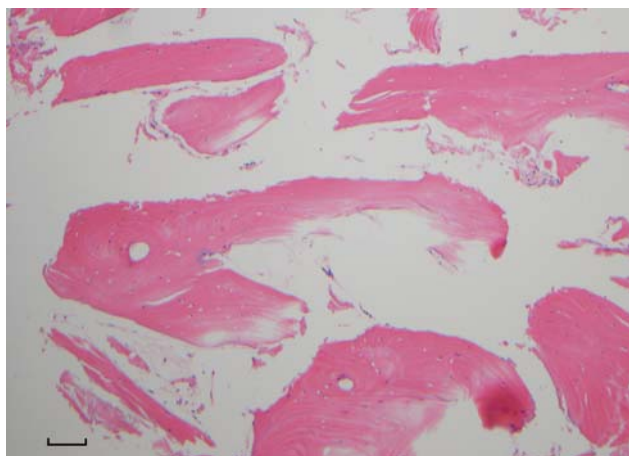
### Case 1

A 67-year-old right-hand dominant woman with a history of diabetes mellitus, pulmonary embolus, and breast cancer presented with a 2-year history of dysequilibrium with frequent falls, vertigo, severe right-sided tinnitus, and progressive bilateral hearing loss (left greater than right). The left sided hearing loss began 10 years earlier and slowly progressed to a profound loss. The hearing loss on the right began 4 years prior to presentation and had been insidiously progressing. Physical examination revealed House–Brackmann grade II right-sided facial weakness and bilateral horizontal nystagmus with both left and right lateral gaze. Audiometric studies with air and bone pure tone thresholds revealed moderate sensorineural hearing loss in the right ear and a profound sensorineural hearing loss in the left ear. The patient had a word recognition score (WRS) of 80% and a speech reception threshold (SRT) of 55 dB in the right ear,

and a WRS which was untestable and a SRT of no response (speech detection threshold of 100 dB) in the left ear. Tympanometry tracings were consistent with normal middle ear pressures and impedances bilaterally.

A temporal bone computed tomography (CT) scan revealed bilateral, broad based, heterogeneous lesions arising from the lateral aspects of the porus acusticus, resulting in narrowing of the IAC, with the right IAC measuring 1.6 mm in diameter and the left IAC measuring 0.9 mm in diameter (→ Fig. 1). Magnetic resonance imaging (MRI) demonstrated areas of high fluid attenuated inversion recovery signal within the hypertrophic bone adjacent to the IAC.

To prevent progressive compressive injury to right facial nerve and improve vertigo symptoms, and to prevent worsening hearing loss, the decision was made to prophylactically surgically decompress the right IAC. The patient underwent a right retrosigmoid keyhole craniotomy to the posterior fossa.<sup>8</sup> After elevating the cerebellum and releasing cerebrospinal fluid for brain relaxation, a large bony mass was encountered encompassing the entrance into the IAC. A 3 mm coarse diamond drill burr with continuous saline irrigation was used to remove the bony lesion involving the floor and posterior wall of the medial segment of the IAC, providing decompression of the cranial nerve complex. Bone removal was performed laterally until reaching the mid portion of the IAC which was relatively less stenotic.



**Fig. 2** H&E stained section,  $\times 100$  magnification, ruler 500  $\mu\text{m}$  of the specimen from patient presented in case 1. Tissue histology revealed mound like bony proliferation resembling normal cortical bone, without any evidence of hematopoietic cells consistent with exostosis. H&E, hematoxylin and eosin.

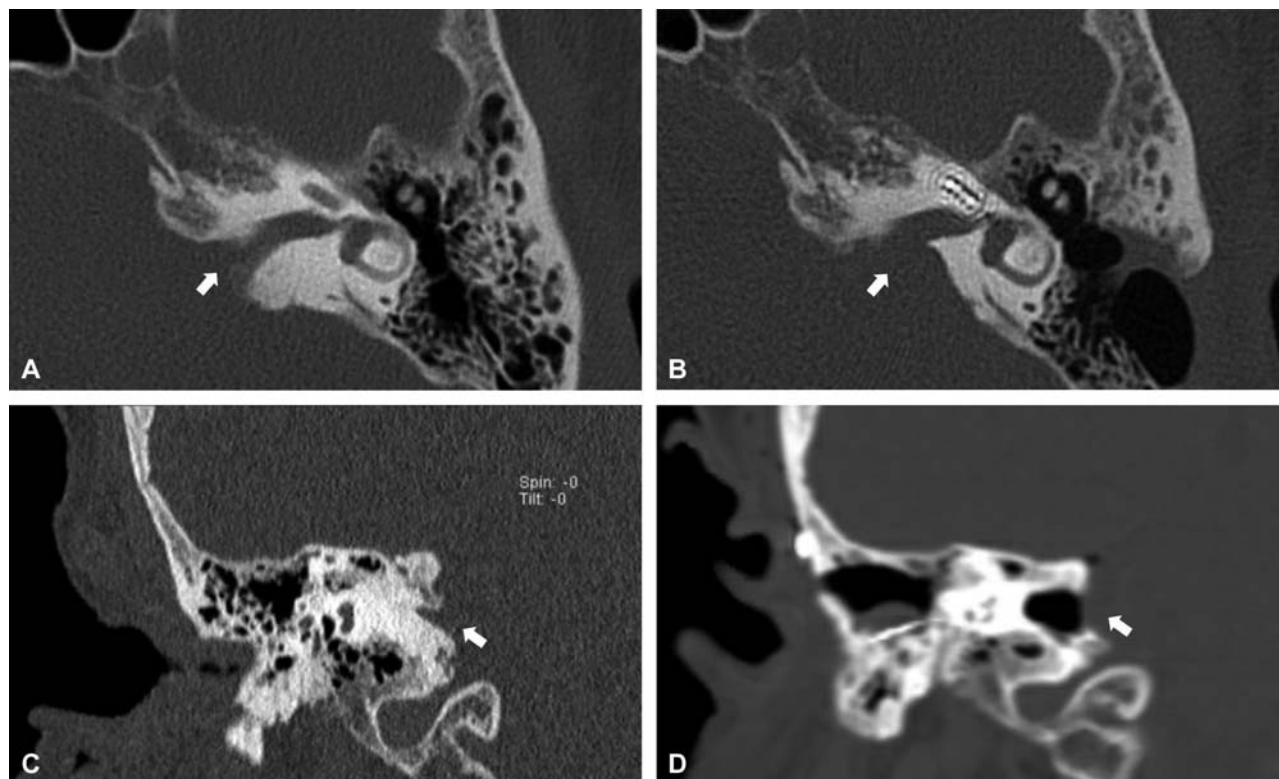
Following surgery, the patient reported resolution of her tinnitus and vertigo symptoms, although she continues to experience intermittent disequilibrium. Her hearing remained stable in the week following surgery but then slowly declined over the subsequent 2 months. Postoperative CT scans of the temporal bone demonstrated adequate decompression of the IAC (**Fig. 1**). Repeat audiogram

4 weeks after surgery revealed a 25 dB worsening in SRT in the right ear and a 54% reduction in WRS (80–26%). Six months after surgery, the patient continued to be free of vertigo, and did not report significant tinnitus. There were no significant improvements in her hearing, with WRS remaining stable at 26%. At this time, she was referred for cochlear implantation.

Surgical tissue histology revealed mound-like bony proliferation resembling normal cortical bone, without any evidence of hematopoietic cells. This was consistent with a diagnosis of exostosis (**Fig. 2**).

### Case 2

A 68-year-old right-hand dominant woman with a history of breast cancer, hypothyroidism, and recurrent otitis media in childhood presented with a 20-year history of progressive bilateral hearing loss, and severe right-sided tinnitus. Audiometric studies revealed a WRS of 26% and pure tone audiogram (PTA) of 83 dB in the right ear, and WRS of 32% and PTA of 77 dB in the left ear. Pure tone audiogram air conduction and bone conduction testing were demonstrated profound hearing loss for 250 to 8,000 Hz in the right ear and moderate to profound hearing loss in the left ear. Tympanometry tracings were consistent with normal middle ear pressure and tympanic membrane mobility bilaterally. Arizona Biomedical Institute (AZ-BIO) score was 0% bilaterally when using a hearing aid.



**Fig. 3** Temporal bone computed tomography (CT) demonstrating preoperative IAC stenosis and postoperative IAC surgical decompression. (A) Preoperative axial plane CT of the temporal bone demonstrating stenosis of the IAC (white arrow). (B) Postoperative axial plane CT of the temporal bone demonstrating decompression of the IAC (white arrow). (C) Preoperative coronal plane CT of the temporal bone demonstrating stenosis of the IAC (white arrow). (D) Postoperative coronal plane CT of the temporal bone demonstrating decompression of the IAC (white arrow). IAC, internal acoustic canal.

Temporal bone CT scans revealed bilateral broad-based hyperostotic lesions arising from the lateral aspect of the porus acusticus, resulting in narrowing of IAC with the right IAC measuring 0.8 mm in diameter and the left IAC measuring 2 mm in diameter (►Fig. 3).

The patient met the criteria for a cochlear implant; however, there were concerns that if the IAC stenosis progressed, the long-term viability for hearing preservation would be diminished. Consequently, the decision was made to decompress the IAC in conjunction with the placement of a cochlear implant. The patient underwent a right retrosigmoid keyhole craniotomy approach to the posterior fossa.<sup>8</sup> Severe hyperostosis involving the petrous ridge was encountered, obscuring surgical visualization of the porus acusticus. A combination of 3 mm and curved 2 mm coarse diamond drill burrs with continuous saline irrigation were used to remove bone posteriorly to provide visualization of the porus acusticus. The decompression was achieved by removing bone posterior and inferior to the IAC. Bone removal was performed laterally until reaching the relatively less stenotic mid portion of the IAC. At the conclusion of the decompression, a right-sided cochlear implant was placed via a mastoidectomy facial recess approach to the round window insertion.

Immediately after surgery, the patient noted stable right-sided hearing acuity and no tinnitus. A postoperative CT scan of the temporal bone demonstrated adequate decompression of the IAC (►Fig. 3), and she was discharged on postoperative day 3. Repeat audiologic evaluation 6 weeks after surgery showed significant improvements in warble tone acuity, especially from the right cochlear implant. AZ-BIO scores were 83% with the right cochlear implant active and 90% in the bimodal condition. However, the patient continued to have intermittent tinnitus.

Surgical tissue histology revealed concentric layers of subperiosteal bone with frequent osteocytes and there was no evidence of hematopoietic cells. These results were consistent with a diagnosis of exostosis.

## Discussion

The terms exostoses and osteomas have been used interchangeably since 1979, when they were first differentiated based on histology and radiographic studies.<sup>5</sup> Although both of these lesions are benign, exostoses are thought to represent an inflammatory overgrowth of bone whereas osteomas are thought to be neoplastic in origin.<sup>9</sup> Osteomas commonly occur as solitary and pedunculated lesions arising near the tympanosquamous or tympanomastoid suture lines.<sup>7</sup> In contrast, exostoses appear as multiple broad-based, smooth, and elevated lesions, which arise from the tympanic portion of the temporal bone.<sup>3,7</sup> Histologically, osteomas have fibrovascular channels with surrounding lamellar bone and few osteocytes.<sup>4,5</sup> In contrast, exostoses appear as concentric and dense layers of parallel subperiosteal bone with many osteocytes and no fibrovascular channels.<sup>4,5</sup> Although histologically distinct, both lesions can present with hyperostotic growth adjacent to the IAC resulting in compression of

neurovascular structures. Bilateral presence of either of these lesions is exceedingly rare, with only 13 cases reported.<sup>1-7</sup> To better address the existing knowledge gap regarding IAC exostoses and osteomas, we review the relevant pathophysiology and treatment strategies.

## Pathophysiology

Osteomas are benign, well-differentiated overgrowths of cancellous bone composed of laminar sheets and Haversian canals.<sup>3,5</sup> They are generally classified into three subtypes based on location: central, peripheral, and extra-skeletal.<sup>3,5</sup> Central osteomas project from endosteal surfaces of the cortical bone.<sup>5</sup> Peripheral osteomas project from the periosteum, and extra-skeletal osteomas develop within muscle.<sup>3</sup> Although benign in nature, osteomas are considered true neoplasms of the bone. They constitute approximately 1% of all bone tumors, and 11% of benign lesions of the bone.<sup>1,9</sup> There are mixed reports regarding gender ratios, with some authors citing a higher incidence in women.<sup>3,10</sup>

The pathogenesis of osteomas is poorly understood and likely multifactorial. Trauma, inflammation, embryological errors, and hormonal dysregulation have all been implicated as possible contributors.<sup>1,3,11</sup> It's been proposed that trauma during puberty may lead to aberrant bone overgrowth giving rise to an osteoma.<sup>3</sup> Frequent ear infections with repeated and chronic inflammation, or abnormal ossification of cranial and skull base sutures during embryological development, have also been implicated.<sup>1</sup> Furthermore, hormonal dysregulation and subsequent effects on bone and suture development may act together to contribute to development of osteomas.<sup>3,12</sup> It is possible that hormonal mechanisms may explain a slight female preponderance, particularly in cases of bilateral osteomas. Moreover, since osteomas often arise near suture lines, it is possible that a combination of abnormal bone ossification and closure of sutures, due to hormonal influences, may promote the development of osteomas.<sup>3,12</sup>

Exostoses are also benign, slow growing, reactive bony overgrowth of the calvarium.<sup>9</sup> Exostoses can arise bilaterally from all surfaces of the temporal bone, and they often appear as smooth and continuous with surrounding cortical surfaces.<sup>6,13,14</sup>

Although the exact pathogenesis of IAC exostoses is unknown, there are links between chronic inflammation and formation of exostoses in other anatomical locations.<sup>15</sup> For example, exostoses are commonly found in the external auditory canal (EAC) of surfers and swimmers exposed to cold water, and those suffering from frequent ear infections.<sup>13-15</sup> Preclinical work on guinea pigs has hinted at a correlation between cold irrigation of the EAC and accelerated bone formation.<sup>13</sup> However, the underlying pathophysiology of cold exposure has not yet been elucidated and is unlikely to be the sole driver behind the formation of IAC exostoses.<sup>13</sup> Furthermore, there are other examples reported in the literature linking reactive periostitis of the arm to exostoses formation.<sup>10,16</sup> Similar to osteomas, the pathogenesis of IAC exostoses is also likely multifactorial, and linked to inflammatory triggers that lead to the formation of these

reactive lesions. The presence of bilateral lesions, however, may suggest a more diffuse process, such as an underlying bone remodeling abnormality similar to the abnormalities observed in hyperostosis cranialis interna (HCI), hyperostosis frontalis interna, fibrous dysplasia, or Paget's disease.<sup>6,17,18</sup> HCI is an especially intriguing candidate to explain bilateral calvarial and skull base hyperostosis that is isolated to the cranium. Patients with HCI present with significant thickening of the inner table of the frontal, parietal, occipital, and temporal bones. Moreover, HCI is a familial disorder with an autosomal dominant expression than can affect the IAC and lead to cranial neuropathies. Radiographically, the hyperostotic lesions of the IAC found in HCI resemble exostoses.<sup>17,18</sup> Thus, in patients with diffuse thickening of the inner table across the calvarium there is likely a genetic predisposition to IAC hyperostosis that is compounded by phenotypical factors, such as local inflammation, and aberrant suture closure.

### Clinical Presentation and Evaluation

Symptoms of IAC osteomas and exostoses result from compression of the neurovascular structures within the cerebellopontine angle and IAC. Compression of the vestibulocochlear nerve can cause vestibular and auditory symptoms, such as vertigo, ataxia, tinnitus, and hearing loss.<sup>11</sup> Compression of the facial nerve can lead to unilateral or bilateral facial weakness and hemifacial spasms. Facial nerve dysfunction appears to be less prevalent than vestibulocochlear nerve dysfunction (– **Table 1**), suggesting that the facial nerve is more resilient to compression.<sup>11</sup>

The differential diagnosis for IAC lesions arising from the bone includes osteomas, exostoses, osteopetrosis, HCI, hyperostosis frontalis interna, Paget's disease, and neoplastic lesions.<sup>5,17,18</sup> Osteopetrosis is a rare metabolic disease that results in the formation of thick and brittle bone caused by osteoclastic dysfunction.<sup>14,19</sup> Osteopetrosis can affect the skull, causing thickening of the cranial vault, stenosis of the skull base foramina, and stenosis of the IAC.<sup>14</sup> The diagnosis of osteopetrosis can be made based on radiographic evidence of parallel bands of dense bone giving a “bone within bone” appearance on CT.<sup>20</sup> HCI and hyperostosis frontalis interna are diseases caused by thickening of cancellous bone within

**Table 1** Presenting patient characteristics

	Exostoses	Osteoma
<b>Sex</b>	Total <i>n</i> = 7	Total <i>n</i> = 6
Male	7	4
Female	0	2
<b>Presenting symptoms</b>	Total <i>n</i> = 7	Total <i>n</i> = 6
Tinnitus	3	2
Vertigo	3	3
Hearing loss	3	3
Incidental finding	2	2

Note: data calculated using all previously reported cases in the literature.<sup>1–7</sup>

the inner table of the calvarium.<sup>17,18,21</sup> Patients with HCI and hyperostosis frontalis interna often present with intracranial hypertension, atrophy of the cerebrum due to compression, hypercalcemia, and abnormal electroencephalograms.<sup>17,22</sup> The pathogenesis of HCI was previously discussed; however, the etiology of hyperostosis frontalis interna is unknown, and this disease process has been associated with hormonal dysregulation including elderly postmenopausal women, obesity, and virilism.<sup>21,22</sup> The diagnosis of hyperostosis frontalis interna can be made by CT to visualize the thickening of the frontal bone, however, with HCI, it can also involve the parietal and temporal bones.<sup>23</sup> Paget's disease of the bone is characterized by overactive osteogenesis and bone remodeling, leading to replacement of normal bone with fibrovascular tissue.<sup>24</sup> Paget's disease can also affect the skull base and IAC, with reports of sensorineural hearing loss attributed to stenosis of the IAC.<sup>25</sup> Other attributes of Paget's disease include macrocephaly and concentric thickening of the cranial vault.<sup>14</sup>

CT is the imaging modality of choice to visualize and evaluate osteomas and exostoses of the IAC. On CT, both lesions appear as well demarcated and hyperdense bony outgrowths near or within the IAC. It is seldom possible to accurately differentiate between osteomas and exostoses purely based on imaging but there are general characteristics that can aid in differentiating between the two. Bilateral lesions with homogenous density are more likely to be exostoses, while osteomas are generally more heterogeneous.<sup>7</sup> Moreover, osteomas typically occur as solitary, and pedunculated lesions arising near the tympanosquamous or tympanomastoid suture lines.<sup>7</sup> Osteomas tend to grow on the medial aspect of the IAC in contrast to exostoses which can originate from all surfaces of the canal.<sup>6,13</sup> The presence of fat and bone marrow on MRI makes osteomas more likely than exostoses.<sup>1</sup>

Histological analysis can accurately differentiate these two lesions. Osteomas are benign, bosselated, ovoid, sessile tumors made of woven and lamellar bone with Haversian canals, and sometimes include trabecular bone that harbors hematopoietic marrow and fat.<sup>11</sup> Most lesions exhibit a combination of two growth patterns: compact, lamellar bone that grows in parallel layers, and rapidly growing spongy bone with wide medullary spaces that lack Haversian canals.<sup>1,11</sup> Exostoses, on the other hand, are composed of parallel concentric layers of subperiosteal bone that on hematoxylin and eosin staining have an “onion skin” appearance.<sup>6</sup> They have many osteocytes, few fibrovascular channels and no hematopoietic cells.<sup>6,15</sup> These lesions appear histologically continuous with their surroundings without any distinct differentiating cortical features.<sup>25</sup>

### Implications for Management

Treatment goals for IAC stenosis consist of decompression of the neural elements and preservation of neurologic function. Indications for surgical decompression depend on the location, symptomatology, and risk of potential complications of the surgical approach.<sup>27</sup> If a lesion is small and the patient is asymptomatic, conservative treatment

with routine surveillance imaging is a viable option given the benign nature of osteomas and exostoses.<sup>10</sup> Larger lesions causing progressive hearing deficits, vestibular dysfunction, tinnitus, refractory hemifacial spasm, facial weakness, or brainstem compression, however, may require urgent surgical decompression to prevent further neurological decline.<sup>3,5,6,10</sup>

The most common surgical approach for decompression is the retrosigmoid suboccipital corridor to the cerebello-pontine angle.<sup>3</sup> However, even in the setting of early surgical intervention, functional recovery can be slow.<sup>3</sup> Improvements in vertigo and tinnitus following decompression have been previously reported, whereas recovery of auditory function is not likely.<sup>3,5,6</sup> This observation is consistent with other compressive pathologies of the IAC, for example, retrosigmoid craniotomy for resection of a vestibular schwannoma greater than 15–20 mm has a hearing preservation rate of 5 to 52%.<sup>28–30</sup> The goals of surgical decompression for IAC stenosis; therefore, must be prevention of progressive loss of cranial nerve function, improvement/resolution of vertigo, and to maximize the potential for a successful cochlear implants.

## Conclusion

Osteomas and exostoses are benign bony lesions that can arise in the vicinity of the IAC and rarely occur bilaterally. It is often difficult to distinguish these lesions based on imaging alone, and histology is necessary. Both of these lesions can result in compression of the vestibulocochlear and facial nerves, leading to debilitating symptoms. For asymptomatic lesions without mass effect, medical management and conservative surveillance is recommended. In symptomatic cases, surgical decompression can alleviate vertigo symptoms but is unlikely to result in recovery of hearing loss. Careful patient selection and counseling is paramount when treating patients with IAC stenosis due to hyperostosis.

### Disclosures

The authors have no conflicts of interest concerning the materials used in this study or the findings specified in this paper.

### Conflict of Interest

None.

## References

- Vishwakarma R, Joseph ST, Patel KB, Sharma A. Giant frontal osteoma: case report with review of literature. *Indian J Otolaryngol Head Neck Surg* 2011;63(Suppl 1):122–126
- Brake MK, Morris DP, Trites J, Taylor SM, Van Wijhe RG, Hart RD. A case of bilateral internal auditory canal osteomas. *Ear Nose Throat J* 2014;93(01):E15–E18
- Schutt CA, Guo JN, Bagwell KA, Bulsara KR, Malhotra A, Michaelides E. Bilateral osteomas and exostoses of the internal auditory canal. *Am J Otolaryngol* 2015;36(04):583–586
- Estrem SA, Vessely MB, Oro JJ. Osteoma of the internal auditory canal. *Otolaryngol Head Neck Surg* 1993;108(03):293–297
- Gerganov VM, Samii A, Paterno V, Stan AC, Samii M. Bilateral osteomas arising from the internal auditory canal: case report. *Neurosurgery* 2008;62(02):E528–E529, discussion E529
- Baik FM, Nguyen L, Doherty JK, Harris JP, Mafee MF, Nguyen QT. Comparative case series of exostoses and osteomas of the internal auditory canal. *Ann Otol Rhinol Laryngol* 2011;120(04):255–260
- Ciorba A, Aimoni C, Bianchini C, Borrelli M, Calzolari F, Martini A. Bilateral osseous stenosis of the internal auditory canal: case report. *Acta Otorhinolaryngol Ital* 2011;31(03):177–180
- Goodarzi A, Ahmadpour A, Toussi A, Shahlaie K. A Multilayered Technique for Repair of the Suboccipital Retrosigmoid Craniotomy. *J Neurol Surg B Skull Base* 2018;79(05):508–514
- Jackler RK, Driscoll CL, Lieberman E. *Tumors of the Ear and Temporal Bone*. Philadelphia, PA: Lippincott Williams and Wilkins; 2000
- Baxter MC, Keller M, Shah A, Wise S. Surgical emphysema following canalplasty for aural exostoses. *Otol Neurotol* 2017;38(08):1174–1177
- Liétin B, Bascoul A, Gabrillargues J, et al. Osteoma of the internal auditory canal. *Eur Ann Otorhinolaryngol Head Neck Dis* 2010;127(01):15–19
- Yates JA, Patel PC, Millman B, Gibson WS. Isolated congenital internal auditory canal atresia with normal facial nerve function. *Int J Pediatr Otorhinolaryngol* 1997;41(01):1–8
- Graham MD. Osteomas and exostoses of the external auditory canal. A clinical, histopathologic and scanning electron microscopic study. *Ann Otol Rhinol Laryngol* 1979;88(4, Pt. 1):566–572
- Stella I, Vinchon M, Guerreschi P, De Berranger E, Bouacha I. Case update on cranial osteopetrosis: which is the role of the neurosurgeon? *Childs Nerv Syst* 2017;33(12):2181–2186
- Nager GT, Hyams VJ. *Pathology of the Ear and Temporal Bone*. Baltimore: Williams and Wilkins; 1993
- Mathew SE, Madhuri V, Alexander M, Walter NM, Gibkote SV. Florida reactive periostitis of the forearm bones in a child. *J Bone Joint Surg Br* 2011;93(03):418–420
- Waterval JJ, van Dongen TM, Stokroos RJ, De Bondt BJ, Chenault MN, Manni JJ. Imaging features and progression of hyperostosis cranialis interna. *AJNR Am J Neuroradiol* 2012;33(03):453–461
- Manni JJ, Scaf JJ, Huygen PL, Cruysberg JR, Verhagen WI. Hyperostosis cranialis interna. A new hereditary syndrome with cranial-nerve entrapment. *N Engl J Med* 1990;322(07):450–454
- Hamersma H. Osteopetrosis (Marble bone disease) of the temporal bone. *Laryngoscope* 1970;80(10):1518–1539
- Wu CC, Econs MJ, DiMeglio LA, et al. Diagnosis and management of osteopetrosis: consensus guidelines from the osteopetrosis working group. *J Clin Endocrinol Metab* 2017;102(09):3111–3123
- She R, Szakacs J. Hyperostosis frontalis interna: case report and review of literature. *Ann Clin Lab Sci* 2004;34(02):206–208
- Gegick CG, Danowski TS, Khurana RC, et al. Hyperostosis frontalis interna and hyperphosphatasemia. *Ann Intern Med* 1973;79(01):71–75
- Cetiner Batun G, Yuruyen M, Vatankulu B, Elmali AD, Emul M. Hyperostosis frontalis interna presenting as depression and parkinsonism in an older woman. *Psychogeriatrics* 2016;16(05):329–330
- Roodman GD, Windle JJ. Paget disease of bone. *J Clin Invest* 2005;115(02):200–208
- Applebaum EL, Clemis JD. Temporal bone histopathology of Paget's disease with sensorineural hearing loss and narrowing of the internal auditory canal. *Laryngoscope* 1977;87(10, Pt. 1):1753–1759
- Unlu E, Albayram S, Argimak Y, Cakir B. Bilateral exostoses of the internal auditory canal. *Neuroradiol J* 2005;18(01):87–89
- Yudoyono F, Sidabutar R, Dahlan RH, Gill AS, Ompusunggu SE, Arifin MZ. Surgical management of giant skull osteomas. *Asian J Neurosurg* 2017;12(03):408–411

- 28 Wanibuchi M, Fukushima T, McElveen JT Jr., Friedman AH. Hearing preservation in surgery for large vestibular schwannomas. *J Neurosurg* 2009;111(04):845-854
- 29 Jacob A, Robinson LL Jr., Bortman JS, Yu L, Dodson EE, Welling DB. Nerve of origin, tumor size, hearing preservation, and facial nerve outcomes in 359 vestibular schwannoma resections at a tertiary care academic center. *Laryngoscope* 2007;117(12):2087-2092
- 30 Wanibuchi M, Fukushima T, Friedman AH, et al. Hearing preservation surgery for vestibular schwannomas via the retrosigmoid transmeatal approach: surgical tips. *Neurosurg Rev* 2014;37(03):431-444