

UC Davis

Dermatology Online Journal

Title

Late onset nevus comedonicus of scalp: a rare site for an uncommon condition

Permalink

<https://escholarship.org/uc/item/6dv5s7dn>

Journal

Dermatology Online Journal, 25(3)

Authors

Mathachan, Sinu Rose
Arora, Pooja
Ahuja, Arvind
et al.

Publication Date

2019

DOI

10.5070/D3253043342

Copyright Information

Copyright 2019 by the author(s). This work is made available under the terms of a Creative Commons Attribution-NonCommercial-NoDerivatives License, available at <https://creativecommons.org/licenses/by-nc-nd/4.0/>

Peer reviewed

Late onset nevus comedonicus of scalp: a rare site for an uncommon condition

Sinu Rose Mathachan¹ MD, Pooja Arora¹ MD, Arvind Ahuja² MD, Ram Kishan Gautam¹ MD

Affiliations: ¹Department of Dermatology, Venereology and Leprosy, Dr. Ram Manohar Lohia and Post Graduate Institute of Medical Education and Research, New Delhi, India, ²Department of Pathology, Dr. Ram Manohar Lohia and Post Graduate Institute of Medical Education and Research, New Delhi, India

Corresponding Author: Sinu Rose Mathachan MD, Department of Dermatology, Venereology and Leprosy, Dr. Ram Manohar Lohia and Post Graduate Institute of Medical Education and Research, New Delhi, India, Email: sinurose@gmail.com

Abstract

Nevus comedonicus is an uncommon hamartoma of the pilosebaceous unit characterized by keratin filled pits simulating open comedones. It may present at birth but is more commonly seen during childhood or adolescence. The most commonly affected sites are the face, neck, trunk, and arms with a few reported cases on palms, genitalia, and scalp. We report a case of a 19-year old woman with nevus comedonicus of the scalp that appeared in adolescence. This case has been presented for its sheer rarity, atypical site, and classic appearance.

Keywords: nevus comedonicus, scalp, late onset

Introduction

Nevus comedonicus (NC) is rare developmental abnormality of the pilosebaceous unit. It is characterized by aggregates of dilated follicular orifices filled with keratin plugs giving the appearance of a group of open comedones. It appears sporadically and males and females are similarly affected. However, familial cases have also been reported [1]. It usually occurs in groups or may follow a linear pattern along the lines of Blaschko. Most common sites for NC are the face, neck, trunk, and proximal extremities. Rarely, lesions occurring on the palms, genitalia, and ear have been reported [2]. The scalp is a very unusual site for NC with only a few cases being reported. Herein, we report a case of NC on scalp of a 19-year old woman with its onset in adolescence.

Case Synopsis

A 19-year old woman presented to our outpatient department with a pruritic patch of alopecia over her scalp of two years duration. The plaque was initially small in size, but gradually increased to reach the present size. She noticed discrete hyperpigmented raised papules clustered on certain areas of the alopecic patch. There was no history of any discharge or suppuration from the lesions. No such lesions were present in any of the family members. Two years before the appearance of the plaque, the patient was hospitalized for treatment of congestive heart failure secondary to rheumatic heart disease and she underwent surgery for mitral valve repair. There was no other evidence of any skeletal, mental, or cutaneous abnormalities.

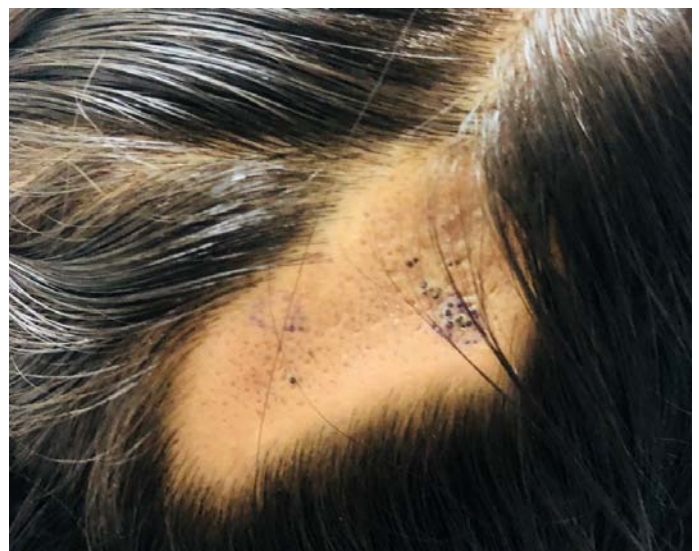

Figure 1. Multiple keratin filled pits on scalp.

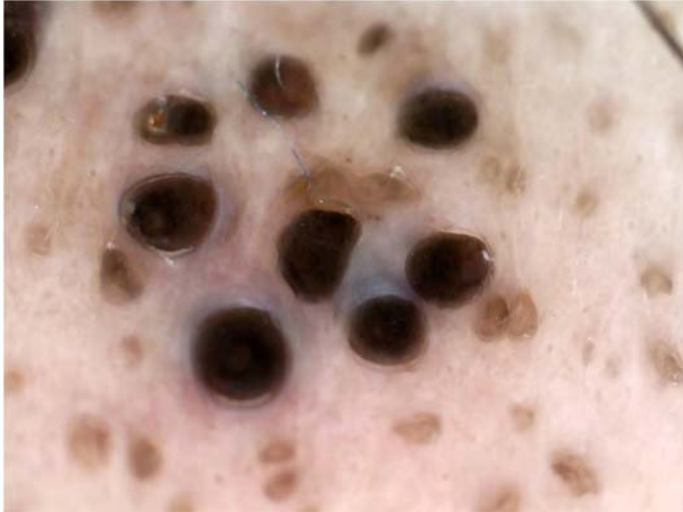

Figure 2. Dermoscopy of nevus comedonicus showing multiple circular and barrel shaped homogenous areas in brown and black shades with keratin plugs.

On examination a patch of alopecia of size 7×4cm was present over the right parietal region of the scalp. The plaque was studded with aggregated discrete pits filled keratinous material with intervening normal skin and in some regions the black plugs protruded above the surface and were firmly adherent to the scalp (**Figure 1**).

Routine hematological investigations along with neurological and ophthalmological examinations were within normal limits. Chest X-ray showed cardiomegaly and increased broncho-vascular markings. Dermoscopy showed keratinous plugs and vellus hair arising from the pilosebaceous units (**Figure 2**). Biopsies were taken from two different sites. The first biopsy taken from the site showing black plugs revealed hyperkeratosis with multiple

comedones lined by epidermis, filled with keratin, and opening to the surface (**Figure 3A**). A second biopsy taken from the smooth part of the plaque was also suggestive of nevus comedonicus (**Figure 3B**).

Case Discussion

Nevus comedonicus is a hamartoma of the pilosebaceous unit occurring as a result of a defect of the mesodermal component of the follicle with abnormal differentiation of the epithelial portion. It was first described by Kofmann in 1895 [3]. It is also known as comedone nevus, nevus follicularis keratosis, nevus zoniforme, and nevus acneiformis unilateralis. The affected follicles produce soft keratin and are unable to form mature hairs, matrix cells, or sebaceous glands. Rarely, vellus hair may arise from follicles. Nevus comedonicus syndrome occurs when NC are associated with other non-cutaneous findings such as cerebral, skeletal, or ocular abnormalities [1]. The main conditions in the differential diagnosis of NC of the scalp includes folliculitis decalvans and nevus sebaceus, which can be ruled out by clinical and histopathological examination. Therapy for NC is advisable for aesthetic reasons or for the treatment of superinfections. Topical treatment with retinoids, 12% ammonium lactate, tacalcitol, tazarotene, and calcipotriene are found to be variably effective [4]. Topical and systemic antibiotics are given for the treatment of secondary infections [5]. Surgical excision with tissue expansion may be performed for disfiguring and cystic lesions [4]. We chose to treat our patient with topical tazarotene.

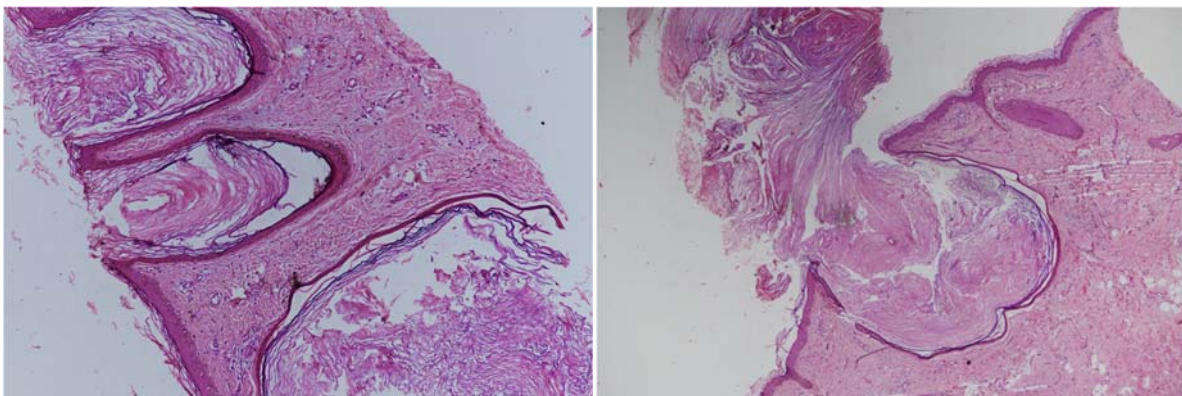


Figure 3. A) Histologic presentation showing comedo-like communication with surface and lamellated keratin with in the cystic cavity (first biopsy). H&E, 10x. **B)** Histologic presentation showing comedo-containing lamellated keratin with in the cystic cavity (second biopsy). H&E, 10x.

Nevus comedonicus most commonly occurs over face, trunk, and proximal extremities, especially the upper arm. A few cases have been reported with the unusual occurrence of NC over the palms, genitalia, and ear [2]. Our patient had a history of rheumatic heart disease. Cripps and Bertram have also reported a similar case in a 44-year old woman who had bilateral NC along with a history of congestive heart failure secondary to rheumatic heart disease [6]. Further research and evaluation is required to investigate whether this association is a coincidence, or not. Scalp involvement in NC is rare with only a few cases being reported. All the cases that have been

reported on NC over the scalp had their onset since birth and no other systemic associations were seen in any of these [4, 5, 7-9], (**Table 1**).

Conclusion

In conclusion, our case highlights a patient with an unusual site of this developmental abnormality that had a later onset compared to prior cases reported.

Potential conflicts of interest

The authors declare no conflicts of interests.

References

1. Cestari TF, Rubim M, Valentini BC. Nevus comedonicus: case report and brief review of the literature. *Pediatr Dermatol*. 1991;8(4):300-5. [PMID: 1792203].
2. Lefkowitz A, Schwartz RA, Lambert WC. Nevus comedonicus. *Dermatology*. 1999;199(3):204-7. [PMID: 10592398].
3. Kofmann South A case of rare localization and spreading of Comedones. *Arch Dermatol Syphilol*. 1895;32:177-8. [DOI: [10.2336/nishinohifu.70.410](https://doi.org/10.2336/nishinohifu.70.410)].
4. Kikkeri NN, Priyanka R, Parshawanath H. Nevus comedonicus on scalp: a rare site. *Indian J Dermatol*. 2015;60(1):105. [PMID: 25657429].
5. Sahu P, Aggrawal K, Bansal C, Jain VK. Nevus comedonicus on scalp: An unusual presentation. *Int J Trichology*. 2018;10(1):37. [PMID: 29440859].
6. Cripps DJ, Bertram JR. Nevus comedonicus bilateralis et verruciformis. *J Cutan Pathol*. 1976;3(6):273-81. [DOI: [10.1111/j.1600-0560.1976.tb00876.x](https://doi.org/10.1111/j.1600-0560.1976.tb00876.x)].
7. Sikorski D, Parker J, Shwayder T. A boy with an unusual scalp birthmark. *Int J Dermatol*. 2011;50(6):670-2. [PMID: 21595659].
8. Ghaninezhad H, Ehsani AH, Mansoori P, Taheri A. Naevus comedonicus of the scalp. *J Eur Acad Dermatol Venereol*. 2006;20(2):184-5. [PMID: 16441628].
9. Kaliyadan, F., Nambiar, A., Al, A.A. and Amri, M., 2014. Nevus comedonicus of the scalp. *Skinmed*, 12(1), pp.59-60. [PMID: 24720088].