

UC Davis

UC Davis Previously Published Works

Title

Resection of a thoracoabdominal ganglioneuroma via a retroperitoneal minimally invasive approach

Permalink

<https://escholarship.org/uc/item/6dq3g7ns>

Authors

Galganski, Laura A

Hirose, Shinjiro

Saadai, Payam

Publication Date

2019

DOI

10.1016/j.epsc.2018.10.012

Copyright Information

This work is made available under the terms of a Creative Commons Attribution-NonCommercial-NoDerivatives License, available at <https://creativecommons.org/licenses/by-nc-nd/4.0/>

Peer reviewed



Published in final edited form as:

J Pediatr Surg Case Rep. 2019 January ; 40: 47–49. doi:10.1016/j.epsc.2018.10.012.

Resection of a thoracoabdominal ganglioneuroma via a retroperitoneal minimally invasive approach

Laura A. Galganski*, Shinjiro Hirose, Payam Saadai

University of California – Davis, Division of Pediatric General, Thoracic and Fetal Surgery, USA

Abstract

A 10-year-old girl presented to her pediatrician with a history of cough and fever. A chest radiograph revealed a paraspinal mass. On cross-sectional imaging, the mass traversed the diaphragm, extending from T9 to L1 spinal levels with involvement of the T10–12 neural foramen. Vanillylmandelic and homovanillic acid levels were normal. On review of historical radiographs, the mass had increased in size. Thus, surgical resection was recommended for diagnosis and treatment.

The patient was placed in left lateral decubitus position. The retroperitoneal space was accessed inferior to the twelfth rib. One 12 mm and two 5 mm ports were used. Development of the retroperitoneal space was achieved with both blunt dissection and a vessel-sealing device. The diaphragm was incised to resect the thoracic component of the mass. The tumor was adherent at the neural foramen and was resected flush with the spine. The diaphragm repaired primarily. She was discharged home on post-operative day four without complication. Pathology demonstrated a ganglioneuroma. The patient was well at her follow-up, and imaging one year postoperatively was without recurrence. No additional treatment was required.

A laparoscopic retroperitoneal approach allows for a safe, minimally invasive resection of a thoracoabdominal mass without violation of the abdominal cavity.

Keywords

Pediatric laparoscopic; Retroperitoneoscopic; Ganglioneuroma; Ganglioneuroblastoma; Neuroblastoma; Thoracoabdominal resection

This is an open access article under the CC BY-NC-ND license (<http://creativecommons.org/licenses/by-nc-nd/4.0/>).

*Corresponding author. University of California – Davis, Division of Pediatric General, Thoracic and Fetal Surgery, 2425 Stockton Blvd., Room 517, Sacramento, CA 95817, USA. lgalganski@ucdavis.edu (L.A. Galganski).

Authorship

All authors attest that they meet the current ICMJE criteria for Authorship.

Presented at the 51st meeting of Pacific Association of Pediatric Surgeons May 2018 in Sapporo, Japan.

Patient consent

Consent was obtained from the parent of the patient.

Conflicts of interest

The following authors have no financial disclosures: LG, PS, SH.

Thoracoabdominal masses present a challenge for minimally invasive resections due to their involvement of two body cavities. We present a case of a thoracoabdominal ganglioneuroma resected via a retroperitoneoscopic approach and describe the benefits of the approach.

1. Case report

A 10-year-old girl presented to her pediatrician with a five-day history of cough and fever. A chest radiograph revealed an incidental paraspinal mass. On cross-sectional imaging, the mass traversed the diaphragm and extended from T9 to L1 spinal levels with involvement of the T10–12 neural foramen (Fig. 1).

The caudal aspect of the mass was at the level of the renal arteries and the mass was directly posterior to the inferior vena cava. The differential diagnosis included a benign ganglioneuroma, intermediate ganglioneuroblastoma and malignant neuroblastoma. She was referred to pediatric surgery and oncology. Vanillylmandelic and homovanillic acid levels were normal. On review of historical radiographs, the mass had increased in size (Fig. 2).

Given the growth, surgical resection was recommended for diagnosis and treatment.

The patient was placed in left lateral decubitus position. The retroperitoneal space was accessed inferior to the distal aspect of the twelfth rib. One 12 mm and two 5 mm ports were used (Fig. 3).

Development of the retroperitoneal space was achieved with a combination of blunt dissection and occasional use of a vessel-sealing device. The diaphragm was incised allowing for resection of the thoracic component of the mass. The tumor was adherent at the neural foramen and it was resected flush with the spine (Video 1). The diaphragm was primarily repaired and a chest drain was placed. She was discharged home on post-operative day four without complication. Pathology demonstrated a ganglioneuroma. The patient was well at her follow-up, and imaging one year post-operatively was without recurrence. No additional treatment was required for the ganglioneuroma.

Supplementary video related to this article can be found at <https://doi.org/10.1016/j.epsc.2018.10.012>.

2. Discussion

Thoracoabdominal masses represent a challenging entity for minimally invasive resection due to the involvement of two body cavities. We present a case of a benign thoracoabdominal ganglioneuroma resected via a retroperitoneoscopic approach, which allowed resection of the abdominal and thoracic components of the mass en bloc.

Ganglioneuromas of the retroperitoneum have been successfully resected via a laparoscopic transperitoneal approach [1]. However, the retroperitoneoscopic approach has been previously only reported in adrenal ganglioneuromas in adults and children [2,3]. This is the first report of resection of a thoracoabdominal ganglioneuroma.

The retroperitoneoscopic approach has largely been applied to adrenal and urologic pathologies in the pediatric setting. For retroperitoneal structures, this approach allows excellent exposure while avoiding key intraabdominal structures including the liver, intestine, kidney and their associated vasculature, which would be encountered in a laparoscopic approach [4]. The retroperitoneoscopic approach avoids entry in the peritoneum and has the traditional advantages of minimally invasive modalities that improve patient recovery. For example, in a series of pediatric nephrectomies, the retroperitoneoscopic approach was associated with decreased analgesia and hospitalization without a significant increase in operative time compared to open surgery [5].

One concern with a retroperitoneal exposure is perceived difficulty in access if hemorrhage is encountered. Our patient was positioned in left lateral decubitus position rather than prone position to allow for rapid repositioning if necessary for hemorrhage control. We suggest that the superior exposure via retroperitoneal exposure presents a low risk of hemorrhage in trained hands.

3. Conclusion

A laparoscopic retroperitoneal approach allows for a safe, minimally invasive resection of a thoracoabdominal mass without violation of the abdominal cavity.

Supplementary Material

Refer to Web version on PubMed Central for supplementary material.

Funding

Author LG was supported by the National Center for Advancing Translational Sciences, National Institutes of Health, through grant number UL1 TR001860. The content is solely the responsibility of the authors and does not necessarily represent the official views of the NIH.

References

- [1]. Yamaguchi K, Hara I, Takeda M, et al. Two cases of ganglioneuroma. *Urology* 2006;67(3):622.e621–624.
- [2]. Ahn KS, Han HS, Yoon YS, et al. Laparoscopic resection of nonadrenal retroperitoneal tumors. *Arch Surg (Chicago, Ill 1960)* 2011;146(2):162–7.
- [3]. Zhang S, Cao Q, Li P, et al. A modified retroperitoneoscopic technique in supine position for primary retroperitoneal tumors: technique and clinical outcomes. *J Endourol* 2016;30(7):799–804. [PubMed: 27065301]
- [4]. Cerulo M, Escolino M, Turra F, Roberti A, Farina A, Esposito C. Benefits of retroperitoneoscopic surgery in pediatric urology. *Curr Urol Rep* 2018;19(5):33. [PubMed: 29616411]
- [5]. Lee RS, Retik AB, Borer JG, Diamond DA, Peters CA. Pediatric retroperitoneal laparoscopic partial nephrectomy: comparison with an age matched cohort of open surgery. *J Urol* 2005;174(2):708–11. discussion 712. [PubMed: 16006955]

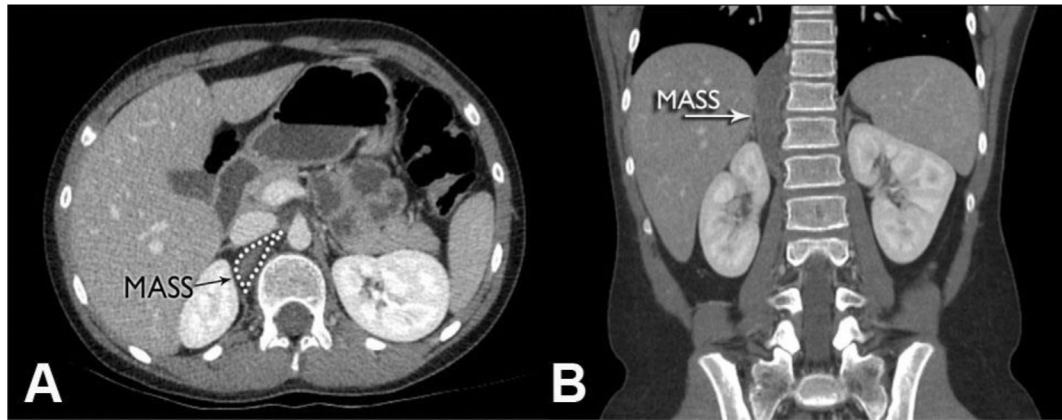


Fig. 1. Computed tomography of thoracoabdominal mass.

The caudal aspect of the mass (labeled) was at the level of the renal arteries and the mass was directly posterior to the inferior vena cava (Fig. 1A). The mass extended from T9 to L1 with involvement of the T10–12 neural foramen (Fig. 1B).

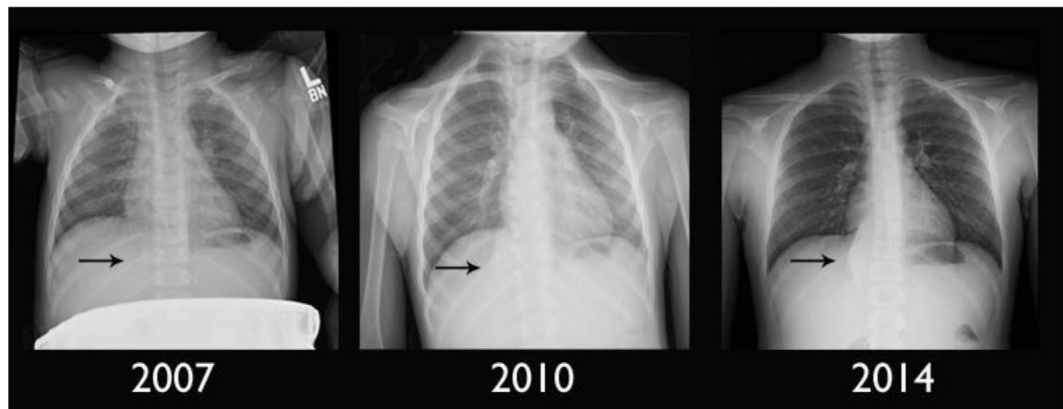


Fig. 2. Enlargement of mass on historical chest radiographs.

The mass (black arrows) had progressively increased in size on historical radiographs.

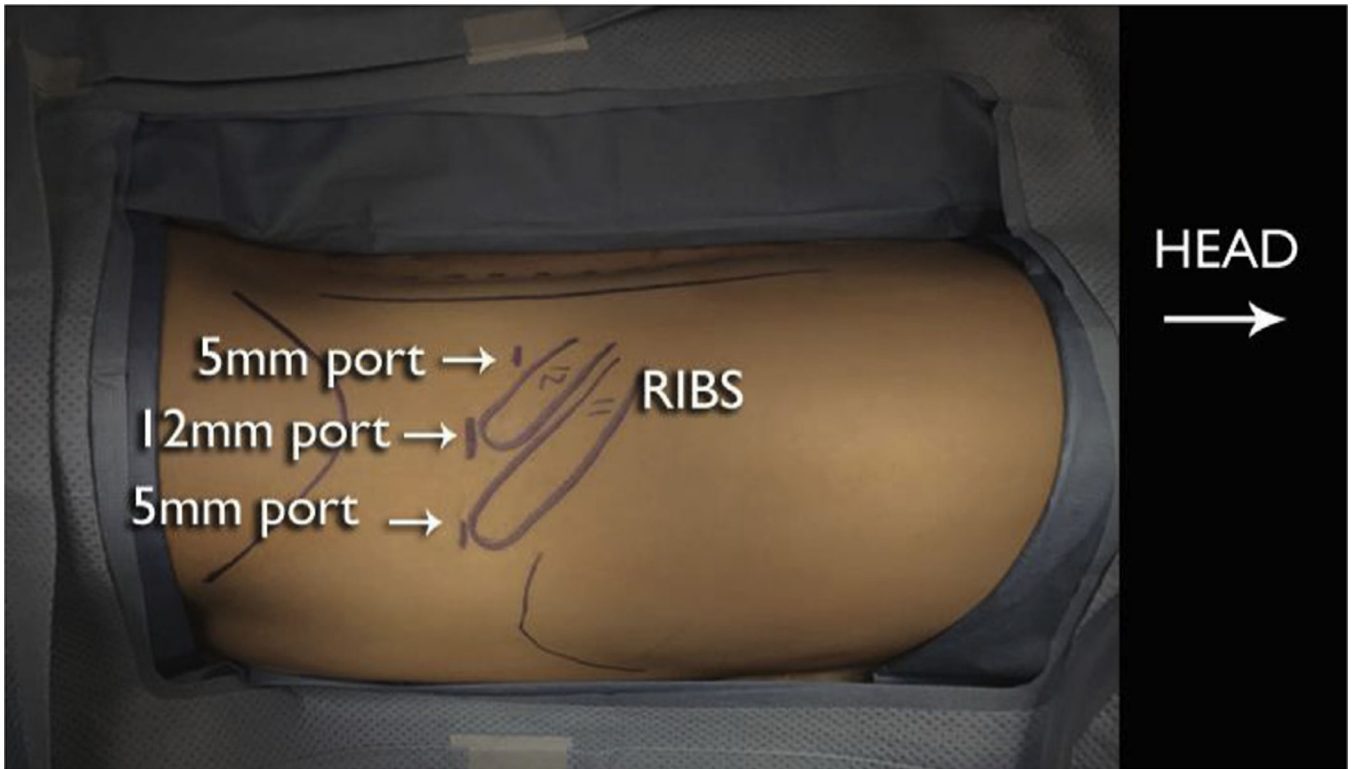


Fig. 3. Positioning and port placement.

The patient was placed in left lateral decubitus position. A 12 mm port was placed under direct visualization distal to the 12th rib and two additional 5 mm ports were used.