

UC Davis

Dermatology Online Journal

Title

Rapid response of tattoo-associated cutaneous sarcoidosis to minocycline: case report and review of the literature

Permalink

<https://escholarship.org/uc/item/6dd1m2j9>

Journal

Dermatology Online Journal, 20(8)

Authors

Sheu, Johanna
Saavedra, Arturo P
Mostaghimi, Arash

Publication Date

2014

DOI

10.5070/D3208023529

Copyright Information

Copyright 2014 by the author(s). This work is made available under the terms of a Creative Commons Attribution-NonCommercial-NoDerivatives License, available at <https://creativecommons.org/licenses/by-nc-nd/4.0/>

Peer reviewed

Case Presentation

Rapid response of tattoo-associated cutaneous sarcoidosis to minocycline: case report and review of the literature

Johanna Sheu MS¹, Arturo P. Saavedra MD PhD MBA², Arash Mostaghimi MD MPA³

Dermatology Online Journal 20 (8): 6

¹Harvard Medical School, Boston MA USA

²Department of Dermatology, Massachusetts General Hospital and Harvard Medical School, Boston MA USA

³Department of Dermatology, Brigham and Women's Hospital and Harvard Medical School, Boston MA USA

Correspondence:

Arash Mostaghimi, MD, MPA
Department of Dermatology
Brigham and Women's Hospital and Harvard Medical School
15 Francis Street, PBB-B 421
Boston, MA 02115
Phone number: (617) 732-5889
Fax number: (617) 525-3177
Email: AMOSTAGHIMI@partners.org

Abstract

Importance: Cutaneous sarcoidosis can present in pre-existing tattoos. Previous reports suggest modest improvement with systemic or topical corticosteroids or other immunomodulating medications. Tetracyclines have anti-inflammatory properties and have been shown to be efficacious in non-tattoo associated cutaneous sarcoidosis. The pharmacology of minocycline suggests that its higher concentration in the skin may improve its efficacy in the treatment of cutaneous granulomas.

Case Report: We present a case of a 35-year-old man with a history of pulmonary sarcoidosis who developed raised plaques within tattoos present for over 10 years. Skin biopsy findings revealed non-caseating granulomas consistent with cutaneous sarcoidosis. The patient was started on minocycline 100mg twice daily and had resolution of pruritus in four days and improvement of sarcoidal plaques within one week.

Conclusions: To our knowledge, this is the first report of cutaneous sarcoidosis in tattoos treated with minocycline. Our patient's rapid response to minocycline suggests that minocycline may be a quickly effective medication for cutaneous sarcoidosis and should be considered as a therapeutic option given its favorable side-effect profile.

Keywords: Cutaneous sarcoid, sarcoidosis, tetracyclines, minocycline, tattoo

Introduction

Sarcoidosis is an inflammatory disease of unknown etiology characterized by the development of non-caseating granulomas; the skin is involved in 10-30% of cases [1]. Cutaneous sarcoidosis is thought to result from immune system dysregulation, possibly triggered by antigens causing a Th1 response with granuloma formation. Cutaneous sarcoidosis has a predilection towards sites of previous trauma such as scars, injection sites, and tattoos. Tattoo sarcoidosis is thought to arise from foreign pigment or pigment by-products that serve as targets for inflammation. Treatment for tattoo-associated sarcoidosis has varied widely with mixed results [1,2]. Recent reports suggest that tetracyclines may be a promising therapy for cutaneous sarcoidosis. We report a case of rapid resolution of cutaneous sarcoidosis presenting in tattoos after treatment with minocycline.

Case synopsis

A 35-year-old man with a history of sarcoidosis presented with a several week history of pruritic lesions within tattoos on his arms and chest. These tattoos had been obtained professionally over a two-year period, 10-12 years ago.

Eleven months prior to presentation, a chest x-ray performed for the evaluation of cough identified hilar lymphadenopathy. A subsequent bronchoscopy demonstrated non-necrotizing granulomatous inflammation consistent with sarcoidosis. Pulmonary function tests demonstrated forced vital capacity within normal limits and forced expiratory volume in 1 second mildly decreased at 2.52L (72% of predicted value, 3.51L). His cough resolved after two 6-day courses of prednisone. At the time of presentation to dermatology he did not have any other signs or symptoms of sarcoidosis and was not on any active treatment for his disease. His past medical history was positive for asthma. He did not have a family history of sarcoidosis.

On physical exam, the patient had extensive tattoos of the bilateral upper extremities, shoulders, and upper chest. Hard, infiltrated papules coalescing into plaques were scattered throughout tattooed areas (Figure 1). No scale or skin ulceration was noted. Laboratory examinations including a complete blood cell count and full chemistry panel were within normal limits.

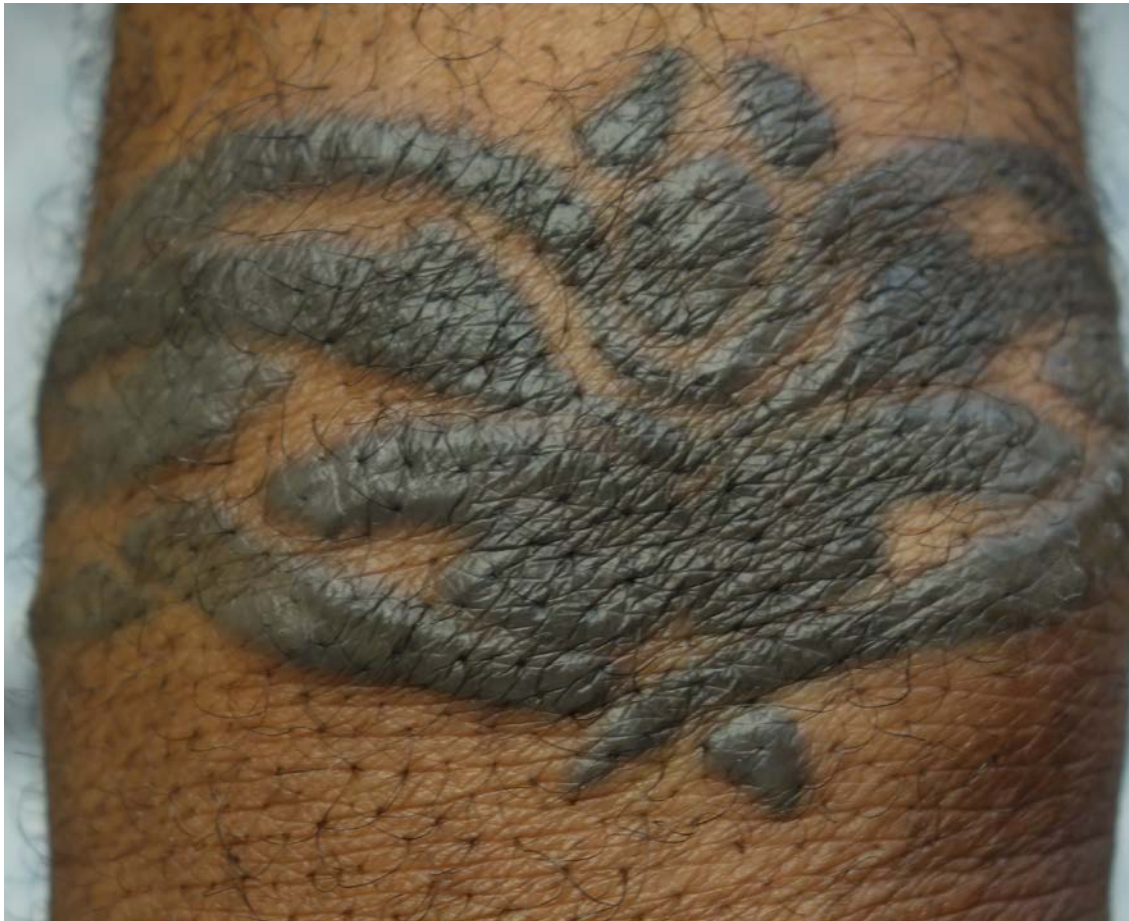



Figure 1A and 1B. Cutaneous sarcoidosis in tattoos, before minocycline therapy 1A) Area on the right wrist with a geometric plaque in the shape of a previous tattoo site 2A) Area on the right upper arm with numerous papules beginning to coalesce into plaques within a previous tattoo site

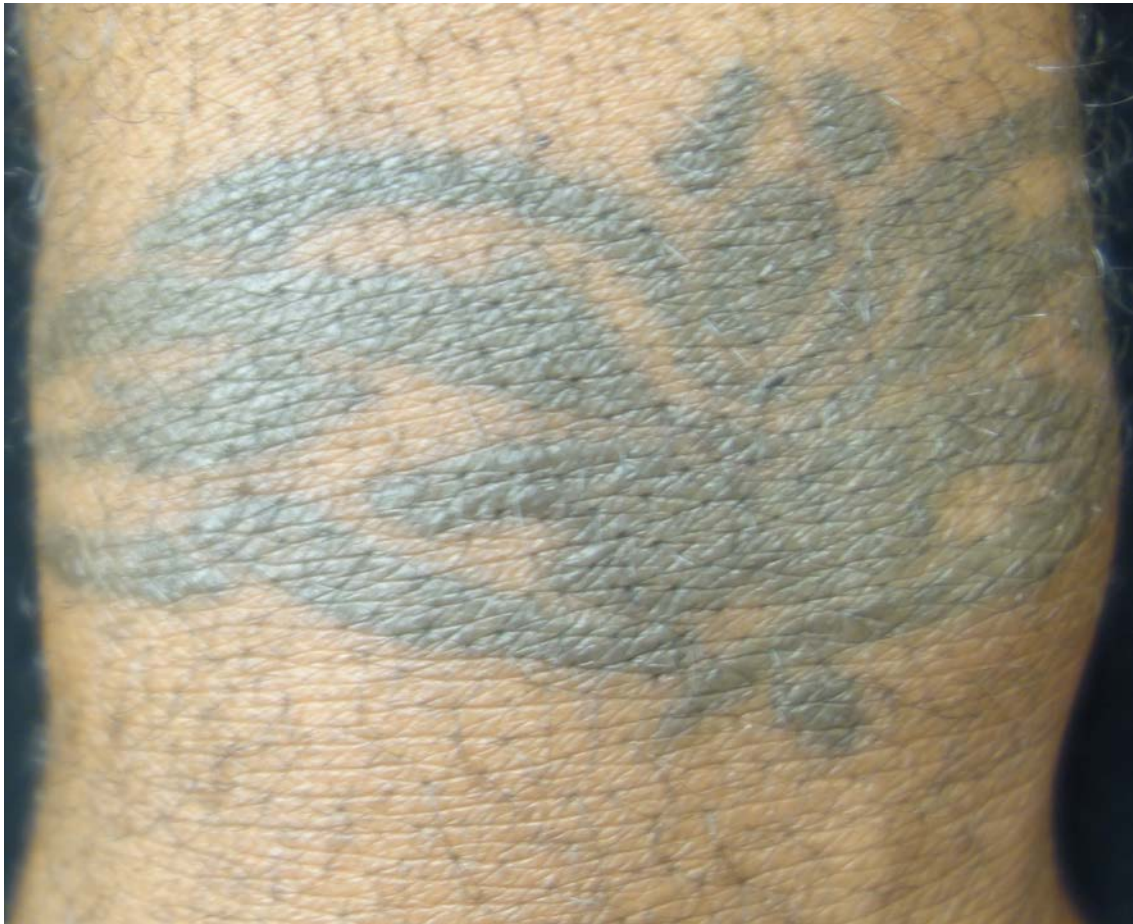

Figure 2. Cutaneous sarcoidosis in tattoos, after minocycline therapy: Complete resolution of right wrist lesion and flattening of tattooed area, 11 weeks after minocycline treatment and 9 weeks after hydroxychloroxine addition is observed.

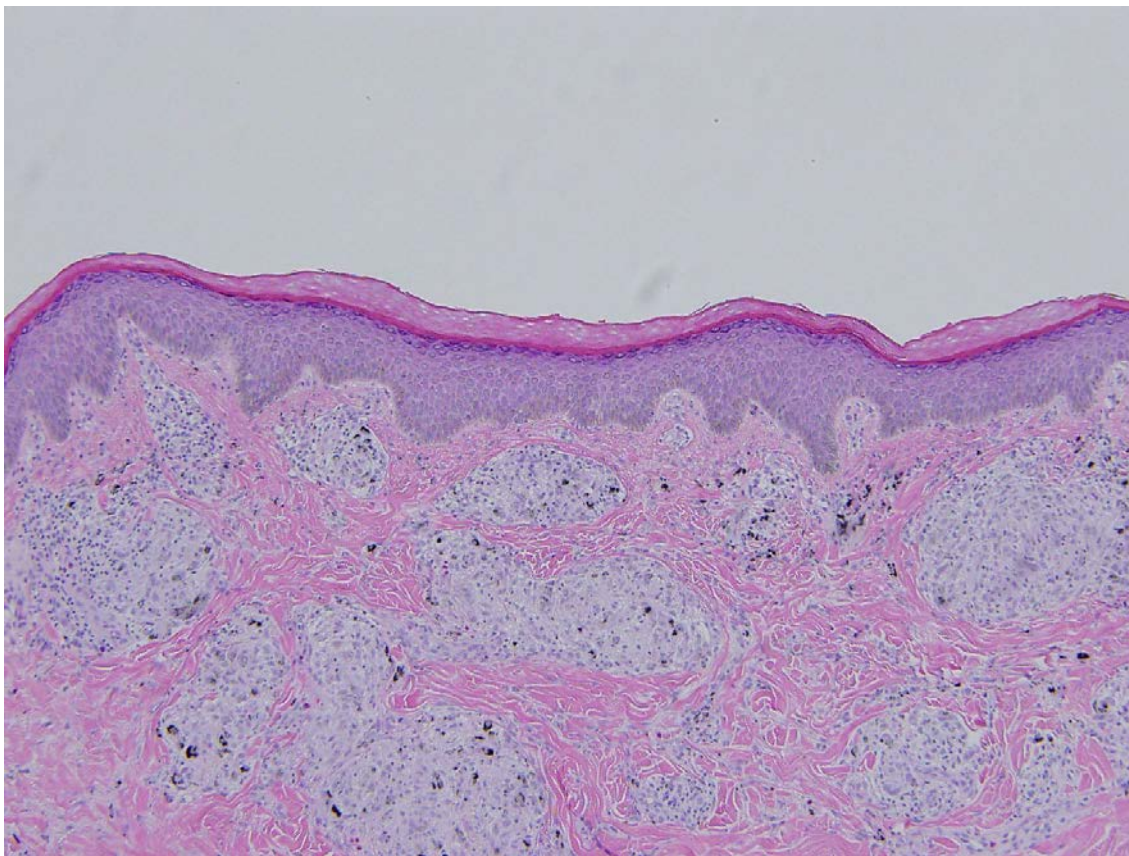


Figure 3. Skin biopsy specimen from right wrist lesion before minocycline therapy: Histopathologic findings demonstrate non-caseating granulomas with pigment granules and a mild interstitial lymphocytic infiltrate (Hematoxylin-Eosin, original magnification x 10).

The patient was given a clinical diagnosis of cutaneous sarcoidosis and was treated with topical clobetasol propionate in addition to hydroxyzine and cetirizine for pruritus. After one month, the patient did not experience any improvement of symptoms and continued to develop additional areas of involvement within his tattoos. A biopsy of a plaque within a tattoo on the ventral right wrist revealed non-caseating granulomas present throughout the dermis consistent with a diagnosis of cutaneous sarcoidosis (Figure 3). Topical steroids and oral antihistamines were discontinued and minocycline 100mg twice daily was initiated.

The patient's pruritus resolved after four days and his skin lesions began to recede after one week of treatment. In follow-up, two weeks after minocycline initiation, the patient had a dramatic reduction of skin lesions. At this visit, the patient was also started on hydroxychloroquine 200mg twice daily. After 11 weeks of minocycline and 9 weeks of hydroxychloroquine treatment, the majority of the patient's tattoos returned to their original appearance without scarring (Figure 2).

Discussion

The development of tattoo-associated sarcoidosis has been previously described in over 60 cases. Patients of all ages, tattoo type and color, and tattoo body location have been affected. The age of the affected tattoo prior to complication has ranged from 6 months to 45 years. Treatment has included surgical excision, systemic steroids, topical steroids, intralesional steroids, antimalarials, and doxycycline, with mixed results [2]. Currently, treatment for cutaneous sarcoidosis is similar to the above treatments and includes systemic and topical steroids, immunomodulating drugs, and recently, tetracyclines [3].

Tetracyclines have anti-inflammatory properties, which may explain their utility in the treatment of cutaneous sarcoidosis. Both doxycycline and minocycline have been shown to inhibit granuloma formation and suppress both neutrophilic chemotaxis and inflammatory reactions [4,5]. Specifically, minocycline has been shown to decrease T cell activation and T cell production of cytokines such as interferon gamma and tumor necrosis factor-alpha (TNF- α) [6]. TNF- α , likely through inhibition of protein kinase C, is important in both granuloma formation and maintenance, a key characteristic of sarcoidosis [7]. Minocycline has also been shown to decrease levels of IP-10 and IL-12p40, molecules produced by granuloma macrophages whose serum levels may reflect sarcoidosis disease activity [8].

Minocycline has not been reported for use in cutaneous sarcoidosis in tattoos. However, minocycline is at least twice more lipid-soluble than doxycycline and ten times more lipid-soluble than tetracycline. Minocycline also has an extended half-life as

compared to tetracycline, enabling sustained blood levels of the drug that result in improved tissue penetration and higher concentrations in the skin. [9,10].

Bachelez et al. reported that 10 of 12 patients had a clinical response of cutaneous sarcoidosis to minocycline treatment [11]. In addition, the efficacy of minocycline for cutaneous sarcoidosis was demonstrated in a retrospective review of 27 patients, in which 22% of patients experienced complete remission and 52% experienced partial remission of their skin lesions [12].

In the Bachelez series, 7 of 10 patients who improved with minocycline responded within one month of treatment; in all 10 patients with response to minocycline, the median time to reach maximal response of cutaneous lesions of 3 months (range 1-6 months) [11]. These cases, in addition to this report of symptom relief and flattening of lesions within one week, suggest that minocycline may be rapidly effective in treating cutaneous sarcoidosis in contrast to the 3-4 months of doxycycline and topical steroid treatment required for improvement in prior case reports [13,14].

Given the favorable side-effect profile of the tetracyclines, their use for cutaneous sarcoidosis is increasing and may represent a safer treatment option. Of the tetracyclines, minocycline is thought to be the most efficacious for treating the skin given increased skin concentrations when compared with tetracycline and doxycycline, which may explain its rapid effects on cutaneous sarcoidosis. Further studies are needed to determine which patients may benefit the most from minocycline treatment. We suggest that minocycline may be a rapidly efficacious alternative for treatment of cutaneous sarcoidosis in tattoos.

References

1. Selim A, Ehram E, Atassi MB, Khachemoune A. Scar sarcoidosis: a case report and brief review. *Cutis*. Dec 2006;78(6):418-422. [PMID: 17243430]
2. Kluger N. Sarcoidosis on tattoos: a review of the literature from 1939 to 2011. *Sarcoidosis Vasc Diffuse Lung Dis*. Jul 2013;30(2):86-102. [PMID: 24071880]
3. Badgwell C, Rosen T. Cutaneous sarcoidosis therapy updated. *J Am Acad Dermatol*. Jan 2007;56(1):69-83. [PMID: 17190623]
4. Sapadin AN, Fleischmajer R. Tetracyclines: nonantibiotic properties and their clinical implications. *J Am Acad Dermatol*. Feb 2006;54(2):258-265. [PMID: 16443056]
5. Webster GF, Toso SM, Hegemann L. Inhibition of a model of in vitro granuloma formation by tetracyclines and ciprofloxacin. Involvement of protein kinase C. *Arch Dermatol*. Jun 1994;130(6):748-752. [PMID: 8002645]
6. Kloppenburg M, Brinkman BM, de Rooij-Dijk HH, et al. The tetracycline derivative minocycline differentially affects cytokine production by monocytes and T lymphocytes. *Antimicrob Agents Chemother*. Apr 1996;40(4):934-940. [PMID: 8849255]
7. Monk E, Shalita A, Siegel DM. Clinical applications of non-antimicrobial tetracyclines in dermatology. *Pharmacol Res*. Feb 2011;63(2):130-145. [PMID: 20937386]
8. Miyazaki E, Ando M, Fukami T, Nureki S, Eishi Y, Kumamoto T. Minocycline for the treatment of sarcoidosis: is the mechanism of action immunomodulating or antimicrobial effect? *Clin Rheumatol*. Sep 2008;27(9):1195-1197. [PMID: 18458989]
9. Garner SE, Eady EA, Popescu C, Newton J, Li WA. Minocycline for acne vulgaris: efficacy and safety. *The Cochrane database of systematic reviews*. 2003(1):CD002086. [PMID: 12535427]
10. Cunha BA. New uses for older antibiotics. The 'rediscovery' of four beneficial and cost-effective antimicrobials. *Postgraduate medicine*. Apr 1997;101(4):68-70, 73-64, 79-80 passim. [PMID: 9126205]
11. Bachelez H, Senet P, Cadranet J, Kaoukhov A, Dubertret L. The use of tetracyclines for the treatment of sarcoidosis. *Arch Dermatol*. Jan 2001;137(1):69-73. [PMID: 11176663]
12. Steen T, English JC. Oral minocycline in treatment of cutaneous sarcoidosis. *JAMA Dermatol*. Jun 2013;149(6):758-760. [PMID: 23783160]
13. Tournalaki A, Boneschi V, Tosi D, Pigatto P, Brambilla L. Granulomatous tattoo reaction induced by intense pulse light treatment. *Photodermatol Photoimmunol Photomed*. Oct 2010;26(5):275-276. [PMID: 21175859]
14. Antonovich DD, Callen JP. Development of sarcoidosis in cosmetic tattoos. *Arch Dermatol*. Jul 2005;141(7):869-872. [PMID: 16027303]