

UCSF

UC San Francisco Previously Published Works

Title

Spermatic cord torsion: diagnostic limitations.

Permalink

<https://escholarship.org/uc/item/6bg0w2c7>

Journal

Pediatrics, 76(6)

ISSN

0031-4005

Authors

Stoller, Marshall L

Kogan, Barry A

Hricak, Hedvig

Publication Date

1985-12-01

DOI

10.1542/peds.76.6.929

Peer reviewed

Spermatic Cord Torsion: Diagnostic Limitations

Marshall L. Stoller, MD, Barry A. Kogan, MD, and Hedvig Hricak, MD

From the Departments of Urology, Pediatrics, and Radiology, University of California School of Medicine, San Francisco

ABSTRACT. To distinguish spermatic cord torsion from other intrascrotal pathology, scrotal ultrasound and radionuclide scanning have been highly recommended on the basis of both clinical and experimental studies. We review the data from six patients in whom ultrasound or nuclear medicine examination was misleading. We emphasize that history, physical examination, and urinalysis remain the cornerstones of the diagnosis of spermatic cord torsion. Scrotal ultrasound and nuclear medicine scans are useful adjuncts and are reassuring when in agreement with the clinical picture. However, they are not 100% sensitive or specific, and a negative study should not prevent emergency operative exploration of a clinically suspicious lesion. *Pediatrics* 1985;76:929-933; spermatic cord torsion, testicular torsion, scrotal ultrasound, scrotal radionuclide scanning.

The child with acute scrotal pain presents an urgent diagnostic dilemma. The differential diagnosis is extensive but, most importantly, spermatic cord torsion must be ruled out. Rapid assessment is essential because, experimentally, spermatogenic injury occurs within six hours of an ischemic injury and Leydig cell damage occurs within ten hours.¹ Clinically, the duration of torsion and subsequent atrophy are directly related.² Prompt evaluation is mandatory in all patients. However, in many instances the decision to intervene surgically may be difficult. Such trying clinical situations have prompted attempts to use recent technologic advances in sonographic imaging and nuclear scanning to distinguish those patients who require emergency surgical intervention from those best treated nonoperatively. Although the enthusiasm for these studies has been considerable, we have seen six patients during the past year in whom

ultrasound and/or nuclear medicine examinations were misleading.

CASE REPORTS

Case 1

A 16-year-old boy presented with acute scrotal pain. He specifically denied prior pain, associated changes in urinary habits, or recent trauma. Physical examination revealed a normal right testicle and epididymis. The left testicle felt enlarged but not tender; the epididymis was enlarged and posterior in position with tenderness superiorly. Abdominal examination was unremarkable, and urinalysis findings were normal. The patient and his family were hesitant to undergo surgical exploration. Subsequently, a scrotal ultrasound revealed normal testicular anatomy and echogenicity (Fig 1). A mass was noted at the superior pole of the left testis, consistent with epididymitis or torsion of a testicular appendage (Fig 1). The patient and his family elected to forego further treatment at that time, only to return two days later because of persistent pain. A repeat sonogram showed marked hypoechogenicity with increased through transmission, highly suggestive of torsion (Fig 1). An infarcted testicle was found during surgical exploration. A left orchietomy and right orchiopexy were performed.

Case 2

A 12-year-old boy had awakened from sleep with the acute onset of right-sided scrotal and abdominal pain. He denied any change in bowel or urinary habits or recent trauma but did recall past episodes of transient scrotal discomfort. Physical examination revealed a pubescent male in mild distress; temperature was 99°F orally, with normal vital signs; the abdomen was normal. Examination of the genitalia revealed a normal phallus with no urethral discharge but swelling of the right hemiscrotum. Although the right testicle was difficult to evaluate because of a moderate hydrocele, there was questionable tenderness at the superior pole. On laboratory evaluation, urinalysis results were normal; white blood cell count was 8,400/ μ l. A technetium-99 metastable (^{99m}Tc)perchnetate scan demonstrated normal testicular vascularity on the left and an abnormality on the right which was

Received for publication Dec 26, 1984; accepted Feb 22, 1985. Presented at the 60th Annual Meeting, Western Section, American Urological Association, Inc, Reno, NV; July 15-19, 1984. Reprint requests to (B.A.K.) Department of Urology, U-518, University of California, San Francisco, CA 94143. PEDIATRICS (ISSN 0031 4005). Copyright © 1985 by the American Academy of Pediatrics.

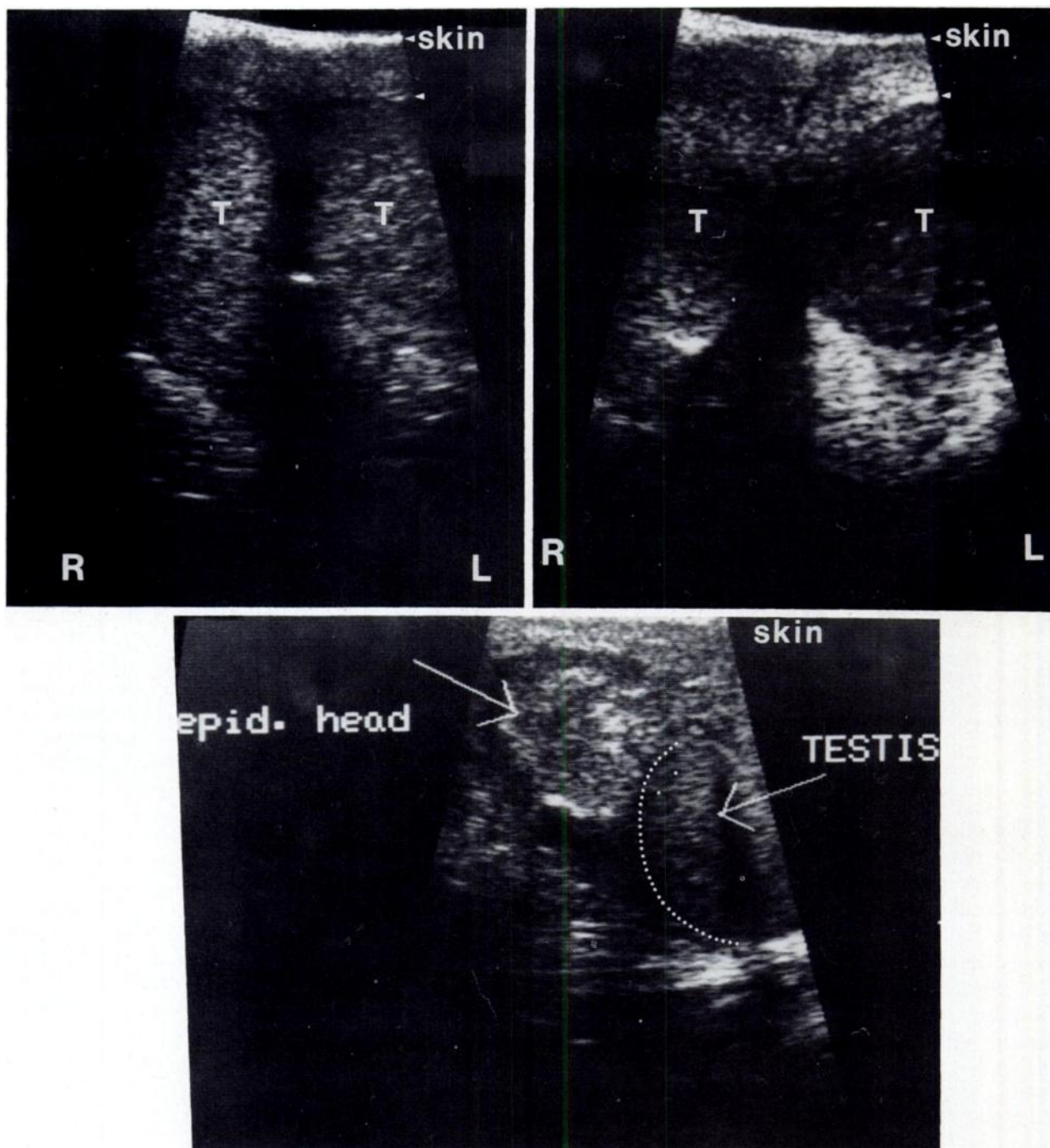


Fig 1. Patient 1. Top left, Transverse ultrasound of testes soon after onset of scrotal pain. In both size and echogenicity, appearance is symmetrical. This part of examination is normal. Bottom, Simultaneous longitudinal ultrasound of left testis. There is an inhomogeneous mass in region of epididymal (epid.) head. This corresponded to exact site of tenderness on physical exami-

nation. Although originally thought to represent a torted testicular appendage, this later proved to be site of spermatic cord torsion. Top right, Repeat transverse ultrasound two days later. Forty-eight hours posttorsion, enlarged left testis is hypoechoic with increased through-transmission. This study is unquestionably abnormal.

thought to be secondary to the hydrocele (Fig 2). The patient was followed and thought to have an infarcted appendix testis. His pain persisted, however, and during surgical exploration 1 week later, a torted testicle with hemorrhagic infarction was found. A right orchiectomy was performed as well as a contralateral orchiopexy.

RESULTS

The six patients ranged in age from 12 to 16 years (Table). Right and left sides were equally involved and symptoms had been present from three hours to eight days. Urinalysis findings were normal in

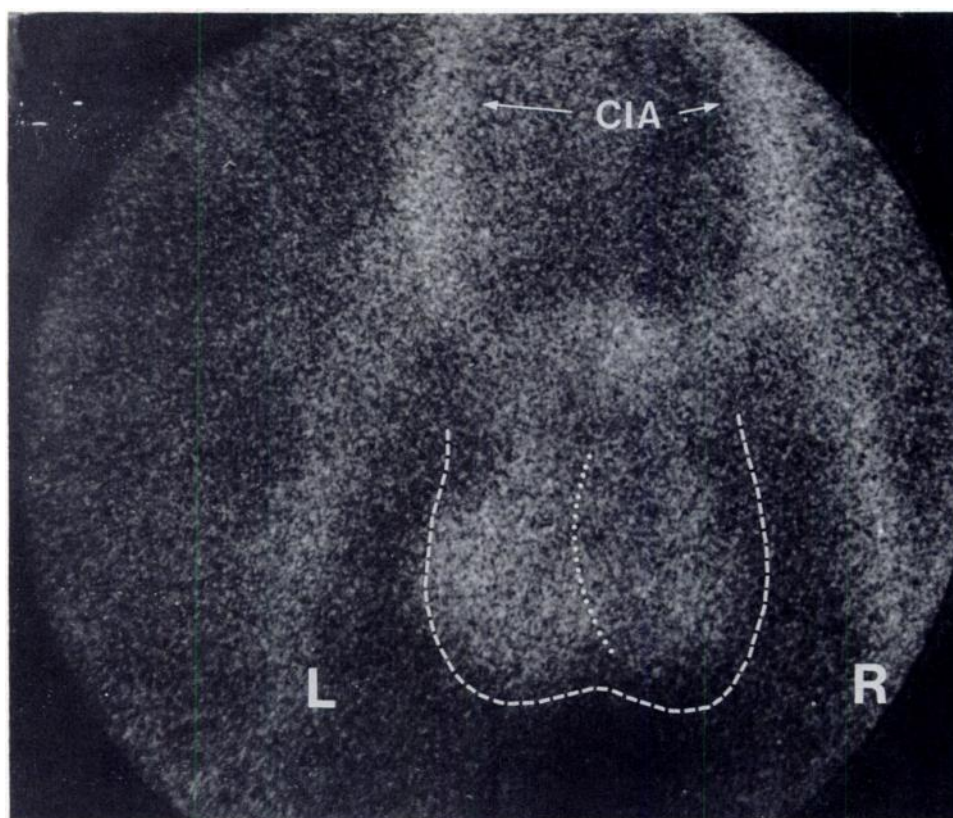


Fig 2. Patient 2. ^{99m}Tc -Pertechnetate scrotal scan shortly after onset of pain demonstrates definite photopenic area on right side. Although originally thought secondary to hydrocele, this ultimately proved to be avascular testis. CIA, Common iliac artery.

TABLE. Clinical Findings,* Ultrasound, and Radionuclide Scanning in Six Patients With Surgically Proven Spermatic Cord Torsion

Patient No.	Age (yr)	Side of Involvement	Duration of Symptoms	Nuclear Scan	Real-Time Ultrasonography	WBC Count (μL)	Correct Diagnosis
1	16	Left	3 h	...	Epididymitis or torsed appendix testis	...	Infarcted testicle
2	12	Right	8 h	Hydrocele	...	8,400	Infarcted testicle
3	12	Right	8 d	...	Epididymitis	...	Torsed appendix testis
4	14	Right	24 h	Epididymitis	Probable torsion	7,100	Intermittent torsion
5	15	Left	24 h	...	Epididymitis	10,300	Infarcted testicle
6	16	Left	36 h	...	Epididymitis	10,800	Spontaneous detorsion

* Urinalysis results were normal in all patients.

each case. The nuclear scan was misinterpreted in one patient with intermittent torsion and in one with a large inflammatory hydrocele. Findings from real-time sonography were inconclusive to diagnose accurately torsion of the appendix testis in one patient, spontaneous detorsion in another, and a clearly necrotic testis in two. The ultimate diagnosis was established by operative exploration in all

five patients with spermatic cord torsion and long-term follow-up in the one with torsion of the appendix testis.

DISCUSSION

The major diagnostic dilemma in patients with acute scrotal pain is the differentiation of acute

spermatic cord torsion from other pathologic entities. The complete differential diagnosis is extensive and includes torsion, both of the spermatic cord and testicular appendages, epididymitis, orchitis, hydrocele, spermatocele, Henoch-Schonlein purpura, trauma, and retroperitoneal irritation (eg, urinary calculus disease or appendicitis).

Age is an important historical factor: the peak incidence of testicular torsion occurs during pubescence (85% of patients are between 12 and 18 years); it is rare in those less than 10 years (with the exception of newborns) and in those older than 30 years.³ Probably, the predisposing anatomic defect allows the torsion to occur when the pubertal testis has become heavy enough to twist and remain fixed in position. Other historical considerations, eg, the rapid onset of symptoms or the past history of scrotal pain, are helpful but nondiagnostic. Similarly, the lack of abnormal voiding symptoms suggests torsion but is not conclusive.

Physical examination is the cornerstone in diagnosis of spermatic cord torsion. Defining the anatomy, including orientation of the testis, the epididymis, and the spermatic cord, is crucial. A high-lying ipsilateral testicle, a change in the normal posterolateral location of the epididymis, and tenderness throughout the testis and epididymis all suggest torsion of the spermatic cord. Presumably, abnormal position of the tunica vaginalis and testicle allows the twisting to take place and, hence, torsion is suggested by finding a horizontal lie of the contralateral testicle (bell-clapper deformity). Precise delineation of the anatomic location of the pain is very helpful: in epididymitis, the tenderness is directly posterior; in torsion of a testicular appendage, the tenderness is superior in the scrotum. Historically, Prehn's sign has also been used: scrotal elevation should lead to pain relief in epididymitis; with torsion, the pain will be unchanged. Unfortunately, Prehn's sign is nonspecific and often misleading. The observation of cremasteric reflex or a "blue-dot sign" can also help rule out torsion, but they are not always present. Urinalysis is an important adjunct to the history and physical examination: marked pyuria suggests epididymitis; clear urine points more strongly to testicular torsion.

Testicular torsion requires prompt surgical intervention. Delay can lead to testicular atrophy, decreased testosterone levels, and, possibly, autoimmunity against contralateral spermatogenesis.⁴ Unfortunately, even after a thorough history and physical examination, the diagnosis is not always clear-cut, and testicles have been lost because of diagnostic error. A "safer" approach would be to operate emergently on every case; however, this would re-

sult in considerable unnecessary surgery and unwarranted morbidity.

Newer, relatively noninvasive diagnostic studies have been added to the work-up in order not to jeopardize salvageable testes while avoiding unnecessary surgery. Nuclear imaging of the scrotum was the first such test: an intravenous dose of radioisotope, most commonly ^{99m}Tc-pertechnetate, is used to assess testicular perfusion (because bilateral synchronous torsion is rare, the contralateral testicle usually serves as an excellent control); a "cold" or hypoperfused area denotes testicular torsion, although a tumor, hydrocele, or abscess can mimic it.⁵ Increased radioisotope activity resulting from increased blood flow suggests epididymitis. Advantages of the study include minimal morbidity and radioactivity and ease of interpretation.⁶ Some studies have suggested that the nuclear scan will miss no acutely torsed testicle requiring urgent surgical intervention.⁷ However, it does require a cooperative patient capable of remaining stationary during imaging and, to be useful, must be immediately available, 24 hours a day. We have found these studies helpful on occasion; however, we have recently had two falsely negative nuclear scans. These errors occurred because of spontaneous detorsion and a large inflammatory hydrocele.

Continuous-wave Doppler ultrasonography is used to measure blood flow and is available as a mobile unit in most medical centers with trained personnel.⁸ Unlike nuclear imaging, it requires no injection or exposure to radioactivity, and it has the distinct advantage of following the return of blood flow after manual or spontaneous detorsion.⁹ Although the reported sensitivity is 95%, this method is highly operator dependent.¹⁰ The major limitation relates to the blind positioning of the transducer: a finding of decreased blood flow in the scrotum may be due to a poor position of the probe rather than torsion; conversely, normal blood flow will be seen with torsion if the probe is not positioned below the torsed spermatic cord. Recently, a duplex system with combined continuous-wave Doppler and real-time ultrasound has been introduced, and this may circumvent some of the difficulties described.¹¹

Real-time ultrasonography is very helpful in defining scrotal anatomy. It is especially useful in difficult testicular examinations—in the neonate, in patients with an extremely tender scrotum, and in those with prior intrascrotal pathology. Experimentally, early sonographic changes are detectable at 15 minutes posttorsion, even before light microscopic changes.¹¹ Other groups have reported characteristic changes in the first 24 hours, including decreased testicular echogenicity and minimal en-

largement of both testicle and epididymis.¹² From one day to 1 week, testicular echogenicity progressively decreases, testicular size decreases, and the epididymis remains enlarged. In a chronic situation, eg, ten days, the testicle is small with poor echogenicity. In our institution, real-time ultrasonography is the most readily available and reliable of all the ancillary tests, particularly in defining anatomy. However, it does not assess blood flow and may not be accurate early enough after the ischemia. Sensitivity may be improved, however, with combined continuous-wave Doppler and real-time ultrasonography. Recently, three of our patients had falsely negative sonograms. Surgical exploration proved spermatic cord torsion in each instance. In fact, two of these testes were necrotic and orchiectomy was performed.

We do not mean to imply that these tests are of no value. They should be considered useful adjuncts in the management of these patients. Unfortunately, more patients are needed for a definitive assessment of the sensitivity and specificity of sonography and nuclear medicine studies in the diagnosis of spermatic cord torsion.

SUMMARY

Acute scrotal pain in a child is always an emergency. A thorough history, physical examination, and urinalysis are mandatory. Supplemental laboratory data and sonographic and nuclear imaging may be helpful but are not infallible. The penalty of delay or misdiagnosis is considerable. Hence, negative supportive data should not prevent oper-

ative exploration of a clinically suspicious lesion. In the end, if torsion is at all suspected, emergency exploration is imperative.

ACKNOWLEDGMENT

We thank Dr Vernon Weldon for permission to include his patient (case 2) in this series.

REFERENCES

1. Smith GI: Cellular changes from graded testicular ischemia. *J Urol* 1955;73:355-362
2. Haynes BE, Bessen HA, Haynes VE: The diagnosis of testicular torsion. *JAMA* 1983;249:2522-2527
3. Perry S, Hoopingarner D, Askins D: Testicular torsion in the older patient. *Ann Emerg Med* 1983;12:319-320
4. Thomas WEG, Williamson RCN: Diagnosis and outcome of testicular torsion. *Br J Surg* 1983;70:213-216
5. Nakielny RA, Thomas WEG, Jackson P, et al: Radionuclide evaluation of acute scrotal disease. *Clin Radiol* 1984;35:125-129
6. Levy OM, Gittelman MC, Strashun AM, et al: Diagnosis of acute testicular torsion using radionuclide scanning. *J Urol* 1983;129:975-977
7. Lutzker LG: The fine points of scrotal scintigraphy. *Semin Nucl Med* 1982;12:387-393
8. Hricak H, Jeffrey RB: Sonography of acute scrotal abnormalities. *Radiol Clin North Am* 1983;21:595-603
9. Betts JM, Norris M, Cromie WJ, et al: Testicular detorsion using Doppler ultrasound monitoring. *J Pediatr Surg* 1983;18:607-610
10. Bitker MO, Martin B, Chatelain Ch, et al: Torsion of the spermatic cord: Can it be diagnosed by Doppler ultrasound? *Presse Med* 1983;12:1925-1926
11. Hricak H, Lue T, Filly RA, et al: Experimental study of the sonographic diagnosis of testicular torsion. *J Ultrasound Med* 1983;2:349-356
12. Bird K, Rosenfield AT, Taylor KJW: Ultrasonography in testicular torsion. *Radiology* 1983;147:527-534

Spermatic Cord Torsion: Diagnostic Limitations
Marshall L. Stoller, Barry A. Kogan and Hedvig Hricak
Pediatrics 1985;76:929

Updated Information & Services

including high resolution figures, can be found at:
<http://pediatrics.aappublications.org/content/76/6/929>

Permissions & Licensing

Information about reproducing this article in parts (figures, tables) or in its entirety can be found online at:
<http://pediatrics.aappublications.org/site/misc/Permissions.xhtml>

Reprints

Information about ordering reprints can be found online:
<http://pediatrics.aappublications.org/site/misc/reprints.xhtml>

PEDIATRICS is the official journal of the American Academy of Pediatrics. A monthly publication, it has been published continuously since 1948. PEDIATRICS is owned, published, and trademarked by the American Academy of Pediatrics, 141 Northwest Point Boulevard, Elk Grove Village, Illinois, 60007. Copyright © 1985 by the American Academy of Pediatrics. All rights reserved. Print ISSN: 0031-4005. Online ISSN: 1098-4275.

American Academy of Pediatrics

DEDICATED TO THE HEALTH OF ALL CHILDREN™



PEDIATRICS®

OFFICIAL JOURNAL OF THE AMERICAN ACADEMY OF PEDIATRICS

Spermatic Cord Torsion: Diagnostic Limitations
Marshall L. Stoller, Barry A. Kogan and Hedvig Hricak
Pediatrics 1985;76:929

The online version of this article, along with updated information and services, is located on the World Wide Web at:

<http://pediatrics.aappublications.org/content/76/6/929>

PEDIATRICS is the official journal of the American Academy of Pediatrics. A monthly publication, it has been published continuously since 1948. PEDIATRICS is owned, published, and trademarked by the American Academy of Pediatrics, 141 Northwest Point Boulevard, Elk Grove Village, Illinois, 60007. Copyright © 1985 by the American Academy of Pediatrics. All rights reserved. Print ISSN: 0031-4005. Online ISSN: 1098-4275.

American Academy of Pediatrics

DEDICATED TO THE HEALTH OF ALL CHILDREN™

