

UC Davis

Dermatology Online Journal

Title

Multiple keratotic projections on the palms and soles

Permalink

<https://escholarship.org/uc/item/6bc931cj>

Journal

Dermatology Online Journal, 29(3)

Authors

Barbosa, Joana
Coelho, Miguel
Joao, Alexandre

Publication Date

2023

DOI

10.5070/D329361431

Copyright Information

Copyright 2023 by the author(s). This work is made available under the terms of a Creative Commons Attribution-NonCommercial-NoDerivatives License, available at <https://creativecommons.org/licenses/by-nc-nd/4.0/>

Peer reviewed

Multiple keratotic projections on the palms and soles

Joana Barbosa MD, Miguel Coelho MD, Alexandre João MD

Affiliations: Department of Dermatology and Venereology, Centro Hospitalar Universitário de Lisboa Central, Lisbon, Portugal

Corresponding Author: Joana Barbosa, Serviço de Dermatologia e Venereologia, Hospital de Santo António dos Capuchos, Alameda Santo António dos Capuchos, 1169-050 Lisboa, Portugal, Tel: 351-911110884, E-mail: joanafabarbosa@gmail.com

Abstract

Spiny keratoderma (SKD) is a rare palmoplantar keratoderma that presents with few to numerous millimetric hyperkeratotic projections on the palms and soles. It has been described with both hereditary and acquired variants. The acquired form, which presents in older adults, has been associated with a variety of systemic diseases and malignant conditions. In patients suspected of having acquired spiny keratoderma, an evaluation for malignant conditions may be warranted. Treatment with topical keratolytics or topical and oral retinoids is usually insufficient. Herein, we present the case of a 58-year-old man diagnosed with idiopathic SKD.

Keywords: keratoderma, spiny, palmoplantar

Case Synopsis

A 58-year-old man presented to the dermatology department with a 3-year history of multiple, asymptomatic, millimetric, hyperkeratotic papules projecting from his palms and soles, bilaterally (**Figure 1**). He reported that these projections frequently got caught on clothing and other objects and, for that reason, he often shaved his own hands. He had a personal history of dyslipidemia and hypertension. He denied any personal or family history of skin disease or malignancy. He denied direct arsenic exposure. Skin biopsy was performed and revealed a thick column of parakeratosis over an area of hypogranulosis and slight depression of the epidermis (**Figure 2**).

Case Discussion

“Music-box” spiny keratoderma (SKD) is a rare palmoplantar keratoderma that presents with few to numerous millimetric hyperkeratotic projections on the palms and soles. The pathophysiology of SKD is unknown but may involve either abnormal or ectopic keratinization [1]. Inherited forms (autosomal dominant inheritance) typically begin in the first to third decade of life and acquired forms usually appear later in adulthood [1-3]. They can be idiopathic or arise in association with internal malignancies (breast, colon, kidney, lung, skin, and hematologic neoplasms), [4]. Notably, there have been described fewer than 50 different cases of spiny keratoderma and about a third of these have been reported in patients with personal history of malignancies [5]. Acquired SKD has also been

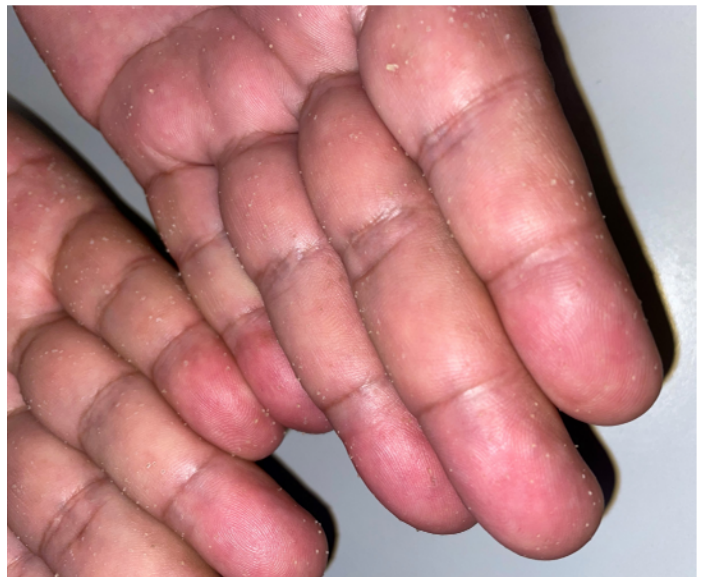

Figure 1. Multiple millimetric keratotic filiform papules on the palmar surface of both hands, including fingers.

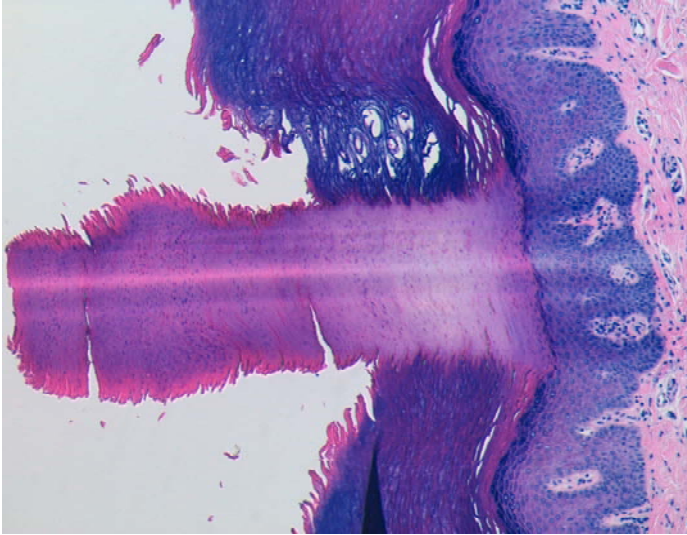


Figure 2. H&E stained skin biopsy shows a thick and well-demarcated column of parakeratosis over an area of hypogranulosis and slight depression of the epidermis, $\times 40$.

associated with chronic systemic diseases, such as, type IV hyperlipoproteinemia, diabetes, asthma, chronic renal failure, Darier disease, or HIV [3-8]. Therefore, a detailed clinical history, thorough physical examination, full laboratory work-up and appropriate cancer screenings are of paramount importance in patients with acquired SKD [4]. Our patient's work up included full blood and urine test

References

1. Torres G, Behshad R, Han A, Castrovinci AJ, Gilliam AC. 'I forgot to shave my hands': A case of spiny keratoderma. *J Am Acad Dermatol.* 2008;58:344-8. [PMID: 18068266].
2. Azevedo TP, Sodré CT, Santangelo C de L, et al. Spiny keratoderma: Report of three cases. *J Cosmet Dermatol.* 2020;19:2006-10. [PMID: 31860150].
3. Mohtashim M, Amin SS, Adil M, Tabassum H. Localized Music Box Spiny Keratoderma: A Rare Variant. *Indian Dermatol Online J.* 2020;11:842-843. [PMID: 33235863].
4. Chee SN, Ge L, Agar N, Lowe P. Spiny keratoderma: case series and review. *Int J Dermatol.* 2017;56:915-919. [PMID: 28681429].
5. Gironi LC, Landucci G, Cammarata E, Camillo L, Savoia P. Neoplasia-related spiny keratoderma: Dermoscopic findings of two cases and a literature review. *Australas J Dermatol.* 2021;62:393-396. [PMID: 34110015].
6. Corral M, Paret C, Iglesias M et al. Spiny keratoderma. *Dermatol Online J.* 2020;26:13030/qt8j43s926. [PMID: 33054945].
7. Campbell EH, Becknell C. Spiny keratoderma exposes underlying renal cell carcinoma. *JAAD Case Rep.* 2018;4:382-383. [PMID: 29693077].
8. Bordel-Gómez M. Palmoplantar spiny keratoderma associated with chronic lymphoid leukaemia. *J Eur Acad Dermatol Venereol.* 2008;22:1507-8. [PMID: 18355198].
9. Bao W, Hand CS, Davis LS. Palmoplantar hyperkeratotic projections. *JAAD Case Rep.* 2020;6:1042-1044. [PMID: 32995441].

(including prostate-specific antigen), chest X-ray, abdominal ultrasound and colonoscopy, which were all unremarkable.

The differential diagnosis includes arsenical keratosis, multiple filiform verrucae, parakeratosis palmaris plantaris or Buschke-Fisher-Brauer disease [4,6,9]. Although biopsy is not essential to establish a diagnosis in all cases, it will reveal a sharply demarcated column of parakeratotic cells above a fine granular layer [1,7,8]. Treatment is often difficult: mechanical friction, emollients, topical keratolytics, topical vitamin D3 derivatives, 5-fluorouracil, and topical and oral retinoids may be useful but lesions tend to recur without maintenance treatment [4,8]. Our patient's cancer screening was negative at the time, which confirmed the diagnosis of idiopathic spiny keratoderma. Topical keratolytics revealed only slight improvement. Due to the paraneoplastic phenomena associated with spiny keratoderma, longitudinal follow-up is required [4].

Potential conflicts of interest

The authors declare no conflicts of interest.