

# UCLA

## UCLA Previously Published Works

### Title

Case report 707

### Permalink

<https://escholarship.org/uc/item/69027800>

### Journal

Skeletal Radiology, 21(1)

### ISSN

0364-2348

### Authors

Dungan, David H  
Seeger, Leanne L  
Grant, Edward G

### Publication Date

1992

### DOI

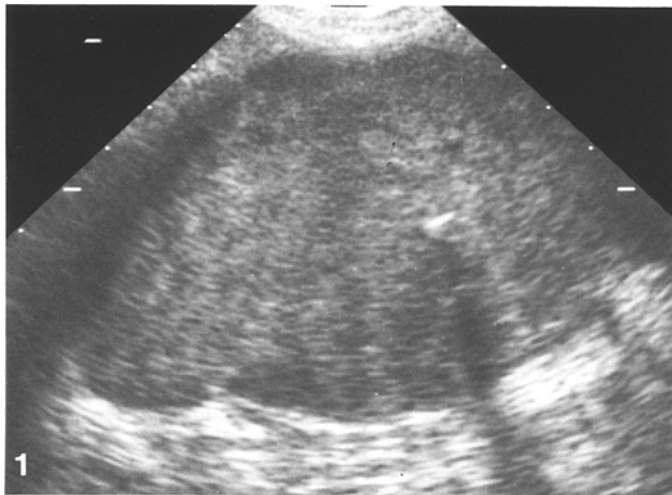10.1007/bf00243096

Peer reviewed

## Case report 707

David H. Dungan, M.D., Leanne L. Seeger, M.D., and Edward G. Grant, M.D.

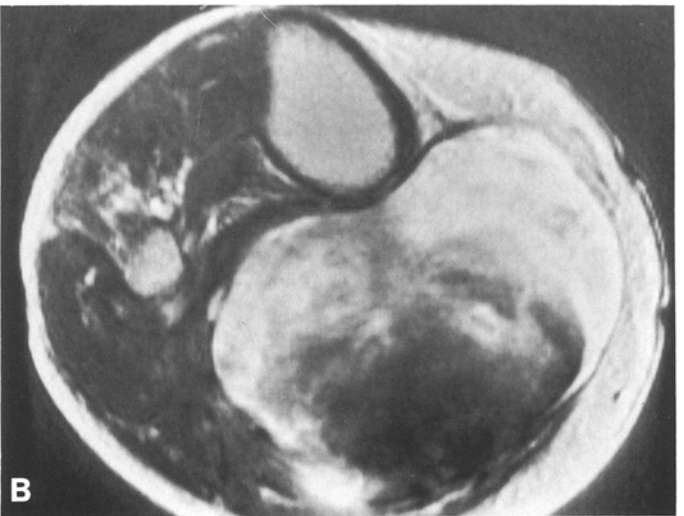
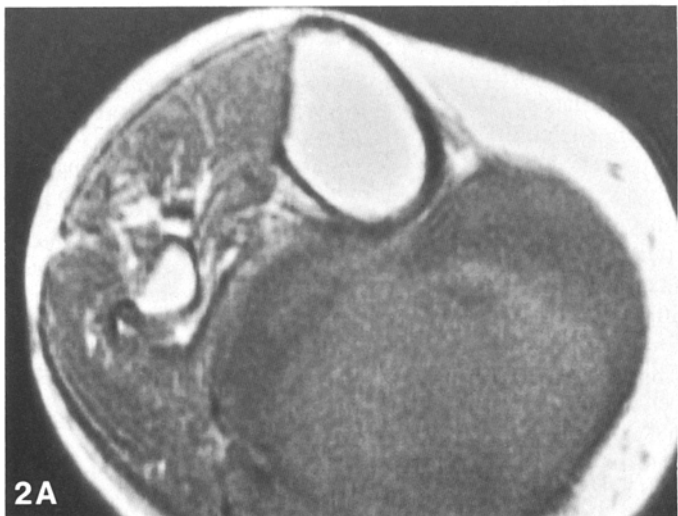UCLA School of Medicine, Department of Radiological Sciences, Los Angeles, California, USA



### Imaging studies

**Fig. 1.** Coronal ultrasound scan just below the knee shows a relatively homogeneous mass with scattered areas of acoustic shadowing

**Fig. 2 A, B.** Magnetic resonance (MR) imaging of the area of the proximal portion of the calf shows (A) T1-weighted axial scan (SE 500/22) and (B) T2-weighted axial scan (SE 2000/85). Central portion of the mass shows signal characteristics indicating blood



### Clinical information

This patient is a 50-year-old woman with a history of juvenile onset rheumatoid arthritis since the age of 15 years. Severe disease in both knees led to bilateral total knee arthroplasties more than 10 years previously. One year prior to presentation, she noted a mass in her right calf. The mass was increasing in size and

caused pain on ambulation with numbness of the right foot.

Physical examination revealed a 10 × 8 cm mass in the mid-calf. The mass was firm and tender, with no erythema or edema.

Roentgenograms of the right leg showed the total knee prosthesis in good position. A 2-mm radiolucency at the bone-cement interface of the tibial component was present. No soft-tissue calcifications were evident. Ultrasound examination demonstrated a relatively homogeneous, echogenic mass with scattered areas of acoustic shadowing, typical of calcifications (Fig. 1). Color doppler

imaging results suggested that the mass was avascular and displacing surrounding vessels. Magnetic resonance imaging (MRI) showed a large mass associated with the posterior aspect of the proximal portion of the calf (Fig. 2). The periphery of the lesion showed low signal intensity on T1-weighted images and high signal intensity on T2-weighted images. Centrally, the mass was of mixed low and intermediate signal intensity with T1-weighting and retained low signal intensity on T2-weighted images.

A surgical procedure was performed.

---

*Address reprint requests to:* L.L. Seeger, UCLA School of Medicine, Department of Radiological Sciences, 200 Medical Plaza, Suite 165-59, Los Angeles, CA 90024-6952, USA

### Diagnosis: Hemorrhagic Baker's cyst of the right calf

The differential diagnosis initially included Baker's cyst, popliteal artery aneurysm, soft-tissue sarcoma, deep venous thrombosis, and tear of the calf muscle.

The real-time ultrasound findings were initially interpreted as a solid mass, most suspicious for neoplasm. Color doppler scan showed the mass to be completely avascular, lessening the possibility of a tumor. The popliteal artery and vein were displaced by the mass, but they were normal.

The MR results suggested that the lesion was cystic with a large central clot. Differential diagnosis therefore became Baker's cyst versus clotted popliteal artery aneurysm. Because the patient had a history of iodinated contrast allergy, an air contrast arthrogram was performed. Arthrography clearly demonstrated communication between the joint and the mass, identifying the mass as a Baker's cyst (Fig. 3).

The mass was removed without complication. Pathological examination revealed a 2-mm thick, fibrous wall containing serous fluid with fibrin clots floating within it.

### Special study

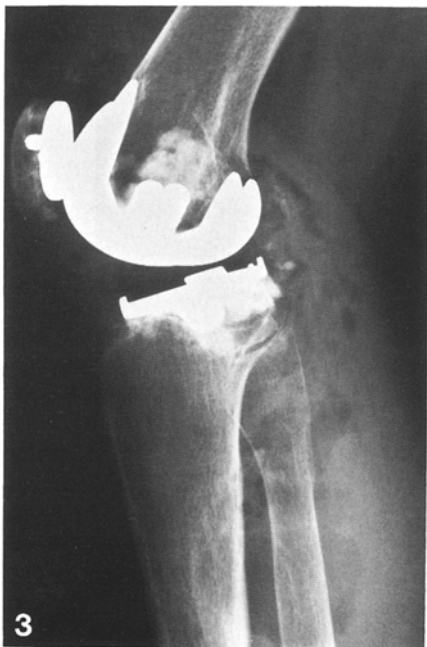

Fig. 3. Air arthrogram. Air freely communicates with the large cyst

### Discussion

Baker's (popliteal) cyst is a relatively common complication of chronic arthritis of the knee. In 1840, Adams described a cystic tumor in the medial popliteal region in patients with chronic rheumatoid arthritis [1]. W.M. Baker's classic article in 1877 described eight patients with popliteal cysts [2]. Baker suggested that the cyst represented distension of the semimembranosus bursa and that the fluid accumulated as a result of chronic arthritis. Apart from improved diagnostic techniques, there has been little to add since Baker's description. Even in cases of large cysts, hemorrhage into the cyst is unusual and to our knowledge has not been previously reported. While the diagnosis of uncomplicated cyst is generally straightforward, cyst with hemorrhage, as in this case, may be difficult to differentiate from aneurysm or sarcoma.

Anatomically, the popliteal cyst represents a distended gastrocnemio-semimembranosus bursa. In up to 50% of adults, the bursa connects to the joint space in the region of the insertion of the medial head of the gastrocnemius muscle. Chronic effusion in the knee joint becomes decompressed by flowing into the bursa. The fluid is trapped by a valve-like mechanism, causing varying degrees of distension [12]. Some authors have suggested that cyst formation may play a protective role by allowing the joint to decompress [3].

Because chronic effusion results in popliteal cysts, a number of disorders of the knee can lead to the formation of cysts. The most common causes are rheumatoid arthritis and osteoarthritis [4, 13]. Very large cysts, which may dissect into the calf muscles, are most commonly secondary to rheumatoid arthritis. Some authors refer to these as giant rheumatoid or calf cysts [11].

Clinically, popliteal cysts have varying presentations. An enlarging cyst may exert pressure on surrounding neurovascular structures, causing pain, paresthesias, and edema. Large cysts are prone to dissection and/or rupture [9]. This can result in sudden or insidious onset of pain in the calf

and swelling, the "pseudothrombophlebitis" syndrome [5, 6].

Radiographic evaluation of swelling of the calf should begin with roentgenograms to search for soft-tissue calcification, followed by ultrasound to evaluate the venous system and joint space and to determine the cystic versus solid character of the swelling [10]. If MRI is done, uncomplicated cysts will show a mass with homogeneous low signal intensity on T1-weighted scans, changing to high signal intensity on T2-weighted scans. Arthrography is the definitive method to delineate communication between the joint and a cyst. Arthrography can also determine the size, configuration, and possible rupture of a cyst [14].

Differential diagnosis of an uncomplicated popliteal cyst is limited to a few entities, and the diagnosis is usually readily evident with a variety of imaging techniques. Diagnosis of the complicated cyst may, however, be difficult.

Clinically, differentiation between cyst and *deep venous thrombosis* may pose problems. Ultrasound is the imaging modality of choice to differentiate venous occlusion from an uncomplicated cystic collection of fluid.

*Popliteal artery aneurysm* is another entity which should be easily distinguished from uncomplicated popliteal cyst. Ultrasound is especially useful in demonstrating communication between an aneurysm and the popliteal artery. Color doppler ultrasound study however, should also definitively diagnose this entity. In our patient, the MRI appearance was highly suggestive of aneurysm with central clot. The definitive examination proved to be the arthrogram, which demonstrated communication between the cyst and the joint.

Popliteal cysts have been mistaken for *soft-tissue tumors* of the calf on several occasions [7, 8]. In our case, the sonographic appearance (that of a solid mass) was particularly misleading. A major facet of this report, in fact, is the demonstration that hemorrhage into a Baker's cyst, like hemorrhage elsewhere in the body, is initially echogenic and therefore solid in appearance. The extremely well-defined borders and

avascular nature with color doppler imaging should lead the diagnosis away from neoplasm.

*Traumatic tear* of the gastrocnemius muscle can be easily differentiated from a popliteal cyst by history. The sonographic appearance of a dissecting hematoma caused by the muscle tear may, however, be difficult to differentiate from a ruptured cyst. As in our case, arthrography may establish the diagnosis.

In *summary*, a 50-year-old woman with juvenile rheumatoid arthritis presented with painful swelling of the right calf. Roentgenograms, sonograms, magnetic resonance images, and arthrograms were obtained. A diagnosis of hemorrhagic Baker's cyst was made, and surgical excision was performed. The etiology, clinical features, and radiological evaluation of simple and complicated Baker's cysts are discussed and the differential diagnosis considered.

## References

1. Adams R (1840) Arthritis, chronic rheumatic, of the knee joint. *Dublin J Med Sci* 17:520
2. Baker WM (1877) On the formation of synovial cysts in the leg in connection with disease of the knee joint. *St Bartholomews Hosp Rep* 13:245
3. Gerber NJ, Dixon ASJ (1974) Synovial cysts and juxtaarticular bone cysts. *Semin Arthritis Rheum* 3:323
4. Gristina AG, Wilson PD (1964) Popliteal cysts in adults and children. *Arch Surg* 88:357
5. Hench PK, Reid RT, Reames PM (1966) Dissecting popliteal cyst simulating thrombophlebitis. *Ann Intern Med* 64(6):1259
6. Katz RS, Zizic TM, Arnold WP, Stevens MB (1977) The pseudothrombophlebitis syndrome. *Medicine* 56:151
7. Kersley GD, Barber HS, Cregan JCF, Gibson HJ (1954) Degenerative rheumatoid changes. *J Bone Joint Surg [Br]* 36:238
8. Kristiansen B, Varmarken JE, Olsen CA (1988) Giant rheumatoid cyst of the calf simulating a soft tissue tumour. *Scand J Rheumatol* 17:297
9. Lieberman JM, Yulish BS, Bryan PJ, Newman AJ (1988) Magnetic resonance imaging of ruptured Baker's cyst. *J Can Assoc Radiol* 39:295
10. Moore CP, Sarti DA, Louie JS (1975) Ultrasonographic demonstration of popliteal cysts in rheumatoid arthritis: a non-invasive technique. *Arthritis Rheum* 18:577
11. Perri JA, Rodnan GP, Mankin HJ (1968) Giant synovial cysts of the calf in patients with rheumatoid arthritis. *J Bone Joint Surg [Am]* 50:709
12. Rauschnig W (1979) Popliteal cysts and their relation to the gastrocnemio-semimembranosus bursa. *Acta Orthop Scand (Suppl)* 179:7
13. Wigley RD (1982) Popliteal cysts: variations on a theme of Baker. *Semin Arthritis Rheum* 12(1):1
14. Wolfe RD, Colloff B (1972) Popliteal cysts: an arthrographic study and review of the literature. *J Bone Joint Surg [Am]* 54:1057