

# UC Irvine

## UC Irvine Previously Published Works

### Title

Consensus Statement for the Management and Treatment of Port-Wine Birthmarks in Sturge-Weber Syndrome

### Permalink

<https://escholarship.org/uc/item/68c7v95d>

### Journal

JAMA Dermatology, 157(1)

### ISSN

2168-6068

### Authors

Sabeti, Sara  
Ball, Karen L  
Burkhart, Craig  
[et al.](#)

### Publication Date

2021

### DOI

10.1001/jamadermatol.2020.4226

Peer reviewed

# Consensus Statement for the Management and Treatment of Port-Wine Birthmarks in Sturge-Weber Syndrome

Sara Sabeti, BS; Karen L. Ball, BS; Craig Burkhardt, MS, MPH, MD; Lawrence Eichenfield, MD; Esteban Fernandez Faith, MD; Ilona J. Frieden, MD; Roy Geronemus, MD; Deepti Gupta, MD; Andrew C. Krakowski, MD; Moise L. Levy, MD; Denise Metry, MD; J. Stuart Nelson, MD, PhD; Megha M. Tollefson, MD; Kristen M. Kelly, MD

**IMPORTANCE** Sturge-Weber syndrome (SWS) is a neurocutaneous syndrome involving the skin, brain, and eyes. Consensus recommendations for management are lacking.

**OBJECTIVE** To consolidate the current literature with expert opinion to make recommendations that will guide treatment and referral for patients with port-wine birthmarks (PWBs).

**EVIDENCE REVIEW** In this consensus statement, 12 nationally peer-recognized experts in dermatology with experience treating patients with SWS were assembled. Key topics and questions were formulated for each group and included risk stratification, optimum treatment strategies, and recommendations regarding light-based therapies. A systematic PubMed search was performed of English-language articles published between December 1, 2008, and December 1, 2018, as well as other pertinent studies identified by the expert panel. Clinical practice guidelines were recommended.

**FINDINGS** Treatment of PWBs is indicated to minimize the psychosocial impact and diminish nodularity and potentially tissue hypertrophy. Better outcomes may be attained if treatments are started at an earlier age. In the US, pulsed dye laser is the standard for all PWBs regardless of the lesion size, location, or color. When performed by experienced physicians, laser treatment can be safe for patients of all ages. The choice of using general anesthesia in young patients is a complex decision that must be considered on a case-by-case basis.

**CONCLUSIONS AND RELEVANCE** These recommendations are intended to help guide clinical practice and decision-making for patients with SWS and those with isolated PWBs and may improve patient outcomes.

There is a need for a consensus statement regarding an approach to managing Sturge-Weber syndrome (SWS). In 2018, the Sturge-Weber Foundation published a comprehensive review of research needs regarding the pathogenesis, clinical features, and treatment options for SWS.<sup>1</sup> Our consensus aims to provide clinical practice guidelines for the care of the major dermatologic feature of SWS: the port-wine birthmark (PWB).

Sturge-Weber syndrome is a sporadic, congenital, neurocutaneous syndrome involving the skin, brain, and eyes, with an estimated prevalence of 1 in 20 000 to 1 in 50 000 live births.<sup>2</sup> It is caused by a somatic mosaic mutation in the GNAQ gene located on chromosome 9q21, affecting neural crest cells emanating from the forebrain region and resulting in vascular abnormalities of the cutaneous forehead, cerebral cortex, and eye.<sup>3,4</sup> Patients with SWS typically have at least 2 of the following 3 components: facial PWB, vascular malformation in the brain, and vascular malformation in the eye. However, clinical manifestations vary, and workup and treatment are guided by the extent of these manifestations.

The goals of this consensus statement are to review the literature and provide an approach to risk stratification and evaluation of PWBs, offer guidance on diagnostic workup for patients with suspected or newly diagnosed SWS, and assess current treatment options for PWBs in light of the patient's age and condition severity. The treatment recommendations are currently applicable to all patients with a PWB.

## Methods

Twelve national experts in dermatology were consulted to develop a consensus statement on the management and treatment of cutaneous manifestations of SWS as part of a larger consensus statement. The panel was created from a list of experts provided by the Sturge-Weber Foundation who had significant experience in treating patients with SWS and patients with PWBs who agreed to participate. Three key needs were identified: (1) risk stratification and evaluation of PWBs, (2) optimum treatment strategies for PWBs, and (3) specific recommendations regarding light-based therapies. The expert group was divided into 4 subgroups that formulated questions to address each topic. An extensive literature review was performed using PubMed for English-language articles published between December 1, 2008, and December 1, 2018, an arbitrarily selected date range, to explore articles within the past 10 years. Articles before 2008 or after 2018 were added by the expert panel based on importance. Search terms included Sturge-Weber syndrome plus the following: clinical presentation, pathogenesis, risk prediction, port-wine birthmark or port-wine stain, diagnostic workup, triage, management, treatment, laser therapy, light-based therapy or treatment, photodynamic therapy, infantile hemangioma, and nevus simplex. A total of 112 articles were identified; 76 were relevant to dermatology. This number was narrowed to 41 articles based on abstract or full-text review and supplemented with 10 additional references identified by the expert panel. Publications were assigned to questions for each key topic and distributed to each subgroup to develop responses and key guidelines, which were consolidated into 10 key topics (Box). One of us (S.S.) drafted the manuscript and presented it to all 4 subgroups for electronic discussion and modification. The drafts were circulated to the full expert panel and edited multiple times until each participant gave final approval.

### **Box. Key Topics for Dermatologic Management and Treatment in SWS**

1. The characteristic skin manifestation of Sturge-Weber syndrome (SWS) is a port-wine birthmark (PWB), a congenital vascular malformation composed of malformed capillary-like vessels that is present at birth as a typically unilateral, bilateral, or centrally located, well-demarcated, pink to red patch on the face.
2. The best timing for evaluation of a facial PWB is at birth.
3. There are a number of factors that should be considered regarding treatment, including minimizing the psychosocial impact, diminishing nodularity and, potentially, tissue hypertrophy, and financial considerations for the family.
4. In the US, light-based devices are the standard of care for PWB treatments, and pulsed dye laser is considered first line.
5. Light-based devices are still first-line treatment for PWBs in patients with skin of color; however, higher rates of adverse effects may be seen than in lighter-skinned patients, mainly dyspigmentation and atrophic scarring. Moderate energy densities, less pulse overlap, and increased cooling are recommended in the treatment of patients with darker skin types to minimize risks.
6. There are a number of alternative therapies that have been investigated for PWBs that do not respond to traditional laser and light-based treatments.
7. The interval between laser treatments is dependent on a multitude of factors. No optimal interval has been established by scientific evaluation; thus, treatment interval must be tailored to each patient.

8. Greater rates of lightening and possible prevention of future darkening and hypertrophy may be attained if treatments are started at an earlier age. The main goal of treatment is to ensure healthy and adequate psychosocial development and minimize the stigma associated with PWBs.
9. Pulsed dye laser in young patients is a safe treatment option with a low incidence of permanent complications when performed by an experienced laser surgeon.
10. Laser treatments can be associated with significant discomfort. The choice of using general anesthesia is complex, and informed decision-making should be shared with the patients and their parents/guardians.

### Key Points

**Question** What are clinical practice guidelines for treatment and management of port-wine birthmarks, including those associated with Sturge-Weber syndrome?

**Findings** In this consensus statement, 10 key recommendations for treatment of port-wine birthmarks were formulated. These recommendations address risk stratification, optimum treatment strategies, and recommendations regarding light-based therapies.

**Meaning** The recommendations provided in this statement may help guide clinical decision-making for these patients.

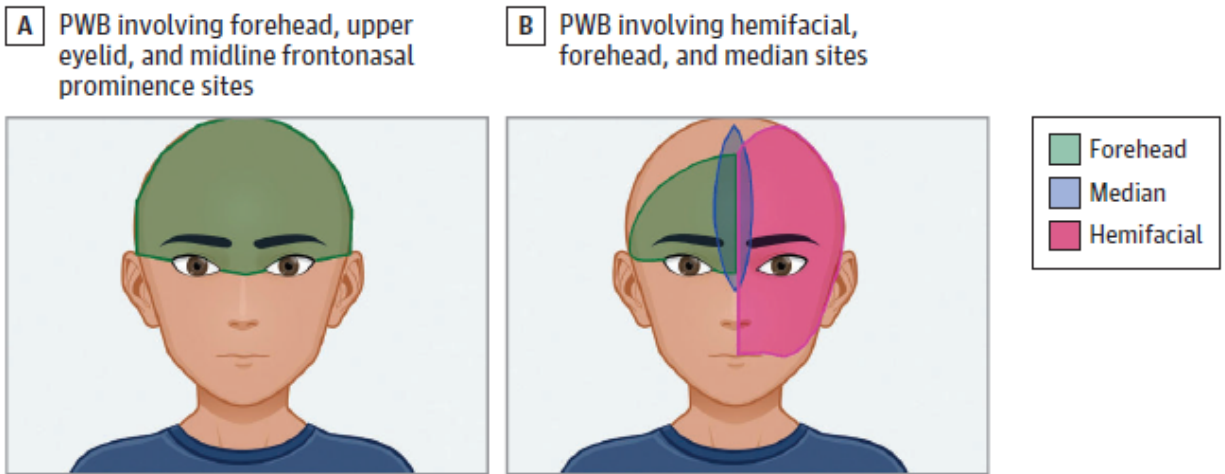
### Dermatologic Factors

Key topic 1: The characteristic skin manifestation of SWS is a PWB, a congenital vascular malformation composed of malformed capillary-like vessels that is present at birth as a typically unilateral, bilateral, or centrally located, well-demarcated, pink to red patch on the face.

The best predictor for SWS is a facial PWB involving any part of the forehead, including the upper eyelid and the midline frontonasal prominence (Figure, A).<sup>3</sup> The distribution appears to follow the patterns of embryologic vasculature, challenging the long-held belief of a trigeminal nerve cause. Not all patients with PWBs will develop SWS; however, certain distributions indicate an increased risk. Studies have reported a 7% to 28% risk for SWS in patients with a PWB in what was previously described as a V1 distribution.<sup>6</sup> More recent research has reported that hemifacial, forehead, and median PWB locations are associated with increased SWS risk (Figure, B).<sup>7</sup> Bilateral PWBs or those that extend from the forehead to include the cheek and skin overlying the mandibles have a higher risk of SWS,<sup>8,9</sup> but the forehead location is the strongest independent predictor of SWS risk.<sup>3,5</sup> Port-wine birthmarks in SWS most often involve the lateral forehead and are less commonly localized to the midline forehead, but there are exceptions, as even a small PWB of the midline forehead can be associated with severe neurologic disease.<sup>9</sup> Facial PWBs persist throughout life and may become darker red or red-purple over time. Particularly when located over the midface, facial PWBs may develop progressive vascular ectasia/thickening, soft tissue hypertrophy, and proliferative nodules that are prone to bleeding, discomfort, and less commonly, infection.<sup>10</sup> On histologic examination, most such nodules represent vascular ectasias, pyogenic granulomas, or arteriovenous malformations,<sup>11</sup> although other epithelial and mesenchymal hamartomas have been described.<sup>12</sup> Progression may result from both vascular ectasia and specific genetic alterations with PWBs that lead to soft tissue hypertrophy.<sup>13</sup> Progressive changes are uncommon before puberty. Eczematous skin changes (eg, Meyerson phenomenon) have been observed within PWBs earlier in childhood, particularly in children with preexisting atopic dermatitis.<sup>14</sup>

Key topic 2: The best timing for evaluation of a facial PWB is at birth.

**Figure. Port-Wine Birthmarks (PWBs) With the Highest Risk of Sturge-Weber Syndrome**



A, Forehead PWB location described by Waelchli et al.<sup>3</sup> B, Forehead, median, and hemifacial PWB locations described by Dutkiewicz et al.<sup>5</sup> Illustration by Sara Sabeti, BS.

Identification of an at-risk facial PWB, especially those involving the forehead, should prompt an eye examination for congenital glaucoma and neurology referral. In cases in which the diagnosis is uncertain, referral to an experienced specialist is appropriate (eAppendix in the Supplement). Differential diagnoses include segmental infantile hemangioma that may warrant a PHACE (posterior fossa anomalies, hemangioma, arterial anomalies, cardiac anomalies, and eye anomalies) workup or other capillary malformations, such as nevus simplex. Early diagnosis of a PWB affords the option of maximizing early laser treatments, which may be performed without the need for general anesthesia and may improve treatment outcome.<sup>3</sup>

### **Determination of the Optimum Treatment**

Key topic 3: There are a number of factors that should be considered regarding treatment, including minimizing the psychosocial impact, diminishing nodularity and, potentially, tissue hypertrophy, and financial considerations for the family.

Patients and parents seek treatment for several reasons, including lesion appearance that affects quality of life, confidence, and self-esteem, among other psychosocial issues.<sup>15</sup> Laser treatments may prevent or treat the proliferative nodules that can develop over time.<sup>16</sup> There is no clear evidence that laser treatment definitively prevents tissue hypertrophy. However, superficial overgrowth may be minimized if adequate vessel removal is achieved. Because laser light is unable to reach deep vessels, PWBs may develop hypertrophy despite treatment.

Key topic 4: In the US, light-based devices are the standard of care for PWB treatment, and pulsed dye laser (PDL) is considered first line.

Pulsed dye laser has the longest history of efficacy and safety for treatment of PWBs, and many studies support this device as the standard.<sup>6,17</sup> For infants, PDL is considered the standard of care in the US. Experienced surgeons can safely perform laser surgery in patients of all ages.

Several other wavelength lasers (532, 755, and 1064 nm) and intense pulsed light have been used for PWB treatment. These techniques can be used for all PWBs but are especially useful for those that have demonstrated PDL resistance. The longer wavelengths (755 and 1064 nm) may help target larger or deeper vessels, such as those in patients with nodular and hypertrophic lesions.<sup>6,18</sup> These

devices also target hemoglobin but have a higher risk of damage to nontargeted tissue than PDL. To our knowledge, there have been few or no randomized clinical trials with these alternative devices, and children have not been included in most of the reports. However, small studies have shown promising results for recalcitrant PWBs.<sup>19,20</sup> The Alexandrite laser is the most commonly used alternative when PDL is inadequate.<sup>21</sup> Long-pulsed Nd:YAG may also be considered but has a particularly narrow margin of safety.<sup>6</sup>

A variety of fractionated ablative devices designed for facial rejuvenation have also been used for PWB treatment. Many of these devices use infrared laser pulses (carbon dioxide, erbium:YAG, and erbium:glass), while others use bipolar radiofrequency ablation to coagulate skin and blood vessels. In small studies combined with PDL, efficacy has been demonstrated with these devices for recalcitrant PWBs.<sup>22,23</sup>

When discussing the option of laser treatment with families, several factors should be addressed, the first of which is pain control. Topical anesthetics; epidermal cooling methods; injection of local anesthetics; nerve blocks; intramuscular pain medication, such as meperidine; or general anesthesia can minimize discomfort.<sup>16</sup> Multiple factors are involved in choosing the optimal method of pain control for a patient, including but not limited to patient age and state of health, PWB location and extent, availability of methods dependent on practice, surgeon experience, and parent/child preference. Second, adverse effects should be discussed; these are detailed in key topic 10. Third, the family will be faced with financial obligations. Costs may include such factors as professional fees of the laser surgeon, anesthesia fees, and facility fees. The fourth factors are clinical outcomes. Realistic expectations should be set with families as complete PWB clearance is rarely achieved.<sup>24</sup> Pulsed dye laser can achieve 50% to 90% clearance, and most patients will have more than 50% lightening.<sup>6</sup> Most patients require 8 to 10 treatments or more for optimal results; however, touch-up treatments are frequently needed even after an initial successful series of lightening. Despite considering the following factors, response is difficult to predict.

Several factors have an effect on treatment response. Patients with lighter skin types have a better treatment response.<sup>25</sup> Portwine birthmarks on the face and neck respond better than those on the extremities,<sup>17</sup> and PWBs on the lateral face respond better than those in the central face.<sup>22,26</sup> Proximal extremity lesions respond better than distal extremity lesions.<sup>17</sup> The eyelids and neck are at higher risk for blistering and scarring, and this possibility should be considered when selecting laser parameters. Based on our experiences, individuals with PWBs associated with SWS may be more resistant to laser. Pink, red, and reticular lesions may respond better than those that are purple and geographic shaped.<sup>17,25</sup> Not unexpectedly, PWBs with overgrowth will show a lesser response than those that are flat, smooth, and not associated with contour change.<sup>6,17</sup>

Fifth, psychosocial consequences should be discussed. It is important that the short- and long-term well-being of the patient from a psychosocial perspective is considered and, above all else, the patient's safety.

Key topic 5: Light-based devices are still first-line treatment for PWBs in patients with skin of color; however, higher rates of adverse effects may be seen than in lighter-skinned patients, mainly dyspigmentation and atrophic scarring. Moderate energy densities, less pulse overlap, and increased cooling are recommended in the treatment of patients with darker skin types to minimize risks.

Port-wine birthmarks occur in patients with all skin types, and this is probably the greatest factor influencing treatment. While limited clinical studies exist for certain races/ethnicities, specifically East Asian and Indian patients, and in certain skin types, particularly Fitzpatrick skin types V and VI, a few studies provide insight for pigmented skin. In one study, PDL was used successfully in Indian patients without permanent adverse effects, although the lightening achieved was modest.<sup>27</sup> This study included 74 flat, nonhypertrophic PWBs with a mean of 7.3 treatment sessions and 24 hypertrophic

PWBs with a mean of 8.5 treatment sessions. The mean lightening achieved was 54% in nonhypertrophic lesions and 40% in hypertrophic lesions.<sup>27</sup> In East Asian populations, PDL has also been used safely and successfully. While the percentage of improvement varies, reported results are slightly better than those in the aforementioned Indian study with fewer treatment sessions. In 239 Korean patients, 51.9% showed a good to excellent response, defined as greater than 51% clearance, after a mean of 4.29 sessions.<sup>28</sup> In a study of 848 Chinese patients, a 69.9% response was achieved after a mean of 6.2 sessions.<sup>29</sup> This study also underscored the importance of patient age in treatment response, with a 93.9% response rate reported in children treated during the first year of life and only a 25% response rate in adults treated when they were older than 50 years.

While patients with darker skin types can experience improvement in their PWBs, they are also at higher risk of persistent dyspigmentation, atrophy, and scarring.<sup>17,21</sup> In general, moderate fluences, less pulse overlap, and increased cooling are recommended in treating patients with skin of color, and patients should be counseled that transient hyperpigmentation is common.<sup>27</sup>

Key topic 6: There are a number of alternative therapies that have been investigated for PWBs that do not respond to traditional laser and light-based treatments.

Alternatives to laser or intense pulsed light therapy can be divided into 4 groups: (1) adjuvant medications, (2) photodynamic therapy, (3) surgery, and (4) corrective cover-up. There are currently no adjunctive medical therapies that have demonstrated consistent impressive efficacy for PWBs.<sup>30,31</sup> Several small studies have reported some benefit for PDL plus topical imiquimod vs PDL alone.<sup>30</sup> Similarly, a few small studies and case reports demonstrated some benefit of topical rapamycin as an adjunct with PDL<sup>32,33</sup> but no consistent benefit over PDL alone. Photodynamic therapy involves the intravenous administration of a photosensitizer (various forms of porphyrin) followed by exposure to a light source, producing intravascular singlet oxygen molecules that destroy local tissue. Although photodynamic therapy is not currently performed in the US, studies from China have shown promising results.<sup>34-36</sup> Approximately 20% of patients experience hyperpigmentation and scarring. However, melanin does not influence the efficacy of photodynamic therapy, so this treatment can be performed in patients of all skin types, although patients with darker skin types will still be more susceptible to pigmentary change post treatment.<sup>6,17</sup> Surgery can be used to selectively debulk thick PWBs or lip hypertrophy, remove larger nodules, or completely remove small lesions in which the resulting surgical scar is acceptable to the patient. A variety of corrective cover-up products and concealers are available for dermatologic conditions and can be used in patients with PWBs.

## **Laser and Light-Based Therapies**

Key topic 7: The interval between laser treatments is dependent on a multitude of factors. No optimal interval has been established by scientific evaluation; thus, treatment interval must be tailored to each patient.

The interval between laser sessions depends on age, skin type, PWB location, pain tolerance, and presence of hypertrophy, nodules, or blebs. The interval is also influenced by resolution of prior purpura and/or hyperpigmentation, convenience, financial limitations, and potential restriction of activities after treatments. Only a few small studies in infants have analyzed the interval between PDL treatment sessions ranging from 2 weeks to 3 months.<sup>37,38</sup> These studies do not provide a clear recommendation on shorter vs longer intervals, although a subset of patients appears to benefit from shorter intervals. These studies have demonstrated the safety of PDL when performed at short intervals.

In older children, adolescents, and adults, it is uncertain whether there is an optimal timing interval between treatments. A small pilot study in adults suggested that 2-week treatment intervals resulted in greater lightening compared with 6-week intervals.<sup>39</sup> Other studies have failed to show this benefit.<sup>40</sup> While shown to be safe, shorter treatment intervals may result in a higher incidence of

undesirable effects, especially in patients with darker skin who often benefit from longer intervals to avoid postinflammatory hyperpigmentation. It is also important to allow purpura to heal before treating again because the increased chromophore can heighten the risk of adverse effects.

Key topic 8: Greater rates of lightening and possible prevention of future darkening and hypertrophy may be attained if treatments are started at an earlier age. The main goal of treatment is to ensure healthy and adequate psychosocial development and minimize the stigma associated with PWBs.

Based on expert observations and limited studies, treatment of PWBs at an earlier age, particularly in the first year of life, results in better outcomes. Factors associated with improved prognosis in young children include proportionately smaller PWBs, more superficial and smaller blood vessels, and less melanin as a competing chromophore for PDL. Liu et al<sup>41</sup> found greater efficacy when treatments were started before age 6 years. Other studies have reported better responses in infants younger than 1 year, particularly with smaller PWBs (<20 cm).<sup>3,42-44</sup> However, these studies are limited by their retrospective design and relatively short follow-up periods. Larger case-control studies are needed to support this observation.

Current laser technology is less successful in reverting progressive PWB changes of darkening, hypertrophy, and nodularity. Thus, performing laser treatment in early childhood may prevent or minimize these changes. Limited retrospective studies support the concept that early treatment inhibits progression; however, longitudinal studies are needed.<sup>45,46</sup> It has been shown that patients aged 7 to 16 years with facial differences, including PWBs, experience impaired health-related quality of life.<sup>47</sup> The negative impact in the child's psychosocial development and quality of life is one of the main reasons to pursue early treatment. This impact may be diminished when lightening of the PWB is attained at an earlier age.

Key topic 9: Pulsed dye laser in young patients is a safe treatment option with a low incidence of permanent complications when performed by an experienced laser surgeon.

The risks associated with laser treatment of PWBs can be categorized in 2 groups: risks inherent to the procedure and risks associated with the method of analgesia. The latter is discussed with the next key topic. The risks associated with PDL are focused on here because it is the most widely used and safest treatment option in infants and toddlers, particularly when compared with longer-wavelength vascular lasers. The safety and tolerance of PDL was also improved with the addition of cooling technology. Immediate treatment effects include erythema and purpura, which has traditionally been considered the desired clinical end point. The risk of complications has been reported to be less than 10%, and most complications are temporary.<sup>41</sup> Swelling may occur, which in most patients is mild except in the periorbital or lip area. Dyspigmentation may occur in response to direct epidermal and melanocyte damage and is most common in patients with darker skin types, tanned skin, and recent sun exposure. Sun protection is advised before and after treatments. Temporary blistering may occur. Erosions, ulcerations, and secondary infection are rare when appropriate laser settings are used and adequate postprocedure skin care is followed. Permanent scarring, both atrophic and hypertrophic, is one of the most serious potential complications of PDL but has an estimated incidence below 1%.<sup>41,48,49</sup> In addition, PDL treatment over hair-bearing areas may cause hair loss, which is typically temporary but can be permanent in an estimated 1.5% to 2.6% of cases.<sup>50</sup>

The most serious potential complication resulting directly from PDL is ocular damage, especially when the periorbital area is treated. Appropriate use of corneoscleral eye shields is mandatory when treating the skin within the orbital rim. Laser-specific eye shields may be used when treating outside the orbital rim. Special care must be taken when PDL is performed without sedation, as young patients may move in response to the discomfort. Securing the patient's position and ensuring eye protection is crucial when treating infants and toddlers. Parents, nursing staff, and the laser surgeon must also wear adequate protective eyewear.



Key topic 10: Laser treatments can be associated with significant discomfort. The choice of using general anesthesia is complex, and informed decision-making should be shared with the patients and their parents/guardians.

An important factor to consider when treating younger patients is the pain and discomfort associated with laser treatments. While treatment of small and moderate-size lesions is fast and generally well tolerated, patients with larger PWBs may experience significant discomfort, in which case topical anesthesia or sedation may be considered. Topical anesthetics, including lidocaine preparations, can be used safely, but there is a risk of methemoglobinemia, especially in infants.<sup>16</sup> Published guidelines regarding topical anesthesia should be followed if this option is chosen.<sup>51</sup>

General anesthesia requires careful consideration given the potential risks and higher cost. General anesthesia carries a risk of cardiorespiratory complications, which is highest in the neonatal period and decreases with age.<sup>52,53</sup> It is common practice to wait until the infant is at least age 6 months to use general anesthesia for elective procedures, but procedures before this age can be performed without general anesthesia. Anesthesia should be administered by clinicians specialized in pediatric care to reduce the risk of perioperative morbidity. The risk of neurotoxicity with potential long-term negative effects on neurologic development has gained recent attention.<sup>54</sup> The US Food and Drug Administration advises caution in patients younger than 3 years requiring repeated use of general anesthesia and sedation during surgeries or procedures, which is relevant to the management of PWBs as multiple treatments early in life are often performed. The warning was based predominantly on preclinical data, and ongoing trials may help to further clarify this risk.<sup>54</sup> Until more information is available, the decision to use general anesthesia or sedation must be carefully considered.

When general anesthesia or sedation is not used, young infants have an advantage over toddlers. Pulsed dye laser treatment without general anesthesia is more safely and efficiently performed in infants since the area of involvement is proportionally smaller and the patient's position and eye protection can be secured more easily.<sup>55</sup> Nevertheless, the potential impact of painful procedures must be carefully weighed. Noxious stimuli early in life may lead to short-term and possibly long-term effects in behavior, particularly toward medical care.<sup>56</sup> Parental stress and satisfaction must also be considered when making this decision.

## Conclusions

This consensus statement provides expert consensus on identification and risk stratification, optimal treatment strategies, and recommendations for light-based therapies for patients with PWBs. These recommendations are intended to help guide clinical practice and decision-making for patients with SWS and those with isolated PWBs and may improve patient outcomes.

**Author Affiliations:** Department of Dermatology, University of California, Irvine School of Medicine, Irvine (Sabeti, Kelly); The Sturge-Weber Foundation, Houston, Texas (Ball); Department of Dermatology, University of North Carolina, Chapel Hill (Burkhart); Department of Pediatric and Adolescent Dermatology, University of California, San Diego (Eichenfield); Department of Pediatric and Adolescent Dermatology, Rady Children's Hospital, San Diego, California (Eichenfield); Division of Dermatology, Department of Pediatrics, Nationwide Children's Hospital, Columbus, Ohio (Fernandez Faith); Division of Dermatology, Department of Pediatrics, The Ohio State University College of Medicine, Columbus (Fernandez Faith); Department of Dermatology, School of Medicine, University of California, San Francisco (Frieden); Department of Dermatology, New York University School of Medicine, New York (Geronemus); Laser & Skin Surgery Center of New York, New York (Geronemus); Department of Pediatrics, Division of Dermatology, Seattle Children's Hospital/University of Washington School of Medicine, Seattle (Gupta); Department of Dermatology, St Luke's University Health Network, Easton,

Pennsylvania (Krakowski); Pediatric and Adolescent Dermatology, Dell Children's Medical Center, Austin, Texas (Levy); Department of Pediatrics, Dell Medical School, University of Texas at Austin (Levy); Department of Medicine, Division of Dermatology, Dell Medical School, University of Texas at Austin (Levy); Department of Dermatology, Baylor College of Medicine, Houston, Texas (Metry); Department of Surgery, Beckman Laser Institute and Medical Clinic, University of California, Irvine (Nelson); Department of Biomedical Engineering, Beckman Laser Institute and Medical Clinic, University of California, Irvine (Nelson); Department of Dermatology and Pediatrics, Mayo Clinic, Rochester, Minnesota (Tollefson).

**Author Contributions:** Ms Sabeti and Dr Kelly had full access to all of the data in the study and take responsibility for the integrity of the data and the accuracy of the data analysis.

**Concept and design:** Sabeti, Ball, Burkhart, Fernandez Faith, Frieden, Geronemus, Krakowski, Metry, Nelson, Tollefson, Kelly.

*Acquisition, analysis, or interpretation of data:* Sabeti, Burkhart, Eichenfield, Fernandez Faith, Geronemus, Gupta, Krakowski, Levy, Metry, Kelly.

*Drafting of the manuscript:* Sabeti, Burkhart, Fernandez Faith, Geronemus, Krakowski, Levy, Metry, Nelson, Tollefson, Kelly.

*Critical revision of the manuscript for important intellectual content:* Sabeti, Ball, Burkhart, Eichenfield, Fernandez Faith, Frieden, Geronemus, Gupta, Krakowski, Levy, Metry, Kelly.

*Obtained funding:* Sabeti.

*Administrative, technical, or material support:* Sabeti, Ball, Burkhart, Geronemus, Krakowski, Levy, Nelson.

*Supervision:* Sabeti, Krakowski, Levy, Kelly.

**Conflict of Interest Disclosures:** Ms Sabeti reported receiving grants from the Sturge-Weber Foundation during the conduct of the study. Dr Frieden reported receiving personal fees from Pfizer, Venthera Biobridge, Nobel Pharmaceuticals, and Novartis outside the submitted work. Dr Kelly reported receiving personal fees from IQVIA, Shanghai Fudan-Zhangjiang Bio-Pharmaceutical Co Ltd, and Sciton; grants and other support from Sturge-Weber Foundation; nonfinancial support from Michaelson Diagnostics; and grants and other support from Allergan during the conduct of the study; other support from R2Derm outside the submitted work; and serving as an unpaid board member for the American Society for Laser Medicine and Surgery. No other disclosures were reported.

**Funding/Support:** This study was supported by the Sturge-Weber Foundation.

**Role of the Funder/Sponsor:** The Sturge-Weber Foundation played a role in the design and conduct of the study; collection, management, analysis, and interpretation of the data; preparation, review, or approval of the manuscript; and decision to submit the manuscript for publication.

**Meeting Presentation:** This paper was presented at the American Society for Laser Medicine and Surgery (ASLMS) 2020 virtual Annual Conference.

**Additional Information:** The figure was created with Avatarmaker.com for facial figure and with the Notability application for illustration.

## REFERENCES

1. De la Torre AJ, Luat AF, Juhász C, et al. A multidisciplinary consensus for clinical care and research needs for Sturge-Weber syndrome. *Pediatr Neurol*. 2018;84:11-20. doi:10.1016/j.pediatrneurol.2018.04.005
2. ShirleyMD, Tang H, Gallione CJ, et al. Sturge-Weber syndrome and port-wine stains caused by somatic mutation in GNAQ. *N Engl J Med*. 2013;368(21):1971-1979. doi:10.1056/NEJMoa1213507
3. Waelchli R, Aylett SE, Robinson K, Chong WK, Martinez AE, Kinsler VA. New vascular classification of port-wine stains: improving prediction of Sturge-Weber risk. *Br J Dermatol*. 2014;171(4):861-867. doi:10.1111/bjd.13203
4. Rosser T. Neurocutaneous disorders. *Continuum (Minneapolis, Minn)*. 2018;24(1, Child Neurology):96-129. doi:10.1212/CON.0000000000000562
5. Dutkiewicz AS, Ezzedine K, Mazereeuw-Hautier J, et al; Groupe de Recherche Clinique en Dermatologie Pédiatrique. A prospective study of risk for Sturge-Weber syndrome in children with upper facial port-wine stain. *J Am Acad Dermatol*. 2015;72(3):473-480. doi:10.1016/j.jaad.2014.11.009
6. Brightman LA, Geronemus RG, Reddy KK. Laser treatment of port-wine stains. *Clin Cosmet Investig Dermatol*. 2015;8:27-33. doi:10.2147/CCID.S53118
7. Zallmann M, Leventer RJ, Mackay MT, Ditchfield M, Bekhor PS, Su JC. Screening for Sturge-Weber syndrome: a state-of-the-art review. *Pediatr Dermatol*. 2018;35(1):30-42. doi:10.1111/pde.13304
8. KasekaML, Bitton JY, Décarie JC, Major P. Predictive factors for epilepsy in pediatric patients with Sturge-Weber syndrome. *Pediatr Neurol*. 2016; 64:52-58. doi:10.1016/j.pediatrneurol.2016.08.009
9. DymerskaM, Kirkorian AY, Offermann EA, Lin DD, Comi AM, Cohen BA. Size of facial port-wine birthmark may predict neurologic outcome in Sturge-Weber syndrome. *J Pediatr*. 2017;188:205-209.e1. doi:10.1016/j.jpeds.2017.05.053
10. Higueros E, Roe E, Granell E, Baselga E. Sturge-Weber syndrome: a review. *Actas Dermosifiliogr*. 2017;108(5):407-417. doi:10.1016/j.ad.2016.09.022
11. Chen D, Hu XJ, Lin XX, et al. Nodules arising within port-wine stains: a clinicopathologic study of 31 cases. *Am J Dermatopathol*. 2011;33(2):144-151. doi:10.1097/DAD.0b013e3181e169f5
12. Sanchez-Carpintero I, Mihm MC, Mizeracki A, Waner M, North PE. Epithelial and mesenchymal hamartomatous changes in a mature port-wine stain: morphologic evidence for a multiple germ layer field defect. *J Am Acad Dermatol*. 2004;50 (4):608-612. doi:10.1016/j.jaad.2003.04.002
13. Nguyen V, Hochman M, Mihm MC Jr, Nelson JS, TanW. The pathogenesis of port wine stain and SturgeWeber syndrome: complex interactions between genetic alterations and aberrant MAPK and PI3K activation. *Int J Mol Sci*. 2019;20(9):E2243. doi:10.3390/ijms20092243
14. Fonder MA, Mamelak AJ, Kazin RA, Cohen BA. Port-wine-stain-associated dermatitis: implications for cutaneous vascular laser therapy. *Pediatr Dermatol*. 2007;24(4):376-379. doi:10.1111/j.1525-1470.2007.00453.x
15. Hagen SL, Grey KR, Korta DZ, Kelly KM. Quality of life in adults with facial port-wine stains. *J Am Acad Dermatol*. 2017;76(4):695-702. doi:10.1016/j.jaad.2016.10.039
16. Shahriari M, Makkar H, Finch J. Laser therapy in dermatology: kids are not just little people. *Clin Dermatol*. 2015;33(6):681-686. doi:10.1016/j.clindermatol.2015.09.010
17. Updyke KM, Khachemoune A. Port-wine stains: a focused review on their management. *J Drugs Dermatol*. 2017;16(11):1145-1151.
18. Izikson L, Nelson JS, Anderson RR. Treatment of hypertrophic and resistant port wine stains with a 755 nm laser: a case series of 20 patients. *Lasers Surg Med*. 2009;41(6):427-432. doi:10.1002/lsm.20793
19. McGill DJ, MacLarenW, Mackay IR. A direct comparison of pulsed dye, alexandrite, KTP and

- Nd:YAG lasers and IPL in patients with previously treated capillary malformations. *Lasers Surg Med.* 2008;40(6):390-398. doi:10.1002/lsm.20638
20. Tierney EP, Hanke CW. Alexandrite laser for the treatment of port wine stains refractory to pulsed dye laser. *Dermatol Surg.* 2011;37(9):1268-1278. doi:10.1111/j.1524-4725.2011.02079.x
21. Carlsen BC, Wenande E, Erlendsson AM, Faurichou A, Dierickx C, Haedersdal M. A randomized side-by-side study comparing alexandrite laser at different pulse durations for port wine stains. *Lasers Surg Med.* 2017;49(1):97-103. doi:10.1002/lsm.22532
22. Bae YC, Alabdulrazzaq H, Brauer JA, Geronemus RG. Treatment of recalcitrant port-wine stains (PWS) using a combined pulsed dye laser (PDL) and radiofrequency (RF) energy device. *J Am Acad Dermatol.* 2017;76(2):321-326. doi:10.1016/j.jaad.2016.03.004
23. Toren KL, Marquart JD. Fractional thermoablation using an erbium-doped yttrium aluminum garnet fractionated laser for the treatment of pulsed dye laser-resistant port wine stain birthmarks. *Dermatol Surg.* 2011;37(12):1791-1794. doi:10.1111/j.1524-4725.2011.02160.x
24. Groopman J. *The Anatomy of Hope: How People Prevail in the Face of Illness.* Random House Publishing Group; 2003.
25. Fitzpatrick RE, Lowe NJ, Goldman MP, Borden H, Behr KL, Ruiz-Esparza J. Flashlamp-pumped pulsed dye laser treatment of port-wine stains. *J Dermatol Surg Oncol.* 1994;20(11):743-748. doi:10.1111/j.1524-4725.1994.tb03197.x
26. Yu W, Ma G, Qiu Y, et al. Why do port-wine stains (PWS) on the lateral face respond better to pulsed dye laser (PDL) than those located on the central face? *J Am Acad Dermatol.* 2016;74(3):527-535. doi:10.1016/j.jaad.2015.08.026
27. Khandpur S, Sharma VK. Assessment of efficacy of the 595-nm pulsed dye laser in the treatment of facial port-wine stains in Indian patients. *Dermatol Surg.* 2016;42(6):717-726. doi:10.1097/DSS.0000000000000723
28. Woo SH, Ahn HH, Kim SN, Kye YC. Treatment of vascular skin lesions with the variable-pulse 595 nm pulsed dye laser. *Dermatol Surg.* 2006;32(1):41-48. doi:10.1097/00042728-200601000-00007
29. Shi W, Wang J, Lin Y, et al. Treatment of port wine stains with pulsed dye laser: a retrospective study of 848 cases in Shandong Province, People's Republic of China. *Drug Des Dev Ther.* 2014;8:2531-2538. doi:10.2147/DDDT.S71710
30. Lipner SR. Topical adjuncts to pulsed dye laser for treatment of port wine stains: review of the literature. *Dermatol Surg.* 2018;44(6):796-802. doi:10.1097/DSS.0000000000001507
31. Passeron T, Maza A, Fontas E, et al. Treatment of port wine stains with pulsed dye laser and topical timolol: a multicenter randomized controlled trial. *Br J Dermatol.* 2014;170(6):1350-1353. doi:10.1111/bjd.12772
32. Marqués L, Núñez-Córdoba JM, Aguado L, et al. Topical rapamycin combined with pulsed dye laser in the treatment of capillary vascular malformations in Sturge-Weber syndrome: phase II, randomized, double-blind, intraindividual placebo-controlled clinical trial. *J Am Acad Dermatol.* 2015;72(1):151-158.e1. doi:10.1016/j.jaad.2014.10.011
33. Musalem HM, Alshaikh AA, Tuleimat LM, Alajlan S. Outcome with topical sirolimus for port wine stain malformations after unsatisfactory results with pulse dye laser treatment alone. *Ann Saudi Med.* 2018;38(5):376-380. doi:10.5144/0256-4947.2018.376
34. Li-Qiang G, Hua W, Si-Li N, Chun-Hua T. A clinical study of HMME-PDT therapy in Chinese pediatric patients with port-wine stain. *Photodiagnosis Photodyn Ther.* 2018;23:102-105. doi:10.1016/j.pdpdt.2018.06.006
35. Wu Q, Tu P, Zhou G, et al. A dose-finding study for hemoporphin in photodynamic therapy for port-wine stain: a multicenter randomized double-blind phase IIb trial. *Photodermatol Photoimmunol Photomed.* 2018;34(5):314-321. doi:10.1111/phpp.12384
36. Zhao Y, Tu P, Zhou G, et al. Hemoporphin photodynamic therapy for port-wine stain: a randomized controlled trial. *PLoS One.* 2016;11(5): e0156219. doi:10.1371/journal.pone.0156219

37. Anolik R, Newlove T, Weiss ET, et al. Investigation into optimal treatment intervals of facial port-wine stains using the pulsed dye laser. *J Am Acad Dermatol.* 2012;67(5):985-990. doi:10.1016/j.jaad.2011.11.964
38. Swan BC, Robertson SJ, Tuxen A, et al. Pulsed dye laser treatment of capillary malformations in infants at 2-weekly versus 3-monthly intervals, reducing the need for general anaesthesia. *Australas J Dermatol.* 2017;58(3):214-218. doi:10.1111/ajd.12457
39. Tomson N, Lim SPR, Abdullah A, Lanigan SW. The treatment of port-wine stains with the pulsed-dye laser at 2-week and 6-week intervals: a comparative study. *Br J Dermatol.* 2006;154(4): 676-679. doi:10.1111/j.1365-2133.2005.07113.x
40. Yu W, Zhu J, Changc SJ, et al. Shorter treatment intervals of East Asians with port-wine stain with pulsed dye laser are safe and effective—a prospective side-by-side comparison. *Photomed Laser Surg.* 2018;36(1):37-43. doi:10.1089/pho.2017.4315
41. Liu X, Fan Y, Huang J, et al. Can we predict the outcome of 595-nm wavelength pulsed dye laser therapy on capillary vascular malformations from the first beginning: a pilot study of efficacy co-related factors in 686 Chinese patients. *Lasers Med Sci.* 2015;30(3):1041-1046. doi:10.1007/s10103-014-1695-0
42. Morelli JG, Weston WL, Huff JC, Yohn JJ. Initial lesion size as a predictive factor in determining the response of port-wine stains in children treated with the pulsed dye laser. *Arch Pediatr Adolesc Med.* 1995;149(10):1142-1144. doi:10.1001/archpedi.1995.02170230096014
43. Nguyen CM, Yohn JJ, Huff C, Weston WL, Morelli JG. Facial port wine stains in childhood: prediction of the rate of improvement as a function of the age of the patient, size and location of the port wine stain and the number of treatments with the pulsed dye (585 nm) laser. *Br J Dermatol.* 1998;138(5):821-825. doi:10.1046/j.1365-2133.1998.02219.x
44. Ashinoff R, Geronemus RG. Flash lamp pumped pulsed dye laser for port-wine stains in infancy: earlier versus later treatment. *J Am Acad Dermatol.* 1991;24(3):467-472. doi:10.1016/0190-9622(91)70075-D
45. Lee JW, Chung HY, Cerrati EW, O TM, Waner M. The natural history of soft tissue hypertrophy, bony hypertrophy, and nodule formation in patients with untreated head and neck capillary malformations. *Dermatol Surg.* 2015;41(11):1241-1245. doi:10.1097/DSS.0000000000000525
46. Minkis K, Geronemus RG, Hale EK. Port wine stain progression: a potential consequence of delayed and inadequate treatment? *Lasers Surg Med.* 2009;41(6):423-426. doi:10.1002/lsm.20788
47. Masnari O, Schiestl C, Rössler J, et al. Stigmatization predicts psychological adjustment and quality of life in children and adolescents with a facial difference. *J Pediatr Psychol.* 2013;38(2):162-172. doi:10.1093/jpepsy/jss106
48. Levine VJ, Geronemus RG. Adverse effects associated with the 577- and 585-nanometer pulsed dye laser in the treatment of cutaneous vascular lesions: a study of 500 patients. *J Am Acad Dermatol.* 1995;32(4):613-617. doi:10.1016/0190-9622(95)90346-1
49. Chiu CH, Chan HHL, HoWS, Yeung CK, Nelson JS, Tsai RY. Prospective study of pulsed dye laser in conjunction with cryogen spray cooling for treatment of port wine stains in Chinese patients. *Dermatol Surg.* 2003;29(9):909-915. doi:10.1046/j.1524-4725.2003.29255.x
50. Feldstein S, Totri CR, Friedlander SF. Can long-term alopecia occur after appropriate pulsed-dye laser therapy in hair-bearing sites? pediatric dermatologists weigh in. *Dermatol Surg.* 2015;41(3):348-351. doi:10.1097/DSS.0000000000000284
51. Kouba DJ, LoPiccolo MC, Alam M, et al. Guidelines for the use of local anesthesia in office-based dermatologic surgery. *J Am Acad Dermatol.* 2016;74(6):1201-1219. doi:10.1016/j.jaad.2016.01.022
52. Cohen MM, Cameron CB, Duncan PG. Pediatric anesthesia morbidity and mortality in the perioperative period. *Anesth Analg.* 1990;70(2):160-167. doi:10.1213/00000539-199002000-00005
53. Habre W, Disma N, Virag K, et al; APRICOT Group of the European Society of Anaesthesiology

Clinical Trial Network. Incidence of severe critical events in paediatric anaesthesia (APRICOT): a prospective multicentre observational study in 261 hospitals in Europe. *Lancet Respir Med*. 2017;5(5):412-425. doi:10.1016/S2213-2600(17)30116-9

54. Orser BA, Suresh S, Evers AS. SmartTots update regarding anesthetic neurotoxicity in the developing brain. *Anesth Analg*. 2018;126(4):1393-1396. doi:10.1213/ANE.0000000000002833

55. Jeon H, Bernstein LJ, Belkin DA, Ghalili S, Geronemus RG. Pulsed dye laser treatment of port-wine stains in infancy without the need for general anesthesia. *JAMA Dermatol*. 2019;155(4):435-441. doi:10.1001/jamadermatol.2018.5249

56. Mathes EF, Frieden IJ. Early use of laser for port-wine stains: timing, efficacy, and shared decision making. *JAMA Dermatol*. 2019;155(4):421-423. doi:10.1001/jamadermatol.2018.5189

**Corresponding Author:** Kristen M. Kelly, MD, University of California, Irvine, 118 Medical Surge I, Mail Code:1475, Irvine, CA 92697 (kmkelly@uci.edu).