

# UC Davis

## Dermatology Online Journal

### Title

Zosteriform mycosis fungoides: case report of progression to tumor stage and review of the literature

### Permalink

<https://escholarship.org/uc/item/67p062p2>

### Journal

Dermatology Online Journal, 30(4)

### Authors

Hida, Yasutoshi  
Iwawaki, Ayaka  
Fujii, Yoshiyuki  
[et al.](#)

### Publication Date

2024

### DOI

10.5070/D330464112

### Copyright Information

Copyright 2024 by the author(s). This work is made available under the terms of a Creative Commons Attribution-NonCommercial-NoDerivatives License, available at <https://creativecommons.org/licenses/by-nc-nd/4.0/>

Peer reviewed

# Zosteriform mycosis fungoides: case report of progression to tumor stage and review of the literature

Yasutoshi Hida<sup>1</sup> MD PhD, Ayaka Iwawaki<sup>1</sup> MD, Yoshiyuki Fujii<sup>2</sup> MD PhD, Kyosuke Osaki<sup>3</sup> MD

Affiliations: <sup>1</sup>Division of Dermatology, Tokushima Red Cross Hospital, Tokushima, Japan, <sup>2</sup>Division of Diagnostic Pathology, Tokushima Red Cross Hospital, Tokushima, Japan, <sup>3</sup>Division of Radiology, Tokushima Red Cross Hospital, Tokushima, Japan

Corresponding Author: Yasutoshi Hida, Division of Dermatology, Tokushima Red Cross Hospital, 773-8502, Tokushima Komatsushima, Komatsushima-cho, Irinoguchi 103, Japan, Tel: 885-32-2555, Fax: 885-32-0719, Email: [yasutoshi@ae.auone-net.jp](mailto:yasutoshi@ae.auone-net.jp)

## Abstract

Mycosis fungoides (MF) is the most common type of cutaneous T-cell lymphoma, although it has many clinicopathological variants. Zosteriform MF is an extremely rare variant characterized by dermatomal distribution. To date, only six patients with zosteriform MF have been reported. We report a 57-year-old man with tumor-stage zosteriform MF localized on the left T4, T7-8, and bilateral L4 dermatomes for seven years after the first visit. Local skin-target therapy radiotherapy effectively led to complete remission, which was maintained with a combination of oral etretinate (30mg/day) and narrow-band ultraviolet B phototherapy. No other reports exist of zosteriform MF occurring in multiple dermatomes. We reviewed the literature to add to our understanding of the nature of rare variants of MF and discuss therapeutic options for zosteriform MF.

*Keywords: dermatome, herpes zoster, mycosis fungoides, radiotherapy, zosteriform*

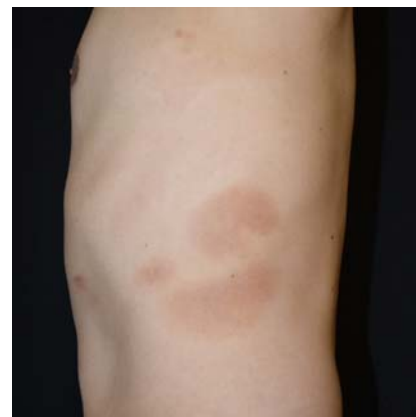## Introduction

Mycosis fungoides (MF) is the most common cutaneous T-cell lymphoma (CTCL) and generally has an indolent course. Most cases gradually progress over several decades from the erythematous to the plaque stage and finally to the tumor stage. Multiple lesions are typically observed throughout the body. However, atypical MF variants also occur. Zosteriform MF is an extremely rare variant of MF, characterized by lesions that occur in a dermatomal

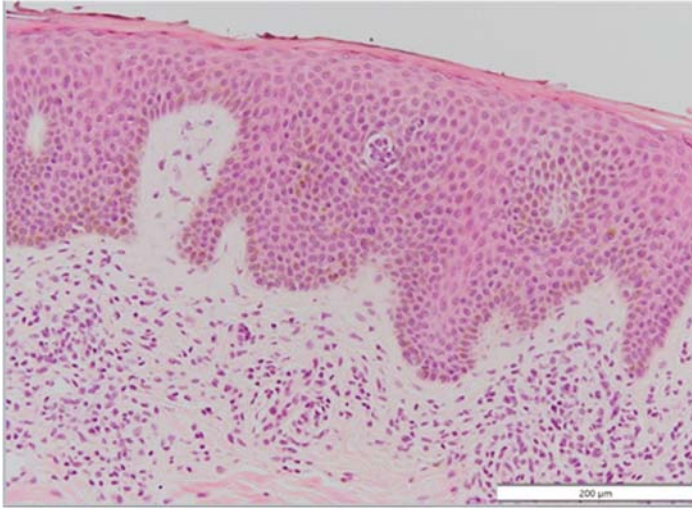
distribution and histopathological features indistinguishable from those of usual MF [1]. We present a patient with tumor-stage MF that localized to several dermatomes seven years after initial diagnosis.

## Case Synopsis

A 57-year-old man presented with a one-year history of asymptomatic scaly erythematous patches on the left flank and bilateral dorsal lower legs with less than 10% body surface involvement (**Figure 1**). Skin biopsy revealed relatively large atypical lymphocytes and a paucity of spongiosis (**Figure 2**). CD3 and CD4 staining were positive for intraepidermal atypical lymphocytes. CD7 and CD8 reactivities were less robust and were mainly restricted to dermal lymphocytes. Staging showed no involvement of the visceral organs or peripheral blood, which indicated stage IA. We treated the patient with narrow-band ultraviolet B (nUVB) phototherapy once every two weeks along with topical corticosteroid therapy



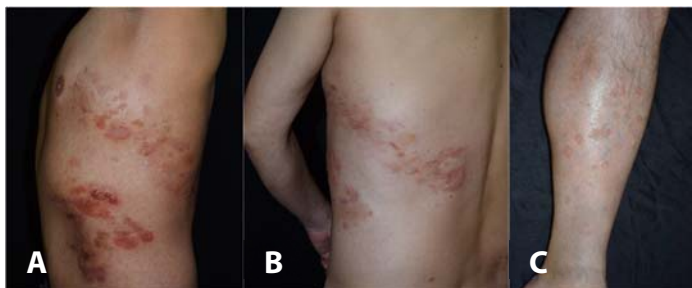**Figure 1.** Erythematous patches on the left flank.



**Figure 2.** Atypical lymphocytes with a paucity of spongiosis in a biopsy from the left flank. H&E, 100x.

(betamethasone butyrate propionate and, clobetasol propionate), which resulted in a decrease in MF patches. However, new MF patches continued to appear on limited dermatomes of the left flank, back, and bilateral lower legs. Nonetheless, the patient continued to respond well to this regimen for six years. After time, red plaques and tumors appeared from the left flank to the back, similar to the zosteriform distribution (left T4, T7-8 dermatome), (**Figure 3A, B**). The only patches without plaques or tumors were on the dorsal lower legs (bilateral L4 dermatome), (**Figure 3C**). A second incisional biopsy of the tumor revealed small atypical lymphocyte proliferation with large lymphocytes (10% of the total cell population), (**Figure 4**).

Immunohistochemical analysis revealed that these small atypical lymphocytes were positive for both CD3 and CD4 and that the large lymphocytes were CD30 positive. Southern blot analysis, using a T cell receptor beta-chain probe, revealed a new band of rearranged DNA, which confirmed monoclonality.

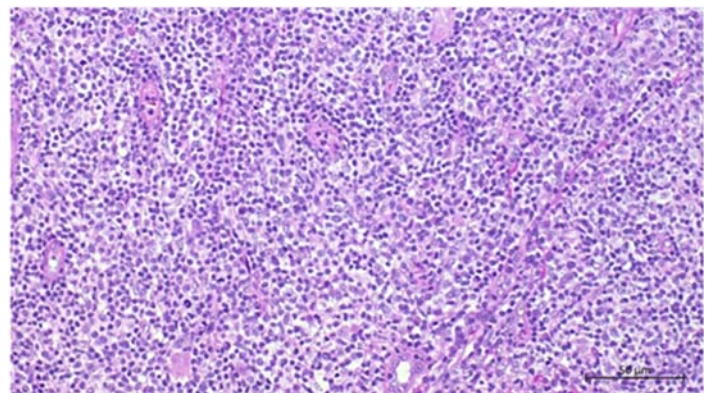


**Figure 3.** **A)** Red plaques and tumors on the left flank, **B)** back. **C)** Erythematous patches on the dorsal lower legs.

Re-staging showed no involvement of the visceral organs or peripheral blood, which indicated stage IIB. We initiated treatment with a histone deacetylase inhibitor (vorinostat 400mg/day) in addition to nUVB phototherapy he was already receiving. Vorinostat partially shrank the plaques and tumors; it was discontinued after the patient developed renal dysfunction. At that time, we discontinued nUVB phototherapy and treated the plaques and tumors on the left flank with local radiotherapy (2Gy, 12 fractions). These lesions progressively became less indurated and cleared completely after a few weeks. We then initiated etretinate at 30mg/day and re-started nUVB phototherapy. Subsequently, patches on both legs resolved. Currently, the patient remains clear, with no evidence of lesion recurrence.

## Case Discussion

Zosteriform and epidermotropic cutaneous metastases have been observed in oncology patients [2]. Zosteriform MF is defined as a lesion occurring in the dermatome. To the best of our knowledge, there have been seven reports of zosteriform MF or CTCL, including the present case (**Table 1**), [3-8]. The average age at the first visit was 57 years (range 21, 86 years). All patients underwent skin biopsy; six patients were diagnosed with MF and one patient (case 2) was diagnosed with CTCL. However, the reported histological features revealed epidermotropism and microabscesses, therefore we considered Case 2 to be MF. The cause of death in one patient (Case1), an 86-year-old man who died



**Figure 4.** Histology of biopsy of a tumor from the left flank. Small atypical lymphocyte proliferation with large lymphocytes as 10% of total cell population. H&E, 40x.

**Table 1.** Summary of the reported cases of zosteriform mycosis fungoides or primary cutaneous T-cell lymphoma.

Case	Age/sex	Location	Duration* (months)	Treatment	Follow-up (months)	Ref
1	86/M	Left neck, shoulder (C5)	2	Radiotherapy	4 (Death)	[3]
2	66/F	Right chest	24	Excision	12 (NED)	[4]
3	21/F	Right abdomen, flank, back (T10)	18	Topical steroid	9 (LR)	[5]
4	55/M	Right upper thigh (L2-3)	48	Topical steroid	4 (PR)	[6]
5	69/F	Left chest, arm back (T1)	1	Valacyclovir	166 (LR)	[7]
6	45/M	Right abdomen and back	unknown	MTX 10mg/week, Topical steroid	1 (NED)	[8]
7	57/M	Left flank and back (T4, T7-8), bilateral legs (L4)	12	Topical steroid, nUVB, vorinostat, radiotherapy, oral etretinate	84 (NED)	Current report

\*Duration: between onset and first visit.

LR, local recurrence, MTX, methotrexate, NED, no evidence of disease, nUVB, narrow-band ultraviolet B, PR, partial response.

four months after the initial presentation, was not described in detail. Six patients, (all except Case 1), had a chronic indolent course. In five of the seven cases, the eruptions were distributed in the dermatomal lesions of the trunk, because the trunk has a large area and a relatively large number of dermatomes. Except for our patient, all patients had a single dermatome.

Other variants of MF that occur in a localized areas are unilesional MF and localized pagetoid reticulosis (Woringer-Kolopp disease), clinically characterized by a solitary lesion with no evidence of non-contiguous spread over long periods [9-10]. Although zosteriform MF affects a larger area than unilesional MF or localized pagetoid reticulosis, the lesions that occur in localized areas are the same. The recommended therapy for unilesional MF is local radiotherapy, because the vast majority of cases treated with this skin-targeted therapy show no recurrence during long-term follow-up periods [11-13]. Micaily et al. reported the usefulness of radiotherapy for unilesional MF. The authors treated 18 patients with unilesional MF using local radiotherapy and achieved a complete response rate of 100% [13]. Based on these results, we attempted local radiotherapy for the left T4, T7, and T8 dermatomes. However, the patient did not wish for local radiotherapy to be administered to both legs. To date, complete remission has been achieved with a combination of nUVB phototherapy and oral etretinate. Therefore, we consider local radiotherapy to be viable treatment options for zosteriform MF.

Several other cutaneous lesions have been reported to have zosteriform or dermatomal patterns. Eruptions that may display this distribution include herpes zoster, herpes simplex, lichen striatus, lichen planus, verruca plana, linear epidermal nevus, and syringomas. The mechanism of the dermatomal distribution in MF remains unclear. Although our patient did not experience herpes zoster, two of the previously reported cases developed zosteriform MF at the site of a previous herpes zoster eruption [6, 8]. Williams et al. postulated that zosteriform MF represents a "Koebner-like" reaction at the site of a previously unrecognized herpes zoster infection [3]. This reaction may diminish immunological resistance against MF cells. Herpes-infected areas are also known to be sites for the developing of neoplasms [14]. This phenomenon has lately been included into the concept of the 'immunocompromised cutaneous district' [14-16]. After the herpes zoster infection had disappeared, the affected skin region may appear clinically normal, but its immune behavior is often compromised, prone to developing neoplasms. An alternative possibility is perineural lymphatic invasion or fenestrated vasculature of the dorsal root ganglion.

Two patients with zosteriform MF were diagnosed as herpes zoster at their first visit [4, 8]. However, not all cases that follow a dermatome are herpes zoster. Therefore, other cutaneous diseases must be considered in the differential diagnosis. When the presenting lesions are not typical vesicles, biopsy is

indicated to rule out other diseases, especially cutaneous malignancies.

## Conclusion

Zosteriform MF is an extremely rare variant of MF. We recommend local radiotherapy as a skin-targeted

therapy for this variant of MF. An accumulation of cases will help to elucidate the pathogenesis of zosteriform MF.

## Potential conflicts of interest

The authors declare no conflicts of interest.

## References

1. Abdelmaksoud A, Vestita M, Lotti T. Valacyclovir as a potential therapy for mycosis fungoides and vitiligo in a zosteriform pattern. *Dermatol Ther*. 2019;32:e12870. [PMID: 30838701].
2. Manteaux A, Cohen PR, Rapini RP. Zosteriform and epidermotropic metastasis. Report of two cases. *J Dermatol Surg Oncol*. 1992;18:97-100. [PMID: 1537956].
3. Williams LR, Levine LJ, Kauh YC. Cutaneous malignancies mimicking herpes zoster. *Int J Dermatol*. 1991;30:432-434. [PMID: 1894409].
4. Ricci RM, Latham PL, Song V, Mullins D. Zosteriform cutaneous T-cell lymphoma. *J Am Acad Dermatol*. 1995;32:127-128. [PMID: 7822504].
5. Rieger KE, Kim J, Kim YH. Zosteriform mycosis fungoides: A new clinical presentation with a dermatomal distribution. *Am J Dermatopathol*. 2017;39:e17-e18. [PMID: 28134736].
6. Huang S, Kim EJ, Lewis DJ, et al. Mycosis fungoides occurring at the site of previous herpes zoster eruption. *Australas J Dermatol*. 2018;59:217-219. [PMID: 29280139].
7. Lewis DJ, Hinojosa T, Chan WH, et al. Successful suppression of recurrent zosteriform mycosis fungoides with maintenance valacyclovir. *Actas Dermosifiliogr*. 2018;109:757-760. [PMID: 29499833].
8. Zhao P, Gish TJ, Mannschreck D, et al. Zosteriform mycosis fungoides and lymphomatoid papulosis arising in an area of prior herpes zoster. *JAAD Case Rep*. 2023;40:84-88. [PMID: 37771361].
9. Oliver GF, Wikelmann RK. Unilesional mycosis fungoides: A distinct entity. *J Am Acad Dermatol*. 1989;20:63-70. [PMID: 2783594].
10. Matsuzaki Y, Kimura K, Nakano H, et al. Localized pagetoid reticulosis (Woringer-Kolopp disease) in early childhood. *J Am Acad Dermatol*. 2009;61:120-123. [PMID: 19539847].
11. PW Heald, EJ Glusac. Unilesional cutaneous T-cell lymphoma: Clinical features, therapy, and follow-up of 10 patients with a treatment-responsive mycosis fungoides variant. *J Am Acad Dermatol*. 2000;42:283-285. [PMID: 10642687].
12. Ally MS, Rawade J, Tanaka M, et al. Solitary mycosis fungoides: A distinct clinicopathologic entity with a good prognosis. *J Am Acad Dermatol*. 2012;65:736-744. [PMID: 2233993].
13. Micaily B, Miyamoto C, Kantor G, et al. Radiotherapy for unilesional mycosis fungoides. *Int J Radiat Oncol Biol Phys*. 1998;42:361-364. [PMID: 9788416].
14. Caccavale S, Kannangara AP, Ruocco E. The immunocompromised cutaneous district and the necessity of a new classification of its disparate causes. *Indian J Dermatol Venereol Leprol*. 2016;82:227-229. [PMID: 26924409].
15. Ruocco E, Di Maio R, Caccavale S, et al. Radiation dermatitis, burns, and recall phenomena: Meaning instances of immunocompromised district. *Clin Dermatol*. 2014;32:660-669. [PMID: 25160108].
16. Vojvodic A, Tirant M, Nardo VD, et al. Immunocompromised district of skin: A case series and a literature review. *Open Access Maced J Med Sci*. 2019;7:2969-2975. [PMID: 31850101].