

UC Davis

Dermatology Online Journal

Title

Blastic plasmacytoid dendritic cell neoplasm presenting as violaceous forehead plaque

Permalink

<https://escholarship.org/uc/item/66w875t5>

Journal

Dermatology Online Journal, 28(4)

Authors

Morrison, Georgia Mae
Hopkins, Amy
Knapp, Calvin
et al.

Publication Date

2022

DOI

10.5070/D328458522

Copyright Information

Copyright 2022 by the author(s). This work is made available under the terms of a Creative Commons Attribution-NonCommercial-NoDerivatives License, available at <https://creativecommons.org/licenses/by-nc-nd/4.0/>

Peer reviewed

Blastic plasmacytoid dendritic cell neoplasm presenting as violaceous forehead plaque

Georgia Mae Morrison¹ BS, Amy Hopkins¹ MD PhD, Calvin Knapp¹ MD, Raj Kulkarni¹ MD PhD, John P Scopetta² MD

Affiliations: ¹Department of Dermatology, Oregon Health & Science University, Portland, Oregon USA, ²Department of Pathology, Portland Oregon Veterans Affairs Medical Center, Portland, Oregon USA

Corresponding Author: Georgia Mae Morrison, Department of Dermatology, Oregon Health & Science University, 3303 South Bond Avenue, Building 1, Portland, OR 97239-3098, Tel: 406-868-4070, Email: [morrissog@ohsu.edu](mailto:morrisog@ohsu.edu); Raj Kulkarni MD PhD, Department of Dermatology, Oregon Health & Science University, 3303 South Bond Avenue, Building 1, Portland, OR 97239-3098, Email: kulkarnr@ohsu.edu

Abstract

A 72-year-old man with a history of squamous cell carcinoma presented to the Portland VA with forehead discoloration. He was initially diagnosed with actinic damage and prescribed topical treatment. However, he returned to clinic months later with a large, violaceous forehead plaque. Upon biopsy, he was diagnosed with blastic plasmacytoid dendritic cell neoplasm, a rare hematological malignancy. This case report illustrates the importance of keeping blastic plasmacytoid dendritic cell neoplasm in the differential diagnosis for ecchymotic plaques that fail to respond to first line therapy.

Keywords: blastic, cutaneous lymphoma, dendritic cell, dermatology, neoplasm, plasmacytoid

Introduction

Blastic plasmacytoid dendritic cell neoplasm (BPDCN) is a rare hematological malignancy that arises from plasmacytoid dendritic cell precursors [1]. The presentation of this disorder is highly heterogeneous and has a high frequency of cutaneous and bone marrow involvement [1]. Skin manifestations are often the first symptoms that cause a patient to seek medical care and these can precede leukemic spread [1,2]. Dermatological presentations vary between bruise-like macules to

isolated violaceous nodules and may be limited and focal or diffuse [3]. This range of clinical presentations sometimes creates a diagnostic pitfall, with BPDCN being mistaken for traumatic purpura, inflammatory conditions such as contact dermatitis, or leukemia cutis [2]. The prognosis for BPDCN is poor, and diagnostic delay can prevent patients from receiving early and aggressive treatment, which is the only approach shown to improve outcomes [2,3]. We present a case of BPDCN presenting as a violaceous plaque on the forehead in an otherwise asymptomatic man.

Case Synopsis

A 72-year-old man with a history of squamous cell carcinoma presented to the Portland Veterans Affairs Medical Center for forehead discoloration in February 2020. Initially, he was diagnosed with actinic damage and prescribed fluorouracil cream. By July 2020, he developed a red-to-violaceous scaly plaque and we recommended hydrocortisone 2.5% ointment for irritant versus allergic contact dermatitis. In October 2020, he returned to clinic concerned about the "lump on his forehead" (**Figure 1**).

Punch biopsy demonstrated a dermal infiltrate of large dyscohesive cells. H&E staining revealed a dermis that was filled and expanded by the tumor cells (**Figure 2**). Further staining demonstrated

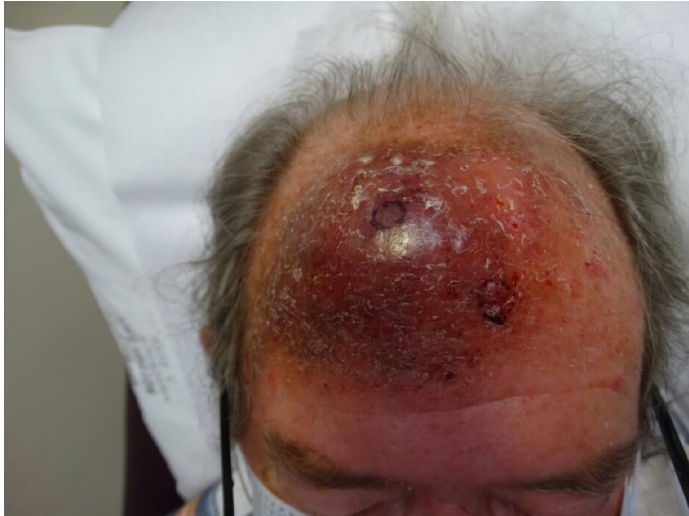

Figure 1. Violaceous forehead plaque on patient's forehead in October 2020.

positive expression of CD4, CD56, and CD123 (**Figure 3**). Subsequent bone marrow biopsy showed mildly hypercellular bone marrow (50% cellularity) with myeloid predominant trilineage hematopoiesis. Blasts were less than 5%. There was mild megakaryocytic hyperplasia and clustering. Flow cytometry demonstrated atypical plasmacytoid dendritic cell population (0.5% of CD45+ events) with a normal karyotype. These cells exhibited aberrant expression of CD56, CD7, and CD33.

Treatment was initiated with tagraxofusp 12mcg/kg (1000mg daily) in December 2020. The patient underwent five rounds of targeted therapy, which was complicated by atrial fibrillation, elevated liver enzymes, thrombocytopenia, and a drop in albumin. Due to new development of atrial fibrillation with sinus pause during his first treatment, amiodarone was initiated briefly and then replaced with metoprolol 200mg and apixaban following

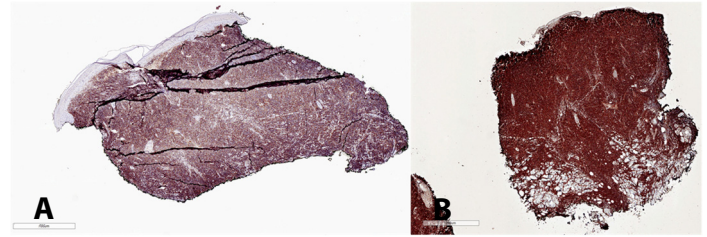


Figure 3. Punch biopsy of the scalp with immunostaining **A)** demonstrating strong positivity for CD4, 250x, **B)** demonstrating strong positive staining for CD56, 250x, **C)** demonstrating strong positive staining for CD123, 250x.

detection of elevated liver enzymes. A pacemaker was eventually placed due to refractory atrial fibrillation from the tagraxofusp. It was believed that capillary leak syndrome, a side effect of tagraxofusp, predisposed the patient to atrial fibrillation with sinus pause. A second bone marrow biopsy following cycle 5 showed persistent but decreased percentage of blastic plasmacytoid dendritic cells. His forehead plaque was re-biopsied in March 2021 and showed residual disease. He is currently receiving azacitidine and venetoclax treatments while awaiting eligibility for a clinical trial.

Case Discussion

Blastic plasmacytoid dendritic cell neoplasm is a rare and life-threatening hematologic malignancy. Blastic plasmacytoid dendritic cell neoplasm has several former names including CD4+CD56+ hematodermic neoplasm and blastic natural killer cell lymphoma. In 2008, the World Health Organization clarified the cell of origin and it is now classified as a distinct clinical disease of malignant proliferation of a contingent blastic plasmacytoid dendritic cell [1,3]. It is considered a subtype of acute myeloid leukemia and

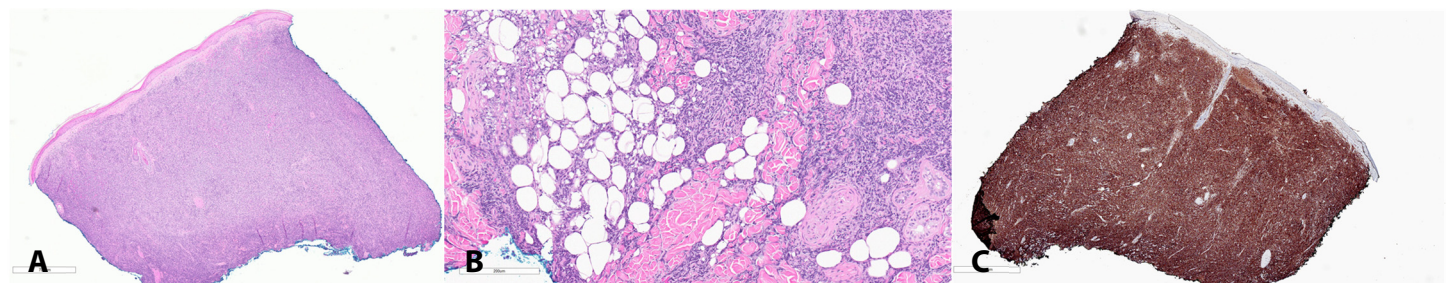


Figure 2. Punch biopsy of the scalp with H&E staining showing **A)** tumor cells filling and expanding the dermis, 35x, **B)** tumor cells in the dermis as well as possibly in the periadnexal fat, 150x.

related neoplasms and represents approximately 0.8% of primary cutaneous lymphomas [3,4]. Phenotypically, it is characterized by the expression of CD4, CD56, CD123, blood dendritic cell antigen (BDCA)2, T-Cell leukemia/lymphoma (TCL)1, and B-cell lymphoma/leukemia (BCL)11A [3]. A common entity in the histologic differential includes myeloid sarcoma, which is typically lysozyme and myeloperoxidase (MPO) positive and may also be positive for CD56 [5].

Plasmacytoid dendritic cells comprise less than 0.5% of circulating mononuclear cells and are classically found in lymph nodes and tonsils [6]. They are absent in healthy skin, but in certain dermatological conditions such as contact dermatitis and lupus erythematosus, they are recruited to the skin where they secrete massive amounts of IFN1, IFNalpha, and IFNbeta [2].

Blastic plasmacytoid dendritic cell neoplasm classically affects older white men, with a median age range of 53 to 68 years of age and a two to 3.3:1 male to female ratio [6]. However, there have been reports of pediatric cases and recent research suggests a bimodal age distribution, affecting individuals younger than 20 or older than 60 at higher frequencies [6,7]. As previously stated, the skin is the first organ involved in most cases of BPDCN with variable presentation, but there can also be involvement of bone marrow, central nervous system, lung, breast, gallbladder, and paranasal sinuses [6]. A skin biopsy is key to making the diagnosis and initiating treatment [2]. Early diagnosis is needed as generally, BPDCN has a poor prognosis with a median survival rate of only 8 to 14 months [1-3]. There is emerging evidence that a bone marrow transplant following complete remission can lead to long term survival [1,3,6].

A targeted agent called tagraxofusp was recently approved by the Food and Drug Administration in

2018 for treatment of BPDCN in patients two years of age or older [8]. Tagraxofusp is a CD123-directed cytotoxin that consists of recombinant human interleukin-3 fused to a truncated diphtheria toxin [8]. When tagraxofusp binds to CD123 on the pDC surface, the diphtheria toxin is internalized, halts protein synthesis, and induces apoptosis [9]. In one clinical trial involving 47 patients, previously untreated individuals had a 90% overall response rate and previously treated individuals had a 67% overall response rate, leading to a meaningful increase in survival [8]. Tagraxofusp allowed more patients to be bridged to hematopoietic stem cell transplant once in remission [8]. However, tagraxofusp is far from benign with potential for severe side effects including capillary leak syndrome, hepatic dysfunction, and thrombocytopenia, two of which were seen in our patient [8]. Capillary leak syndrome, in particular, may be fatal and may present with hypoalbuminemia, weight gain, edema, hypotension, or hemodynamic instability [8,9]. These signs and symptoms should be monitored in patients taking tagraxofusp for their BPDCN.

Conclusion

Our patient demonstrates a typical presentation of BPDCN and highlights how clinical presentation may mimic inflammatory conditions. Keeping BPDCN in the differential diagnosis for singular or diffuse red-to-violaceous scaly or ecchymotic plaques which fail to respond to standard first line therapies may lead to earlier diagnosis and improved outcomes of BPDCN.

Potential conflicts of interest

The authors declare no conflicts of interest.

References

1. Pagano L, Valentini CG, Grammatico S, Pulsoni A. Blastic plasmacytoid dendritic cell neoplasm: diagnostic criteria and therapeutic approaches. *Br J Haematol*. 2016;174:188-202. [PMID: 27264021].
2. Hirner JP, O'Malley JT, LeBoeuf NR. Blastic Plasmacytoid Dendritic Cell Neoplasm: The Dermatologist's Perspective. *Hematol Oncol Clin North Am*. 2020;34:501-509. [PMID: 32336415].
3. Julia F, Petrella T, Beylot-Barry M, et al. Blastic plasmacytoid dendritic cell neoplasm: clinical features in 90 patients. *Br J Dermatol*. 2013;169:579-86. [PMID: 23646868].

4. Ramachandran V, Park KE, Loya A, Duvic M. Second primary malignancies in blastic plasmacytoid dendritic cell neoplasm: A national database study. *J Am Acad Dermatol*. 2020;83:1786-1789. [PMID: 32278799].
5. Patterson, James. *Weedon's Pathology of the Skin*. 5th ed. Elsevier; 2019.
6. Venugopal S, Zhou S, El Jamal SM, Lane AA, Mascarenhas J. Blastic Plasmacytoid Dendritic Cell Neoplasm-Current Insights. *Clin Lymphoma Myeloma Leuk*. 2019;19:545-554. [PMID: 31281107].
7. Kim MJ, Nasr A, Kabir B, de Nanassy J, Tang K, Menzies-Toman D, Johnston D, El Demellawy D. Pediatric Blastic Plasmacytoid Dendritic Cell Neoplasm: A Systematic Literature Review. *J Pediatr Hematol Oncol*. 2017;39:528-537. [PMID: 28906324].
8. Pemmaraju N, Lane AA, Sweet KL, Stein AS, Vasu S, Blum W, Rizzieri DA, Wang ES, Duvic M, Sloan JM, Spence S, Shemesh S, Brooks CL, Balsler J, Bergstein I, Lancet JE, Kantarjian HM, Konopleva M. Tagraxofusp in Blastic Plasmacytoid Dendritic-Cell Neoplasm. *N Engl J Med*. 2019;380:1628-1637. [PMID: 31018069].
9. Morin A, Kechedjian F, Walton P, Tavakoli A. Tagraxofusp Treatment: Implications for Patients With Blastic Plasmacytoid Dendritic Cell Neoplasm. *Clin J Oncol Nurs*. 202;25:E10-E16. [PMID: 33739343].