

# UCSF

## UC San Francisco Previously Published Works

### Title

Parapharyngeal tuberculoid mass: A rare complication of Bacillus Calmette-Guérin therapy for urothelial carcinoma in situ

### Permalink

<https://escholarship.org/uc/item/6668t3qk>

### Journal

Clinical Case Reports, 9(6)

### ISSN

2050-0904

### Authors

Plonowska-Hirschfeld, Karolina A  
Fung, Monica  
Glastonbury, Christine  
et al.

### Publication Date

2021-06-01

### DOI

10.1002/ccr3.4172

Peer reviewed

## CASE REPORT

# Parapharyngeal tuberculoid mass: A rare complication of Bacillus Calmette-Guérin therapy for urothelial carcinoma in situ

Karolina A. Plonowska-Hirschfeld<sup>1</sup>  | Monica Fung<sup>2</sup> | Christine Glastonbury<sup>1,3</sup> | Patrick K. Ha<sup>1,4</sup>

<sup>1</sup>Department of Otolaryngology-Head and Neck Surgery, University of California-San Francisco, San Francisco, CA, USA

<sup>2</sup>Department of Medicine – Infectious Disease, University of California-San Francisco, San Francisco, CA, USA

<sup>3</sup>Department of Clinical Radiology, University of California-San Francisco, San Francisco, CA, USA

<sup>4</sup>Division of Head and Neck Surgical Oncology, Department of Otolaryngology-Head and Neck Surgery, University of California-San Francisco, San Francisco, CA, USA

## Correspondence

Patrick K. Ha, University of California-San Francisco, 550 16th Street, Rm 6765, Box 3213, San Francisco, CA 94158, USA.  
Email: Patrick.Ha@ucsf.edu

## Funding information

The author(s) received no specific funding for this work.

## Key Clinical Message

Local and systemic complications of Bacillus Calmette-Guérin therapy are important to recognize as they require prolonged antimicrobial therapy; molecular genomic testing may be key to diagnosis when culture data are inconclusive.

## KEYWORDS

Bacillus Calmette-Guérin (BCG), case report, mycobacterial infection, parapharyngeal space mass, tuberculoid mass

## 1 | INTRODUCTION

We present the first reported case of a parapharyngeal space mass as manifestation of disseminated mycobacterial infection following Bacillus Calmette-Guérin (BCG) intravesical therapy. Systemic complications of BCG administration are challenging to recognize and require prolonged antimicrobial therapy. Molecular assays with 16S rRNA are instrumental in cases where microbial cultures and serologies are equivocal.

Bacillus Calmette-Guérin (BCG), a live-attenuated strain of *Mycobacterium bovis*, has been successfully used as intravesical immunotherapy in superficial (muscle-sparing) bladder cancer for over 40 years.<sup>1</sup> It is the treatment of choice

in patients with urothelial carcinoma in situ (Tis) and early-stage disease (Ta-T1), and has been shown to reduce both its recurrence and progression.<sup>2</sup> While its precise mechanism of action remains poorly defined, it is postulated that BCG infection of the urothelium stimulates a cytokine-mediated immune response and confers antitumor activity by cytotoxic T lymphocytes.<sup>3</sup>

Local and systemic infectious complications of BCG intravesical therapy are rare. The most common of these is BCG cystitis, but reported manifestations include orchitis, sepsis, granulomatous hepatitis and nephritis, pneumonitis, osteomyelitis, arthritis, and mycotic aneurysms. In this report, we describe a rare case of a parapharyngeal mass in a

This is an open access article under the terms of the Creative Commons Attribution-NonCommercial-NoDerivs License, which permits use and distribution in any medium, provided the original work is properly cited, the use is non-commercial and no modifications or adaptations are made.

© 2021 The Authors. *Clinical Case Reports* published by John Wiley & Sons Ltd.

71-year-old patient treated with intravesical BCG for urothelial carcinoma in situ at a tertiary academic medical center. Following molecular diagnostics, the cervical mass was ultimately identified as a distant mycobacterial infection. This is the first reported deep neck space infection resultant from intravesical BCG therapy.

## 2 | CASE REPORT

This study was exempt from review by the University of California-San Francisco (UCSF) Institutional Review Board. A 71-year-old man presented to clinic with a six-month history of a left-sided soft, compressible neck mass. He denied any associated pain or dysphagia, compressive symptoms, hoarseness, or globus. His past head and neck surgical history was notable for a childhood adenotonsillectomy. He was diagnosed urothelial carcinoma in situ in 2018 and had undergone two transurethral resections of bladder tumors and two therapeutic courses with one maintenance intravesical immunotherapy with BCG. His treatment was complicated by BCG cystitis, for which the patient was treated with a three weeks of isoniazid and rifampin, and his symptoms resolved. The last therapeutic intravesical BCG therapy was completed three months prior to developing a neck mass and 10 months prior to presentation in otolaryngology clinic (timeline of events is presented in Table 1).

Outside hospital workup of his symptoms included a neck ultrasound and an MRI for evaluation of a left-sided neck mass. These showed a left level II/III 6.6 × 2.8 cm complex cystic mass with a mural soft tissue component and an unusually thick septation. The patient had undergone two fine-needle aspirations, which yielded purulent material with neutrophils but no observed growth on bacterial, fungal, and acid-fast bacilli cultures. A multidisciplinary review of this case favored additional imaging with computed tomography of the neck and chest (Figure 1). This demonstrated a left lateral neck noncalcified fluid collection with a thick rim and an enhancing internal septation. There were no associated calcifications, no surrounding inflammatory changes, and the collection displaced the carotid and jugular vessels anteriorly. Chest CT revealed calcifications within mediastinal lymph nodes and spleen, indicating prior granulomatous infection.

The infectious disease service was consulted for diagnostic workup and management given concern for an infectious granulomatous process. QuantiFERON-TB Gold Plus testing returned negative. The patient also tested negative for human immunodeficiency virus (HIV), which confers a higher incidence of tuberculous lymphadenitis with HIV co-infection.<sup>4</sup> Additional antibody and antigen testing for *Histoplasma capsulatum*, *Coccidioides immitis*, *Coxiella burnetii*, *Bartonella*, and *Brucella* species was unremarkable. The patient was started empirically on isoniazid,

**TABLE 1** Timeline of intravesical BCG therapy relative to onset of left neck mass symptoms, its diagnosis, and treatment

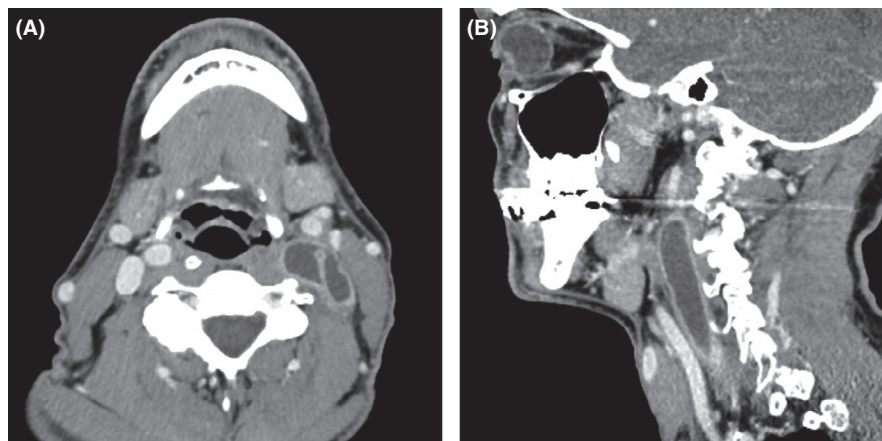
Time	Event
June 2018	Diagnosis of urothelial carcinoma in situ
July-Aug 2018	First therapeutic course of intravesical BCG (6 wk)
Oct 2018	Second therapeutic course of intravesical BCG (6 wk)
Jan 2019	Onset of left neck swelling
Feb 2019	Maintenance course of intravesical BCG (3 wk)
April 2019	Diagnosis of BCG cystitis, 3-wk course of isoniazid and rifampin initiated
July 2019	Nondiagnostic FNA of left neck mass
Aug 2019	Referred to UCSF Otolaryngology. Repeat FNA of left neck mass with necrotizing granulomatous infection. Bacterial and fungal cultures and acid-fast bacilli staining return negative
Sept 2019	Testing for <i>Histoplasma capsulatum</i> , <i>Coccidioides immitis</i> , <i>Coxiella burnetii</i> , <i>Bartonella</i> and <i>Brucella</i> species returns negative. Patient was prophylactically started on isoniazid, rifampin, and ethambutol. Universal microbial PCR (16S rRNA testing) detects mycobacterium tuberculosis complex
Dec 2019	Interval decrease in left neck mass size
March 2020	Completion of 6-mo course of isoniazid and rifampin

rifampin, and ethambutol given high clinical suspicion for disseminated BCG infection. 16S ribosomal RNA sequencing of fine-needle aspirate (FNA) specimen ultimately detected *mycobacterium tuberculosis* complex. The FNA specimen was sent to the California State Laboratory for pyrosequencing, which detected DNA of *M. bovis* and confirmed susceptibility to isoniazid and rifampin. The patient initially experienced paradoxical worsening of the left neck mass with initiation of therapy before subsequent decrease in left neck swelling. At most recent follow-up with the infectious disease service in March 2020, the patient had nearly completed the planned six months of antimicrobial therapy, and his examination was remarkable for a persistent small area of nodular hyperpigmentation at the neck mass site. He otherwise did not experience any adverse effects of isoniazid and rifampin therapy.

## 3 | DISCUSSION

A parapharyngeal space lesion is a rare complication of BCG treatment for urothelial carcinoma. Testicular, pelvic, prostatic, and renal abscesses are among reported side effects of intravesical BCG, but incidence of systemic dissemination of *M. tuberculosis* following treatment is less

**FIGURE 1** (A) Axial and (B) sagittal contrast-enhanced computed tomography demonstrating an elongated thick-walled, irregular fluid density collection deep to the sternocleidomastoid muscle, displacing carotid vessels anteriorly. There were no associated calcifications or infiltration of adjacent tissues



than 0.4%.<sup>5,6</sup> A pediatric case of a retropharyngeal abscess following BCG vaccination has been previously reported, but this is the first published report of a deep neck space infection following intravesical BCG therapy.<sup>7</sup> Risk of disseminated mycobacterial infection is increased in individuals with foreshortened time between urologic surgery and intravesical instillation of BCG. The reported onset of symptoms can vary from 3 months to 1 year following treatment, making disseminated tuberculous infections challenging to recognize and treat.<sup>8</sup>

Diagnostic tests for extrapulmonary *M. tuberculosis* infections include microbial cultures and acid-fast bacilli staining, as well as molecular diagnostic assays identifying highly conserved bacterial gene sequences (16S rRNA). The latter confers ability to identify tuberculous infections with increased speed and accuracy, with reported specificity as high as 96%-100%.<sup>9,10</sup> Its utility is particularly valuable in cases where phenotype-based testing is equivocal, as for the patient described in this report.

The role of surgical intervention for tuberculous lesions of the head and neck from extrapulmonary *M. tuberculosis* is variable. One small series of patients with tuberculous thyroid nodules reported resolution of lesions with nine month medical therapy alone.<sup>11</sup> In cervical tuberculous lymphadenitis, majority of cases can be treated medically, though surgical intervention may be required in cases of disease persistence despite prolonged antimicrobial course or cervical disease burden causing significant mass effect on the airway.<sup>12,13</sup> Benefit of surgical intervention must be weighed against the risk of forming fistula and chronically draining sinus tracts.

Disseminated BCG infections may not require surgical intervention, but should be treated with extended courses of medical therapy and undergo surveillance for treatment response. A suggested duration of therapy is three to six months with a multidrug regimen of rifampin, isoniazid, and ethambutol. A close review of the patient's medical history and exposures is needed to raise suspicion for this rare etiology. Molecular diagnostics, such as 16S rRNA sequencing,

may be key to diagnosis in cases where serology and culture-based testing is inconclusive.

### ETHICS STATEMENT

This study was deemed exempt from review by the University of California-San Francisco (UCSF) Institutional Review Board.

### CONFLICT OF INTEREST

The authors report no relevant disclosures. PKH did serve on advisory boards for Loxo/Bayer Oncology and received research/educational funding from Stryker, Synthes, and Medtronic.

### AUTHOR CONTRIBUTIONS

KAP: performed patient chart review, literature review for prior reported BCG therapy sequelae, and authored the manuscript. PKH and MF: involved in the clinical care for the case patient presented and contributed to the final manuscript. CG: reviewed and interpreted imaging studies for the case, identified representative imaging findings, and contributed to the manuscript text.

### DATA AVAILABILITY STATEMENT

Data sharing is not applicable to this article as no new data were created or analyzed in this study.

### ORCID

Karolina A. Plonowska-Hirschfeld  <https://orcid.org/0000-0002-8429-5779>

### REFERENCES

- Morales A, Eiding D, Bruce AW. Intracavitary Bacillus Calmette-Guerin in the treatment of superficial bladder tumors. *J Urol.* 1976;116(2):180-183.
- Han RF, Pan JG. Can intravesical bacillus Calmette-Guerin reduce recurrence in patients with superficial bladder cancer? A meta-analysis of randomized trials. *Urology.* 2006;67(6):1216-1223.

3. De Boer EC, De Jong WH, Steerenberg PA, et al. Induction of urinary interleukin-1 (IL-1), IL-2, IL-6, and tumour necrosis factor during intravesical immunotherapy with bacillus Calmette-Guerin in superficial bladder cancer. *Cancer Immunol Immunother.* 1992;34(5):306-312.
4. Hill AR, Premkumar S, Brustein S, et al. Disseminated tuberculosis in the acquired immunodeficiency syndrome era. *Am Rev Respir Dis.* 1991;144(5):1164-1170.
5. Lamm DL, van der Meijden PM, Morales A, et al. Incidence and treatment of complications of bacillus Calmette-Guerin intravesical therapy in superficial bladder cancer. *J Urol.* 1992;147(3):596-600.
6. Leis JA, Ricciuto DR, Gold WL. Attenuated but live: a pelvic abscess caused by bacille Calmette-Guerin. *CMAJ.* 2011;183(13):1511-1514.
7. Parvaneh N, Mamishi S, Monajemzadeh M. Retropharyngeal abscess after BCG vaccination. *Intern J Ped Otorhinolaryngol Extra.* 2006;1(4):279-281.
8. Gonzalez OY, Musher DM, Brar I, et al. Spectrum of Bacille Calmette-Guérin (BCG) infection after intravesical BCG immunotherapy. *Clin Infect Dis.* 2003;36(2):140-148.
9. Linasmita P, Srisangkaew S, Wongsuk T, Bhongmakapat T, Watcharananan SP. Evaluation of Real-time Polymerase Chain Reaction for Detection of the 16S Ribosomal RNA Gene of *Mycobacterium tuberculosis* and the Diagnosis of Cervical Tuberculous Lymphadenitis in a Country With a High Tuberculosis Incidence. *Clin Infect Dis.* 2012;55(3):313-321.
10. Cloud JL, Neal H, Rosenberry R, et al. Identification of *Mycobacterium* spp. by Using a Commercial 16S Ribosomal DNA Sequencing Kit and Additional Sequencing Libraries. *J Clin Microbiol.* 2002;40(2):400-406.
11. Majid U, Islam N. Thyroid tuberculosis: a case series and a review of the literature. *J Thyroid Res.* 2011;2011:359864.
12. Lee KC, Tami TA, Lalwani AK, Schechter G. Contemporary management of cervical tuberculosis. *Laryngoscope.* 1992;102(1):60-64.
13. Qureshi FG, Newman KD. Chapter 57 - Lymph Node Disorders. In: Coran AG, ed. *Pediatric Surgery (Seventh Edition)*. Mosby; 2012:737-743.

**How to cite this article:** Plonowska-Hirschfeld KA, Fung M, Glastonbury C, Ha PK. Parapharyngeal tuberculoid mass: A rare complication of Bacillus Calmette-Guérin therapy for urothelial carcinoma in situ. *Clin Case Rep.* 2021;9:e04172. <https://doi.org/10.1002/ccr3.4172>