

# UCSF

## UC San Francisco Previously Published Works

### Title

Cervical deformity patients with baseline hyperlordosis or hyperkyphosis differ in surgical treatment and radiographic outcomes.

### Permalink

<https://escholarship.org/uc/item/65f8566m>

### Journal

Journal of craniovertebral junction & spine, 13(3)

### ISSN

0974-8237

### Authors

Passias, Peter Gust  
Alas, Haddy  
Kummer, Nicholas  
[et al.](#)

### Publication Date

2022-07-01

### DOI

10.4103/jcvjs.jcvjs\_66\_21

Peer reviewed

# Cervical deformity patients with baseline hyperlordosis or hyperkyphosis differ in surgical treatment and radiographic outcomes

## ABSTRACT

**Background:** Patients with symptomatic cervical deformity (CD) requiring surgical correction often present with hyperkyphosis (HK), although patients with hyperlordotic curves may require surgery as well. Few studies have investigated differences in CD corrective surgery with regard to HK and hyperlordosis (HL).

**Objective:** The objective of the study is to evaluate patterns in treatment for CD patients with baseline (BL) HK and HL and understand how extreme curvature of the spine may influence surgical outcomes.

**Materials and Methods:** Operative CD patients with BL and 1-year (1Y) radiographic data were included in the study. Patients were stratified based on BL C2–C7 lordosis (CL) angle: those >1 standard deviation (SD) from the mean ( $6.96 \pm 21.47$ ) were hyperlordotic (>14.51°) or hyperkyphotic (<28.43°) depending on directionality. Patients within 1SD were considered control group.

**Results:** 102 surgical CD patients (61 years, 65% F, 30 kg/m<sup>2</sup>) with BL and 1Y radiographic data were included. 20 patients met definitions for HK and 21 patients met definitions for HL. No differences in demographics or disability were noted. HK had higher estimated blood loss (EBL) with anterior approaches than HL but similar EBL with posterior approach. Operative time did not differ between groups. Control, HL, and HK groups differed in BL TS-CL (36.6° vs. 22.5° vs. 60.7°,  $P < 0.001$ ) and BL-SVA (10.8 vs. 7.0 vs. -47.8 mm,  $P = 0.001$ ). HL patients had less discectomies, less corpectomies, and similar osteotomy rates to HK. HL had 3x revisions of HK and controls (28.6 vs. 10.0 vs. 9.2%, respectively,  $P = 0.046$ ). At 1Y, HL patients had higher cSVA and trended higher SVA and SS than HK. In terms of BL-upper cervical alignment, HK patients had higher McGregor's slope (MGS) (16.1° vs. 3.3°,  $P = 0.002$ ) and C0–C2 Cobb (43.3° vs. 26.9°,  $P < 0.001$ ), however, postoperative differences in MGS and C0–C2 were not significant. HK drivers of deformity were primarily C (90%), whereas HL had primary CT (38.1%), UT (23.8%),

**PETER GUST PASSIAS, HADDY ALAS, NICHOLAS KUMMER, PETER TRETIAKOV, BASSEL G. DIEBO<sup>1</sup>, RENAUD LAFAGE<sup>2</sup>, CHRISTOPHER P. AMES<sup>3</sup>, BRETON LINE<sup>4</sup>, ERIC O. KLINEBERG<sup>5</sup>, DOUGLAS C. BURTON<sup>6</sup>, JUAN S. URIBE<sup>7</sup>, HAN JO KIM<sup>2</sup>, ALAN H. DANIELS<sup>8</sup>, SHAY BESS<sup>4</sup>, THEMISTOCLES PROTOPSALTIS, GREGORY M. MUNDIS<sup>9</sup>, CHRISTOPHER I. SHAFFREY<sup>10</sup>, FRANK J. SCHWAB<sup>2</sup>, JUSTIN S. SMITH<sup>10</sup>, VIRGINIE LAFAGE<sup>2</sup>, INTERNATIONAL SPINE STUDY GROUP**

Department of Orthopaedic and Neurosurgery, Division of Spinal Surgery, NYU Langone Orthopaedic Hospital, New York Spine Institute, <sup>1</sup>Department of Orthopaedic Surgery, State University of New York Downstate Medical Center, Brooklyn, <sup>2</sup>Department of Orthopaedic Surgery, Hospital for Special Surgery, NY, <sup>3</sup>Department of Neurological Surgery, University of California San Francisco, San Francisco, <sup>4</sup>Department of Orthopaedic Surgery, University of California Davis, Davis, <sup>5</sup>San Diego Center for Spinal Disorders, La Jolla, CA, <sup>6</sup>Rocky Mountain Scoliosis and Spine, Denver, CO, <sup>7</sup>Department of Orthopaedic Surgery, University of Kansas Medical Center, Kansas City, <sup>8</sup>Department of Neurosurgery, University of South Florida, Tampa, FL, <sup>9</sup>Department of Orthopaedic Surgery, Warren Alpert School of Medicine, Brown University, Providence, RI, <sup>10</sup>Department of Neurosurgery, University of Virginia Medical Center, Charlottesville, VA, USA

**Address for correspondence:** Dr. Peter Gust Passias, New York Spine Institute, NYU Langone Medical Center, Hospital for Joint Diseases, 301 East 17<sup>th</sup> Street, 10003, NY, USA. E-mail: pgpassias@yahoo.com

Submitted: 04-May-21


Accepted: 18-Oct-21

Published: 14-Sep-22

This is an open access journal, and articles are distributed under the terms of the Creative Commons Attribution-NonCommercial-ShareAlike 4.0 License, which allows others to remix, tweak, and build upon the work non-commercially, as long as appropriate credit is given and the new creations are licensed under the identical terms.

For reprints contact: WKHLRPMedknow\_reprints@wolterskluwer.com

**How to cite this article:** Passias PG, Alas H, Kummer N, Tretiakov P, Diebo BG, Lafage R, *et al.* Cervical deformity patients with baseline hyperlordosis or hyperkyphosis differ in surgical treatment and radiographic outcomes. *J Craniovert Jun Spine* 2022;13:271-7.

Access this article online	
<b>Website:</b> <a href="http://www.jcvjs.com">www.jcvjs.com</a>	<b>Quick Response Code</b> 
<b>DOI:</b> 10.4103/jcvjs.jcvjs_66_21	

and C (14.3%) drivers.

**Conclusions:** Hyperlordotic patients trended higher revision rates with greater radiographic malalignment at 1-year postoperative, perhaps due to undercorrection compared to kyphotic etiologies.

**Keywords:** Cervical deformity, cervical lordosis, hyperlordosis, spine surgery

## INTRODUCTION

The cervical, thoracic, and lumbar curvatures exist in reciprocal lordotic and kyphotic harmony. A wide variation of spinal curvatures exists in a healthy population – particularly for the cervical spine.<sup>[1,2]</sup> Recent evidence suggests the cervical spine need not necessarily be lordotic at all, with straight or kyphotic angulations existing as normal variants.<sup>[3]</sup>

The most common method to assess cervical lordosis is with the Cobb angle, typically measured from C2 to C7. This angle may underestimate true cervical lordosis but remains a clinical mainstay with high intra and interrater reliability.<sup>[4]</sup> While the majority of cervical lordosis originates in the upper cervical spine, the subaxial region lies adjacent to the cervicothoracic junction and is more susceptible to lordotic or kyphotic compensation from thoracic changes below.<sup>[2]</sup> The unique load distribution of the cervical spine onto one anterior column (36%) and two posterior columns (64%) also plays an important role in determining subaxial curvature, especially under mechanical stress.<sup>[5]</sup> Whether these compensatory changes manifest into a hyperlordotic or hyperkyphotic cervical spine depends on the etiology of the cervical deformity (CD).

CD can occur in the coronal and sagittal planes, although the latter is more frequent and associated with better clinical outcomes when corrected.<sup>[6-8]</sup> Cervical kyphosis or hyperkyphosis (HK) is the most common presentation of sagittal CD and may arise secondary to degenerative causes, autoimmune phenomena, or previous spine surgery.<sup>[9,10]</sup> Hyperlordosis (HL), although more rare, can manifest itself into a form of CD separate from its kyphotic counterpart. No consensus exists for optimal correction of CD, and there is a dearth of literature comparing hyperlordotic versus hyperkyphotic types with respect to postoperative alignment and outcomes.

Our objective, through a retrospective analysis of operative CD patients, was to identify differences in surgical treatment, radiographic alignment, and clinical outcomes between two extremes of cervical spinal curvature measured through the Cobb method. We aimed to shed light on a relatively rare and understudied patient population within CD in hopes of optimizing surgical strategy and perioperative planning.

## MATERIALS AND METHODS

### Data source

This study is a retrospective review of a prospective, multicenter CD database. Consenting patients were consecutively enrolled at 13 surgical centers across the United States from 2013 to 2017. All participating centers obtained Institutional Review Board approval before patient enrollment. Inclusion criteria for the database were age > 18 years and radiographic evidence of CD, as defined by the presence of at least one of the following on baseline (BL) imaging: cervical kyphosis (C2–C7 Cobb angle > 10°), cervical scoliosis (C2–C7 coronal Cobb angle < 10°), C2–C7 sagittal vertical axis (cSVA) > 40 cm or chin-brow vertical angle > 25°. Additional inclusion criteria for the present analysis included available BL and 1-year (1Y) postoperative sagittal radiographic imaging.

### Data collection and radiographic assessment

Patient demographics, comorbidities, self-reported disability index, and radiographic data were obtained with standardized patient questionnaires at the preoperative interval. Procedural, perioperative, and postoperative radiographic data were collected following surgery at 1-year follow-up. Standardized health-related quality of life (HRQL) measures were administered at BL and 1Y study intervals and included the Neck Disability Index (NDI), Numeric Rating Scale (NRS) for both neck and back pain, the modified Japanese Orthopedics Association (mJOA) outcomes questionnaire, and the EuroQol five-dimension 3-severity-level (EQ-5D) questionnaire.

Preoperative standing lateral radiographs were collected at BL and 1Y intervals and analyzed with SpineView® (ENSAM, Laboratory of Biomechanics, Paris, France) software as previously published.<sup>[11-13]</sup> Cervical alignment was assessed based on the following sagittal parameters: C2–C7 angle measured through the Cobb method, C2–C7 sagittal vertical axis (SVA), mismatch between T1 slope and cervical lordosis (TS-CL), T1 slope, C0–C2 lordosis, and McGregor's slope (MGS) as previously described.<sup>[14]</sup> Global sagittal alignment was assessed based on the sagittal vertical axis (SVA, C7 plumbline relative to the posterosuperior corner of S1, pelvic tilt (PT), and mismatch between PI and LL (PI-LL) as previously described.<sup>[14-16]</sup> Postoperative distal

junctional kyphosis (DJK) was assessed through the Cobb angle method between the superior endplate of lowest instrumented vertebra (LIV) and the inferior endplate of the vertebra two levels superior to the LIV (LIV + 2). An angle  $> 10^\circ$  with a progression of at least  $10^\circ$  from BL was considered DJK.

### Statistical analysis

Patients were grouped by respective cervical lordosis C2–C7 angle relative to the mean cervical lordosis angle of the cohort. A C2–C7 angle greater than or less than one standard deviation (SD) of the mean was considered HK or HL depending on directionality. C2–C7 angles within 1 SD of the mean were considered controls. Demographic, radiographic, and clinical, and surgical variables were summarized using means and SDs for continuous variables and frequencies and percentages for categorical variables. Differences in BL demographics, surgical factors, radiographic alignment, and clinical outcomes between HK, HL, and control groups were assessed using analysis of variance sampling for normally distributed continuous variables, Mann–Whitney U-tests for nonnormally distributed continuous variables and Chi-squared tests for categorical variables. Radiographic alignment at 1-year postoperative was compared across groups as described above, with a statistical cutoff of  $P < 0.05$  indicating statistical significance. All statistical analyses were performed using SPSS software (v23.0, IBM, Armonk, NY, USA).

## RESULTS

### Overall cohort realignment

One hundred and two CD patients meeting inclusion criteria underwent corrective surgery. At 1 year, patients showed improvement in both regional and global alignment compared to BL: mean C2–C7 Cobb angle increased ( $P < 0.001$ ), TS-CL decreased ( $P < 0.001$ ), C2–C7 SVA decreased ( $P = 0.002$ ), and C7–S1 SVA increased ( $P < 0.001$ ). Table 1 illustrates overall cohort realignment.

Surgical CD patients ( $61.4 \pm 10.2$  years,  $29.0 \pm 7.94$  kg/m<sup>2</sup>, CCI:  $0.89 \pm 1.19$ ) had complete radiographic and clinical data at BL. Mean cervical lordosis C2–C7 angle was  $-6.96^\circ$  with a SD of  $21.47^\circ$ . Twenty-one patients met definitions for HL, with a C2–C7 Cobb angle  $> +14.51^\circ$  ( $> 1SD$ ) and a mean angle of  $25.8^\circ$ . Twenty patients met definitions for HK, with a C2–C7 Cobb angle  $< -28.43^\circ$  and a mean angle of  $-41.7^\circ$ . Control patients were within one SD of the mean C2-C7 angle.

No differences in age ( $P = 0.709$ ), BMI ( $P = 0.222$ ), and CCI ( $P = 0.495$ ) were noted between HL, HK, and controls at BL [Table 2]. HK patients presenting significantly

**Table 1: Pre to postoperative changes in sagittal alignment for our entire cohort of cervical deformity patients**

Overall CD cohort correction			
Sagittal alignment parameters	Preoperative	Postoperative	P
C2-C7 Cobb angle ( $^\circ$ )	-7.13	6.84	<0.001*
C2-C7 SVA (mm)	46.7	40.5	0.002*
TS-CL ( $^\circ$ )	37.5	28.5	<0.001*
C7-S1 SVA (mm)	-0.96	23.0	<0.001*
PT ( $^\circ$ )	19.6	19.7	0.910
PI-LL ( $^\circ$ )	0.77	2.31	0.167
Sacral slope ( $^\circ$ )	34.2	34.0	0.872

\*Indicates statistical significance to  $P < 0.05$ . CD - Cervical deformity, SVA - Sagittal vertical axis, TS-CL - T1 slope and cervical lordosis, PT - Pelvic tilt, PI-LL - Pelvic incidence-lumbar lordosis

more malaligned in terms of TS–CL ( $P < 0.001$ ), C7–S1 SVA ( $P = 0.001$ ), MGS ( $P = 0.002$ ), and C0–C2 upper cervical lordosis ( $P < 0.001$ ) compared to HL and controls. No significant differences in C2–C7 plumbline (cSVA), PT, sacral slope, and PI-LL were noted (all  $P > 0.05$ ).

In terms of HRQL metrics, some differences were found between groups. HK, HL, and controls scored similarly in neck disability ( $P = 0.666$ ) and NRS for neck pain ( $P = 0.938$ ). HL patients had significantly higher myelopathy symptoms than HK patients ( $P = 0.048$ ) and higher EQ5D scores than the control ( $P = 0.037$ ) [Table 3].

### Procedural and perioperative details

Surgical approach differed according to BL HL or HK presentation. HL patients trended higher rates of posterior only approaches (73.7%) than HK (31.6%) or controls (46.5%) ( $P = 0.028$ ), while HK patients trended higher rates of combined (anterior then posterior) approaches than HL patients (47.4% vs. 10.5%,  $P = 0.046$ ). HL patients trended significantly less index discectomies than HK or controls ( $P = 0.023$ ). HL patients trended less corpectomies than HK or controls ( $P = 0.071$ ) but had similar rates of laminectomies and osteotomies ( $P > 0.05$ ). Estimated blood loss (EBL), operative time (optime), and length of stay did not differ significantly between groups [Table 2].

### Postoperative radiographic outcomes at 3 months and 1 year

At 3-month postoperative, HL patients trended toward greater global malalignment with greater PT on average than HK and control patients (27.6 vs. 22.9 vs. 20.3,  $P = 0.059$ ), in addition to trending higher PI-LL mismatch (11.3 vs. 5.3 vs. 3.3,  $P = 0.292$ ). No trends in cervical regional alignment parameters including TS-CL ( $P = 0.392$ ) or cSVA ( $P = 0.717$ ) were noted between HL and HK groups at 3 months.

**Table 2: Demographic, procedural, and radiographic differences (baseline and 1-year postoperatively) between patients with baseline hyperkyphosis, hyperlordosis, or neither (control)**

	Control	HL	HK	P
<b>Demographics</b>				
Age (years)	60.3	59.1	61.8	0.709
Gender (female %)	63	68.4	72.2	0.710
BMI (kg/m <sup>2</sup> )	30.1	27.4	27.3	0.222
CCI	1.00	0.74	0.63	0.495
<b>Procedural factors</b>				
Posterior only approach (%)	46.5	73.7	31.6	0.028*
Anterior only approach (%)	19.8	10.5	10.5	0.435
Combined approach (%)	33.7	10.5	47.4	0.046*
EBL, anterior approach (cc)	170.7	160.0	335.0	0.229
EBL, posterior approach (cc)	812.4	882.4	925.9	0.879
Optime, anterior approach (min)	228.2	155.0	296.8	0.110
Optime, posterior approach (min)	339.5	315.1	378.9	0.573
LOS (days)	7.71	8.31	6.00	0.765
Corpectomy	0.45	0.00	0.74	0.071
Discectomy	1.80	1.00	2.85	0.023*
Osteotomy	2.23	2.00	2.42	0.875
Smith-Peterson osteotomy	0.85	1.38	0.80	0.577
Revision (%)	9.2	28.6	10.0	0.046*
<b>Baseline radiographics</b>				
C2–C7 Cobb	-6.89	25.8	-41.7	<0.001*
C2–C7 SVA (mm)	43.7	50.5	53.4	0.443
TS–CL (°)	36.6	22.5	60.7	<0.001*
T1 slope	29.7	48.3	19.0	<0.001*
C7–S1 SVA (mm)	10.8	7.01	-47.8	0.001*
PT (°)	20.4	18.1	17.9	0.799
PI–LL (°)	3.06	-1.91	-6.24	0.110
Sacral slope (°)	34.2	37.1	32.8	0.483
MGS (°)	3.28	-3.26	16.1	0.002*
C0–C2 angle (°)	32.8	26.9	43.3	<0.001*
PJK (%)	25.6	46.2	16.7	0.280
<b>Radiographic parameters at 1 year</b>				
C2–C7 Cobb	4.80	20.2	-0.60	<0.001*
C2–C7 SVA (mm)	39.5	49.8	33.8	0.041*
TS–CL (°)	30.1	24.2	26.7	0.234
T1 slope	34.9	44.3	26.1	0.003*
C7–S1 SVA (mm)	31.3	15.7	-13.3	0.092
PT (°)	19.6	17.5	23.0	0.375
PI–LL (°)	2.57	-0.84	-0.03	0.736
Sacral slope (°)	34.4	37.5	29.1	0.091
MGS (°)	-1.45	-3.79	-0.92	0.650
C0–C2 angle (°)	29.6	27.1	29.1	0.765
DJK rate (%)	26.7	15.8	26.3	0.597

\*Indicates statistical significance to  $P < 0.05$ . Italicized values approached statistical significance. MGS - McGregor's slope, SVA - Sagittal vertical axis, TS-CL - T1 slope and cervical lordosis, PT - Pelvic tilt, PI-LL - Pelvic incidence-lumbar lordosis, BMI - Body mass index, CCI - Charlson Comorbidity Index, LOS - Length of stay, EBL - Estimated blood loss, Optime - Operative time, PJK - Proximal junctional kyphosis, DJK - Distal junctional kyphosis, HL - Hyperlordosis, HK - Hyperkyphosis

By 1 year, HL patients had greater cervical and global malalignment, illustrated by significantly higher average cSVA ( $P = 0.041$ ) and global SVA ( $P = 0.092$ ). HL patients

also trended higher mean sacral slope ( $P = 0.091$ ) but similar TS–CL mismatch ( $P = 0.234$ ), PT ( $P = 0.375$ ), and PI–LL mismatch ( $P = 0.736$ ). No differences in upper cervical parameters for MGS and C0–C2 angle were found at 3 months or 1 year (all  $P > 0.05$ ). No differences in DJK magnitude (HL: 12.74°, HK: 15.51°, control: 12.66°,  $P = 0.795$ ) or DJK rate (HL: 15.8%, HK: 26.3%, control: 26.7%,  $P = 0.597$ ) were found between groups [Table 2].

### Clinical Outcomes at 3 months and 1 year

Differences in patient-reported HRQLs were analyzed across all groups both at 3 months and 1-year postoperative. No significant differences nor trends in NDI, mJOA, EQ5D, and NRS neck pain scores were noted between groups (all  $P > 0.05$ ). Rates of revision surgery were documented as well. Patients with BL HL had nearly three times the revision rate of HK and control patients, respectively (28.6% vs. 10% vs. 9.2%,  $P = 0.046$ ) [Table 2].

### Ames deformity classification

We correlated HL and HK groups with established Ames CD classifications. A significant majority (90%) of HK patients had their driver of deformity primarily in the Cervical© region, whereas HL patients had primary cervicothoracic (CT, 38.1%), upper thoracic (UT, 23.8%), and cervical (14.3%) drivers.

### Case examples

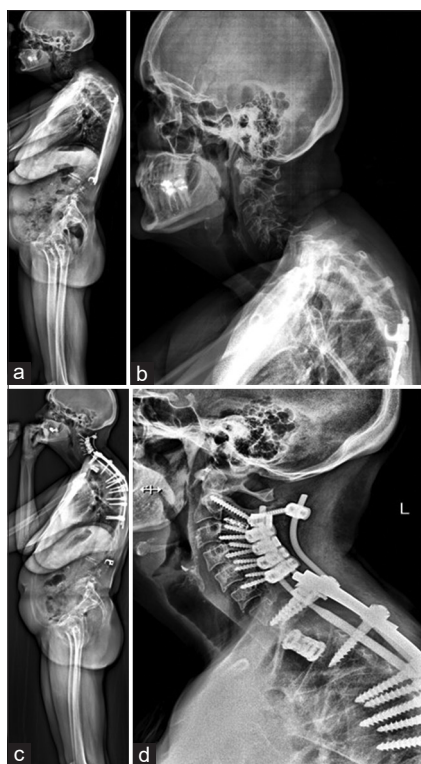Figure 1 depicts pre (left) and post (right) operative full-length standing and cervical lateral radiographs of a 57-year-old female with BL HL (C2–C7 Cobb angle = 39.0°). By 1Y, cervical malalignment was still present, with cSVA = 86.8 mm and offset of T1 slope minus CL = 56.6°.

Figure 2 depicts neutral standing radiographs, preoperative (left) to 1Y postoperative (right) changes in a 58-year-old female with BL HK (BL: C2–C7 Cobb angle = -34.4°). Cervical lordosis was significantly restored at 1Y (C2–C7 Cobb = 4.3°) and cSVA significantly reduced (39.24–25.37 mm) without need for revision.

## DISCUSSION

Both extremes of cervical spinal curvature benefited from corrective surgery by improvement in radiographic alignment and modest myelopathy relief. They differed with respect to surgical treatment, sagittal realignment, and revision rates. HL groups had persistent cervical sagittal malalignment and global malalignment at 1-year follow-up compared to conventional kyphotic CD patients. HL patients also had a revision rate three times higher than HK or controls. These patients had a higher rate of preoperative PJK, indicating some patients with previous thoracolumbar correction and





**Figure 1:** Pre (a and b) and postoperative (c and d) full-length standing and cervical lateral radiographs of a patient with baseline hyperlordosis (C2–C7 Cobb angle = 39.0°). By 1Y, cervical malalignment was still present, with cSVA = 86.8 mm and offset of T1 slope minus CL = 56.6°

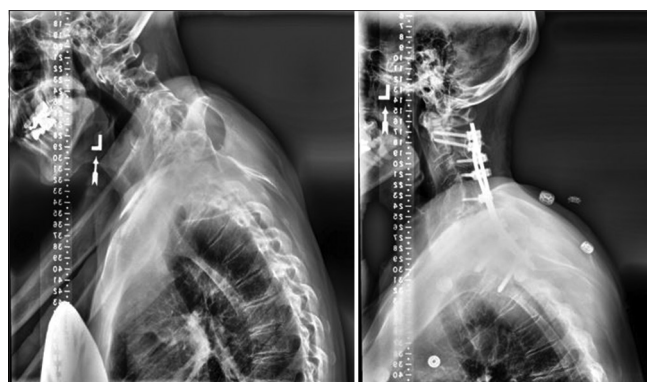**Table 3: Differences in patient-reported outcome measures between control, hyperlordosis and hyperkyphosis cohorts at baseline and 1-year follow-up**

	PROMs			P
	Control	HL	HK	
Baseline				
mJOA	13.48	14.78*	12.56*	0.048*
NDI	49.78	46.15	50.86	0.666
EQ5D	0.726*	0.766*	0.731	0.037*
NRS neck pain	6.88	6.67	6.79	0.938
1-year postoperative				
mJOA	14.10	15.24	14.14	0.371
NDI	37.50	34.68	37.84	0.877
EQ5D	0.774	0.818	0.790	0.139
NRS neck pain	4.10	4.29	4.79	0.740

\*Indicates statistical significance to  $P < 0.05$ . PROMs - Patient-reported outcome measures, HL - Hyperlordosis, HK - Hyperkyphosis, mJOA - Modified Japanese Orthopedic Association, NDI - Neck disability index, EQ-5D - European quality of life five dimensions, NRS - Numeric Rating Scale

subsequent reciprocal changes in cervicothoracic alignment are being undertreated, or that they may not be responsive to surgical correction.

HL of the cervical spine has been well documented with a wide range of symptomatology, however, no consensus for its range currently exists.<sup>[1,3,17-20]</sup> Our CD cohort had a mean C2–C7 Cobb angle of  $-7.13^\circ$  overall, indicating a more severe



**Figure 2:** Neutral standing radiographs, preoperative (left) to 1Y postoperative (right) changes in a patient with baseline hyperkyphosis (BL: C2–C7 Cobb angle =  $-34.4^\circ$ ). Cervical lordosis was significantly restored at 1Y (C2–C7 Cobb =  $4.3^\circ$ ) and cSVA significantly reduced (39.24–25.37 mm) without need for revision

BL kyphotic deformity. Given the number of chin-on-chest deformities and overall severity of CD in our population, we found it appropriate to define HL as a C2–C7 angle beyond one SD of the average.

After surgical correction, treated HL showed more persistent cervical and global malalignment at 1 year compared to hyperkyphotic patients or controls (within 1 SD), with a higher cSVA (49.8 mm), SVA (15.7 mm), and sacral slope (37.5). Previous studies investigated etiologies of pathological changes in the cervical spine, particularly with respect to previous thoracolumbar fixation.<sup>[21-26]</sup> Positive sagittal malalignment correlated with increased cervical lordosis in an effort to maintain horizontal gaze.<sup>[26]</sup> Some patients underwent spontaneous correction of their cervical HL following correction of their primary sagittal malalignment with pedicle subtraction osteotomy, with significant reduction in mean C2–C7 Cobb angle from  $30.8^\circ$  to  $21.6^\circ$  ( $P < 0.001$ ). Similarly, Jang *et al.* found that in a cohort of 53 patients treated for lumbar degenerative kyphosis, thoracic kyphosis (TK) was significantly restored from  $1.1^\circ$  to  $17.6^\circ$  following correction of sagittal malalignment.<sup>[27]</sup>

Despite adequate restoration of global sagittal balance, cervical HL may remain resistant to correction.<sup>[28]</sup> Oh *et al.* found that ASD patients undergoing correction of their thoracic deformity with concomitant cervical HL lacked significant improvement in their cervical malalignment. The authors found that cSVA increased at 2-year follow-up and suggested this may have been due to undercorrection of the entire deformity, particularly in the UT region from T1–4.<sup>[28]</sup> Our HL patients trended higher rates of concurrent PJK at BL, which typically occurs in the UT and cervicothoracic junction. We posit their cervical malalignment will remain resistant to correction if adjacent thoracic segments causing

hyperlordotic reciprocal changes are not also adequately realigned.

HL patients trended higher positive sagittal malalignment with greater SVA and sacral slopes on average than hyperkyphotics. These relationships did not reach statistical significance but remain important in the context of whole-body alignment and chain of correlation. Numerous studies have shown pelvic incidence to accurately predict lumbar lordosis.<sup>[6,29,30]</sup> Cervical lordosis has been correlated to changes in T1 slope, with Protosaltis *et al.* reporting a T1 slope minus cervical lordosis  $>17^\circ$  indicative of CD.<sup>[31]</sup> Staub *et al.* utilized normal gaze and mobile cervical spines to generate a normative TS–CL cutoff value of  $16.5^\circ$ .<sup>[32]</sup> The degree of change in T1 slope positively correlated with change in C2–C7 Cobb angle. T1 slope is the only cervical parameter that also correlates with other spinopelvic parameters.<sup>[33–37]</sup> In patients with cervical HK whose C2–C7 lordosis increased significantly ( $-40.0^\circ$  to  $-0.59^\circ$ ,  $P < 0.001$ ), T1 slope also increased significantly ( $13.8$ – $26.1$ ,  $P = 0.002$ ) with significant improvement in T2–12 TK ( $P = 0.011$ ). Hyperlordotic patients whose C2–C7 lordosis did not decrease significantly ( $24.8$ – $20.2$ ,  $P = 0.232$ ) did not experience improvement in T1 slope ( $45.0$ – $44.3$ ,  $P = 0.765$ ) nor T2–12 TK ( $P = 0.327$ ). Even when controlling for those patients who were previously fused, HL patients did not show significant decrease in C2–C7 CL ( $29.3$ – $19.3$ ,  $P = 0.067$ ) or improvement in T1 slope ( $43.2$ – $44.3$ ,  $P = 0.661$ ) at 1 year.

The lack of differences in surgical treatment between HL and HK patients may be problematic in light of recent findings, which have shown that UT osteotomies during correction of marked CD can indirectly decrease cervical lordosis through a reduction in T1 slope.<sup>[32]</sup> While HL patients did show slightly higher rates of Smith-Peterson osteotomy than others, this trend was not significant. These results, coupled with the persistence of cervical and global malalignment in HL patients as previously illustrated, may suggest a need for more aggressive surgical treatment.

Limitations of our study include its retrospective nature, which may inherently restrict granularity. The strength of our multicenter-based study could also be considered a limitation, introducing potential variability in surgical technique, clinician preference, and procedural bias. Future studies should focus on prospective data collection and a larger sample size, especially in these relatively rare subpopulations. Although the present study found no differences between HL and HK patients with regard to clinical outcomes, future studies should correlate patient health- HRQL metrics with varying extremes of cervical curvature.

## CONCLUSIONS

Cervical HL and HK exist within a spectrum of CD that remains underexplored. This multicenter analysis of consecutively enrolled CD patients undergoing surgical correction revealed that patients with a BL hyperlordotic deformity may be undertreated and inadequately realigned in the context of their unique presentation. Whereas hyperkyphotic CD patients had lower cSVA and SVA at 1 year, hyperlordotic cervical deformities proved more resistant to proper sagittal realignment. Special consideration in this patient population should be encouraged, and clinicians should be aware of a potentially increased risk for persistent cervical malalignment following surgical correction.

## Financial support and sponsorship

Nil.

## Conflicts of interest

The International Spine Study Group (ISSG) is funded through research grants from DePuy Synthes and supported the current work.

## REFERENCES

- Gore DR. Roentgenographic findings in the cervical spine in asymptomatic persons: A ten-year follow-up. *Spine (Phila Pa 1976)* 2001;26:2463-6.
- Hardacker JW, Shuford RF, Capicotto PN, Pryor PW. Radiographic standing cervical segmental alignment in adult volunteers without neck symptoms. *Spine (Phila Pa 1976)* 1997;22:1472-80.
- Gay RE. The curve of the cervical spine: Variations and significance. *J Manipulative Physiol Ther* 1993;16:591-4.
- Harrison DE, Harrison DD, Cailliet R, Troyanovich SJ, Janik TJ, Holland B. Cobb method or Harrison posterior tangent method: Which to choose for lateral cervical radiographic analysis. *Spine (Phila Pa 1976)* 2000;25:2072-8.
- Pal GP, Sherk HH. The vertical stability of the cervical spine. *Spine (Phila Pa 1976)* 1988;13:447-9.
- Glassman SD, Berven S, Bridwell K, Horton W, Dimar JR. Correlation of radiographic parameters and clinical symptoms in adult scoliosis. *Spine (Phila Pa 1976)* 2005;30:682-8.
- Mummaneni PV, Deutsch H, Mummaneni VP. Cervicothoracic kyphosis. *Neurosurg Clin N Am* 2006;17:277-87, vi.
- Steinmetz MP, Stewart TJ, Kager CD, Benzel EC, Vaccaro AR. Cervical deformity correction. *Neurosurgery* 2007;60:S90-7.
- Butler JC, Whitecloud TS 3rd. Postlaminectomy kyphosis. Causes and surgical management. *Orthop Clin North Am* 1992;23:505-11.
- Deutsch H, Haid RW, Rodts GE, Mummaneni PV. Postlaminectomy cervical deformity. *Neurosurg Focus* 2003;15:E5.
- Champain S, Benchikh K, Nogier A, Mazel C, Guise JD, Skalli W. Validation of new clinical quantitative analysis software applicable in spine orthopaedic studies. *Eur Spine J* 2006;15:982-91.
- Rillardon L, Levassor N, Guigui P, Wodecki P, Cardinne L, Templier A, *et al.* Validation of a tool to measure pelvic and spinal parameters of sagittal balance. *Rev Chir Orthop Reparatrice Appar Mot* 2003;89:218-27.
- O'Brien MF, Kuklo TR, Blanke KM, Lenke LG. Spinal Deformity

- Study Group Radiographic Measurement Manual. Rosemont: IL, USA; Medtronic Sofamor Danek; 2005. Available from: <https://www.oref.org/docs/default-source/default-document-library/sdsg-radiographic-measurement-manual.pdf>. [Last accessed on 2022 Jul 02].
14. Lafage R, Challier V, Liabaud B, Vira S, Ferrero E, Diebo BG, *et al.* Natural head posture in the setting of sagittal spinal deformity: Validation of chin-brow vertical angle, slope of line of sight, and McGregor's slope with health-related quality of life. *Neurosurgery* 2016;79:108-15.
  15. Ames CP, Blondel B, Scheer JK, Schwab FJ, Le Huec JC, Massicotte EM, *et al.* Cervical radiographical alignment: Comprehensive assessment techniques and potential importance in cervical myelopathy. *Spine (Phila Pa 1976)* 2013;38:S149-60.
  16. Ames CP, Smith JS, Scheer JK, Bess S, Bederman SS, Deviren V, *et al.* Impact of spinopelvic alignment on decision making in deformity surgery in adults: A review. *J Neurosurg Spine* 2012;16:547-64.
  17. Leigh JH, Cho K, Barcenas CL, Paik NJ. Dysphagia aggravated by cervical hyperlordosis. *Am J Phys Med Rehabil* 2011;90:704-5.
  18. Gore DR, Sepic SB, Gardner GM, Murray MP. Neck pain: A long-term follow-up of 205 patients. *Spine (Phila Pa 1976)* 1987;12:1-5.
  19. Guo Q, Ni B, Yang J, Liu K, Sun Z, Zhou F, *et al.* Relation between alignments of upper and subaxial cervical spine: A radiological study. *Arch Orthop Trauma Surg* 2011;131:857-62.
  20. Gwinn DE, Iannotti CA, Benzel EC, Steinmetz MP. Effective lordosis: Analysis of sagittal spinal canal alignment in cervical spondylotic myelopathy. *J Neurosurg Spine* 2009;11:667-72.
  21. Canavese F, Turcot K, De Rosa V, de Coulon G, Kaelin A. Cervical spine sagittal alignment variations following posterior spinal fusion and instrumentation for adolescent idiopathic scoliosis. *Eur Spine J* 2011;20:1141-8.
  22. Kuntz C 4<sup>th</sup>, Levin LS, Ondra SL, Shaffrey CI, Morgan CJ. Neutral upright sagittal spinal alignment from the occiput to the pelvis in asymptomatic adults: A review and resynthesis of the literature. *J Neurosurg Spine* 2007;6:104-12.
  23. Nojiri K, Matsumoto M, Chiba K, Maruiwa H, Nakamura M, Nishizawa T, *et al.* Relationship between alignment of upper and lower cervical spine in asymptomatic individuals. *J Neurosurg* 2003;99:80-3.
  24. Sherekar SK, Yadav YR, Basoor AS, Baghel A, Adam N. Clinical implications of alignment of upper and lower cervical spine. *Neurol India* 2006;54:264-7.
  25. Villavicencio AT, Babuska JM, Ashton A, Busch E, Roeca C, Nelson EL, *et al.* Prospective, randomized, double-blind clinical study evaluating the correlation of clinical outcomes and cervical sagittal alignment. *Neurosurgery* 2011;68:1309-16.
  26. Smith JS, Shaffrey CI, Lafage V, Blondel B, Schwab F, Hostin R, *et al.* Spontaneous improvement of cervical alignment after correction of global sagittal balance following pedicle subtraction osteotomy. *J Neurosurg Spine* 2012;17:300-7.
  27. Jang JS, Lee SH, Min JH, Maeng DH. Influence of lumbar lordosis restoration on thoracic curve and sagittal position in lumbar degenerative kyphosis patients. *Spine (Phila Pa 1976)* 2009;34:280-4.
  28. Oh T, Scheer JK, Eastlack R, Smith JS, Lafage V, Protosaltis TS, *et al.* Cervical compensatory alignment changes following correction of adult thoracic deformity: A multicenter experience in 57 patients with a 2-year follow-up. *J Neurosurg Spine* 2015;22:658-65.
  29. Inami S, Moridaira H, Takeuchi D, Shiba Y, Nohara Y, Taneichi H. Optimum pelvic incidence minus lumbar lordosis value can be determined by individual pelvic incidence. *Eur Spine J* 2016;25:3638-43.
  30. Liabaud B, Lafage V, Schwab FJ, Smith JS, Hamilton DK, Hiratzka JR *et al.* How Much Lordosis Is Required for Sagittal Alignment in Patients with High or Low Pelvic Incidence? In: North American Spine Society (NASS); November 12-15, 2014; 2014.
  31. Protosaltis T, Terran J, Soroceanu D, Moses MJ, Bronsard N, Smith J, *et al.* T1 Slope Minus Cervical Lordosis (TS-CL), the cervical answer to PI-LL, defines cervical sagittal deformity in patients undergoing thoracolumbar osteotomy. *Int J Spine Surg* 2018;12:362-70.
  32. Staub BN, Lafage R, Kim HJ, Shaffrey CI, Mundis GM, Hostin R, *et al.* Cervical mismatch: The normative value of T1 slope minus cervical lordosis and its ability to predict ideal cervical lordosis. *J Neurosurg Spine* 2018;30:31-7.
  33. Hyun SJ, Kim KJ, Jahng TA, Kim HJ. Relationship between T1 slope and cervical alignment following multilevel posterior cervical fusion surgery: Impact of T1 slope minus cervical lordosis. *Spine (Phila Pa 1976)* 2016;41:E396-402.
  34. Kim TH, Lee SY, Kim YC, Park MS, Kim SW. T1 slope as a predictor of kyphotic alignment change after laminoplasty in patients with cervical myelopathy. *Spine (Phila Pa 1976)* 2013;38:E992-7.
  35. Lee DH, Ha JK, Chung JH, Hwang CJ, Lee CS, Cho JH. A retrospective study to reveal the effect of surgical correction of cervical kyphosis on thoraco-lumbo-pelvic sagittal alignment. *Eur Spine J* 2016;25:2286-93.
  36. Lee SH, Son ES, Seo EM, Suk KS, Kim KT. Factors determining cervical spine sagittal balance in asymptomatic adults: Correlation with spinopelvic balance and thoracic inlet alignment. *Spine J* 2015;15:705-12.
  37. Weng C, Wang J, Tuchman A, Wang J, Fu C, Hsieh PC, *et al.* Influence of T1 slope on the cervical sagittal balance in degenerative cervical spine: An analysis using kinematic MRI. *Spine (Phila Pa 1976)* 2016;41:185-90.