UCSF
UC San Francisco Previously Published Works

Title

Tracheal Reconstruction Using Endotracheal Stent and Pectoralis Major Muscle Flap.

Permalink

https://escholarship.org/uc/item/65164356

Authors

Abbasi, Ali
Alcon, Andre
Patel, Alap
et al.

Publication Date

2023-03-01

DOI

10.1016/j.atssr.2022.07.002

Peer reviewed

eScholarship.org Powered by the California Digital Library
University of California

© 2022 The Authors. Published by Elsevier Inc. on behalf of The Society of Thoracic Surgeons.
This is an open access article under the CC BY-NC-ND license
(http://creativecommons.org/licenses/by-nc-nd/4.0/).
2772-9931
https://doi.org/10.1016/j.atssr.2022.07.002

Lung: Case Report

Tracheal Reconstruction Using Endotracheal Stent and Pectoralis Major Muscle Flap

Ali B. Abbasi, MD,[1] Andre Alcon, MD,[2] Alap Patel, MD,[2] Yaron Gesthalter, MD,[3] William Hoffman, MD,[2] and Johannes Kratz, MD[4]

We present a case of tracheal anastomotic dehiscence requiring circumferential tracheal replacement. We developed a novel approach by deploying a silicone stent using a hybrid surgical and endobronchial technique, followed by pectoralis major flap coverage. The patient has remained free from dyspnea 6 months after the operation. Our interdisciplinary approach represents a relatively straightforward solution to tracheal anastomotic dehiscence, one of the most devastating complications in thoracic surgery.

(Ann Thorac Surg Short Reports 2023;1:118-120)
© 2022 The Authors. Published by Elsevier Inc. on behalf of The Society of Thoracic Surgeons. This is an open access article under the CC BY-NC-ND license (http://creativecommons.org/licenses/by-nc-nd/4.0/).

Tracheal repair remains one of the most difficult challenges in thoracic surgery because of the tenuous blood supply, functional requirements of the trachea, and exposure to pathogens. The preferred reconstruction after tracheal resection remains primary anastomosis. However, anastomotic complications occur in 10% of patients,[1] which quickly leads to wound infection from exposure to respiratory flora. When reanastomosis is not possible, the surgeon must construct a tracheal conduit in a contaminated field. Here, we present a novel approach to tracheal reconstruction by deploying a silicone stent using a hybrid surgical and endobronchial approach, followed by pectoralis major muscle flap coverage.

The patient is a 62-year-old man who suffered a blast-burn injury requiring prolonged hospitalization and multiple endotracheal intubations. He presented to our facility with progressive dyspnea 16 weeks after initial injury and underwent urgent bronchoscopy, which identified a 2-cm segment of severely stenotic trachea 2.5 cm inferior to the vocal cords. We performed endobronchial incision and balloon dilation, which relieved the acute dyspnea.

Given the severity of stenosis, we recommended tracheal resection and anastomosis. Using a standard collar incision, we resected the second, third, and fourth tracheal rings and performed tracheal anastomosis using 4-0 polydioxanone (PDS) suture buttressed by strap muscles. The innominate artery was not exposed. Bronchoscopy on postoperative day 6 showed that the anastomosis was intact. However, on postoperative day 8, hemoptysis developed, and the patient was returned to the operating room, where we identified ulceration of the innominate artery due to pressure from the anterior trachea, requiring partial sternotomy and ligation of the artery.

One week later, clinical signs of tracheal dehiscence and wound infection developed. He was taken back to the operating room, where we found complete dehiscence of the tracheal anastomosis. The tracheal ends could not be sufficiently mobilized to close the 2-cm tracheal gap, so we placed a long endotracheal (ET) tube that spanned the defect, irrigated the wound, packed with wet-to-dry dressings, and returned the patient to the intensive care unit.

After multidisciplinary review including anesthesia, thoracic surgery, interventional pulmonology, plastic surgery, and head and neck surgery specialists, we returned to the operating room 5 days later for reconstruction. We initiated cross-table ventilation using an armored 4.0 ET tube in the distal trachea. Next, we cut a 15-mm silicone stent to 6 cm, marking the middle with a silk suture. We partially loaded the stent into a rigid stent deployer with the distal 4 cm outside of the deployer but furled up using polypropylene quick-release sutures (Figure 1). We intubated the patient with a rigid bronchoscope and advanced the stent deployer. Appropriate stent position was confirmed by the surgeons using the silk suture as a marker. We then removed the ET tube from the distal trachea, released the quick-release sutures to allow the stent to

Accepted for publication Jul 18, 2022.
[1]Department of Surgery, University of California, San Francisco, California; [2]Division of Plastic and Reconstructive Surgery, Department of Surgery, University of California, San Francisco, California; [3]Section of Interventional Pulmonary Medicine, Division of Pulmonary, Critical Care, Allergy and Sleep Medicine, University of California, San Francisco, California; and [4]Division of Cardiothoracic Surgery, Department of Surgery, University of California, San Francisco, California

Address correspondence to Dr Abbasi, UCSF Department of Surgery, 513 Parnassus Ave, S-321, San Francisco, CA 94143-0470; email: ali.abbasi@ucsf.edu.

unfold in the distal trachea, and deployed the stent into the proximal trachea. The patient was jet ventilated through the rigid bronchoscope while we verified satisfactory stent placement (Figure 2). We sutured the stent to the proximal and distal trachea using 2-0 PDS. We intubated the patient through the stent using fiberoptic bronchoscopy and inflated the ET tube balloon in the distal trachea.

Next, the plastic surgery team performed a left rotational pectoralis major muscle flap. Although either the left or right side could be used in principle, we used the left because of concern for the viability of a right pectoralis major flap. This was because the pectoralis major muscle flap relies on a dominant pedicle, the thoracoacromial artery, which is a branch of the innominate artery that had previously been ligated. After the flap was sutured in place to cover the tracheal defect, the neck and sternum were closed. The patient was discharged 4 weeks after this operation. On subsequent bronchoscopy, the stent has remained well positioned. Six months after discharge, the patient remains free from stridor or dyspnea and is doing well.

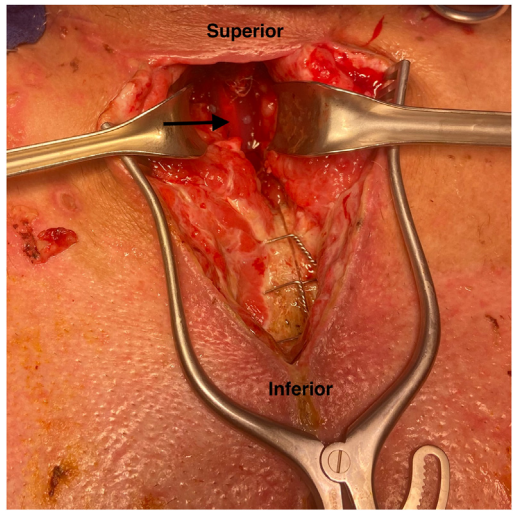

FIGURE 2 The stent is positioned in the tracheal gap (arrow).

COMMENT

Complete dehiscence of a tracheal anastomosis is a devastating complication. Few established techniques are suitable when circumferential tracheal replacement is required after anastomotic dehiscence. Proposed replacements include tracheal transplantation, decellularized allografts, autologous tissue reconstruction, and tissue-engineered tracheal replacements.[2] However, these procedures have had limited success because of their high risk for failure and relative complexity.[2] Here, we describe a multidisciplinary, single-stage approach to restoring tracheal continuity after anastomotic dehiscence.

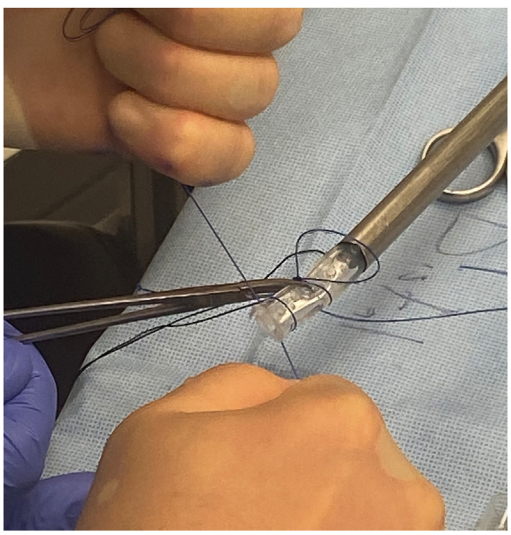

FIGURE 1 The stent is tied with quick-release sutures and partially loaded into a stent deployer.

Muscle flaps are useful for reconstruction in contaminated fields because they introduce well-vascularized tissue into the infected space. For tracheal repair, local flaps like pectoralis major, latissimus dorsi, and serratus anterior are commonly used. Our experience highlights that the left pectoralis major should preferably be used because of the known risk of trachea-innominate fistula, which could require ligation of the innominate artery and put the viability of a right-sided flap at risk. Small case series have demonstrated that these flaps reliably heal infected wounds after tracheal or bronchial suture line dehiscence in cases of non-circumferential or terminal bronchial defects.[3] However, when circumferential tracheal replacement is needed, muscle flaps must be combined with rigid supports to prevent airway collapse.

Rigid supports include autologous tissue and synthetic stents. Autologous tissue, like bone or cartilage grafts, would appear to be the optimal choice in an infected field[4] but require multistage procedures, which was not an option in this patient. Synthetic alternatives include silicone and metal stents. Metal stents can be difficult to remove because of tissue ingrowth, which resulted in a Food and Drug Administration Public Health Notification to avoid their use in benign disease. In a case report of tracheal reconstruction using a nitinol stent sutured to a radial artery fasciocutaneous free flap, the patient suffered from

Ann Thorac Surg Short Reports
2023;1:118-120

repeated pneumonia and required bronchoscopy every 5 to 6 weeks.[5] Given these concerns, we opted for a silicone stent.

Silicone stents cannot typically be deployed across circumferential defects because the stent begins to unfurl as soon as it leaves the deployer and thus cannot intubate the distal trachea. We developed a novel interdisciplinary approach to positioning the stent by using quick-release sutures and guiding the stent with direct visualization from the surgical field, all while continuing to ventilate the patient. We have found that quick-release sutures even allow stent deployment using flexible rather than rigid bronchoscopy, which can allow stenting of otherwise inaccessible airway defects.[6]

Silicone stents are associated with several complications, including granuloma formation, plugging, and migration,[7] leading some to suggest that silicone stents should not be used for long-term tracheal replacement.[2] To counteract these concerns, we sutured the stent in place to prevent migration. We also maintained the patient on an airway clearance regimen including inhaled hypertonic saline, the use of a flutter valve, and serial bronchoscopies. Case reports suggest that silicone stents can remain in place for decades if maintained properly.[8]

Successful tracheal reconstruction using hybrid endobronchial and surgical placement of a silicone stent followed by pectoralis major flap coverage has not been described before. By using the experience of an interdisciplinary team, we restored tracheal continuity in an infected field with a single operation. Our approach stands out because of its relative simplicity in achieving permanent tracheal reconstruction. To date, the patient has recovered well despite suffering one of the most serious complications after tracheal resection.

FUNDING SOURCES

The authors have no funding sources to disclose.

DISCLOSURES

The authors have no conflicts of interest to disclose.

PATIENT CONSENT

Obtained.

REFERENCES

1. Auchincloss HG, Wright CD. Complications after tracheal resection and reconstruction: prevention and treatment. *J Thorac Dis*. 2016;8:S160-S167.

2. Etienne H, Fabre D, Caro AG, et al. Tracheal replacement. *Eur Respir J*. 2018;51:1702211.

3. Smolle-Juettner FM, Pierer G, Schwarzl F, et al. Life-saving muscle flaps in tracheobronchial dehiscence following resection or trauma. *Eur J Cardiothoracic Surg*. 1997;12:351-355.

4. Shinohara H, Yuzuriha S, Matsuo K, Kushima H, Kondoh S. Tracheal reconstruction with a prefabricated deltopectoral flap combined with costal cartilage graft and palatal mucosal graft. *Ann Plast Surg*. 2004;53:278-281.

5. Beldholm BR, Wilson MK, Gallagher RM, Caminer D, King MJ, Glanville A. Reconstruction of the trachea with a tubed radial forearm free flap. *J Thorac Cardiovasc Surg*. 2003;126:545-550.

6. Gesthalter YB, Seeley EJ. Flexible bronchoscopic deployment of a silicone bronchial stent. *J Bronchology Interv Pulmonol*. 2020;27:e10-e12. https://doi.org/10.1097/LBR.0000000000000635

7. Folch E, Keyes C. Airway stents. *Ann Cardiothorac Surg*. 2018;7:273-283.

8. Verma A, Um SW, Koh WJ, et al. Long-term tolerance of airway silicone stent in patients with post-tuberculosis tracheobronchial stenosis. *ASAIO J*. 2012;58:530-534.