

UC Davis

Dermatology Online Journal

Title

Clinical resolution of generalized lichen amyloidosis with dupilumab: a new alternative therapy

Permalink

<https://escholarship.org/uc/item/64s0s466>

Journal

Dermatology Online Journal, 26(12)

Authors

Humeda, Yasmine
Beasley, Jenna
Calder, Kenneth

Publication Date

2020

DOI

10.5070/D32612051364

Copyright Information

Copyright 2020 by the author(s). This work is made available under the terms of a Creative Commons Attribution-NonCommercial-NoDerivatives License, available at <https://creativecommons.org/licenses/by-nc-nd/4.0/>

Peer reviewed

Clinical resolution of generalized lichen amyloidosis with dupilumab: a new alternative therapy

Yasmine Humeda¹ BS, Jenna Beasley² MD, Kenneth Calder³ MD

Affiliations: ¹Florida State University College of Medicine, Tallahassee, Florida, USA, ²Vital Dermatology, Pensacola, Florida, USA, ³Dermopath Diagnostics, Tampa, Florida, USA

Corresponding Author: Jenna Beasley, MD, 6202 North 9th Avenue Suite 2, Pensacola, FL 32504, Tel: 850-723-4394, Email: beasley@vitaldermatology.com

Abstract

Lichen amyloidosis is a subtype of primary localized cutaneous amyloidosis characterized by deposition of amyloid protein in the skin without visceral involvement. Although it is usually limited to localized areas of the body, it rarely can present in a generalized fashion and is severely pruritic. The limited form is treated with skin directed therapies such as topical or intralesional corticosteroids or topical tacrolimus but the generalized type is more difficult to treat. We present a patient with generalized primary cutaneous lichen amyloidosis successfully treated with dupilumab.

Keywords: lichen amyloidosis, primary localized cutaneous amyloidosis, amyloid, dupilumab

Introduction

Lichen amyloidosis (LA), a subtype of primary localized cutaneous amyloidosis, presents clinically as multiple, intensely pruritic, hyperpigmented, hyperkeratotic papules on the anterior legs, thighs, and forearms that later coalesce into plaques [1]. While LA is often limited to localized areas of the body, it can present in a generalized fashion [2]. This form may have a familial component, but is often without known etiology [3-4].

The limited form is treated with skin-directed therapies such as topical or intralesional corticosteroids or topical tacrolimus; management of the generalized type is more difficult owing to

limited options of variable safety and efficacy. Success has been reported with agents such as oral cyclosporine, acitretin, isotretinoin, light therapy, calcipotriene, and amitriptyline [5-7]. To the best of our knowledge, the use of dupilumab, an interleukin (IL)-4 and IL13 α -antagonist, in the treatment of LA has never before been reported. We present a case of generalized primary cutaneous LA successfully treated with dupilumab.

Case Synopsis

A 76-year-old male presented with a four-year history of generalized refractory intense pruritus. His medical history was negative for atopic conditions, such as atopic dermatitis, asthma, and allergic rhinitis but was pertinent for prostate cancer four years prior to presentation. No new prescription or over-the-counter medications or supplements were initiated prior to the onset of symptoms. Family history was negative for chronic skin conditions and atopic disease. Cutaneous examination revealed generalized subtle, rippled, dyschromic gray-brown thin plaques with confluent involvement of the trunk and extremities (**Figure 1A**). Biopsy of the left arm revealed homogenous eosinophilic material within the papillary dermis with an overlying hyperplastic epidermis consistent with a diagnosis of lichen amyloidosis (**Figure 2**). Work up for underlying causes of itch including serum protein electrophoresis and serum light chains was within normal limits. Liver, renal, and thyroid functions, chest X-ray, and hepatitis serologies were normal.

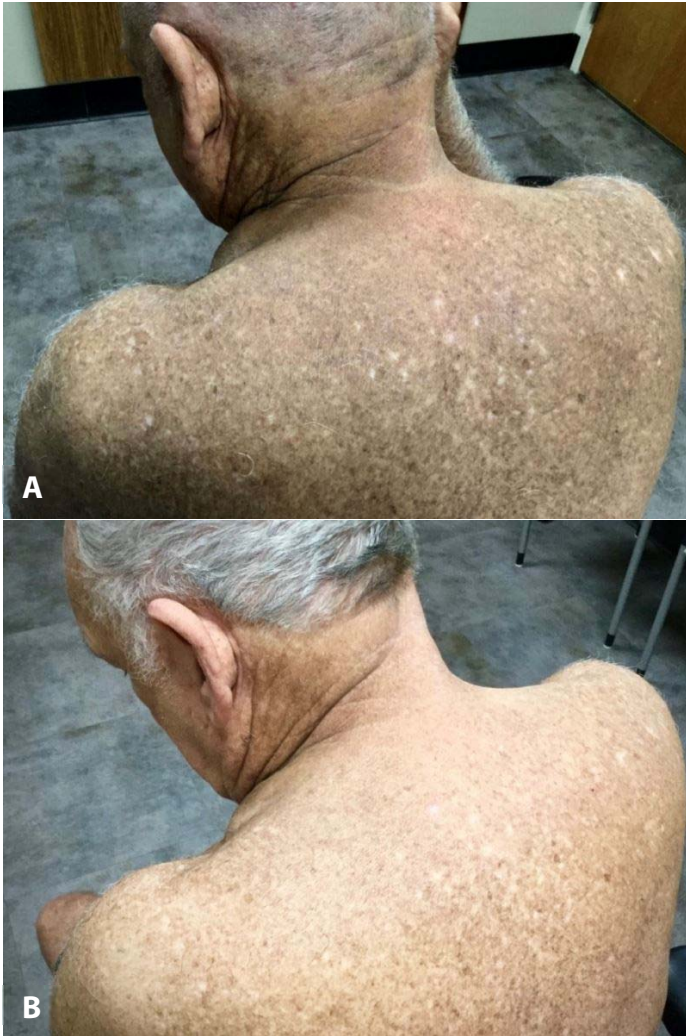

Figure 1. Clinical photographs of lichen amyloidosis before and after treatment. **A)** Patient's back before treatment revealing generalized subtle, rippled, dyschromic gray-brown thin plaques. **B)** Patient's back after 9 months of treatment with dupilumab showing improvement of skin texture and dyschromia.

HIV testing was declined by the patient and considered low risk owing to lack of risk factors. Serum IgE was mildly elevated at 200kU/l (normal 10-100kU/l). A complete blood count with differential noted hypereosinophilia of 1500 cells/ μ L (normal 15-500 cells/ μ L). Additional testing for causes of hypereosinophilia including a complete evaluation by an allergist, serum tryptase, stool ova and parasite, peripheral flow cytometry, and bone marrow biopsy were unremarkable.

Prior treatment consisting of narrow band-ultraviolet B phototherapy, oral anti-pruritics such as amitriptyline, hydroxyzine, and doxepin, and a course of oral acitretin were without benefit. Given

the patient's intractable pruritus and hypereosinophilia, he was treated with benralizumab, an anti-IL5 receptor- α monoclonal antibody, without improvement despite normalization of eosinophil count. Use of cyclosporine was contraindicated because of the history of prostate cancer. Treatment was then initiated with dupilumab 600mg subcutaneously and continued at 300mg every two weeks. Within two weeks, the patient had complete resolution of his pruritus. Within three months, the patient had clinical improvement of his skin lesions with flattening and lightening of the gray-brown plaques (**Figure 1B**). The patient continues on dupilumab to date (9-month course) and maintains resolution of pruritus and continued clinical improvement.

Case Discussion

Primary localized cutaneous amyloidosis is the extracellular deposition of amyloid within the skin without visceral involvement. It is classified into three main types: macular, nodular, and lichen amyloidosis [7]. Lichen amyloidosis is the most common form of primary localized cutaneous amyloidosis, typically presenting in the fifth or sixth decade of life in men and individuals with darker skin pigmentation [8-9]. It is characterized by multiple discrete pruritic, firm, hyperpigmented,

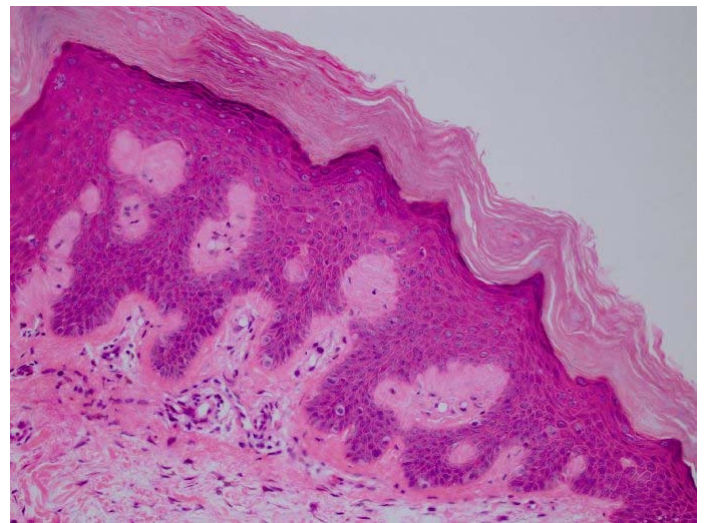


Figure 2. H&E histopathologic image. Skin biopsy revealed homogenous eosinophilic material within the papillary dermis with an overlying hyperplastic epidermis consistent with lichen amyloidosis, 200 \times .

hyperkeratotic papules on the shins, thighs, or forearms that later coalesce into plaques appearing in a rippled pattern [1,4]. Histologically, LA appears as eosinophilic amorphous deposits in the papillary dermis with hyperkeratosis and acanthosis of the epidermis [5,7]. Although it is commonly an isolated finding, LA can be associated with other diseases such as atopic dermatitis, mycosis fungoides, lichen planus, HIV, multiple endocrine neoplasia type 2A, angiolymphoid hyperplasia with eosinophilia, ankylosing spondylitis, autoimmune thyroiditis, and hyperthyroidism [7,10-13].

The pathogenesis of LA is not completely understood, although, viral and genetic etiologies have been implicated [13-14]. Given that pruritus is often the preceding symptom, it has been proposed that chronic scratching and friction of the skin may result in dermal amyloid deposition by inducing keratinocyte degradation and amyloid formation by dermal macrophages and fibroblasts [5,7]. Previous studies suggest that IL31 may play a role in the intense pruritus associated with primary localized cutaneous amyloidosis [15].

Treatment for LA is aimed at alleviating the distressing symptoms and addressing cosmetic complaints. However, the plaques that form over time are often resistant to treatment [4,10]. Therapeutic options are limited and inconsistent, many times resolving the pruritus without resolution of the lesions [4]. Success has been reported with topical or intralesional corticosteroids, topical tacrolimus, antihistamines, ultraviolet light therapy, laser therapy, oral cyclosporine, acitretin, isotretinoin, calcipotriene, amitriptyline,

cyclophosphamide, dermabrasion, and scalpel scraping [1,4-7].

Dupilumab is a human anti-interleukin (IL)-4 receptor- α monoclonal antibody that blocks signaling of both IL4 and IL13. It has been suggested that dupilumab may be an effective treatment for pruritus by directly blocking IL4 and IL13 on sensory neurons. It may also improve pruritus by inhibiting T helper 2 cells from producing IL31, a known potent inciter of itch [16]. This may be one mechanism for dupilumab's success in treating our patient. However, given the generalized nature of cutaneous amyloid in our patient's case, it is unlikely that resolution of pruritus alone can account for his complete clinical improvement. Further studies are warranted to elucidate the complex pathogenesis of generalized LA and the role of dupilumab in its treatment, possibly by modulating other unknown immune mediators involved in the formation of amyloid [5].

Conclusion

Considering the marked success of dupilumab in the treatment of this exceptionally challenging generalized case, and its long-term safety in the treatment of other skin diseases, in addition to limited effective therapeutic options, the use of dupilumab may be a first-line treatment for generalized LA and a wide variety of other skin conditions associated with itch [17].

Potential conflicts of interest

The authors declare no conflicts of interests.

References

1. Weidner T, Illing T, Elsner P. Primary localized cutaneous amyloidosis: A systematic treatment review. *Am J Clin Dermatol*. 2017;18:629-42. [PMID: 28342017].
2. Tursen U, Kaya TI, Dusmez D, Ikizoglu G. Case of generalized lichen amyloidosis. *Int J Dermatol*. 2003;42: 649-51. [PMID: 12890115].
3. Tiwary A, Mishra D, Chaudhary S. Amyloidosis cutis dyschromica: A rare dyschromic subtype of primary cutaneous amyloidosis. *Pig Intl*. 2016;3:33-6. [DOI: 10.4103/2349-5847.184259].
4. Ladizinski B, Lee KC. Lichen amyloidosis. *CMAJ*. 2014;186:532. [PMID: 24130236].
5. Behr F, Levine N, Bangert J. Lichen amyloidosis associated with atopic dermatitis- clinical resolution with cyclosporine. *Arch Dermatol*. 2001;137:553-5. [PMID: 11346332].
6. Atacan D, Ergin C, Çelik G, Gönül M, Adabağ A. Oral isotretinoin: A new treatment alternative for generalized lichen amyloidosis. *Australas J Dermatol*. 2016;57:246-7. [PMID: 27469487].
7. Gönül M, Cakmak SK, Kayaçatin S. Generalized lichen amyloidosis and hyperthyroidism: coincidence or association. *Postepy Dermatol Alergol*. 2013;30:265-7. [PMID: 24278086].
8. Tay CH, Dacosta JL. Lichen Amyloidosis- clinical study of 40 cases.

- Br J Dermatol.* 1970;82:129-36. [PMID: 5435070].
9. Chen JF, Chen YF. Question: Can you identify this condition? Lichen amyloidosis. *Can Fam Physician.* 2012;58:1233-5. [PMID: 23152462].
 10. Salim T, Shenoï SD, Balachandran C, Mehta VR. Lichen amyloidosis: a study of clinical, histopathologic and immunofluorescence findings in 30 cases. *Indian J Dermatol Venereol Leprol.* 2005;71:166-9. [PMID: 16394404].
 11. Hongcharu W, Baldassano M, Gonzalez E. Generalized lichen amyloidosis associated with chronic lichen planus. *J Am Acad Dermatol.* 2000;43:346-8. [PMID: 10901719].
 12. Gül U, Kiliç A, Bilgili S, et al. Lichen amyloidosis with face involvement. *Int J Dermatol.* 2008;47: 1201-3. [PMID: 18986463].
 13. Newton J, Jagjivan A, Bhogal B, McKee PH, McGibbon DH. Familial primary cutaneous amyloidosis. *Br J Dermatol.* 1985;112:201-8. [PMID: 3970841].
 14. Drago F, Ranieri E, Pastorino A, et al. Epstein-barr virus-related primary cutaneous amyloidosis-successful treatment with acyclovir and interferon-alpha. *Br J Dermatol.* 1996;134:170-4. [PMID: 8745909].
 15. He A, Zampella J, Kwatra S. Interleukin-31 receptor and pruritus associated with primary localized cutaneous amyloidosis. *Br J Dermatol.* 2016;175:433.[PMID: 26941119].
 16. Ko MJ, Peng YS, Chen HY. Interleukin-31 is associated with uremic pruritus in patients receiving hemodialysis. *J Am Acad Dermatol.* 2014;71:1151-9.[PMID: 25270263].
 17. Seegräber M, Srour J, Walter A, Knop M, Wollenberg A. Dupilumab for treatment of atopic dermatitis. *Expert Rev Clin Pharmacol.* 2018;11:467-74. [PMID: 29557246].