

# UC San Diego

## UC San Diego Previously Published Works

### Title

Continuous Infraclavicular Brachial Plexus Block for Postoperative Pain Control at Home

### Permalink

<https://escholarship.org/uc/item/64g032mf>

### Journal

Anesthesiology, 96(6)

### ISSN

0003-3022

### Authors

Ilfeld, Brian M  
Morey, Timothy E  
Enneking, F Kayser

### Publication Date

2002-06-01

### DOI

10.1097/00000542-200206000-00006

Peer reviewed

# Continuous Infraclavicular Brachial Plexus Block for Postoperative Pain Control at Home

## A Randomized, Double-blinded, Placebo-controlled Study

Brian M. Ilfeld, M.D.,\* Timothy E. Morey, M.D.,† F. Kayser Enneking, M.D.‡

**Background:** This randomized, double-blinded, placebo-controlled study investigated the efficacy of patient-controlled regional analgesia using an infraclavicular brachial plexus perineural catheter and a portable infusion pump for outpatients undergoing moderately painful, upper extremity orthopedic surgery.

**Methods:** Preoperatively, patients (n = 30) received an infraclavicular nerve block and perineural catheter. Postoperatively, patients were discharged home with oral narcotics and a portable infusion pump delivering study solution (0.2% ropivacaine or 0.9% saline) *via* the catheter for 3 days. Investigators and patients were blinded to random group assignment. Daily end points included pain scores at rest and with limb movement, narcotic use and side effects, sleep quality, patient satisfaction, and symptoms of catheter- or local anesthetic-related complications.

**Results:** Ropivacaine (n = 15) infusion significantly reduced pain compared with saline (n = 15) infusion ( $P < 0.001$ ). For example, the average pain with movement (scale, 0–10) on postoperative day 1 was  $6.1 \pm 2.3$  for the saline group *versus*  $2.5 \pm 1.6$  for the ropivacaine group ( $P < 0.001$ ). Oral narcotic use and related side effects were significantly decreased in the ropivacaine group. For example, on postoperative day 1, mean tablet consumption was  $5.5 \pm 2.4$  and  $1.7 \pm 1.6$  for the saline and ropivacaine groups, respectively ( $P < 0.001$ ). Sleep disturbance scores were 10-fold greater for saline administration than for ropivacaine infusion ( $P < 0.001$ ). Overall satisfaction was significantly greater in the ropivacaine group. No catheter- or local anesthetic-related complications occurred.

**Conclusion:** After moderately painful orthopedic surgery of the upper extremity, ropivacaine infusion using a portable, mechanical pump and an infraclavicular brachial plexus perineural catheter at home decreased pain, sleep disturbances, narcotic use and related side effects, and improved overall satisfaction.

This article is accompanied by an Editorial View. Please see: Klein SM: Beyond the hospital: Continuous peripheral nerve blocks at home. ANESTHESIOLOGY 2002;96:1283–4.

\* Fellow in Anesthesiology, † Assistant Professor of Anesthesiology, ‡ Associate Professor of Anesthesiology, and Orthopedics and Rehabilitation, Departments of Anesthesiology, and Orthopedics and Rehabilitation, University of Florida College of Medicine.

Received from the Departments of Anesthesiology and Orthopedics and Rehabilitation, University of Florida College of Medicine, Gainesville, Florida. Submitted for publication September 24, 2001. Accepted for publication January 17, 2002. Support for this project was received from the University of Florida, Department of Anesthesiology, Gainesville, Florida, and the I. Heermann Anesthesia Foundation, Inc., Gainesville, Florida. An abstract of the article was presented at the Annual Meeting of the American Society of Anesthesiologists, October 15, 2001.

Address reprint requests to Dr. Enneking: Department of Anesthesiology, PO Box 100254, Gainesville, Florida 32610-0254. Address electronic mail to: enneking@anest2.anest.ufl.edu. Individual article reprints may be purchased through the Journal Web site, www.anesthesiology.org.

MORE than 40% of ambulatory patients undergoing orthopedic procedures experience moderate-to-severe postoperative pain at home.<sup>1</sup> Single-injection brachial plexus neural blockade, such as the infraclavicular block, provides an average of 12–14 h of analgesia after upper extremity procedures.<sup>2</sup> After block resolution, ambulatory patients must usually rely on oral narcotics to control pain. Narcotics, however, are associated with undesirable side effects, such as nausea and vomiting, sedation, and pruritus. Previous investigations involving hospitalized patients suggest that local anesthetic infused *via* perineural catheters decreases postoperative pain and narcotic requirements after a variety of procedures.<sup>3–7</sup> Although at-home perineural infusions have been described in several series of patients,<sup>8–10</sup> their efficacy has not been investigated in a randomized, double-blinded, placebo-controlled manner.

The elastomeric balloon pumps previously described for ambulatory infusions are markedly limited in their local anesthetic reservoir volume and, therefore, infusion duration. In addition, these pumps do not allow for patient-controlled local anesthetic bolus doses and a basal infusion. Without the option for a bolus dose, oral narcotics are required for break-through pain. Patient-controlled local anesthetic administration, also called patient-controlled regional analgesia (PCRA), provides equivalent or superior analgesia with lower local anesthetic consumption compared with continuous infusions alone with a variety of perineural techniques.<sup>11–13</sup> PCRA is important for ambulatory patients because the infusion may be tailored to provide a minimum basal rate, yet allow bolus dosing for break-through pain and before physical therapy. With few exceptions, however, the PCRA-capable infusion pumps that have been described are large, heavy, and technically sophisticated. For these reasons, use of PCRA-capable infusion pumps has required patient hospitalization. Recently, a portable, PCRA-capable pump with simple controls has been described for perineural local anesthetic infusion.<sup>14,15</sup> We hypothesized that these pumps could be used in patients' homes to safely and effectively reduce pain after moderately painful surgical procedures.

The objectives of this randomized, double-blinded, placebo-controlled study were to determine (1) if local anesthetic infused *via* an infraclavicular brachial plexus perineural catheter decreases postoperative pain, oral narcotic requirements, narcotic-related side effects, and sleep disturbances; (2) if a small, portable, battery-pow-

ered, infusion pump that allows PCRA is reliable and can be used successfully by outpatients; and (3) if patients accept and understand the catheter and pump system well enough for postoperative analgesia at home to be successful.

## Materials and Methods

### Enrollment

All protocols were approved by the Institutional Review Board. We prospectively enrolled patients scheduled for unilateral, moderately painful ambulatory orthopedic surgery of the upper extremity involving, or distal to, the elbow. Inclusion criteria included (1) American Society of Anesthesiologists (ASA) physical status I or II, (2) age 18 yr or more, (3) ability to provide informed consent, and (4) understanding of the possible local anesthetic-related complications, the study protocol, and care of the catheter and infusion pump system. In addition, patients were required to have a caretaker who would remain with them through the first postoperative night and be available and capable to remove the catheter in the evening of postoperative day 2. Exclusion criteria included any contraindication to infraclavicular nerve block, history of narcotic dependence, current chronic analgesic therapy, coagulopathy, known hepatic or renal insufficiency, peripheral neuropathy, and patient refusal.

### Catheter Insertion

After written, informed consent was obtained, an intravenous cannula was placed, and standard ASA noninvasive monitors were applied. Oxygen (8–10 l/min) was administered *via* a facemask. Intravenous midazolam and fentanyl were titrated for patient comfort in divided doses, while ensuring that patients remained responsive to verbal cues throughout the procedure. After sterile preparation and draping, a nerve stimulator (Stimuplex-DIG, B. Braun Medical, Bethlehem, PA) and a 102-mm, 18-gauge, insulated stimulating needle (Contiplex, B. Braun Medical, Bethlehem, PA) were used to place an infraclavicular brachial plexus block using the landmarks previously described by Wilson *et al.*<sup>16</sup> With the patient lying supine and the operative limb by the patient's side, a skin wheal was raised 2 cm medial and 2 cm caudal to the center of the coracoid process. The needle was inserted through the skin wheal with the bevel pointed toward the patient's head and the long axis of the needle perpendicular to the gurney in all planes. With continuous aspiration and the nerve stimulator initially set at 1.2 mA and 2 Hz, the needle was advanced directly posterior. If the brachial plexus was not identified after 5–8 cm of insertion, depending on patient habitus, the needle was withdrawn to the skin and redirected either cephalad or caudad in the paramedian sagittal plane until discrete, stimulated motion occurred in any digit(s) with

a current between 0.30 and 0.55 mA. Directing the needle tip out of the paramedian sagittal plane was strictly prohibited—neither medially toward the lung nor laterally toward the terminal nerves of the brachial plexus. Flexion or extension at the elbow or wrist that resulted in motion of the fingers, without intrinsic hand or digit motion, was rejected.

For the surgical block, 50 ml of anesthetic solution was injected in divided doses, with gentle aspiration every 3 ml. The injectate contained mepivacaine, 1.5%; sodium bicarbonate, 5 mEq; epinephrine, 125  $\mu$ g; and preservative-free clonidine, 100  $\mu$ g. A 20-gauge, multiport, polyamide catheter (B. Braun Medical, Bethlehem, PA) was then passed through the needle so that 3 cm of the catheter was located past the tip of the needle. Early in this investigation, we noted frequent intravascular placement of the catheter if a moderate amount of resistance was encountered during catheter advancement. Therefore, during the remainder of this investigation, when resistance was encountered when the catheter reached the needle tip, the catheter was held securely in place while the needle was withdrawn over the catheter (see Discussion). This technique left the catheter tip at the original location of the tip of the needle. After being withdrawn roughly halfway to the skin, the needle was held in place, and the catheter was advanced 5 cm. Subsequently, the needle was completely withdrawn over the remaining catheter, leaving 5 cm of catheter “slack” between the skin and brachial plexus.

After negative aspiration, the catheter was injected with 1 ml of sterile saline, 0.9%, to ensure its patency. The catheter was then secured with sterile liquid adhesive (Mastisol, Ferndale Laboratory, Ferndale, MI) and sterile tape (Steri-Strips, 3M Corporation, St. Paul, MN). An occlusive dressing (Tegaderm, 3M Corporation, St. Paul, MN) was placed over the site to retain sterility, and the catheter further secured to the top of the original dressing with a second dressing. Patients were withdrawn from the study if a sensory block failed to develop at 15 min or if the catheter was placed in a vessel. Block failure was defined as a lack of any sensory changes to touch from baseline in the forearm or hand. Specific nerve distributions and degree of sensory blockade were not formally evaluated for purposes of this study.

The infraclavicular block was intended to provide surgical anesthesia for all patients. Intraoperative sedation was provided with intravenous propofol (0–50  $\mu$ g  $\cdot$  kg<sup>-1</sup>  $\cdot$  min<sup>-1</sup>, titrated for patient comfort). Alternatively, higher doses of intravenous propofol and nitrous oxide inhaled *via* a laryngeal mask airway were used at the attending anesthesiologists' discretion. Whether block inadequacy or simply patient or physician preference resulted in a general anesthetic was not evaluated. No anesthetic or analgesic medication besides propofol and nitrous oxide were administered after infraclavicular block placement.

### Randomization

After successful block and catheter placement, patients were assigned to receive one of two possible postoperative catheter infusions: ropivacaine, 0.2%, or sterile saline, 0.9%. An investigational pharmacist using a computer-generated randomization table performed group assignment. Group designation was not revealed to the clinical investigators until after all clinical data were collected and the study completed.

Postoperatively, when patients met standard ambulatory home-discharge criteria, the catheter was tested for intravascular positioning with gentle aspiration followed by a 10-ml incremental bolus of study fluid into which 30  $\mu$ g of fresh epinephrine had been added. Subsequently, a portable, programmable, battery-powered, mechanical infusion pump (Microject PCA Pump, Sorenson Medical, West Jordan, UT) was attached to the catheter with a reservoir containing 550 ml of study solution. A continuous infusion of 8 ml/h was begun with a 2-ml patient-controlled bolus available every 20 min.

The patient and caretaker were given standard postoperative outpatient instructions. In addition, verbal and written instructions on the use of the pump and catheter were given. Specific attention was given to signs and symptoms of local anesthetic toxicity, catheter site infection, and catheter migration. Multiple telephone and pager numbers for physicians available at all times were given to each patient. Patients were instructed not to drive motorized vehicles and to keep the operative arm in a sling during the infusion period. The following supplies were given to patients: a medication log, a prescription for an oral narcotic (oxycodone, 5 mg, combined with acetaminophen, 500 mg), two additional occlusive dressings, a pair of nonsterile gloves, and a hospital-addressed and stamped padded envelope for return of the pump. The narcotic prescription was identical to that used for patients undergoing similar operations at our facility, but who did not participate in this study.

In the event of break-through pain, patients were instructed to first use the bolus function of the infusion pump. If the pain had not resolved after 20 min, patients were instructed to use oral narcotics and to record this use in their medication log. Before discharge from the ambulatory surgical center, all patients were given oral methadone, 5 mg, because approximately one half of the enrolled population would experience resolution of surgical anesthesia without the benefit of a ropivacaine perineural infusion for analgesia.

### Patient Follow-up Evaluation

Patients could contact a physician at any time during the study period by telephone. Patients were telephoned by one of the authors (B.I.), beginning the night of surgery and each evening thereafter, through the night after catheter removal. Information obtained included

pain scores at rest and with limb motion, oral narcotic use, narcotic-related side effects, and sleep quality (see Appendix 1 for questionnaire). Gross sensory and motor function were reviewed. Patients were also questioned about symptoms of local anesthetic toxicity and the appearance of the catheter site. In the evening after surgery, resolution of surgical anesthesia was confirmed. In the first evening after postoperative day 1, the patient was asked if they recalled self-administering an average of one or more bolus injections every 2 h that day. If so, the patient reprogrammed the basal infusion rate of the pump from 8 to 9.9 ml/h (pump maximum) using instructions provided by the physician.

In the evening of postoperative day 2, patients' caretakers were instructed on removal of the catheter using the pair of nonsterile gloves, with the physician in telephone contact throughout. The presence of a blue catheter tip confirmed complete removal. Residual study fluid was disposed of in a sink or toilet. Patients were asked if they would repeat this method of postoperative pain control in the future, and their satisfaction with their postoperative pain control was noted on a scale of 0-10 (0 = very dissatisfied, 10 = very satisfied). In the evening of postoperative day 3, patients were instructed to return their medication log and infusion pump to the surgical center in the preaddressed and stamped envelope the following morning.

### Statistical Analysis

Sample size calculations were centered around our primary hypothesis that local anesthetic infusion *via* an infraclavicular perineural catheter decreases postoperative pain. To this end, we chose the outcome variable "worst pain with movement" on postoperative day 1 to determine the proper sample size. We estimated a difference in mean values of the two groups to be approximately 2. Similarly, we considered the SD of each group to be approximately 2. Using  $\alpha$  and  $\beta$  values of 0.05 and 0.80, respectively, we estimated that approximately 15 patients would be required for each group. Continuous data are reported as mean  $\pm$  SD. Normality of distribution was determined using the Kolmogorov-Smirnov test with Lilliefors correction (SigmaStat 2.03, SPSS, Inc., Chicago, IL). Single comparisons were tested using the Student *t* test. Multiple comparisons were made using analysis of variance (ANOVA) with Tukey *post hoc* pairwise test when appropriate. Categorical data were analyzed using either chi-square or the Fisher exact test as appropriate.  $P < 0.05$  was considered significant.

## Results

Thirty-five patients were approached for study inclusion, and all chose to be enrolled. All patients had an infraclavicular block placed successfully. Five patients

**Table 1. Population Data for the Two Study Groups**

	Ropivacaine	Placebo	P Value
Patients (n)	15	15	1.000
Age (yr)	47 ± 16	49 ± 18	0.780
Sex (M/F)	10/5	11/4	1.000
Height (cm)	170 ± 10	168 ± 14	0.672
Weight (kg)	80 ± 24	76 ± 15	0.554
IV fentanyl (μg)*	200 ± 54	180 ± 25	0.201
IV midazolam (mg)*	2.4 ± 1.1	2.4 ± 0.7	1.000
Tourniquet duration (min)	67 ± 29	65 ± 24	0.840
Surgery duration (min)	76 ± 48	71 ± 23	0.686

Values are mean ± SD. \* Sedation only for preoperative block placement.

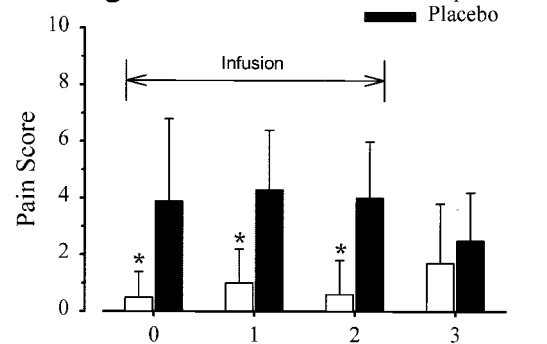
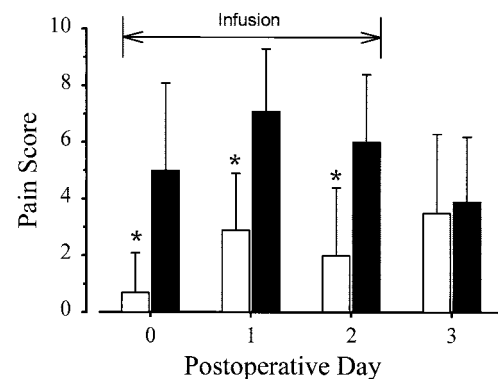
were withdrawn from the study because of intravascular catheter placement (all discovered immediately after insertion). The remaining 30 patients were randomized to receive either ropivacaine (n = 15) or placebo (n = 15) infusion. There were no statistically significant differences between these groups in demographics, intravenous sedation for block placement, tourniquet and surgical duration, or surgical procedures (tables 1 and 2). All patients were pain-free with a dense sensory block (determined grossly) at discharge from the surgical facility.

Patients receiving ropivacaine experienced significantly less postoperative pain compared with patients receiving normal saline during rest (figs. 1A and B) and limb movement (figs. 2A and B). The ropivacaine group used significantly fewer narcotic tablets to remain comfortable (fig. 3). In addition, they experienced fewer narcotic-related side effects and sleep disturbances than the placebo group (table 3). Three patients, all from the ropivacaine group, used their bolus function an average of 1 time every 2 h and therefore had their basal infusion rate increased from 8 to 9.9 ml/h on postoperative day 1 (pump maximum). The average satisfaction with postoperative analgesia on a scale of 0 (dissatisfied) to 10 (very satisfied) was ranked  $9.2 \pm 1.1$  by those who received ropivacaine and  $5.8 \pm 3.0$  by those who received placebo ( $P = 0.002$ ). Whereas all patients who received ropivacaine would repeat this analgesic method, only 8 patients (53%) receiving placebo would repeat this technique ( $P = 0.006$ ).

**Table 2. Surgical Procedures for Each Study Group**

Surgical Procedure	Ropivacaine	Placebo
Elbow ORIF	1	1
Metacarpal arthroplasty	0	1
Radial or ulnar ORIF	5	4
Suspensionplasty	4	3
Ulnar transposition	1	1
Wrist carpectomy or capsulodesis	1	1
Wrist fusion or shrinkage	3	4
Total patients	15	15

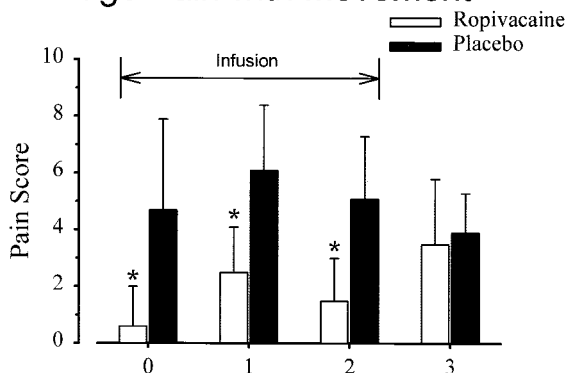
ORIF = open reduction, internal fixation.

**A. Average Pain at Rest****B. Worst Pain at Rest**

**Fig. 1.** Effects of infraclavicular catheter infusion of either ropivacaine or placebo on pain at rest after moderately painful upper extremity surgery. Pain severity was scored as the average (A) and worst (B) pain reported at rest (scale, 0–10). The infusion was discontinued after postoperative day 2 as indicated by the horizontal line. Data are expressed as mean ± SD for patients randomly assigned to receive either 0.2% ropivacaine (n = 15) or 0.9% saline placebo (n = 15). \* $P < 0.05$  compared with placebo for a given postoperative day.

There were no apparent local anesthetic- or catheter-related complications during infusion. All catheters remained *in situ* throughout the study period. Patients used and reprogrammed the portable, mechanical infusion pumps without difficulty. Likewise, patients' caretakers were able to safely remove all of the perineural catheters at home. The only complaint consistently noted by patients (roughly 50%) was leakage of clear fluid from under the occlusive dressing. In addition, one infusion pump had to be replaced on the morning of postoperative day 1 when it alarmed continuously without apparent cause. This patient, who was receiving a saline infusion, returned to the surgical center roughly 2 h after the initial alarm to have the pump replaced. Pump examination by the manufacturer confirmed a pump malfunction, and the unit was removed from service. Approximately 30% of patients had at least one nonscheduled contact with the on-call physician during the course of their infusion. All infusion pumps were returned to the surgical center *via* the postal service.

A. Average Pain with Movement



B. Worst Pain with Movement

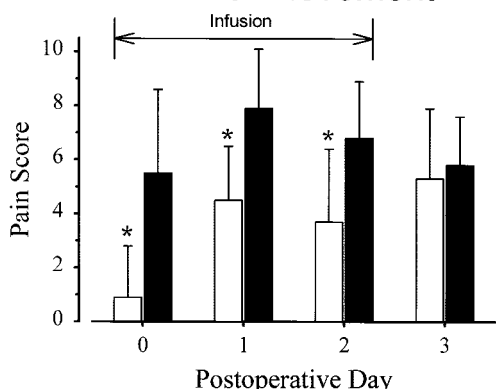


Fig. 2. Effects of infraclavicular catheter infusion of either ropivacaine or placebo on pain during movement after moderately painful upper extremity surgery. Pain severity was scored as the average (A) and worst (B) pain reported during movement (scale, 0–10). The infusion was discontinued after postoperative day 2 as indicated by the horizontal line. Data are expressed as mean ± SD for patients randomly assigned to receive either 0.2% ropivacaine (n = 15) or 0.9% saline placebo (n = 15). \*P < 0.05 compared with placebo for a given postoperative day.

Discussion

This randomized, double-blinded, placebo-controlled study demonstrates that potent analgesia is achievable using a perineural infusion of ropivacaine via an infraclavicular brachial plexus catheter after moderately painful upper extremity surgery. Consequently, patients experienced a significant decrease in sleep disturbances, oral narcotic use, and narcotic-related side effects. These benefits were attained for ambulatory patients with the use of a portable, programmable, PCRA-capable infusion pump. The degree of analgesia and the relative simplicity of the catheter and pump system led to a high rate of satisfaction for all subjects receiving ropivacaine.

Infraclavicular Approach

This approach to the brachial plexus was chosen for several reasons. Unlike axillary placement, the initial nerve block and postoperative infusion reliably provide anesthesia and analgesia to the musculocutaneous nerve with a single injection and catheter.<sup>17,18</sup> Further, catheters in this location are more comfortable for patients and resistant to dislodgement compared with an axillary placement.<sup>19</sup>

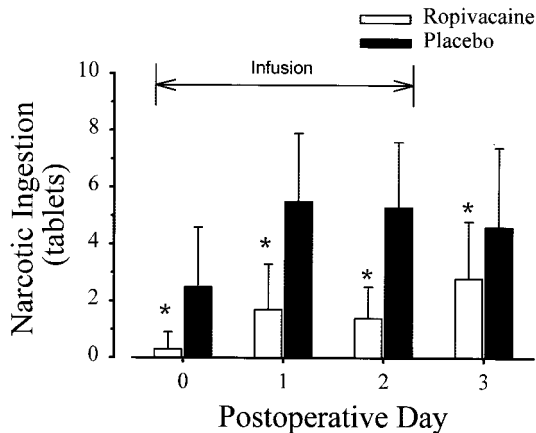


Fig. 3. Effects of infraclavicular catheter infusion of either ropivacaine or placebo on narcotic use after moderately painful upper extremity surgery. Each tablet consisted of oxycodone, 5 mg, and acetaminophen, 500 mg. Patients recorded narcotic use in a daily log. The infusion was discontinued after postoperative day 2 as indicated by the horizontal line. Data are expressed as mean ± SD for patients randomly assigned to receive either 0.2% ropivacaine (n = 15) or 0.9% saline placebo (n = 15). \*P < 0.05 compared with placebo for a given postoperative day.

ters in this location are more comfortable for patients and resistant to dislodgement compared with an axillary placement.<sup>19</sup>

Initially described by Whiffler<sup>20</sup> and later by Wilson,<sup>16</sup> the coracoid technique used in this study was chosen for several reasons. It is simple to perform,<sup>16,20</sup> has a high success rate,<sup>20</sup> and, theoretically, reliably places the catheter tip at the level of the brachial plexus cords.<sup>16</sup> By keeping the length of the needle exclusively in the

Table 3. Medication-related Side Effects\*

	Ropivacaine	Placebo	P Value
POD 1: During Infusion			
Nausea	2	8	0.028
Sedation	5	11	0.037
Pruritus	2	4	0.651
Difficulty sleeping 2° pain	0	9	<0.001
Number of awakenings 2° pain	0.1 ± 0.4	2.0 ± 1.7	<0.001
POD 2: During Infusion			
Nausea	3	6	0.268
Sedation	6	10	0.272
Pruritus	3	5	0.682
Difficulty sleeping 2° pain	1	6	0.080
Number of awakenings 2° pain	0.1 ± 0.3	1.5 ± 1.8	0.002
POD 3: After Infusion			
Nausea	2	3	1.000
Sedation	8	6	0.709
Pruritus	3	6	0.268
Difficulty sleeping 2° pain	4	4	1.000
Number of awakenings 2° pain	0.7 ± 1.0	0.8 ± 1.4	0.455

Values represent the number of patients responding “yes” with the exception of “Number of awakenings 2° pain,” which are mean ± SD; \* See Appendix 1 for nightly questionnaire.

2° = secondary to; POD = postoperative day.

paramedian sagittal plane, the needle tip is not directed toward the lung,<sup>21</sup> and unlike the “vertical” technique,<sup>22-25</sup> no pneumothoracies have been reported using this technique. Whiffler reported that even with deliberate attempts to penetrate the thoracic cavity in cadavers, it proved impossible to enter the lung using the coracoid technique.<sup>20</sup> Further, because the needle insertion point is at the level of the cords, contact with the brachial plexus at the terminal nerves may be avoided,<sup>21</sup> theoretically improving surgical block and postoperative analgesic uniformity. However, this assertion requires investigation with a prospective study.

One disadvantage of the coracoid technique is the 90° angle at which the brachial plexus is contacted by the needle, making catheter insertion difficult. Just proximal to the coracoid process, the brachial plexus cords surround the axillary artery. With the catheter insertion system we used, when the relatively stiff catheter tip was advanced past the needle tip, the catheter often penetrated the vessel. Of the first 15 patients enrolled in this study, 5 (33%) had catheters placed intravascularly when the catheter tip was advanced past the needle tip. In subsequent patients, when resistance was encountered when the catheter reached the needle tip, the catheter was held securely in place while the needle was withdrawn over the catheter (see Methods section). This approach left the catheter tip at the original location of the tip of the needle, and, using this technique, there were no instances of intravascular catheter placement in the remaining 20 study patients. The authors have placed an additional 40 infraclavicular catheters using this technique, without a single intravascular catheter placement (Ilfeld BM, Enneking FK, Unpublished data, December, 2001).

#### *Local Anesthetics*

For the initial surgical block, mepivacaine with clonidine was used because this combination offers 4–5 h of surgical anesthesia,<sup>26</sup> with a lower risk of toxicity than bupivacaine or ropivacaine in case of inadvertent intravascular injection. For postoperative analgesia, ropivacaine was used because it produces less motor impairment than bupivacaine during a continuous perineural infusion, while providing equipotent sensory analgesia.<sup>27</sup> We have also found that after infusion discontinuation, the anesthetic and analgesic duration of ropivacaine is less than bupivacaine. This characteristic would be theoretically valuable if a limb became insensate and a compartment syndrome needed to be differentiated from over-delivery of local anesthetic. In addition, its safety in patients without renal or hepatic failure has been demonstrated.<sup>3,6,7,11-13,28,29</sup>

#### *Postoperative Analgesia*

Because postoperative pain waxes and wanes over time and often increases with movement, an infusion

pump that combines a basal infusion rate with a patient-controlled bolus function is desirable to manage breakthrough pain and minimize motor block.<sup>6,11-13</sup> In this investigation, patients receiving ropivacaine by infusion with PCRA reported, on average, minimal to no pain at rest until their catheters were removed the evening of postoperative day 2 (fig. 1A). In contrast, patients receiving placebo infusions were unable to achieve this degree of comfort using an oral narcotic and acetaminophen. The worst resting pain scores (fig. 1B) reflect breakthrough pain and are similar in this regard. We conclude that perineural ropivacaine infusion significantly decreased patients' break-through pain at rest.

The pain scores with movement (figs. 2A and B) provide an important perspective into the potential applications of this analgesic technique. Of the patients receiving ropivacaine, all moved their limb when requested and experienced a moderate increase in discomfort. Patients receiving placebo and controlling their pain with oral narcotics reported that movement of their surgical limb resulted in pain so severe that they were reluctant to move it. Therefore, although the worst pain scores with movement for those receiving ropivacaine are significantly lower than for patients receiving placebo, they possibly fail to reflect the true degree of difference. That is, the pain score may be biased so that a greater difference actually exists than found in this study.

These results suggest that patients receiving a perineural local anesthetic infusion may achieve more vigorous, postoperative physical therapy with improved analgesia than patients receiving only oral narcotics. Improvement in physical therapy analgesia has previously been reported after shoulder<sup>13</sup> and knee<sup>11,30</sup> surgery using PCRA-capable pumps infusing local anesthetic *via* interscalene,<sup>13</sup> psoas compartment,<sup>30</sup> and “extended” femoral<sup>11</sup> perineural catheters. Although this hypothesis needs to be confirmed by a prospective trial involving upper extremity surgery, these pain scores and patients' experiences suggest a potential for improving pain control during physical therapy after hand and forearm procedures.

Consistent with the improved analgesia in the ropivacaine group, there was a significant decrease in narcotic consumption and narcotic-related side effects for patients receiving ropivacaine compared with those receiving placebo (table 3). This observation confirms the findings of other studies of continuous peripheral nerve blocks.<sup>4,5,31</sup>

#### *Study Limitations*

Because this study was designed to evaluate postoperative perineural infusion, the initial surgical block was not evaluated systematically. A prospective trial with blockade results from all nerve distributions is required to properly evaluate the aforementioned technique. A potential fault of this study design is that patients receiv-

ing a saline infusion may have had their initial regional block duration shortened from a "wash out" effect, as has been described for epidural anesthesia.<sup>32</sup> However, the time from block placement until initial oral narcotic use for patients in the placebo group was, in our experience, comparable with patients receiving single-injection infraclavicular blocks for similar procedures.

### *Safety of Ambulatory Infusion*

Although continuous regional blockade was first described more than 50 years ago,<sup>33</sup> portable infusion pumps have made home infusion a more recent possibility.<sup>14,15</sup> This form of analgesia offers significant improvements in pain control after many ambulatory procedures; however, there are several potential inherent risks, including catheter site infection, nerve injury, and catheter migration with local anesthetic toxicity.

In this study, there were no medical complications attributable to the initial regional block, catheter placement, or local anesthetic infusion. However, the relatively small number of patients does not permit us to draw definite conclusions about its relative safety. To maximize safety with this technique, patients are given extensive written and verbal instruction regarding the signs and symptoms of possible catheter- and local anesthetic-related complications. Patients have the ability to contact a physician at all times, and are contacted by telephone at least once a day and specifically asked about these symptoms. Because not all patients desire, or are capable of accepting, the extra responsibility that comes with the catheter and pump system, appropriate patient selection is crucial for safe ambulatory local anesthetic infusion.

The programmable nature of the pump used in this study provides infusion flexibility. We have found that allowing patients to vary their basal rate (with instructions provided by a healthcare provider *via* the telephone) allows analgesia optimization. However, allowing patient access to the pump controls also provides the potential for accidental misprogramming or abuse. The pump used in this study has a maximum basal rate of 9.9 ml/h and bolus dose of 2 ml and a minimum bolus lockout period of 6 min. Therefore, if a patient reprogrammed the pump with these settings and repeatedly triggered the bolus function, a maximum volume of 29.9 ml/h could be infused. It would require intentional abuse of the pump system for this complication to occur. Given the relative potential toxicity of the oral narcotics that patients are routinely prescribed in the ambulatory setting, we considered the reprogramming risk-to-benefit ratio to be acceptable. Alternatively, a lockable cover is available if the healthcare provider does not desire the option of pump reprogramming.

Many questions remain regarding ambulatory perineural local anesthetic infusion, including the optimal catheter insertion technique and system,<sup>34</sup> infusion pump, basal

infusion rate, bolus dose and lockout period, local anesthetic and concentration, and infusion additives. In keeping with evidence-based medical practice, we believe that the optimal techniques, equipment, and patient oversight should be determined by prospective, controlled trials, and not merely by institutional preference.

The authors thank Sorenson Medical, (West Jordan, Utah), which donated the infusion pumps used in this investigation.

## References

1. Rawal N, Hylander J, Nydahl PA, Olofsson I, Gupta A: Survey of postoperative analgesia following ambulatory surgery. *Acta Anaesthesiol Scand* 1997; 41:1017-22
2. Hickey R, Hoffman J, Ramamurthy S: A comparison of ropivacaine 0.5% and bupivacaine 0.5% for brachial plexus block. *ANESTHESIOLOGY* 1991; 74:639-42
3. Singelyn FJ, Deyaert M, Joris D, Pendeville E, Gouverneur JM: Effects of intravenous patient-controlled analgesia with morphine, continuous epidural analgesia, and continuous three-in-one block on postoperative pain and knee rehabilitation after unilateral total knee arthroplasty. *Anesth Analg* 1998; 87:88-92
4. Capdevila X, Barthelet Y, Biboulet P, Ryckwaert Y, Rubenovitch J, d'Athis F: Effects of perioperative analgesic technique on the surgical outcome and duration of rehabilitation after major knee surgery. *ANESTHESIOLOGY* 1999; 91:8-15
5. Borgeat A, Schappi B, Biasca N, Gerber C: Patient-controlled analgesia after major shoulder surgery: Patient-controlled interscalene analgesia versus patient-controlled analgesia. *ANESTHESIOLOGY* 1997; 87:1343-7
6. Klein SM, Grant SA, Greengrass RA, Nielsen KC, Speer KP, White W, Warner DS, Steele SM: Interscalene brachial plexus block with a continuous catheter insertion system and a disposable infusion pump. *Anesth Analg* 2000; 91:1473-8
7. Singelyn FJ, Aye F, Gouverneur JM: Continuous popliteal sciatic nerve block: An original technique to provide postoperative analgesia after foot surgery. *Anesth Analg* 1997; 84:383-6
8. Rawal N, Axelsson K, Hylander J, Allvin R, Amilon A, Lidgran G, Hallen J: Postoperative patient-controlled local anesthetic administration at home. *Anesth Analg* 1998; 86:86-9
9. Klein SM, Greengrass RA, Gleason DH, Nunley JA, Steele SM: Major ambulatory surgery with continuous regional anesthesia and a disposable infusion pump. *ANESTHESIOLOGY* 1999; 91:563-5
10. Ganapathy S, Amendola A, Lichfield R, Fowler PJ, Ling E: Elastomeric pumps for ambulatory patient controlled regional analgesia. *Can J Anaesth* 2000; 47:897-902
11. Singelyn FJ, Gouverneur JM: Extended "three-in-one" block after total knee arthroplasty: continuous versus patient-controlled techniques. *Anesth Analg* 2000; 91:176-80
12. Singelyn FJ, Vanderelst PE, Gouverneur JM: Extended femoral nerve sheath block after total hip arthroplasty: Continuous versus patient-controlled techniques. *Anesth Analg* 2001; 92:455-9
13. Singelyn FJ, Seguy S, Gouverneur JM: Interscalene brachial plexus analgesia after open shoulder surgery: continuous versus patient-controlled infusion. *Anesth Analg* 1999; 89:1216-20
14. Chelly JE, Gebhard R, Coupe K, Greger J, Khan A: Local anesthetic delivered via a femoral catheter by patient-controlled analgesia pump for pain relief after an anterior cruciate ligament outpatient procedure. *Am J Anesthesiol* 2001; 28:192-4
15. Ilfeld BM, Enneking FK: A portable mechanical pump providing over four days of patient-controlled analgesia by perineural infusion at home. *Reg Anesth Pain Med* 2002; 27:100-4
16. Wilson JL, Brown DL, Wong GY, Ehman RL, Cahill DR: Infraclavicular brachial plexus block: parasagittal anatomy important to the coracoid technique. *Anesth Analg* 1998; 87:870-3
17. Kapral S, Jandrasits O, Schabernig C, Likar R, Reddy B, Mayer N, Weinstabl C: Lateral infraclavicular plexus block vs. axillary block for hand and forearm surgery. *Acta Anaesthesiol Scand* 1999; 43:1047-52
18. Vester-Andersen T, Christiansen C, Sorensen M, Eriksen C: Perivascular axillary block. I: blockade following 40 ml 1% mepivacaine with adrenaline. *Acta Anaesthesiol Scand* 1982; 26:519-23
19. Brown DL: Brachial plexus anesthesia: an analysis of options. *Yale J Biol Med* 1993; 66:415-31
20. Whiffler K: Coracoid block—a safe and easy technique. *Br J Anaesth* 1981; 53:845-8
21. Klaastad O, Lilleas FG, Rotnes JS, Breivik H, Fosse E: Magnetic resonance imaging demonstrates lack of precision in needle placement by the infraclavicular brachial plexus block described by Raj et al. *Anesth Analg* 1999; 88:593-8
22. Kilka HG, Geiger P, Mehrkens HH: Infraclavicular vertical brachial plexus blockade. A new method for anesthesia of the upper extremity. An anatomical and clinical study. *Anaesthesist* 1995; 44:339-44



23. Mehrkens HH, Geiger PK: Continuous brachial plexus blockade via the vertical infraclavicular approach. *Anaesthesia* 1998; 53(suppl 2):19-20
24. Neuburger M, Landes H, Kaiser H: Vertical infraclavicular blockade and pneumothorax. *Anaesthesist* 2000; 49:901-4
25. Schupfer GK, Jöhr M: Infraclavicular vertical plexus blockade: A safe alternative to the axillary approach? *Anesth Analg* 1997; 84:233
26. Singelyn FJ, Gouverneur JM, Robert A: A minimum dose of clonidine added to mepivacaine prolongs the duration of anesthesia and analgesia after axillary brachial plexus block. *Anesth Analg* 1996; 83:1046-50
27. Borgeat A, Kalberer F, Jacob H, Ruetsch YA, Gerber C: Patient-controlled interscalene analgesia with ropivacaine 0.2% versus bupivacaine 0.15% after major open shoulder surgery: The effects on hand motor function. *Anesth Analg* 2001; 92:218-23
28. Scott DA, Emanuelsson BM, Mooney PH, Cook RJ, Junstrand C: Pharmacokinetics and efficacy of long-term epidural ropivacaine infusion for postoperative analgesia. *Anesth Analg* 1997; 85:1322-30
29. Salonen MH, Haasio J, Bachmann M, Xu M, Rosenberg PH: Evaluation of efficacy and plasma concentrations of ropivacaine in continuous axillary brachial plexus block: High dose for surgical anesthesia and low dose for postoperative analgesia. *Reg Anesth Pain Med* 2000; 25:47-51
30. Ilfeld BM, Morey TE, Enneking FK: Outpatient use of patient-controlled local anesthetic administration via a psoas compartment catheter to improve pain control and patient satisfaction after ACL reconstruction (abstract). *ANESTHESIOLOGY* 2001; 95:A38
31. Matheny JM, Hanks GA, Rung GW, Blanda JB, Kalenak A: A comparison of patient-controlled analgesia and continuous lumbar plexus block after anterior cruciate ligament reconstruction. *Arthroscopy* 1993; 9:87-90
32. Sitzman BT, Difazio CA, Playfair PA, Stevens RA, Hanes CF, Herman TB, Yates HK, Leisure GS: Reversal of lidocaine with epinephrine epidural anesthesia using epidural saline washout. *Reg Anesth Pain Med* 2001; 26:246-51
33. Ansbrosio FP: A method of continuous brachial plexus block. *Am J Surg* 1946; 71:716-22
34. Borgeat A, Ekatodramis G, Dumont C: An evaluation of the infraclavicular block *via* a modified approach of the Raj technique. *Anesth Analg* 2001; 93:436-41

## Appendix

### *Nightly Questionnaire (\*asked postoperative days 1-3)*

**Pain Scores.** "Please answer the following questions regarding your surgical pain since the last time we spoke using a scale of 0 to 10, 0 being no pain at all and 10 being the worst pain you can imagine."

1. "With your arm and hand resting, what was the *worst* pain you have felt?"
2. "With your arm and hand resting, what was the *average* pain you have felt after you use the pump's bolus button or take pain pills by mouth?"
3. "When moving your arm and hand, what was the *worst* pain you have felt?"
4. "When moving your arm and hand, what was the *average* pain you have felt?"

**Narcotic-related Side Effects\*.** "Have you experienced nausea since the last time we spoke?"

"Have you felt unusually sleepy since the last time we spoke?"

"Have you experienced unusual itching on any part of your body since the last time we spoke?"

### **Sleep Quality\***

"Did you have difficulty sleeping last night because of pain?"

"Did you awaken last night because of pain?" If "yes," then: "How many times did you awaken last night because of pain?"