

UCLA

UCLA Previously Published Works

Title

Discrepancy between angiography and intravascular ultrasound when analysing small coronary arteries

Permalink

<https://escholarship.org/uc/item/63n2r7mw>

Journal

European Heart Journal, 23(3)

ISSN

0195-668X

Authors

Briguori, C
Tobis, J
Nishida, T
[et al.](#)

Publication Date

2002-02-01

DOI

10.1053/euhj.2001.2730

Copyright Information

This work is made available under the terms of a Creative Commons Attribution License, available at <https://creativecommons.org/licenses/by/4.0/>

Peer reviewed

Discrepancy between angiography and intravascular ultrasound when analysing small coronary arteries

C. Briguori¹, J. Tobis², T. Nishida³, M. Vaghetti³, R. Albiero³, C. Di Mario¹ and A. Colombo^{1,3}

¹San Raffaele Hospital, Milan, Italy; ²Division of Cardiology, Department of Medicine, University of California, Los Angeles Medical Center, California, U.S.A.; ³Centro Cuore Columbus, Milan, Italy

Aims A small reference diameter may be the consequence of high plaque burden and diffuse disease. The reference vessel diameter in small coronary arteries may vary according to the method of measurement used. We endeavoured to confirm the difference between data from examinations conducted using angiography with that revealed by intravascular ultrasound.

Methods and Results Between March 1993 and October 1999, 344 consecutive patients with 419 lesions in small vessels (≤ 2.75 mm, Small group) and 953 patients with 1161 lesions in large vessels (Large group) underwent intravascular ultrasound-guided percutaneous transluminal angioplasty in our Institution. The mean difference between the intravascular ultrasound and the angiographic reference diameter ($\Delta_{\text{IVUS-Angio}}$) was 1.3 ± 0.5 mm in the Small group and 1.0 ± 0.6 mm in the Large group ($P < 0.001$). There was a stronger correlation between plaque burden and $\Delta_{\text{IVUS-Angio}}$ in the Small group ($r = 0.80$, $P < 0.001$) than in the Large group ($r = 0.59$, $P < 0.001$). An $\Delta_{\text{IVUS-Angio}} \geq 0.30$ mm occurred in 99.5% of cases in the Small group and in 90% in the Large group ($P < 0.001$). An $\Delta_{\text{IVUS-Angio}} \geq 0.50$ mm occurred in 96% of case in the Small group

and 80% in the Large group ($P < 0.001$). Predictors of $\Delta_{\text{IVUS-Angio}} \geq 0.50$ in the Small group were: proximal or middle lesion site, vessel type (left anterior descending artery, diagonal and obtuse marginal branches) and female sex. An $\Delta_{\text{IVUS-Angio}} \geq 1.0$ mm occurred in 71% of cases in the Small group and in 49% in the Large group ($P < 0.001$). Predictors of $\Delta_{\text{IVUS-Angio}} \geq 1.0$ mm in the Small group were: proximal or middle lesion site, female sex, and lesion length.

Conclusions A high percentage of vessels measuring ≤ 2.75 mm are large vessels with a high plaque burden. This condition is particularly prevalent in females, with lesions in the proximal or middle left anterior descending artery, and in obtuse marginal and diagonal branches. (Eur Heart J 2002; 23: 247–254, doi:10.1053/euhj.2001.2730) © 2001 The European Society of Cardiology

Key Words: Small vessels, quantitative coronary angiography, intravascular ultrasound.

See page 198, doi: 10.1053/euhj.2001.3021 for the Editorial comment on this article

Introduction

The ability to distinguish between large and small coronary arteries based on quantitative coronary angiography is essential for percutaneous transluminal coronary angioplasty (PTCA) and stent implantation. In fact, small artery size is an independent risk factor for the occurrence of restenosis and major adverse cardiac events at follow-up after percutaneous interventions^[1–5]. Why this is the case is not well understood. In some circumstances, a small reference diameter may be a

consequence of a high plaque burden and diffuse disease^[6]. This may have an impact on percutaneous interventional strategies, as devices are chosen on the basis of the estimated angiographic diameter of the reference segments adjacent to a stenosis.

One of the advantages of intravascular ultrasound imaging for clinical work derives from its ability to define both luminal and vessel dimensions^[7–9]. A distinction needs to be made between the angiographic definition of artery size and the vessel size observed on intravascular ultrasound. Whereas angiography uses the proximal reference lumen diameter to denote the artery size, intravascular ultrasound defines the vessel size as the media-to-media diameter. Since arterial remodelling with compensatory vessel enlargement develops to preserve the lumen, the vessel size by intravascular

Revision submitted 3 April 2001, accepted 4 April 2001, and published online 17 August 2001.

Correspondence: Antonio Colombo, MD, FESC, Centro Cuore Columbus, Via M. Buonarroti, 48, I-20145, Milan, Italy.

ultrasound may be significantly greater than the lumen size by angiography^[10].

In the present study we describe the incidence and predictors of the discrepancy between angiography and intravascular ultrasound examinations in determining the reference artery diameter in small coronary arteries.

Methods

Patient population

The patients in the study were treated by coronary intervention at our Institution from March 1993 to October 1999, and met the following inclusion criteria: (a) successful crossing of the lesion with the guidewire and balloon, and (b) the performance of intravascular ultrasound during the procedure. Chronic total occlusions unsuccessfully crossed with the guidewire ($n=302/1005$) and procedures performed without intravascular ultrasound examination ($n=3185/4765$) were excluded from the analysis. As a result, only 1297 patients with 1580 lesions (33%) met the criteria and were included in the study.

Angiographic examination

Angiographic measurements were performed with an automated computer-based system (QCA-CMS version 3.0, MEDIS, Leiden, The Netherlands), according to previously described and validated edge detection algorithms using the catheter for calibration^[11]. Coronary angiograms were analysed by experienced angiographers who had no knowledge of the intravascular ultrasound results. With the outer diameter of the contrast-filled catheter as the calibration standard, the measurements were performed during diastole, in a single 'worst' view. The reference segment diameter was averaged from 5 mm long angiographically normal segments proximal to the lesion but distal to a major side branch. When a normal proximal segment could not be identified (e.g. ostial lesion location or diffuse disease), a distal angiographically normal segment was analysed. Lesions were characterized according to the modified American College of Cardiology–American Heart Association (ACC–AHA) classification^[12].

Intravascular ultrasound examination

Intravascular ultrasound imaging was performed with a 3.9F monorail system with a 25 MHz transducer-tipped catheter (Interpret Catheter, Inter-Therapy/CVIS) or a 2.9F or 3.2F monorail system with a 30-MHz transducer-tipped catheter (Scimed-Boston Scientific Maple Grove, MN, U.S.A.). Validation of quantitative intravascular ultrasound measurements in our laboratory has been reported^[13]. Images were obtained with a manual (initial experience) or motorized pullback system (in most of the cases). Data were stored on 0.5 inch

Super VHS videotape. The reference segment was selected as the most normal-looking cross section 10 mm proximal to the target lesion but distal to a major side branch. In circumstances in which a proximal reference segment could not be identified (e.g. ostial lesion location or diffuse proximal disease extending back to a major side branch), a distal reference (also within 10 mm of the target lesion, but proximal to a major side branch) was analysed. Reference site measurements were made at sites that did not appear severely diseased on intravascular ultrasound. The external elastic membrane cross-sectional area was defined as the area encompassed by the ultrasonic media/adventitia border, by tracing the leading edge of the adventitia. Lumen measurements were made at the inner border of the echo-dense plaque. Because media thickness cannot be measured accurately^[14], plaque-media cross-sectional area (external elastic membrane cross-sectional area minus lumen cross-sectional area) was used as a measure of atherosclerotic plaque. The following parameters were measured at the reference site: (a) lumen diameter (mm), (b) vessel diameter (mm), (c) percent area stenosis ($100 \times [\text{lesion external elastic membrane area} - \text{lesion lumen area}] / \text{lesion external elastic membrane area}$), (d) plaque-media cross-sectional area (mm^2), (e) cross-sectional narrowing (%) as $100 \times (\text{plaque-media cross-sectional area} / \text{external elastic membrane cross-sectional area})$, (f) plaque-media cross-sectional area indexed to the lumen diameter by intravascular ultrasound.

Definition of artery size

By angiography, artery size was considered from the lumen diameter in the proximal reference segment. By intravascular ultrasound, artery size was considered from the vessel (media-to-media) diameter measured in the reference segment^[15]. This measurement is not available by angiography.

Small arteries were considered to be arteries with a reference diameter ≤ 2.75 mm, assessed by quantitative coronary angiography (Small group). Large arteries were considered to be arteries with a reference diameter > 2.75 mm, assessed by quantitative coronary angiography (Large group).

Statistical analysis

The arteries were evaluated as the unit for analysis. Continuous variables are given as mean \pm 1 standard deviation. Differences between groups were assessed by chi-square analysis for categorical variables and Student's t-test and one-way ANOVA for continuous variables. Correlation between angiographic and intravascular ultrasound variables was assessed by Pearson's correlation coefficient. The contribution of clinical and angiographic variables to the difference between intravascular ultrasound and angiographic

Table 1 Clinical characteristics of the 1297 patients, according to angiographic reference vessel size

	≤2.75 mm (n=344)	>2.75 mm (n=953)	P
Age (years)	57 ± 10	58 ± 10	0.34
Male	298 (86.6%)	880 (92.3%)	<0.001
Previous myocardial infarction	191 (55.7%)	489 (51.3%)	0.12
LV ejection fraction (%)	60 ± 10	59 ± 11	0.10
Unstable angina	122 (35.4)	339 (35.6)	0.97
Multivessel disease	280 (81%)	632 (66%)	0.03
Diabetes mellitus	30 (8.9%)	94 (7.7%)	0.45
Hypertension	157 (45.5%)	398 (41.8%)	0.20
Smoking	196 (57%)	597 (62.6%)	0.06
Hypercholesterolaemia	206 (60%)	552 (58%)	0.53

reference diameter was evaluated with a stepwise multivariate logistic regression analysis (forward conditional method). Only variables with a $P < 0.10$, as identified by univariate analysis, were put into the model. Probability values < 0.05 were considered significant. Data were analysed with SPSS for Windows 10.0.5.

Results

A reference diameter ≤ 2.75 mm occurred in 419 of the 1580 (26.5%) vessels (344/1297 patients), whereas a reference diameter > 2.75 mm occurred in the remaining 1161 (73.5%) vessels (953/1297 patients).

Clinical and angiographic characteristics (Tables 1 and 2)

Patients with lesions in small vessels were more often female, smokers, and with multivessel disease.

Intravascular ultrasound characteristics (Table 3)

In the Small group, the reference artery size was 2.46 ± 0.24 (range 1.40–2.75) mm by quantitative coronary angiography. By intravascular ultrasound, the reference lumen diameter was 2.80 ± 0.40 (range 1.50–4.40) mm, and the reference vessel diameter 3.80 ± 0.58 (range 2.20–5.50) mm. Of note, the patient with the lowest lumen diameter (1.50 mm by intravascular ultrasound) had a very large vessel diameter (4.0 mm). In the Large group, the reference artery diameter was 3.29 ± 0.40 mm (range 2.76–5.10) by quantitative coronary angiography. By intravascular ultrasound, the reference lumen diameter was 3.20 ± 0.60 (range 1.70–5.90) mm, and the reference vessel diameter 4.29 ± 0.64 (range 2.60–6.90) mm. The correlation coefficient r between the lumen diameter as assessed by quantitative coronary angiography and intravascular ultrasound was

Table 2 Angiographic characteristics of the 1580 lesions in the Small and Large groups

	≤2.75 mm (n=419)	>2.75 mm (n=1161)	P
Vessel dilated			
LAD	247 (58.9%)	598 (50.9%)	<0.001
LCx	70 (16.7%)	163 (14%)	0.19
RCA	60 (14.3%)	342 (29.5%)	<0.001
LMCA	1 (0.2%)	18 (1.5%)	0.02
Intermediate	5 (1.2%)	5 (0.4%)	0.10
Diagonal	16 (3.8%)	6 (0.5%)	<0.001
Obtuse marginal	20 (4.8%)	35 (3.0%)	0.066
Lesion site			
Ostial	45 (3.9%)	26 (6.2%)	0.036
Proximal	396 (34.1%)	194 (46.3%)	<0.001
Mid-vessel	532 (45.8%)	170 (40.6%)	0.06
Distal	188 (16.2%)	29 (6.9%)	<0.001
MLD (mm)	0.79 ± 0.41	0.88 ± 0.58	0.005
Diameter stenosis (%)	68 ± 16	73 ± 17	<0.001
Lesion length, mm	25 ± 15	26 ± 15	0.33
Thrombus	7 (1.5%)	37 (3.2%)	0.06
Lesion types*			
A	17 (4%)	43 (3.7%)	0.42
B1	145 (34.6%)	358 (30.8%)	0.15
B2	182 (43.4%)	486 (41.9%)	0.57
C	75 (18%)	274 (23.6%)	0.02

*Modified American Heart Association/American College of Cardiology criteria; LAD=left anterior descending artery; LCx=left circumflex artery; RCA=right coronary artery; LMCA=left main coronary artery; MLD=minimal lumen diameter.

Table 3 Intravascular ultrasound characteristics of the 1580 reference segments in the Small and Large groups

	≤2.75 mm (n=419)	>2.75 mm (n=1161)	P
Vessel CSA, mm ²			
Proximal	12.6 ± 3.6	16.1 ± 4.7	<0.001
Distal	10.2 ± 4.6	11.2 ± 4.5	0.07
Lumen CSA, mm ²			
Proximal	7.3 ± 2.1	9.7 ± 3.2	<0.001
Distal	5.8 ± 1.6	7.7 ± 2.9	<0.001
Lumen diameter, mm			
Proximal	2.8 ± 0.4	3.2 ± 0.6	<0.001
Distal	2.6 ± 0.4	3.1 ± 0.4	<0.001
P&M CSA, mm ²	5.2 ± 2.6	6.5 ± 3.0	<0.001
P&M CSA/lumen diameter	1.9 ± 0.9	2.0 ± 0.9	0.051
CSN (%)	41 ± 14	38 ± 12	0.06

CSA=cross sectional area; P&M=plaque plus media; CSN=cross-sectional narrowing.

0.38 ($P < 0.001$) in the Large group, and 0.28 ($P < 0.001$) in the Small group. The correlation coefficient r between artery size assessed by quantitative coronary angiography and intravascular ultrasound was 0.68 ($P < 0.001$) in the Large group, and 0.40 ($P < 0.001$) in the Small group (Fig. 1), respectively.

The mean difference between intravascular ultrasound and angiographic artery size was 1.3 ± 0.5 mm in the Small group and 1.0 ± 0.6 mm in the Large group

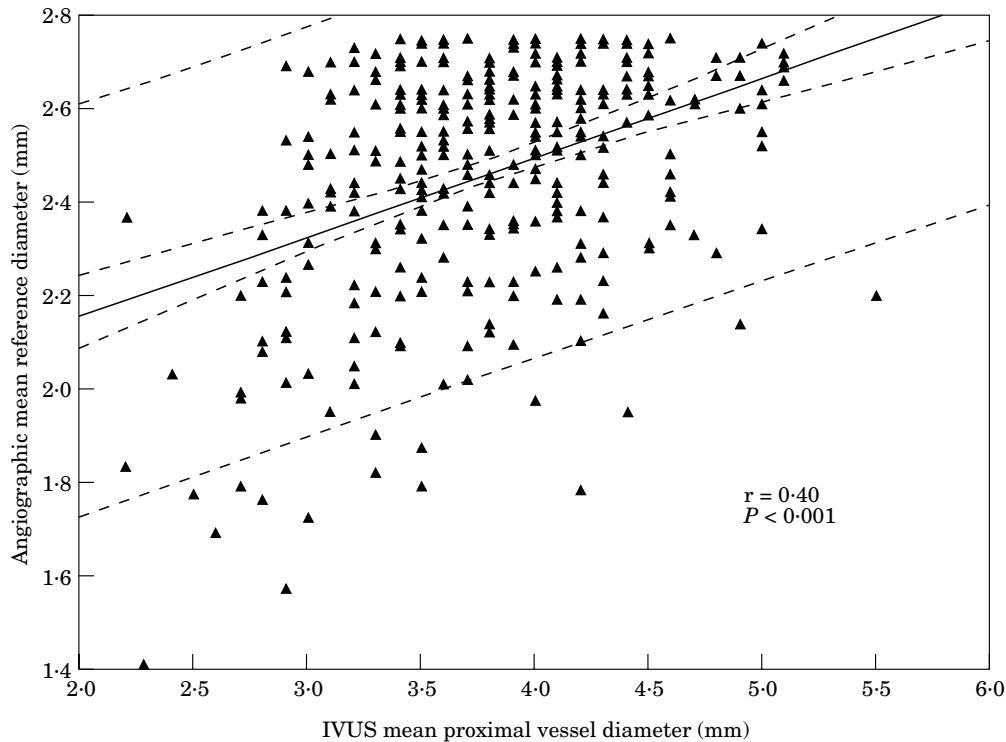


Figure 1 Angiographic reference vessel diameter plotted as a function of the intravascular ultrasound (IVUS) reference vessel diameter, in the Small group. Pair of broken lines = the 95% confidence limits for the solid line. The outer pair of dashed lines = the 95% confidence limits for a single observation. r = correlation coefficient.

($P < 0.001$). The distribution in the difference between intravascular ultrasound and angiographic artery size in the Small group is represented in Fig. 2. The correlation coefficient between the plaque burden in the reference segment and the difference between intravascular ultrasound and quantitative coronary angiography artery size was stronger in the Small group ($r = 0.80$, $P < 0.001$; Fig. 3) than in the Large group ($r = 0.59$, $P < 0.001$). In the Small group, the difference between intravascular ultrasound and angiographic artery size was higher in lesions located in the proximal and/or middle segment of the vessel (Fig. 4).

There were 115 patients with 229 'combined' lesions (that is, at least one lesion in the Small group and another in the Large group). These patients did not differ from the total population in any clinical characteristics. However, plaque burden still differed in these patients ($4.78 \pm 2.65 \text{ mm}^2$ in the Small group vs $6.50 \pm 2.80 \text{ mm}^2$ in the Large group; $P < 0.001$).

The difference between intravascular ultrasound and angiographic artery size
 $(\Delta_{IVUS-Angio}) \geq 0.30 \text{ mm}$

The percentage of cases with $\Delta_{IVUS-Angio} \geq 0.30 \text{ mm}$ was 99.5% in the Small group and 90% in the Large group ($P < 0.001$). By logistic regression analysis, predictors of

$\Delta_{IVUS-Angio} \geq 0.30 \text{ mm}$ in the Small group were: female sex (OR = 2.97; 95% CI = 1.44–6.11; $P = 0.005$), proximal or middle lesion site (OR = 5.20; 95% CI = 2.10–12.50; $P = 0.003$) and vessel type (left anterior descending artery: OR = 4.65; 95% CI = 1.07–20.23; $P < 0.036$, and obtuse marginal branch: OR = 9.15; 95% CI = 1.66–50.35; $P = 0.01$).

$\Delta_{IVUS-Angio} \geq 0.50 \text{ mm}$

The percentage of cases with $\Delta_{IVUS-Angio} \geq 0.50 \text{ mm}$ was 96% in the Small group and 80% in the Large group ($P < 0.001$). By logistic regression analysis predictors of $\Delta_{IVUS-Angio} \geq 0.50$ in the Small group were: proximal or middle lesion site (OR = 5.20; 95% CI = 2.10–12.5; $P < 0.003$), and vessel type (left anterior descending artery, diagonal branch and obtuse marginal branch) (OR = 2.86; 95% CI = 1.54–5.32; $P < 0.001$) and female sex (OR = 1.91; 95% CI = 1.01–3.60; $P < 0.01$).

$\Delta_{IVUS-Angio} \geq 1.0 \text{ mm}$

The percentage of cases $\Delta_{IVUS-Angio} \geq 1.0 \text{ mm}$ was 71% in the Small group and <49% in the Large group ($P < 0.001$). By logistic regression analysis predictors of $\Delta_{IVUS-Angio} \geq 1.0 \text{ mm}$ were: proximal or middle lesion

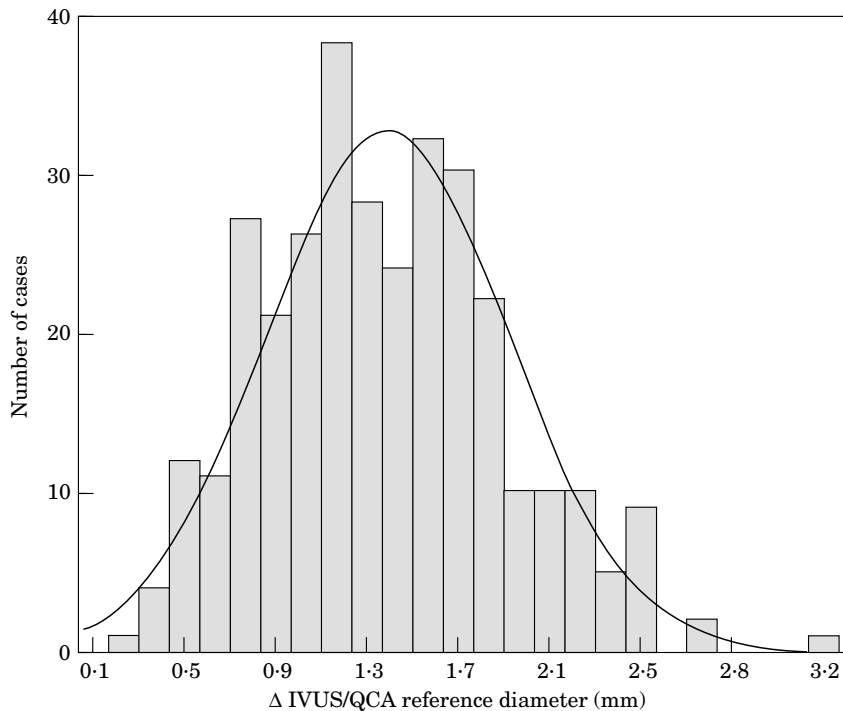


Figure 2 Distribution in the difference between intravascular ultrasound and angiographic reference diameter in the Small group. The mean difference was 1.33 ± 0.52 mm (median=1.30).

site (OR=1.95; 95% CI=1.32–2.89; $P<0.001$), female sex (OR=2.25; 95% CI=1.34–3.79; $P<0.001$), and lesion length (OR=1.05; 95% CI=1.01–1.10; $P=0.021$).

Discussion

Operators who do not use intravascular ultrasound imaging measure the lumen and assume that this measurement at the reference segment correctly represents the true size of the artery. However, with the introduction of intravascular ultrasound imaging a new definition of arterial size was proposed. A primary observation of intravascular ultrasound studies was the diffuse distribution of plaque throughout the artery^[15]. Even within the angiographically normal segment, the plaque burden cross-sectional area averaged 40% of the total vessel area^[10]. The definition of artery size by intravascular ultrasound is the area circumscribed by the media and includes the lumen plus plaque burden^[15]. Due to the recognition of compensatory enlargement^[10,15], it is difficult to know what the original size of the artery should be. However, the observation by intravascular ultrasound that the vessel size is frequently larger than what would be estimated by angiography led to a more aggressive use of larger balloons and stents with improvement in clinical results^[16–20]. The purpose of this study was to (1) document the differences in measurements between angiography and intravascular ultrasound, and (2) describe the clinical and angiographic predictors of this difference.

Small artery size, as assessed by angiography, is an independent risk factor for the occurrence of restenosis and major adverse cardiac events at follow-up after percutaneous coronary interventions^[1–5]. The mechanisms of such an unfavourable outcome for small vessels are not well understood. Factors proposed are (a) high degree of vessel stretch, (b) small post-procedural lumen, and (c) high metal density (in cases of stent implantation)^[21]. It is also possible that a higher plaque burden and more diffuse disease are important factors. In fact, an angiographic small reference lumen diameter may be a consequence of high plaque burden and diffuse disease^[6]. Recent studies support the detrimental influence of plaque burden on restenosis rate after balloon-angioplasty^[22] and stent implantation^[23,24]. It is possible that a subgroup of angiographic small arteries is actually 'large' arteries with a large and diffuse plaque burden. Identification of these 'false' small arteries may have an important impact on percutaneous interventional strategies, and, eventually, on long-term outcome.

Relationship between angiographic and intravascular ultrasound examinations

One of the advantages of intravascular ultrasound imaging for coronary interventions derive from its ability to define both lumen and vessel dimensions^[15]. In the present study we found a better correlation between angiographic and intravascular ultrasound reference artery size (that is, lumen by angiography and vessel by

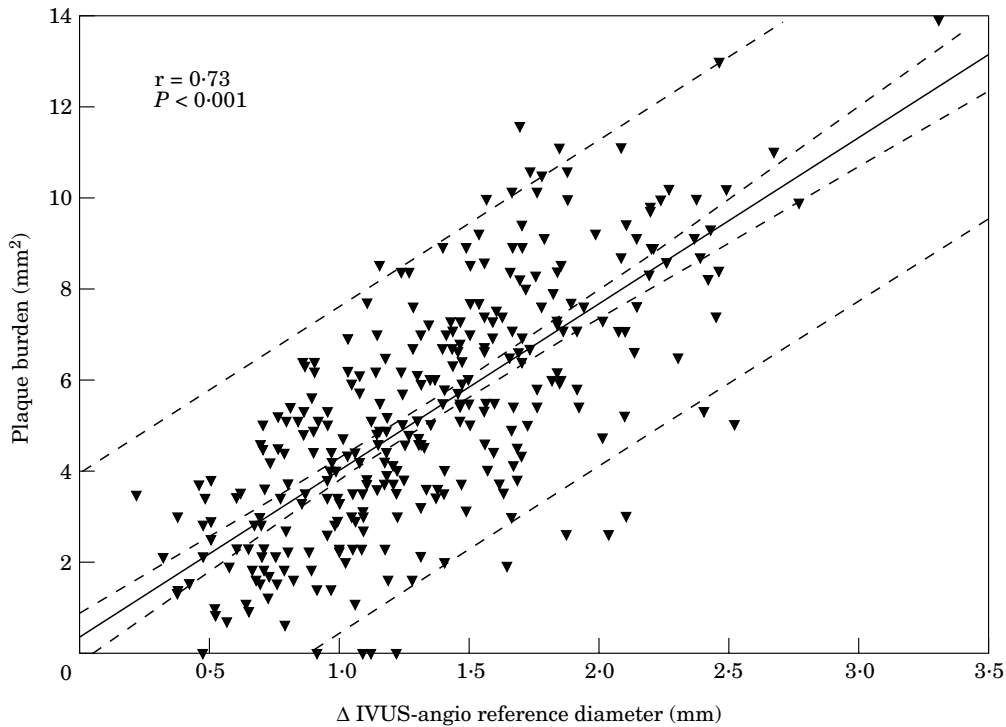


Figure 3 Difference between intravascular ultrasound (IVUS) and quantitative coronary angiography reference vessel diameter ($\Delta_{IVUS-Angio}$) plotted as a function of plaque burden assessed by intravascular ultrasound, in the Small group. Pair of broken lines around the solid line=the 95% confidence limits for the solid line. The outer pair of dashed lines=the 95% confidence limits for a single observation. r =correlation coefficient.

intravascular ultrasound) in the Large than in the Small artery group. Of note, the correlation coefficient between $\Delta_{IVUS-Angio}$ and plaque burden was stronger in the Small

than in the Large group. Furthermore, cross-sectional narrowing in the reference segment was greater in the Small group. This may explain the significantly higher discordance between quantitative coronary angiography and intravascular ultrasound in the assessment of the reference diameter in large and small arteries. In the Small group, a $\Delta_{IVUS-Angio} \geq 0.30$ mm was found in almost all cases, whereas a $\Delta_{IVUS-Angio} \geq 1.0$ mm was present in about 70% of cases.

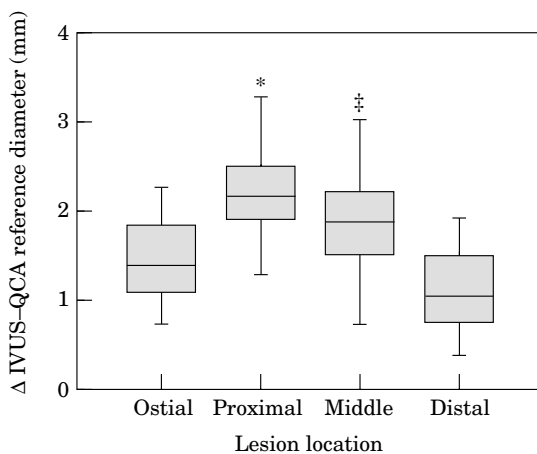


Figure 4 Difference between intravascular ultrasound (IVUS) and quantitative coronary angiography (QCA) reference vessel diameter ($\Delta_{IVUS-QCA}$) according to lesion location, in the Small group. $\Delta_{IVUS-QCA}$ was significantly higher in lesions located in the proximal and middle segment. * $P < 0.05$ vs ostial and distal lesion location; ‡ $P < 0.05$ vs ostial and distal lesion location.

Clinical and angiographic predictors of $\Delta_{IVUS-Angio}$

The use of intravascular ultrasound guidance facilitates decision making in terms of balloon and/or stent sizing in angiographically small vessels that may in fact be large vessels with diffuse atherosclerosis. In order to help operators when angiography alone is used for balloon and/or stent sizing, we identified some clinical and angiographic factors useful in the selection of arteries that appear angiographically small but are actually large. Female sex, vessel type (left anterior descending artery, diagonal and obtuse branches) and location (proximal-middle), and lesion length are important factors to be considered to identify 'false' small coronary arteries.

Clinical implications

Since the initial description by A. Gruentzig in 1978, PTCA has been performed by selecting a balloon with a nominal diameter approximating that of the normal appearing reference segment adjacent to the lesion^[25,26]. However, it was hypothesized that intravascular ultrasound guidance could be used safely to accommodate over-sized balloons in selected patients undergoing PTCA. Because the degree of plaque burden and the true vessel size can be determined only with intravascular ultrasound, the use of ultrasound is thought to be essential for the accurate selection of properly sized balloons if an aggressive balloon strategy is to be safely carried out^[16–20]. Stone *et al.*^[19] showed that despite the presence of atheromatous remodelling, intravascular ultrasound permits the safe use of balloons, traditionally considered over-sized, resulting in significantly improved luminal dimensions, without increased rates of dissections or ischaemic complications.

According to the results of the present study, we can extrapolate that a balloon 0.30 mm larger than the angiographic reference diameter (that is, a 1.1 balloon-to-artery ratio) may be used in all arteries ≤ 2.75 mm in angiographic lumen diameter at the reference site. Furthermore, a balloon 0.50 mm larger than the angiographic reference diameter (that is, a 1.2 balloon-to-artery ratio) may be used in 96% of cases, whereas a balloon 1.0 mm larger than the angiographic reference diameter (that is, a 1.4 balloon-to-artery ratio) may be used in about 70% of cases. This observation may have important implications on percutaneous strategy and possibly on restenosis rate, because it highlights the importance of appropriate balloon and/or stent size when dealing with small arteries. Balloon-to-artery ratio values in the treatment of small vessels range from 0.9 to 1.5^[2,3,27,28]. It has been hypothesized that a greater balloon-to-artery ratio may lead to greater vessel wall injury and more reactive neointimal hyperplasia^[21–29]. Therefore, a less aggressive strategy might be preferred. However, a lower balloon-to-artery ratio has been identified as an additional independent risk factor for restenosis after stent implantation. Elezi *et al.*^[1], in analysing the relationship between vessel size and the probability of restenosis for two arbitrarily assumed cut-off points of balloon-to-artery ratio (0.90 and 1.10), demonstrated that a lower risk for restenosis is expected for a balloon-to-artery ratio of 1.10 over the entire range of vessel sizes. Other studies have shown that major determinants of restenosis are the percent diameter stenosis and the minimal lumen diameter or the minimal cross-sectional area achieved after intervention^[2,30]. Indiscriminate use of balloons larger than the angiographic reference segment lumen may result in unacceptably high rates of ischaemic complications after PTCA^[25,26]. However, in our experience in the treatment of small coronary arteries, a high balloon-to-artery ratio, selected by intravascular ultrasound guidance, did not increase the incidence of acute complications (e.g. coronary ruptures, dissections)^[2,27].

Study limitations

A major limitation for a precise comparison between intravascular ultrasound and quantitative coronary angiography is that the measurement of the same arterial cross-section is difficult. Furthermore, the actual impact of such an observation of early and late outcome is not assessed in the present study. The influence of the balloon-to-artery ratio on the risk of early adverse events must be specifically assessed before the strategy of using over-sized balloons is recommended as a remedy for the excessive restenosis found in the group with small vessels. A prospective, randomized study is necessary to clarify the actual impact of this observation on early and late outcome after percutaneous coronary intervention in arteries ≤ 2.75 mm.

References

- [1] Elezi S, Kastrati A, Neumann FJ, Hadamitzky M, Dirschinger J, Shömig A. Vessel size and long-term outcome after coronary stent placement. *Circulation* 1998; 98: 1875–80.
- [2] Akiyama T, Moussa I, Reimers B *et al.* Angiographic and clinical outcome following coronary stenting of small vessels. A comparison with coronary stenting of large vessels. *J Am Coll Cardiol* 1998; 32: 1610–18.
- [3] Kasaoka S, Tobis JM, Akiyama T *et al.* Angiographic and intravascular ultrasound predictors of in-stent restenosis. *J Am Coll Cardiol* 1998; 32: 1630–5.
- [4] Savage MP, Fishman DL, Rake R *et al.* Efficacy of coronary stenting versus balloon angioplasty in small coronary arteries. *J Am Coll Cardiol* 1998; 31: 307–11.
- [5] Foley DP, Melkert R, Serruys PW. Influence of coronary vessel size on renarrowing process and late angiographic outcome after successful balloon angioplasty. *Circulation* 1994; 90: 1239–51.
- [6] Mintz GS, Popma JJ, Pichard AD *et al.* Intravascular ultrasound predictors of restenosis after percutaneous transcatheter coronary revascularization. *J Am Coll Cardiol* 1996; 27: 1678–87.
- [7] Gussenhoven EJ, Essed CE, Lancee CT *et al.* Arterial wall characteristics determined by intravascular ultrasound imaging: an in vitro study. *J Am Coll Cardiol* 1989; 14: 947–52.
- [8] Nissen SE, Gurley JC, Grines CL *et al.* Intravascular ultrasound assessment of lumen size and wall morphology in normal subjects and patients with coronary artery disease. *Circulation* 1991; 84: 1087–99.
- [9] Tobis JM, Mallery J, Mahon D *et al.* Intravascular ultrasound imaging of human coronary arteries in vivo. *Circulation* 1991; 83: 913–92.
- [10] Glagov S, Weisenberg E, Zarins CK, Stankunavicius R, Kolettis GJ. Compensatory enlargement of human atherosclerotic coronary arteries. *N Engl J Med* 1987; 316: 1371–5.
- [11] Reiber JHC, Serruys PW. *Progress in Quantitative Coronary Arteriography*. Dordrecht, The Netherlands: Kluwer, 1994.
- [12] Ryan TJ, Faxon DP, Gunnar RM *et al.* Guidelines for percutaneous transluminal coronary angioplasty: a report of the American College of Cardiology/American Heart Association Task Force on assessment of diagnostic and therapeutic cardiovascular procedures. *Circulation* 1988; 78: 486–502.
- [13] Colombo A, Hall P, Nakamura S *et al.* Intracoronary stenting without anticoagulation accomplished with intravascular ultrasound guidance. *Circulation* 1995; 91: 1676–88.
- [14] Mallery JA, Tobis JM, Griffith J *et al.* Assessment of normal and atherosclerotic arterial wall thickness with an intravascular ultrasound imaging catheter. *Am Heart J* 1990; 119: 1392–400.

- [15] Mintz GS, Painter JA, Pichard AD *et al.* Atherosclerosis in angiographically 'normal' coronary artery reference segments: a serial intravascular ultrasound study with clinical correlations. *J Am Coll Cardiol* 1995; 25: 1479–85.
- [16] Fitzgerald PJ, Oshima A, Hayase M *et al.* Final results of the can routine ultrasound influence stent expansion (CRUISE) study. *Circulation* 2000; 102: 523–30.
- [17] Frey AW, Hodgson JM, Müller C, Bestehorn HP, Roskemm H. Ultrasound-guided strategy for provisional stenting with focal balloon combination catheter. Results from the randomized strategy for intracoronary ultrasound-guided PTCA and stenting (SIPS) trial. *Circulation* 2000; 102: 2497–502.
- [18] Schiele F, Meneveau N, Vuilleminot A *et al.* Impact of intravascular ultrasound in stent deployment on 6-month restenosis rate: a multicenter, randomized study comparing two strategies — with and without intravascular ultrasound guidance: RESIST Study Group: REStenosis after Ivus guided Stenting. *J Am Coll Cardiol* 1998; 32: 320–8.
- [19] Stone GW, Hodgson JM, St Goar FG *et al.* Improved procedural results of coronary angioplasty with intravascular ultrasound-guided balloon sizing: the CLOUT Pilot Trial. Clinical Outcomes with Ultrasound Trial (CLOUT) Investigations. *Circulation* 1997; 95: 2044–52.
- [20] de Jaegere P, Mudra H, Figulla H *et al.* Intravascular ultrasound-guided optimized stent deployment: Immediate and 6 months clinical and angiographic results from the Multicenter Ultrasound Stenting in Coronaries Study (MUSIC Study). *Eur Heart J* 1998; 19: 1214–23.
- [21] Rogers C, Tseng DY, Squire JC, Edelman ER. Balloon-artery interactions during stent placement. A finite element analysis approach to pressure, compliance, and stent design as contributors to vascular injury. *Circ Res* 1999; 84: 378–83.
- [22] Dangas G, Mintz GS, Mehran R *et al.* Preintervention arterial remodeling as an independent predictor of target-lesion revascularization after nonstent coronary intervention. *Circulation* 1999; 99: 3149–54.
- [23] Moussa I, Moses J, Di Mario C *et al.* Stenting after optimal lesion debulking (SOLD) registry. Angiographic and clinical outcome. *Circulation* 1998; 98: 1604–9.
- [24] Prati F, Di Mario C, Moussa I *et al.* In-stent neointimal proliferation correlates with the amount of residual plaque burden outside the stent. An intravascular ultrasound study. *Circulation* 1999; 99: 1011–14.
- [25] Roubin GS, Douglas JSJ, King SB *et al.* Influence of balloon size on initial success, acute complications, and restenosis after percutaneous transluminal coronary angioplasty. A prospective randomized study. *Circulation* 1988; 78: 557–65.
- [26] Nichols AB, Smith R, Berke AD, Shlofmitz RA, Powers ER. Importance of balloon size in coronary angioplasty. *J Am Coll Cardiol* 1989; 13: 1094–100.
- [27] Briguori C, Nishida T, Adamian M, Albiero R, Di Mario C, Colombo A. Coronary stenting versus balloon angioplasty in small coronary arteries with complex lesions. *Cathet Cardiovasc Interv* 2000; 50:390–7.
- [28] Kastrati A, Shömig A, Dischinger J *et al.* A randomized trial comparing stenting with balloon angioplasty in small vessels in patients with symptomatic coronary artery disease. *Circulation* 2000; 102: 2593–8.
- [29] Serruys PW, Foley DP, Kirkeeide RL, King SB III. Restenosis revisited: insights provided by quantitative coronary angiography. *Am Heart J* 1993; 126: 1243–67.
- [30] Hoffmann R, Mintz GS, Mehran R *et al.* intravascular ultrasound predictors of angiographic restenosis in lesions treated with Palmatz-Schatz stents. *J Am Coll Cardiol* 1998; 31: 43–9.