

**UCLA**

**Proceedings of UCLA Health**

**Title**

Obscure GI Bleeding in a Young Male

**Permalink**

<https://escholarship.org/uc/item/63f0t9h4>

**Journal**

Proceedings of UCLA Health, 24(1)

**Authors**

Farid, Mary

Connolly, Lynn

**Publication Date**

2020-04-14

## CLINICAL VIGNETTE

---

# Obscure GI Bleeding in a Young Male

---

Mary Farid, DO and Lynn Connolly, MD

### Case Summary

A 23-year-old male presented after syncope following two days of bloody diarrhea. He initially noted 2-3 hours of epigastric pain an hour after eating a chicken sandwich. His pain subsided, but recurred the following day after eating a burrito. He also noted hematochezia, described as mostly blood and very little stool. He reported two more episodes of hematochezia that day. At 1am, he felt dizzy and passed out, hitting the floor, prompting emergency department evaluation.

The patient had no prior history of abdominal pain or hematochezia. He denied use of nonsteroidal anti-inflammatory drugs, recent travel, antibiotic use or a personal or family history of inflammatory bowel disease. The remainder of his medical history was unremarkable.

In the ED, initial vital signs included, BP 118/70 with P 98. His physical exam was normal. Initial hemoglobin was 9.8 g/dl with MCV of 91. He had another episode of bloody stool in the ED and was admitted and scheduled for EGD and Colonoscopy. The EGD showed mild gastric erosions but was otherwise normal. The colonoscopy was normal including examination of the terminal ileum. No blood was seen in the stomach or the colon.

He continued to have additional bloody bowel movements and his Hgb dropped from 9.2 to 8.0 to 7.5, despite transfusion of 2 units of packed red cells. A Meckel's scan was obtained and showed persistent focal tracer activity in the mid-abdomen, concerning for a Meckel's diverticulum (Figure 1). He was seen by surgery and underwent a laparoscopic-assisted resection of a bleeding Meckel's diverticulum. A long, chronically inflamed Meckel's diverticulum was found 2 feet from the ileocecal valve, with associated ulceration of the adjacent small bowel. Frozen section confirmed Meckel's diverticulum with oxyntic-type gastric heterotopia and adjacent small bowel mucosal ulceration. The patient did well post-operatively with no further episodes of hematochezia and stable Hg.

### Discussion

Meckel's diverticulum is the most common congenital anomaly of the gastrointestinal (GI) tract.<sup>1</sup> It is a true diverticulum, containing all the layers of the small bowel and is a remnant of the omphalomesenteric duct, the stalk connecting the fetal midgut to the yolk sac. This normally regresses during the 5<sup>th</sup> or 6<sup>th</sup>

week of life, but failure to regress can result in various anomalies.<sup>2</sup>

The most common of these anomalies is a diverticulum which has a rich blood supply provided by the vitelline artery, a branch of the superior mesenteric artery. The estimated prevalence of Meckel's diverticulum is 2% of the population. The general "rule of 2's" regarding Meckel's is that it affects 2% of the population, the male to female ratio is 2:1, it is typically located within 2 feet of the ileocecal valve, and can be 2 inches in length.<sup>1</sup> Approximately 2-4% of those affected develop a complication, including GI bleeding due to presence of ectopic gastric mucosa, bowel obstruction, diverticular inflammation or perforation. Risk factors for a complication include age <50, male sex, diverticulum >2cm in length, the presence of histologically abnormal tissue, a broad based diverticulum and the presence of fibrous bands which can lead to bowel obstruction.<sup>3</sup>

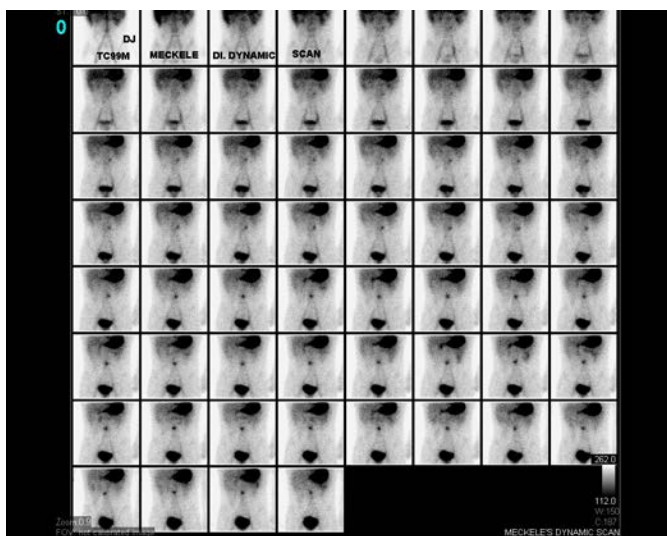
Individuals with Meckel's diverticulum are usually asymptomatic. Approximately 20-25% of those with symptoms are under the age of 10. Meckel's diverticulum should be suspected in children with painless lower GI bleeding, intussusception, or symptoms of acute appendicitis after the appendix has been removed. There should be a high suspicion for a Meckel's diverticulum as the etiology of occult GI bleeding in adult patients under the age of 40.

GI bleeding associated with a Meckel's diverticulum is thought to be caused by ulceration of the small bowel due to acid secretion by ectopic gastric mucosa within the diverticulum. It is unclear why some diverticula have ectopic gastric tissue. The site of mucosal ulceration and bleeding is adjacent to or just downstream from the diverticulum, not from the mucosa or ectopic tissue within the diverticulum. About 12-21% of Meckel's diverticula have ectopic tissue within the diverticulum (most commonly gastric). GI bleeding may be chronic and insidious or acute and massive. It can present with dark red or maroon stools, or melena, especially in adults with slower colonic transit time.<sup>4</sup>

The diagnosis can be made several ways. Conventional arteriography can detect an anomalous superior mesenteric artery branch feeding the diverticulum. Computed tomography angiogram can detect active signs of bleeding. A Meckel's scan is used for hemodynamically stable patients with high clinical suspicion. 99m technetium pertechnetate, which has an affinity

for gastric mucosa, is administered intravenously, then scintigraphy is performed to identify areas of ectopic gastric mucosa. This scan will identify only those diverticula which contain gastric mucosa. The sensitivity is 85-90% in the pediatric population but decreases to about 60% in adults.<sup>2</sup>

Resection is done by either a simple diverticulectomy or segmental small bowel resection. If there is GI bleeding, segmental small bowel resection is recommended. Resection is generally not recommended if a Meckel's diverticulum is incidentally found on routine imaging.



**Figure 1.** Meckel's scan showing persistent focal tracer activity in the mid-abdomen, concerning for a Meckel's diverticulum.

## REFERENCES

1. **Sagar J, Kumar V, Shah DK.** Meckel's diverticulum: a systematic review. *J R Soc Med.* 2006 Oct;99(10):501-5. Review. Erratum in: *J R Soc Med.* 2007 Feb;100(2):69. PubMed PMID: 17021300; PubMed Central PMCID: PMC1592061.
2. **Rashid OM, Ku JK, Nagahashi M, Yamada A, Takabe K.** Inverted Meckel's diverticulum as a cause of occult lower gastrointestinal hemorrhage. *World J Gastroenterol.* 2012 Nov 14;18(42):6155-9. doi: 10.3748/wjg.v18.i42.6155. Review. PubMed PMID: 23155346; PubMed Central PMCID: PMC3496894.
3. **Park JJ, Wolff BG, Tollefson MK, Walsh EE, Larson DR.** Meckel diverticulum: the Mayo Clinic experience with 1476 patients (1950-2002). *Ann Surg.* 2005 Mar;241(3):529-33. PubMed PMID: 15729078; PubMed Central PMCID: PMC1356994.
4. **Dumper J, Mackenzie S, Mitchell P, Sutherland F, Quan ML, Mew D.** Complications of Meckel's diverticula in adults. *Can J Surg.* 2006 Oct;49(5):353-7. PubMed PMID: 17152574; PubMed Central PMCID: PMC3207587.