

UC Davis

Dermatology Online Journal

Title

A case of bullous Sézary syndrome

Permalink

<https://escholarship.org/uc/item/6244g9rx>

Journal

Dermatology Online Journal, 26(4)

Authors

Wu, Sam
Jenkins, Francie
Byrd, Rachel
et al.

Publication Date

2020

DOI

10.5070/D3264048346

Copyright Information

Copyright 2020 by the author(s). This work is made available under the terms of a Creative Commons Attribution-NonCommercial-NoDerivatives License, available at <https://creativecommons.org/licenses/by-nc-nd/4.0/>

Peer reviewed

A case of bullous Sézary syndrome

Sam Wu MD, Francie Jenkins BS, Rachel Byrd MD, Paul B Googe MD, Puneet Singh Jolly MD PhD

Affiliations: University of North Carolina at Chapel Hill, Department of Dermatology, Chapel Hill, North Carolina, USA

Corresponding Author: Puneet Jolly MD PhD, 410 Market Street, Suite 400, Chapel Hill, NC 27516, Tel: 984-974-3900, Email: Puneet_Jolly@med.unc.edu

Abstract

Sézary syndrome is a rare leukemic subtype of cutaneous T cell lymphoma that is characterized by erythroderma, lymphadenopathy, and malignant T cells in the peripheral blood. Poor prognostic factors of Sézary syndrome include advanced disease stage, older age at onset, and large cell transformation. Presentation with bullous lesions, though rare, has been reported in a few patients. We present an elderly woman with bullous Sézary syndrome who presented with a two-month history of progressive rash. Upon admission, the patient had pruritic, erythematous, edematous plaques with overlying flaccid bullae and erosions involving the scalp, neck, torso, and extremities. Despite treatment, the patient died two months after presentation. Although rare, bullous lesions associated with Sézary syndrome may indicate poor prognosis.

Keywords: Sézary syndrome, bullous lesions, cutaneous T cell lymphoma

Introduction

Sézary syndrome is a rare leukemic subtype of cutaneous T cell lymphoma (CTCL) characterized by erythroderma, lymphadenopathy, and malignant T cells (Sézary cells) in the peripheral blood [1]. Although the erythroderma is often accompanied by lichenification, keratoderma, nail dystrophy, and alopecia, bullous lesions are a rare finding in Sézary syndrome [1, 2]. Sézary syndrome can arise in the setting of pre-existing mycosis fungoides or as a de novo form of T cell lymphoma. Although mycosis fungoides is of resident effector memory T cell origin,

de novo primary Sézary syndrome is derived from central memory T cells, showing a characteristic expression of PD1 amidst the neoplastic T cells. We present a case of bullous Sézary syndrome and discuss the prognostic significance of bullous lesions in Sézary syndrome and mycosis fungoides.

Case Synopsis

A 70-year old woman was admitted for pruritic, erythematous, edematous plaques with overlying flaccid bullae and erosions involving the scalp, neck, torso, and extremities (**Figure 1**). Her rash had been slowly progressing over the two months prior to admission and was associated with shallow ulcerations on the tongue and conjunctival injection. She also demonstrated facial skin thickening, ectropion, nail changes, and palmar keratoderma. She had a history of hypertension, diabetes, and hypercholesterolemia and was on medications to treat these conditions. There had not been any changes to her medications for several months preceding her symptoms. A skin biopsy from her chest showed a striking pattern of epidermal infiltration by neoplastic cells, which were also present at the interface between the epidermis and papillary dermis resulting in intraepidermal and subepidermal bulla formation (**Figure 2**). Many larger neoplastic cells and frequent mitoses were identified. Cytologically, neoplastic cells were medium-to-large in size with round-to-oval nuclear contours and prominent nucleoli. Immunophenotypically, these neoplastic cells were positive for CD3, CD4, and negative for CD8, CD20, CD30, CD34, and CD56. Complete blood count

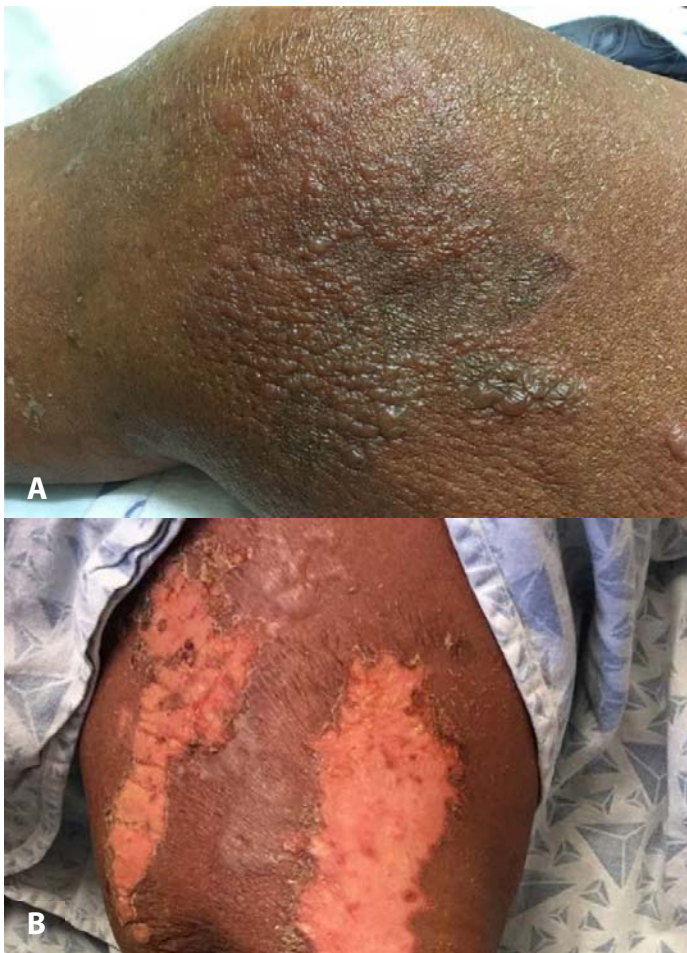

Figure 1. Clinical images of bullous Sézary syndrome. **A)** Right leg showing vesicles and bullae superimposed on erythematous, edematous plaques. **B)** Rupture of bullae resulting in erosions on right arm.

showed a markedly elevated white blood cell count at 55.7×10^3 cells/ μ L with 86% lymphocytes. Peripheral blood was analyzed by flow cytometry, which showed 88% lymphocytes with a CD4:CD8 ratio of 232:1. T cells were positive for CD3, CD4, CD5, CD25 and negative for CD7, CD8, CD10 and CD56. A PET-CT demonstrated increased uptake in bilateral neck, axillary, iliac, and inguinal lymph nodes. A biopsy of a right axillary lymph node showed effacement of normal architecture by innumerable medium-to-large cells with prominent nucleoli that were positive for CD3, CD4 and negative for CD7, CD8, similar to the neoplastic population in the skin. T cell gene rearrangement studies performed on peripheral blood demonstrated a clonal T cell population and cytogenetics also showed changes consistent with T cell malignancy. Antibodies to human T-cell lymphotropic virus I and II were

negative. Testing for herpes simplex virus and varicella zoster virus from cutaneous lesions by PCR was negative. Direct immunofluorescence of perilesional skin and serum indirect immunofluorescence were negative for autoimmune bullous diseases. Given her constellation of clinical symptoms, flow cytometry analysis, and histology, she was diagnosed with bullous Sézary syndrome. She received one cycle of cyclophosphamide-doxorubicin-vincristine-prednisone chemotherapy but she developed infectious complications with both urosepsis and superinfection of cutaneous lesions. She succumbed to her disease less than two months after presentation.

Case Discussion

Bullous lesions are a rare and serious presentation of Sézary syndrome and mycosis fungoides. We present a 70-year-old woman with Sézary syndrome who presented with extensive pruritic flaccid bullae over most of her body. At presentation, given the pruritic nature of her lesions as well as numerous flaccid bullae and oral involvement, autoimmune blistering disorders as well as Stevens Johnson syndrome/toxic epidermal necrolysis (SJS/TEN) were high on our differential diagnosis. Skin biopsies for H&E and immunofluorescence as well as blood analysis for indirect immunofluorescence conclusively demonstrated no evidence of blistering disease and also did not support a diagnosis of SJS/TEN. Immunohistochemistry as well as peripheral blood flow cytometry strongly supported an underlying diagnosis of a cutaneous T cell lymphoma. Subsequent PET-CT scan showed lymph node involvement as well, which was confirmed by biopsy. Although a diagnosis of bullous mycosis fungoides was also considered, her peripheral blood and lymph node involvement along with typical SS clinical features of ectropion, thickened facial skin, nail changes, and palmar keratoderma favored a diagnosis of bullous Sézary syndrome.

Bullous mycosis fungoides or MF bullosa was first characterized by Kaposi in 1887 with fewer than 30 cases reported in the literature to date [3]. Bullous

Sézary syndrome is even rarer with fewer than 10 cases reported. Bullous lesions may arise in existing lesions of CTCL or as the initial presentation, may be associated with patch, plaque, or tumoral lesions and display a predilection for the torso and extremities [2, 4–11]. Oral mucosal involvement was present in our patient and has been described in one other case of bullous Sézary syndrome [9]. Both bullous MF and Sézary syndrome carry a poor prognosis with almost half of patients succumbing to their disease within one year [2, 12, 13]. Histology of bullous lesions may show an intraepidermal or subepidermal split along with features of MF or Sézary syndrome [14]. Immunofluorescence studies are necessary to rule out various autoimmune bullous disorders including pemphigus, pemphigoid, linear IgA, and paraneoplastic pemphigus.

The pathogenesis of intraepidermal and subepidermal bullae in Sézary syndrome is unclear, but proposed hypotheses include the confluence of multiple Pautrier microabscesses resulting in intraepidermal vesicles and the disruption of keratinocyte-basal lamina attachment by epidermotropic lymphocytes resulting in subepidermal vesicles [1, 2, 5]. Alternatively, lymphokines released by atypical lymphocytes have been postulated to be responsible for loss of keratinocyte cohesion [3]. In contrast, an ultrastructural study found normal keratinocyte-keratinocyte and keratinocyte-basal lamina cohesion and proposed that the formation of bullae may instead relate to degeneration of dermal collagen induced by neoplastic cells [15]. Notably, a vesicular variant of MF has also been described, in which clinical findings of weeping, vesicular eczematous plaques correspond to histologic findings of prominent intercellular edema and intraepidermal mucin; this entity exhibits a more aggressive clinical course. In contrast to the proposed mechanisms for the pathogenesis of bullous SS, vesicular MF has been postulated to reflect a transition from a Th1 to a Th2 cytokine profile, which includes the upregulation of the immunosuppressive cytokine IL10 and correlates with disease progression [16]. Negative prognostic factors for Sézary syndrome and

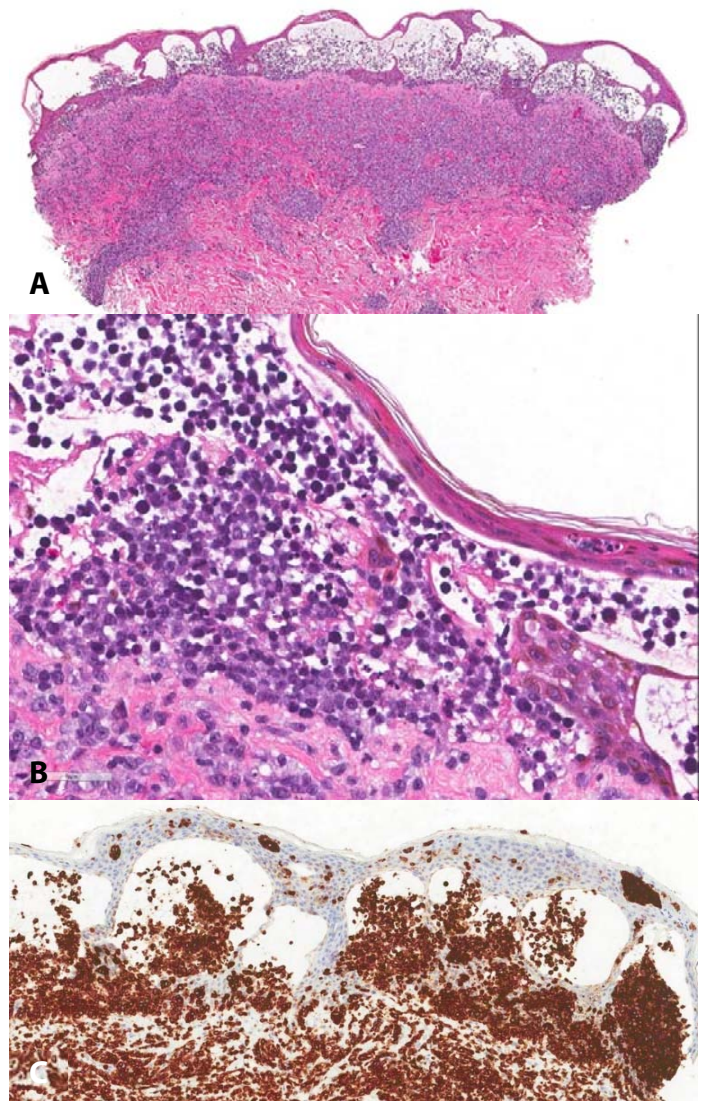


Figure 2. Histopathological images of bullous Sézary syndrome of chest biopsy. **A)** Dense infiltrate of atypical lymphocytes in the upper dermis with striking infiltration into the epidermis. Large collections of neoplastic cells disrupting the epidermis and dermoepidermal junction result in formation of intraepidermal and subepidermal bullae. H&E, 400 \times , **B)** Morphologically, atypical cells are intermediate to large in size with prominent nucleoli, H&E, 400 \times , **C)** and stain positively for CD3, 400 \times .

mycosis fungoides include advanced disease stage, older age at onset, and large cell transformation [17]. In patients with bullous mycosis fungoides, approximately 50% died within one year of presentation [2, 13]. Of the reported cases of bullous Sézary syndrome, two patients passed away within one year of presentation and one patient was in remission at 15 months although longer term follow-up was not reported [9–11]. This parallels the disease

progression of the patient presented in this report, further suggesting that although extremely rare, the presence of bullous lesions in Sézary syndrome portends a poor prognosis.

Conclusion

This case describes bullous lesions as a rare presentation of Sézary syndrome. Although bullous lesions in CTCL predominantly occur on the torso and extremities as was seen in our patient, oral involvement was also present in our case, which

underscores the importance of distinguishing this entity from important conditions in the differential diagnosis including SJS/TEN and autoimmune blistering disorders. A majority of these patients died within one year from presentation. These findings suggest that the development of bullous lesions in cutaneous T cell lymphoma may be associated with a poorer prognosis.

Potential conflicts of interest

The authors declare no conflicts of interests

References

1. Yamashita T, Abbade LPF, Marques MEA, Marques SA. Mycosis fungoides and Sézary syndrome: clinical, histopathological and immunohistochemical review and update. *An Bras Dermatol*. 2012;87:817–28. [PMID: 23197199].
2. Bowman PH, Hogan DJ, Sanusi ID. Mycosis fungoides bullosa: report of a case and review of the literature. *J Am Acad Dermatol*. 2001;45:934–939. [PMID: 11712043].
3. Kartsonis J, Brettschneider F, Weissmann A, Rosen L. Mycosis fungoides bullosa. *Am J Dermatopathol*. 1990;12:76–80. [PMID: 2138435].
4. Sato S, Okamoto O, Kawamoto M, et al. Bullous mycosis fungoides associated with an extensive ulcer and a severe leukemoid reaction. *Dermatol Reports*. 2011 5;3:e54. [PMID: 2538630].
5. Xu X-L, Huang Y-X, Lin L, et al. Bullous mycosis fungoides: report of a case complicated by Kaposi's varicelliform eruption. *J Dermatol*. 2013;40:844–847. [PMID: 23961851].
6. Garb J. Mycosis fungoides with bullous lesions. *Arch Derm Syphilol*. 1943 1;48:359.
7. Natsuga K, Shimizu T, Abe R, Kodama K, Shimizu H. Mycosis fungoides bullosa. *Arch Dermatol*. 2006;142:793–795. [PMID: 16785397].
8. Kneitz H, Bröcker EB, Becker JC. Mycosis fungoides bullosa: a case report and review of the literature. *J Med Case Reports*. 2010 3;4:78. [PMID: 20196875].
9. Ono A, Isomura I, Isogai Z, et al. A case of bullous Sézary syndrome. *J Dermatol*. 2004;31:1027–1031. [PMID: 15801270].
10. Zina G, Bernengo MG, Zina AM. Bullous Sézary Syndrome. *Dermatologica*. 1981;163:25–33. [PMID: 7024006].
11. Dehesa L, Bastida J, Camacho-Galán R, et al. Vesicular Sézary syndrome with bullous lesions on the feet. *Eur J Dermatol*. 2009;19:282–283. [PMID: 19258239].
12. Kamran B, Fatemeh M, Ahmadrza R, Azita N. Bullous mycosis fungoides: a case report. *Dermatol Online J*. 2008 28;14:11. [PMID: 18700114].
13. Momtahan S, Nuovo GJ, Magro CM. Vesicular Mycosis Fungoides. *Am J Dermatopathol*. 2015;37:724–729. [PMID: 25545185].
14. Ahn CS, AlSayyah A, Sangüeza OP. Mycosis fungoides: an updated review of clinicopathologic variants. *Am J Dermatopathol*. 2014;36:933–48. [PMID: 25415138].
15. Ueda C, Makino T, Asano Y, et al. An ultrastructural examination of a blistering lesion of mycosis fungoides bullosa. *Br J Dermatol*. 2011;165:213–214. [PMID: 21428969].
16. Momtahan S, Nuovo GJ, Magro CM. Vesicular Mycosis Fungoides. *Am J Dermatopathol*. 2015;37:724-9. [PMID: 25545185].
17. Foss FM, Girardi M. Mycosis fungoides and Sezary syndrome. *Hematol Oncol Clin North Am*. 2017;31:297–315. [PMID: 28340880].