

UC Davis

Dermatology Online Journal

Title

Pitted keratolysis: successful management with mupirocin 2% ointment monotherapy

Permalink

<https://escholarship.org/uc/item/6155v9wk>

Journal

Dermatology Online Journal, 21(8)

Authors

Greywal, Tanya
Cohen, Philip R

Publication Date

2015

DOI

10.5070/D3218028430

Copyright Information

Copyright 2015 by the author(s). This work is made available under the terms of a Creative Commons Attribution-NonCommercial-NoDerivatives License, available at <https://creativecommons.org/licenses/by-nc-nd/4.0/>

Peer reviewed

Case presentation

Pitted keratolysis: successful management with mupirocin 2% ointment monotherapy

Tanya Greywal BA¹ and Philip R Cohen MD²

Dermatology Online Journal 21 (8): 7

¹School of Medicine and ²Department of Dermatology, University of California, San Diego, San Diego, California

Correspondence:

Tanya Greywal, BA
9767 Alto Drive
La Mesa, CA 91941
tgreywal@gmail.com

Philip R. Cohen, MD
10991 Twinleaf Court
San Diego, CA 92131
mitehead@gmail.com

Abstract

Background: Pitted keratolysis is a benign dermatosis that occurs on plantar skin.

Purpose: We describe a man with pitted keratolysis that was successfully treated with mupirocin 2% ointment monotherapy.

Methods and Materials: We reviewed PubMed for the following terms: mupirocin, ointment, pitted keratolysis, treatment. We also reviewed papers containing these terms and their references.

Results: Complete resolution of pitted keratolysis occurred following monotherapy with twice daily application of mupirocin 2% ointment for a duration of three weeks. There was no recurrence at a follow-up visit eight weeks later.

Conclusions: Several topical and oral treatments are available to successfully manage pitted keratolysis. Our patient confirms previous reports of pitted keratolysis resolving with mupirocin 2% ointment treatment. Monotherapy with mupirocin 2% ointment should be considered as a primary treatment alternative for pitted keratolysis.

Key words: keratolysis, mupirocin, ointment, pitted, treatment

Introduction

Pitted keratolysis is a benign plantar dermatosis with a characteristic clinical appearance. Systemic and/or topical antibiotics can be used to successfully treat this condition. We describe a man with pitted keratolysis whose dermatosis rapidly resolved after application of mupirocin 2% ointment monotherapy.

Case Synopsis

A 48 year-old man presented with lesions of several months duration on the heels of his feet. These plantar lesions were asymptomatic with no presence of malodor or hyperhidrosis. The patient swims frequently.

Cutaneous examination of the heels showed thickened yellow skin with crevices and pits in the central area. The lateral areas of the affected skin showed well-margined crater-like pits (Figure 1).

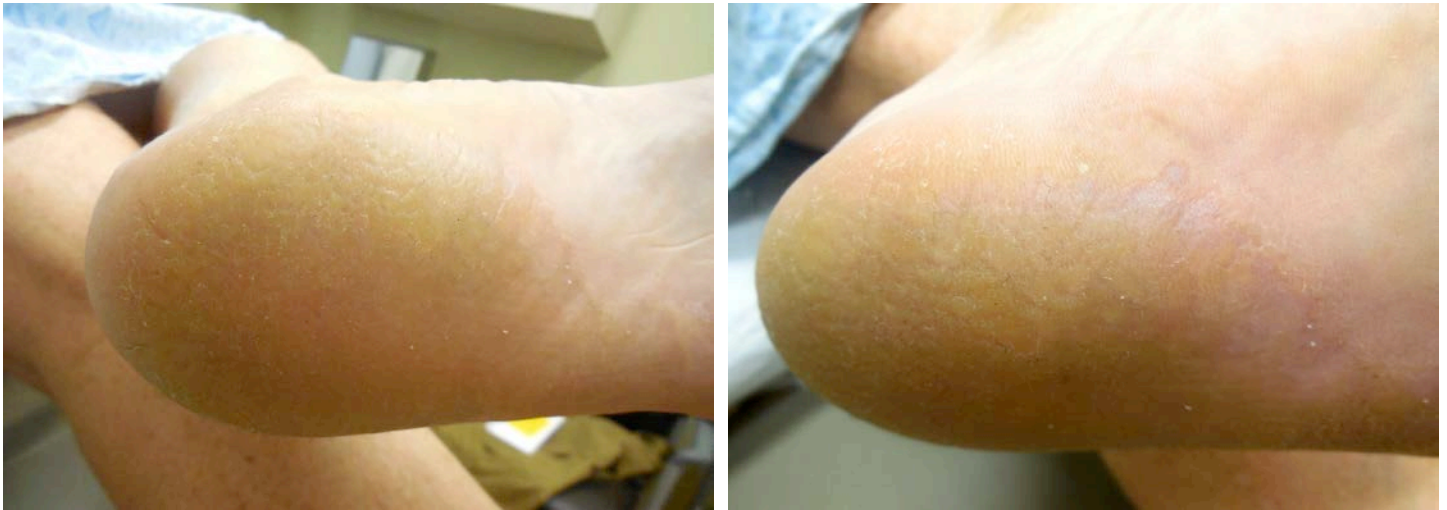

Figure 1. Distant (a) and close (b) views of the pitted keratolysis on the left plantar foot. The lateral heel shows typical appearing morphology of pitted keratolysis with well-margined crater-like pits. The central area shows thickened yellow skin with linear and round depressions.

Correlation of the clinical history and presentation established the diagnosis of pitted keratolysis. Twice daily application of mupirocin 2% ointment was prescribed as monotherapy. The patient observed complete resolution after three weeks of treatment, and then discontinued the medication. Follow-up examination eight weeks after his initial presentation confirmed the complete resolution of pitted keratolysis on both feet (Figure 2).

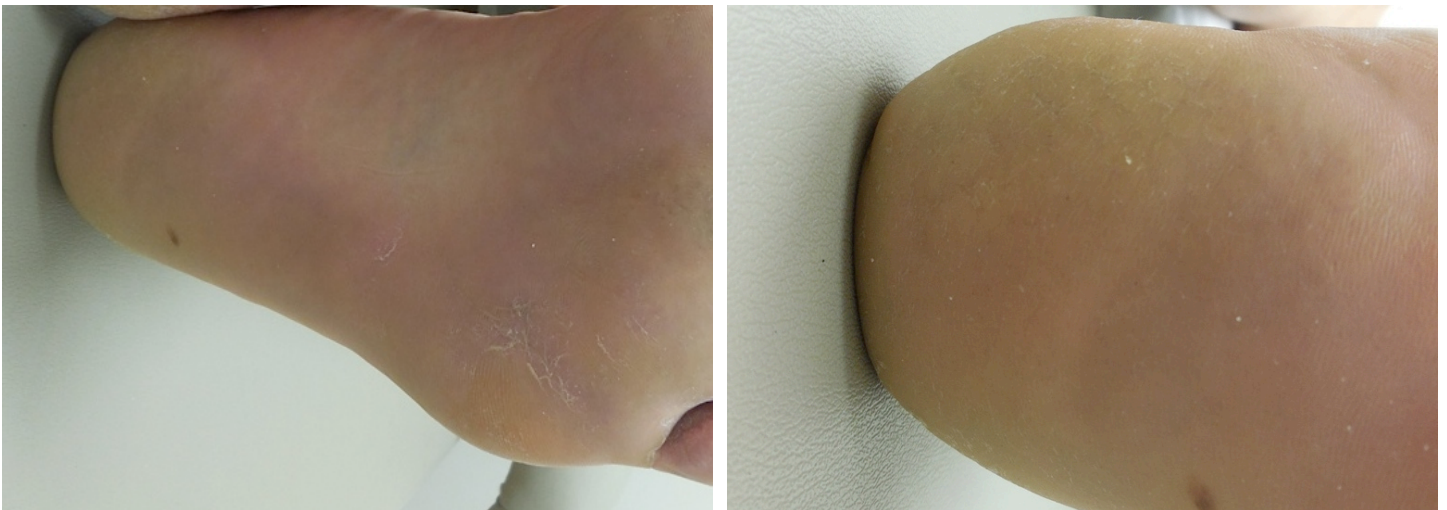


Figure 2. Distant (a) and close (b) views of the left heel from the same individual after three weeks of twice daily application of mupirocin 2% ointment. There is complete resolution of the pitted keratolysis at both the periphery of the dermatosis and within the thickened central area.

Discussion

Pitted keratolysis (which has also been referred to as keratoma plantare sulcatum, keratolysis plantare sulcatum, keratolysis punctata, and ringed keratolysis) is a superficial skin infection that most commonly presents in warm, moist, and occluded environments such as the feet [1-3]. This disease is present worldwide, but is most prevalent in tropical areas where higher humidity levels and more barefoot populations exist [1-4]. Pitted keratolysis does not have a predilection for any particular age or race, but is more common in men than in women [4-6]. Male predominance is likely caused by the higher incidence of pitted keratolysis risk factors: hyperhidrosis and occupations or sport activities that require occlusive footwear [5-7].

Pitted keratolysis usually presents as discrete, circular, crater-like pits on the pressure-bearing areas of the soles [1-5,7,8]. These lesions are shallow (1-2mm deep) with a diameter of 0.5-7mm, producing a “punched-out appearance” of the skin [4,7,8]. Collarettes can also be present, particularly on the palms, which is a rare location for pitted keratolysis [1,2,7,8]. The progression of pitted keratolysis can lead to erosions and maceration of the skin [2,3,7]. Although pain and discomfort is not usually associated, pitted keratolysis can produce a burning sensation, pruritus, and tenderness [4,7-9]. Those patients whose lesions are more symptomatic typically present with greater erythema and thick plaques [7,10]. In addition, most patients report malodor, hyperhidrosis, and sliminess of the feet [2,4,8,9,11].

The diagnosis of pitted keratolysis is classically based upon clinical presentation [5,8]. A Wood’s lamp does not consistently show coral red fluorescence. However, its presence may aid in the diagnosis [4,5,12]. A culture of the lesions can be done, but each organism involved requires special agar [4]. Biopsies are not frequently performed [4,5]. If tissue is obtained, hematoxylin-eosin stain will show organisms in the stratum corneum with dermal inflammation [9]. Electron microscopy reveals bacteria with transverse septations and a surrounding translucent halo within the intracellular spaces of the stratum corneum [9,11,13]. The differential diagnosis for pitted keratolysis includes basal cell nevus syndrome, eczema, hyperkeratosis, keratolysis exfoliativa, plantar verruca, porokeratosis, tinea pedis, tungiasis, and yaws [4,5,8].

Pitted keratolysis is caused by gram-positive bacterial organisms: *Corynebacterium* species, *Kytococcus sedentarius* (formerly *Micrococcus sedentarius*), and *Dermatophilus congolensis* [3,11,14]. The presence of *Corynebacterium* species is most common in pitted keratolysis [6]. However, all of these bacteria possess keratolytic enzymes that allow invasion into the stratum corneum, producing characteristic plantar pits [3,11,14]. The warm, moist, and occlusive environment in which these organisms thrive is thought to promote bacterial proliferation and keratin degradation [3,5]. Researchers previously believed hyperhidrosis to be the main predisposing factor for infection; therefore focusing on the reduction of sweating as a prime therapy [5,6]. However, a more recent investigation determined that hyperhidrosis in pitted keratolysis results from a bacterial infection that induces eccrine sweat gland hyperfunction [6].

The treatment of pitted keratolysis is usually directed by the type of bacterial microorganism present. Oral antibiotics or topical antibiotics or a combination of both are typically used (Table 1) [1-3,5,8-12,15-16]. Mupirocin is a topical antibiotic that is usually used to treat *Streptococcus* and *Staphylococcus* infections, including methicillin-resistant *Staphylococcus aureus*. To the best of our knowledge, there are only two reports in which mupirocin 2% ointment monotherapy was used to treat pitted keratolysis [10,12].

Table 1. Antibiotic Management of Pitted Keratolysis

Systemic Antibiotics	Topical Antibiotics
Cephalexin [9]	Clindamycin hydrochloride, 1% solution [15]
Clindamycin [5]	Clindamycin phosphate, 1% solution [3]
Erythromycin [1,2,9]	Clindamycin 1%-Benzoyl peroxide 5% gel [5]
	Erythromycin, 4% gel [16]
	Fusidic acid, cream [8]
	Mupirocin, 2% ointment [9,10,12]
	Neomycin [5]

In 1996, Vasquez-Lopez and Perez-Olivia reported the successful management of four patients with severe pitted keratolysis [10]. They were all industrial workers with occlusive footwear and hyperhidrosis, presenting with painful pitted keratolysis with erosions. Topical “conventional treatments” did not provide a complete response. After mupirocin ointment was initiated, there was “a rapid disappearance of the disease” in all four patients.

Several years later, Argomániz and Castillo reported a case of pitted keratolysis in a 33 year-old man [12]. He presented with a history of malodor and hyperhidrosis of his feet for several years. Examination findings were consistent with pitted keratolysis with maceration. The patient had significant improvement after two weeks of topical mupirocin treatment that was applied twice daily.

Prompted by these observations, we elected to also treat our patient with mupirocin ointment monotherapy. Our patient's lesions completely resolved within three weeks of treatment initiation and did not recur when evaluated during a subsequent follow-up appointment. We chose an emollient-based antibiotic, in contrast to other alcohol-based antibiotics, since our patient did not have hyperhidrosis.

Conclusion

Pitted keratolysis presents as crater-like pits on the soles of feet and is associated with a *Corynebacterium* species, *Kytococcus sedentarius*, or *Dermatophilus congolensis* infection. Management typically includes topical and/or oral antibiotics to which these gram-positive organisms are susceptible. Our patient's pitted keratolysis rapidly resolved after initiation of monotherapy with mupirocin 2% ointment, confirming similar observations in only two previously published studies using mupirocin therapy. Mupirocin 2% ointment results in the rapid resolution of the dermatosis; it also provides a topical emollient to patients without associated hyperhidrosis. We respectfully suggest that twice daily application of mupirocin 2% ointment monotherapy be considered as one of the first line treatments for pitted keratolysis.

References

1. Zaias N. Pitted and ringed keratolysis. A review and update. *J Am Acad Dermatol.* 1982;7:787-791. [PMID: 6757285]
2. Tamura BM, Cucé LC, Souza RL, Levites J. Plantar hyperhidrosis and pitted keratolysis treated with botulinum toxin injection. *Dermatol Surg.* 2004;30:1510-1514. [PMID: 15606827]
3. Bristow IR, Lee YLH. Pitted keratolysis. A clinical review. *J Am Podiatr Med Assoc.* 2014;104:177-182. [PMID: 15606827]
4. Singh G, Naik CL. Pitted keratolysis. *Indian J Dermatol Venereol Leprol.* 2005;71:213-215. [PMID: 15606827]
5. Vlahovic TC, Dunn SP, Kemp K. The use of a clindamycin 1%-benzoyl peroxide 5% topical gel in the treatment of pitted keratolysis: a novel therapy. *Adv Skin Wound Care.* 2009;22:564-566. [PMID: 15606827]
6. Pranteda G, Carlesimo M, Pranteda G, Abruzzese C, Grimaldi M, de Micco S, Muscianese M, Bottoni U. Pitted keratolysis, erythromycin, and hyperhidrosis. *Dermatol Ther.* 2014;27:101-104. [PMID: 24703267]
7. Nordstrom KM, McGinley KJ, Cappiello L, Zechman JM, Leyden JJ. Pitted keratolysis. The role of *Micrococcus sedentarius*. *Arch Dermatol.* 1987;123:1320-1325. [PMID: 24703267]
8. Khachemoune A, Janjua SA. Pits on the soles of the feet. *J Fam Pract.* 2005;54:597-598. [PMID: 16009086]
9. Cuadros GRG, del Prado YMFN, Estrada JA. Queratolisis punctata emergente en los Andes Cusco-Perú. *Med Cutan Iber Lat Am.* 2006;34:223-228.
10. Vazquez-Lopez F, Perez-Oliva N. Mupirocine ointment for symptomatic pitted keratolysis. *Infection.* 1996;24:55. [PMID: 16009086]
11. De Almeida HL, de Castro LAS, Rocha NEM, Abrantes VL. Ultrastructure of pitted keratolysis. *Int J Dermatol.* 2000;39:698-701. [PMID: 11044196]
12. Argomániz EB, Castillo AT. Queratolisis plantar sulcatum. Formación medica continuada en atención primaria. 2007;14:555-556.
13. Tilgen W. Pitted keratolysis (keratolysis plantare sulcatum). Ultrastructural study. *J Cutan Pathol.* 1979;6:18-30. [PMID: 438391]
14. Longshaw CM, Wright JD, Farrell AM, Holland KT. *Kytococcus sedentarius*, the organism associated with pitted keratolysis, produces two keratin-degrading enzymes. *J Appl Microbiol.* 2002;93:810-816. [PMID: 12392527]
15. Burkhart CG. Pitted keratolysis: a new form of treatment. *Arch Dermatol.* 1980;116:1104. [PMID: 12392527]
16. Kaptanoglu AF, Yuksel O, Ozyurt S. Plantar pitted keratolysis: a study from non-risk groups. *Dermatol Rep.* 2012;4:14-16.