

UCLA

UCLA Previously Published Works

Title

Magnesium therapy for intractable ventricular tachyarrhythmias in normomagnesemic patients.

Permalink

<https://escholarship.org/uc/item/6117t3sb>

Journal

Arizona Medicine, 138(6)

ISSN

0093-0415

Authors

Iseri, LT
Chung, P
Tobis, J

Publication Date

1983-06-01

Copyright Information

This work is made available under the terms of a Creative Commons Attribution License, available at <https://creativecommons.org/licenses/by/4.0/>

Peer reviewed

Magnesium Therapy for Intractable Ventricular Tachyarrhythmias in Normomagnesemic Patients

LLOYD T. ISERI, MD; PETER CHUNG, MD, and JONATHAN TOBIS, MD, Orange, California

Intractable ventricular tachyarrhythmia associated with hypomagnesemia responds well to magnesium given intravenously. Two patients with recurrent ventricular tachycardia and ventricular fibrillation associated with normal serum magnesium levels and resistant to treatment with potassium chloride, lidocaine and bretylium tosylate responded dramatically to the administration of magnesium sulfate. A third patient in whom the serum magnesium level was unknown also showed dramatic response to magnesium therapy.

Magnesium depletion probably interferes with sodium-potassium adenosine triphosphatase enzyme activity and causes ionic imbalance and electrical instability of Purkinje's fibers. Without obvious magnesium depletion this element in high concentration may still prolong transient inward current, prolong the effective refractory period, increase the membrane potential and control ventricular tachyarrhythmia.

When ventricular fibrillation or malignant ventricular tachycardia cannot be controlled with lidocaine and other conventional drugs, we recommend infusing magnesium sulfate, 2 to 3 grams in one minute, followed by 10 grams over five hours.

Repeated episodes of ventricular tachycardia and ventricular fibrillation requiring cardioversion and administration of lidocaine, procainamide hydrochloride, bretylium tosylate and potassium chloride are frequently encountered in patients with ischemic heart disease. The value of magnesium in correcting these potentially lethal dysrhythmias in hypomagnesemic patients has been well established,^{1,2} but its role in treating patients with normal serum magnesium levels has not been described or documented. We report two cases of ischemic heart disease in which the patients had normal serum magnesium levels and in which magnesium sulfate was used successfully to treat intractable ventricular tachycardia and ventricular fibrillation. A third case in which the patient's serum magnesium level was unknown and there were repeated episodes of ventricular fibrillation is also presented.

Reports of Cases

CASE 1. The patient, a 75-year-old woman with a permanent epicardial pacemaker, was admitted to hospital because of dizziness and faintness. A year before she had had an episode of ventricular tachycardia and procainamide therapy was begun but because of a lupus reaction the drug was discontinued. She had been re-

ceiving quinidine, furosemide, potassium chloride, propranolol hydrochloride and levothyroxine. Propranolol therapy was stopped two days before admission because of the development of congestive heart failure. Digoxin was not prescribed. The blood pressure was 100/60 mm of mercury and the heart was being paced at 82 per minute. The lungs were clear, heart sounds were normal and there was no edema. The serum sodium level was 143, potassium 2.9 and magnesium 1.6 mEq per liter; quinidine concentration was 2.4 µg per ml and creatine kinase 26 units per liter (Figure 1). Arterial blood gas determinations done with the patient breathing room air showed a pH of 7.44, a partial carbon dioxide pressure (PCO₂) of 36 mm of mercury and a partial oxygen pressure (PO₂) of 90 mm of mercury. In the emergency room, she had several episodes of ventricular tachycardia converted with precordial thump or by countershock. She was given lidocaine and admitted to the intensive care unit where she continued to have recurrent ventricular tachycardia and ventricular fibrillation. She was given by mouth potassium chloride, 20 mEq every six hours, and quinidine, 300 mg every six hours, and the following drugs intravenously: potassium chloride, 5 mEq per hour; lidocaine, 50, 75 and 75 mg, followed by 4 mg per minute by infusion;

Refer to: Iseri LT, Chung P, Tobis J: Magnesium therapy for intractable ventricular tachyarrhythmias in normomagnesemic patients. West J Med 1983 Jun; 138:823-828.

From the Division of Cardiology, Department of Medicine, California College of Medicine, and University of California Irvine Medical Center, Orange. Submitted, revised, November 3, 1982.

Reprint requests to Lloyd T. Iseri, MD, Professor of Medicine, Division of Cardiology, UCI Medical Center, 101 City Drive So, Orange, CA 92668.

ABBREVIATIONS USED IN TEXT

PCO₂=partial carbon dioxide pressure
PO₂=partial oxygen pressure

propranolol, 5 mg four times in one hour, and bretylium, 300, 600 and 900 mg, followed by 2 mg per minute by infusion. Lidocaine administration was stopped because of toxic symptoms and a serum concentration of 7 µg per ml. Despite these medications and return of the serum potassium value to 4.1 mEq per liter and the spontaneous rise of the magnesium value to 2.6 mEq per liter, the patient continued to have recurrent ventricular tachycardia and ventricular fibrillation requiring a total of 30 direct-current countershocks in a 24-hour period (Figure 2). Magnesium sulfate was then given intravenously at a dose of 16 mEq over 20 minutes followed by an intravenous infusion at 8 mEq per hour. Except for one short run of ventricular tachycardia, which converted spontaneously, there were no further episodes and cardiac rhythm became stable with a continuously paced mode. The serum magnesium level four hours after starting therapy was 3.7 mEq per liter, rising to 4.2 mEq per liter eight hours later. The blood pressure began to fall but rose to control levels after bretylium administration was stopped.

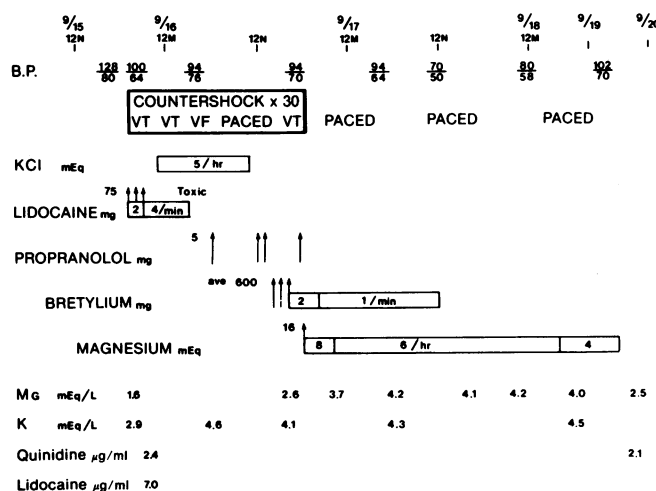


Figure 1.—Diagram showing response to treatment of patient in case 1. The patient had recurrent ventricular tachycardia (VT) and ventricular fibrillation (VF). B.P.=blood pressure, KCl=potassium chloride, Mg=magnesium, K=potassium.

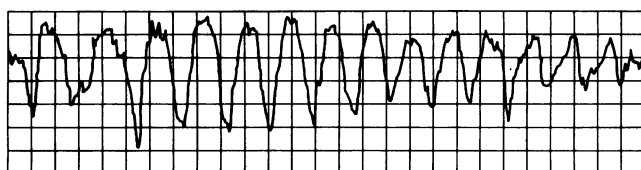


Figure 2.—Electrocardiographic rhythm strip from patient in case 1 showing coarse ventricular fibrillation.

Cardiac catheterization two weeks later showed complete occlusion of the left anterior descending, 75 percent occlusion of the right coronary and 75 percent occlusion of the circumflex arteries and an apical aneurysm. Cardiac output was 2.1 liters per minute and the pulmonary artery wedge pressure was 7 mm of mercury. Two weeks later a three-vessel saphenous vein bypass surgical procedure was done and the patient was discharged in stable condition 2½ weeks later.

Comment. The development of recurrent ventricular tachycardia and fibrillation in this patient was most probably the result of multiple factors involving myocardial ischemia, a tendency to hypokassemia, quinidine therapy and propranolol withdrawal. The electrocardiographic findings originally resembled "torsades de pointes." A valiant effort was made to control the life-threatening arrhythmia. Lidocaine, bretylium, potassium chloride and propranolol were given to maximal doses without success. Finally, even with normal serum levels, magnesium sulfate was given intravenously with a dramatic cessation of ventricular tachycardia and fibrillation.

CASE 2. The patient, a 58-year-old woman, was admitted with severe congestive heart failure. She had had two coronary artery bypass procedures and a porcine mitral valve replacement six months before. She had been taking digoxin, furosemide, potassium chloride, quinidine and hydralazine hydrochloride. She had distended neck veins, atrial fibrillation, pulmonary rales, a pansystolic apical murmur and mild ankle edema. Her blood pressure was 100/62 mm of mercury, pulse rate 88 per minute, respirations 22 and temperature 36.5°C (97.7°F). Her weight was 62 kg. Laboratory studies gave the following values (Figure 3): serum potassium, 3.8, sodium, 140, and magnesium, 1.9 mEq per liter; creatinine, 1.5 mg per dl; creatine kinase, 12 units per

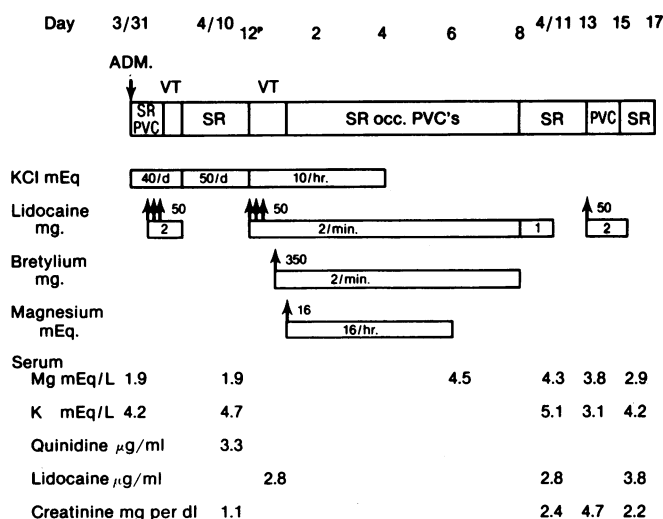


Figure 3.—Diagram showing response to treatment of patient in case 2. The patient had recurrent ventricular tachycardia (VT), with dramatic return to sinus rhythm (SR) and occasional premature ventricular contractions (PVC) following administration of magnesium sulfate. KCl=potassium chloride, Mg=magnesium, K=potassium.

MAGNESIUM THERAPY FOR TACHYARRHYTHMIAS

liter; quinidine concentration, 2.9 μg per ml; digoxin content, 1.6 ng per ml; arterial blood pH, 7.49, PCO_2 , 24.6 mm of mercury, and PO_2 , 90.1 mm of mercury.

Pulmonary congestion was relieved by giving high doses of furosemide supplemented with potassium chloride. On the second day, short runs of ventricular tachycardia developed, controlled by giving lidocaine intravenously, followed by quinidine by mouth, with serum concentrations of 2.4 to 4.3 μg per ml.

Cardiac catheterization done on the eighth day showed an akinetic posterobasal ventricular aneurysm, 2+ mitral regurgitation, occluded native right coronary and circumflex arteries and severely diseased left main and proximal anterior descending arteries. The graft to the mid-anterior descending artery was patent but the grafts to the right coronary and circumflex arteries were not seen. The pulmonary artery pressure was 55/25 mm of mercury and the wedge pressure was 14.7 mm of mercury. The cardiac index was 1.73 liters per minute per sq m and there was evidence of pericardial thickening. The ejection fraction was 59 percent.

On the 11th day, the patient had cough, chills and fever, became hypoxic and had a cardiac arrest with a quick series of 5- to 20-second ventricular beats electrocardiographically resembling torsades de pointes (Figure 4).³ Arterial blood gas determinations made with the patient breathing oxygen by mask showed a pH of 7.54, PCO_2 21.2 and PO_2 61.5 mm of mercury. Laboratory studies disclosed the following values: serum potassium, 4.7, and magnesium, 1.9 mEq per liter; quinidine, 3.3 μg per ml; digoxin, 1.4 ng per ml, and creatinine, 1.1 mg per dl. The patient responded only parti-

ally to lidocaine with a serum concentration of 2.8 μg per ml, and frequent multifocal premature ventricular beats of up to six in sequence continued to recur despite the administration of lidocaine and full doses (350 mg) of bretylium. After an endotracheal tube was inserted the arterial blood gas studies showed a pH of 7.45, PCO_2 26.7 and PO_2 88.6 mm of mercury. Ventricular tachycardia however continued to recur. The blood pressure also fell from 110/60 to 90/58 mm of mercury. Administration of magnesium sulfate, 10 ml of 20 percent solution given intravenously over one minute, followed by infusion of 2 percent solution at 100 ml per hour for five hours, promptly eliminated the episodes of ventricular tachycardia and sharply reduced the total number of ectopic premature ventricular beats from 45 a minute to 3 a minute (Figure 5). Administration of both lidocaine and bretylium was continued at 2 mg per minute. Because of a further fall in the blood pressure to 78/40 mm of mercury, bretylium therapy was discontinued. This was promptly followed by a rise in the blood pressure to 96/52 mm of mercury. Pneumonia developed, which was treated with gentamicin sulfate and nafcillin sodium. On the following morning the serum potassium value was 5.1, magnesium 4.5 and sodium 127 mEq per liter, and the creatinine level 3.4 mg per dl. The endotracheal tube was removed and the patient's condition stabilized on a regimen of procainamide, digoxin, furosemide, captopril, spironolactone and potassium chloride. After gradual improvement of her cardiopulmonary and renal functions, she was discharged from hospital on the 43rd day.

Comment. In this patient who has advanced coronary

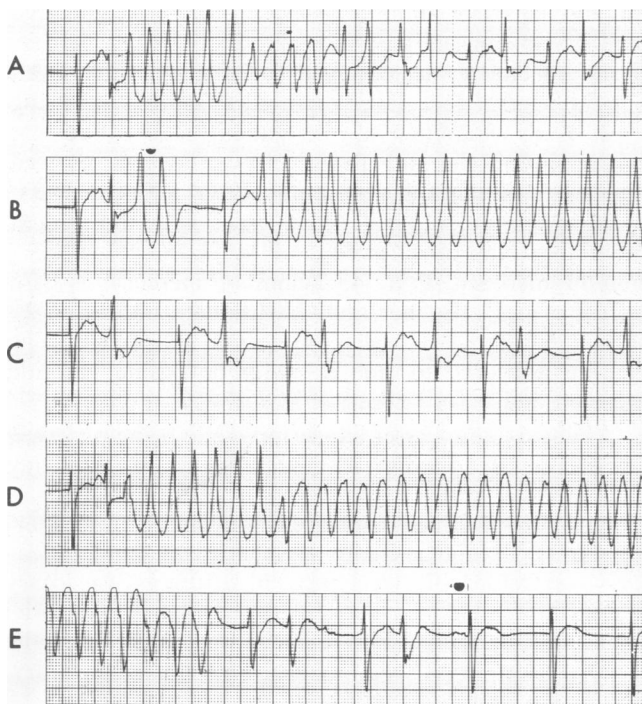


Figure 4.—Electrocardiographic tracings from patient in case 2 showing episodes of ventricular tachycardia resembling torsades de pointes.

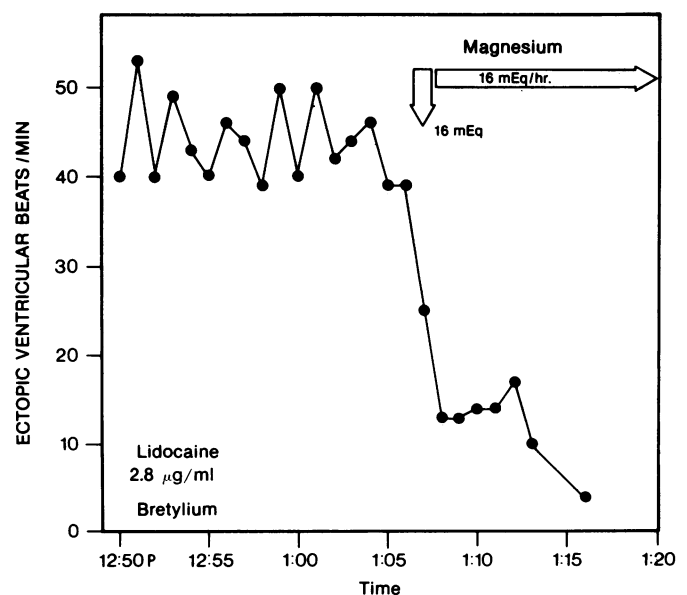


Figure 5.—Schematic showing ventricular response in patient in case 2 following magnesium therapy. The average of 45 ectopic ventricular beats per minute before magnesium therapy represents 30 episodes of ventricular tachycardia in a 15-minute period. After magnesium therapy, no episodes of ventricular tachycardia were seen, except for two runs of three ectopic beats.

MAGNESIUM THERAPY FOR TACHYARRHYTHMIAS

artery and valvular heart disease and ventricular aneurysm, recurrent ventricular tachycardia most probably developed because of hypoxia and respiratory alkalosis from pneumonia. Quinidine concentration in the blood had fallen from 4.3 to 3.3 μg per ml at the time of recurrence of ventricular tachycardia. The digoxin concentration was within the therapeutic range. Serum potassium and magnesium levels were also within normal limits.

Recurrence of ventricular tachycardia could not be controlled by lidocaine or bretylium infusion or by

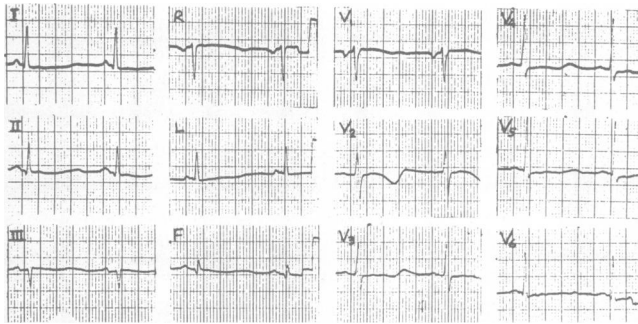


Figure 6.—A 12-lead electrocardiogram done on the patient in case 3 on admission to hospital.

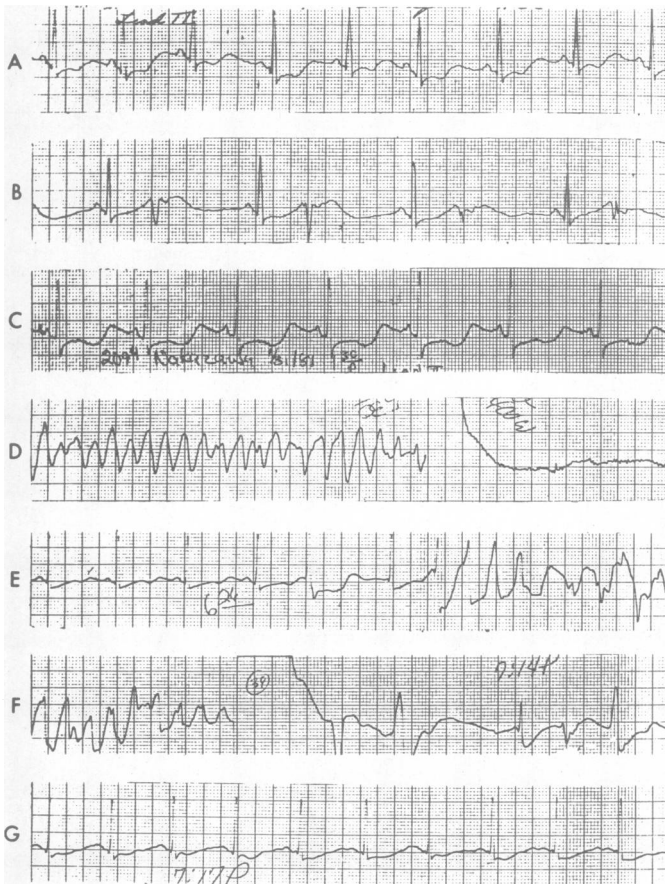


Figure 7.—Representative electrocardiographic tracings of patient in case 3 of hypopotassemia, premature ventricular contractions and repeated episodes of ventricular fibrillation.

endotracheal intubation and improvement of blood gas values. Additional boluses of bretylium were not given because of a drop in the blood pressure. Control of the rhythm, on the other hand, was quite dramatic following the infusion of magnesium sulfate (Figure 5). Episodes of ventricular tachycardia ceased immediately and the number of ectopic ventricular beats per minute fell sharply.

CASE 3. The patient, a 58-year-old male pharmacist, was brought to a local hospital after fainting while driving on the freeway and damaging his car; he was not injured. He had had hypertension for four years and a three-vessel coronary artery bypass operation a year before. He had been taking quinidine gluconate, 325 mg twice a day, hydrochlorothiazide, 50 mg a day, metoprolol tartrate, 25 mg twice a day, and potassium chloride, 16 mEq a day. He said he had had no recent chest pains, shortness of breath, dizziness or syncope.

On admission the blood pressure was 170/100 mm of mercury. The pulse rate was regular at 60 per minute. He weighed about 70 kg. Lung fields were clear and heart sounds were normal. There was no edema. The electrocardiogram showed a sinus bradycardia at 55 per minute, apparent QT prolongation with prominent U waves and probably an old inferior wall infarction (Figures 6 and 7-A). Laboratory studies disclosed the following values: serum potassium, 2.4 mEq per liter; sodium, 140 mEq per liter; blood urea nitrogen, 9 mg per dl; creatinine, 1.2 mg per dl; chloride, 100 mEq per liter, and serum quinidine, 1.8 μg per ml. Serum creatine kinase level was 40 units per liter, α -hydroxybutyrate dehydrogenase, 179 units per ml (normal, 140 to 350), lactate dehydrogenase, 136 units per ml, and aspartate aminotransferase (formerly, glutamic oxaloacetic transaminase [SGOT]), 24 units per liter. A serum specimen was obtained for a magnesium level, but the results were never reported (Figure 8). During chest x-ray examination, the patient had a transient syncope episode and the electrocardiogram showed bigeminal premature ventricular beats (Figure 7-B). Measurement of arterial blood gases with the patient breathing room air showed a pH of 7.45, Po_2 of 53.7 mm of mercury, Pco_2 43.2 mm of mercury, a base excess of 5.5 mEq per liter, bicarbonate radical of 29 mEq per liter and oxygen saturation 90 percent. The rhythm appeared to stabilize with potassium chloride infusion and nasal oxygen (Figure 7-C).

About six hours after admission while being observed in the intensive cardiac care unit the patient suddenly had a cardiac arrest with ventricular fibrillation (Figure 7-D) and immediately received 400 joules of counter-shock. The blood pressure was 160/100 mm of mercury just before the arrest and 240/150 mm of mercury immediately after successful defibrillation. Arterial blood gas determinations made immediately after the arrest showed a pH of 7.53, Po_2 55.6 mm of mercury, Pco_2 34.4 mm of mercury and oxygen saturation 92.5 percent. The serum potassium value was reported later to be 2.6 mEq per liter. Lidocaine, 100 mg intravenously, and 4 mg per minute by intravenous infusion,

MAGNESIUM THERAPY FOR TACHYARRHYTHMIAS

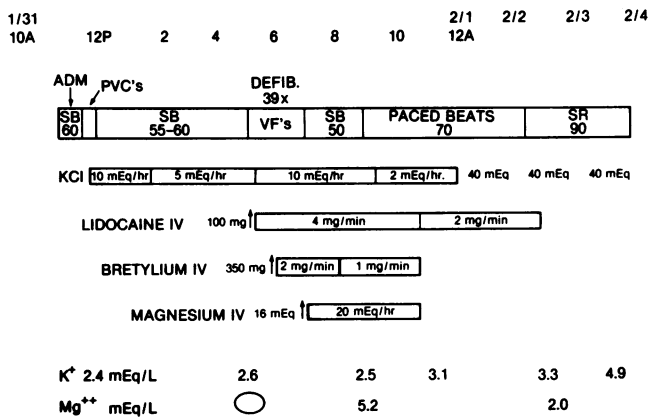


Figure 8.—A schematic showing response to treatment of patient in case 3 who had recurrent ventricular tachycardia and fibrillation. ADM=admission, PVC's=premature ventricular contractions, SB=sinus bradycardia, DEFIB=defibrillation, KCl=potassium chloride, K⁺=potassium, Mg⁺⁺=magnesium.

was immediately given and the potassium chloride infusion rate was increased to 10 mEq per hour. Despite this management ventricular fibrillation and ventricular tachycardia continued to recur, requiring eight separate countershocks in the next 30 minutes. Numerous periods of torsades de pointes were seen. Bretylium tosylate, 350 mg given intravenously and 2 mg per minute by intravenous infusion, was then added but ventricular fibrillation and tachycardia continued to recur, requiring 31 more countershocks in the next 75 minutes. In desperation, even without knowing the serum magnesium level, magnesium sulfate was infused at a dose of 10 ml of 20 percent solution over one minute, followed by 125 ml of 2 percent solution per hour by intravenous infusion. Immediately following the initial infusion of magnesium sulfate the ventricular tachycardia and fibrillation ceased (Figure 7-G). The blood pressure fell to 180/106 mm of mercury after the administration of bretylium and to 110/80 mm of mercury after we added magnesium. Sinus bradycardia of 50 beats per minute again recurred and a temporary pacemaker electrode was inserted to prevent recurrence of ventricular fibrillation. Serial creatine kinase levels were 2,449, 1,624 and 1,673 units per liter with MB fractions of 3 percent, 4 percent and 4 percent, respectively. These high values were considered to be due to the numerous countershocks.

About 3½ hours after starting magnesium therapy, the deep tendon reflexes at the knees disappeared and

the serum magnesium level was 5.2 mEq per liter. Administration of both bretylium and magnesium was stopped and the dose of lidocaine infusion was decreased to 2 mg per minute. Pacing was also discontinued. Procainamide administration, 350 mg four times a day by mouth, was started on the second day to maintain normal rhythm.

A sinus rhythm of 90 per minute supervened and the blood pressure became stable at 130/90 mm of mercury. With potassium chloride supplements, the serum potassium level rose to 3.3 and then to 4.9 mEq per liter. The magnesium level three days later was 2.0 mEq per liter. The pacer electrode was removed and after observation in another hospital for ten days, the patient was discharged. He returned to work as a pharmacist six weeks later.

Comment. The mechanism for this patient's initial syncope resulting in an automobile accident is speculative but the episode he had shortly after being admitted, which was accompanied immediately afterwards by bigeminal premature ventricular beats, suggested that he had transient ventricular tachycardia. Subsequent cardiac arrests preceded by periods of ventricular tachycardia resembling torsades de pointes appeared to confirm this impression (Figure 7-D and E).³ He had increased the dosage of hydrochlorothiazide without increasing potassium supplements and clearly had hypokalemia and alkalosis on admission. In addition, the magnesium was probably depleted.⁴ The failure of the serum potassium level to rise after he received potassium supplements and the rise in the serum potassium level after magnesium administration supports this notion.

Other factors may have contributed to the development of ventricular tachycardia. The patient was known to have ventricular irritability and had been receiving quinidine gluconate therapy prophylactically. Although the serum quinidine concentration was well below the toxic level it could have caused QT prolongation and the development of torsades de pointes.⁵ Hypoxia presumably due to hypokalemic hypoventilation persisted and may have also aggravated the situation. Although acute myocardial infarction was ruled out, myocardial ischemia is always a threat in patients following a coronary bypass procedure.

Whatever the cause of the ventricular tachycardia and ventricular fibrillation, the dramatic turn of events following magnesium therapy after administration of 60 mEq of potassium chloride, two hours of lidocaine

TABLE 1.—Laboratory Values in Patients Before Administration of Magnesium Sulfate

Case	Drug Concentrations		Diuretic Agent	Serum Values		Arterial Blood Gases		
	Digoxin ng/ml	Quinidine µg/ml		Potassium mEq/liter	Magnesium mEq/liter	pH	PCO ₂ mm/mercury	Po ₂ mm/mercury
1	0.0	2.4	Furosemide	4.1	2.6	7.44	36.0	90.0
2	1.4	3.3	Furosemide	4.7	1.9	7.54	21.2	61.5
3	0.0	1.8	Hydrochlorothiazide	2.6	?	7.45	43.2	53.7

PCO₂=partial carbon dioxide pressure, Po₂=partial oxygen pressure.

therapy and one hour of bretylium therapy had failed attests to the value of magnesium.

Discussion

Magnesium is essential for many enzyme systems, among which is the activation of membrane-bound adenosine triphosphatase controlling transfer of sodium and potassium across the cell membrane.⁶ Depression of this enzyme activity results in decreased intracellular potassium and increased intracellular sodium leading to electrical instability of Purkinje's fibers. Undoubtedly when hypomagnesemia is present, intractable tachyarrhythmias can be corrected immediately by magnesium replacement.² There is, however, equivocal evidence that when the serum magnesium level is not low, arrhythmias could still be corrected by magnesium.⁷ It has been shown recently by direct measurement of skeletal muscles that prolonged diuretic therapy results in a loss of cellular potassium and magnesium.⁸ These cellular losses could be prevented by magnesium but not by potassium replacement. The cellular changes did not correlate with plasma concentrations either for potassium or for magnesium.⁹ Because all three patients described here were on prolonged diuretic therapy, cellular depletion of these two interlocked elements probably occurred. Whether or not magnesium therapy will protect against ventricular tachyarrhythmia in patients with a normal serum level and without substantial cellular depletion of magnesium cannot be answered. Some evidence suggests, however, that high magnesium levels may prolong the effective refractory period and increase the membrane potential (make more negative). These changes have been suggested as a mechanism of the antiarrhythmic effects of magnesium.¹⁰ Magnesium has also been shown to block the transient inward current generated by cardiotonic steroids.¹¹ Specificity of magnesium therapy in the treatment of recurrent ventricular fibrillation with a serum digoxin concentration of 20 ng per ml in a recent case was reaffirmed when giving maximum doses of lidocaine and phenytoin (Dilantin) had initially failed. It is entirely possible that a transient inward current not due to digitalis preparations may be responsible for the recurrent ventricular tachycardia and fibrillation described here and that administering magnesium in high doses blocked these currents and was thereby effective in controlling the rhythm.

All three patients were also taking quinidine (Table 1) and the possibility that this drug is responsible for ventricular tachycardia must be strongly considered. However, the successful disruption of recurrent ventricular tachycardia with magnesium despite continued use of quinidine in one case indicated that at least in this case quinidine was not solely responsible for the arrhythmia.¹² If quinidine toxicity indeed was responsible for the arrhythmia in these cases, magnesium would have to be considered an effective antidote. The ionic basis for such a relationship has not been reported.

The importance of these observations lies in the fact that parenteral magnesium therapy may be life-saving

in cases of intractable recurring ventricular tachycardia and fibrillation even with normal serum magnesium levels.

We recommend that if lidocaine infusions fail to control these potentially lethal rhythms, magnesium infusion be started immediately along with potassium even before serum levels for these elements are known. Oliguric forms of renal failure resulting in hyperpotassemia and hypermagnesemia will obviously contraindicate such replacement therapy but absence of hyperkalemic electrocardiographic changes and the presence of deep tendon reflexes should give some assurance that neither hyperpotassemia nor hypermagnesemia is present. A "sick sinus syndrome" or evidence of atrioventricular block previously diagnosed or brought to light after cardioversion may necessitate temporary pacing before either magnesium or potassium therapy can be started. Mild hypotension brought on by magnesium therapy is considered no more dangerous than that caused by the administration of procainamide or bretylium and for that reason magnesium infusion can be recommended as a second-line drug in the treatment of recurring ventricular fibrillation.

For intravenous infusion, 10 to 15 ml of 20 percent magnesium sulfate (16 to 24 mEq) solution given slowly for one minute followed by 500 ml of 2 percent magnesium sulfate (80 mEq) solution given over five hours is recommended.² Administration of a second bottle of 500 ml of 2 percent magnesium sulfate solution given over ten hours may be necessary in those patients severely depleted of magnesium. Potassium chloride infusion at 10 mEq per hour for five hours is also recommended because there is substantial evidence that potassium and magnesium depletion usually occurs together.^{4,13} Needless to say, overdosage with these drugs should be monitored closely with serum levels, electrocardiograms, blood pressure readings and neurologic examinations for such manifestations as loss of deep tendon reflexes.

REFERENCES

1. Loeb HS, Petras RJ, Gunrar RM, et al: Paroxysmal ventricular fibrillation in two patients with hypomagnesemia. *Circulation* 1967; 37: 210-215
2. Iseri LT, Freed J, Bures AR: Magnesium deficiency and cardiac disorders. *Am J Med* 1975; 58:837-846
3. Smith WM, Gallagher JJ: Les torsades de pointes: An unusual ventricular arrhythmia. *Ann Intern Med* 1980; 93:578-584
4. Whang R, Oei TO, Aikawa JK, et al: Magnesium and potassium interrelationships, experimental and clinical. *Acta Med Scand* 1981; (Suppl) 647:139-144
5. Jenzer HR, Hagemeijer F: Quinidine syncope: Torsade de pointes with low quinidine plasma concentrations. *Eur J Cardiol* 1976 Dec; 4: 447-451
6. Wacker WEC: The biochemistry of magnesium. *Ann NY Acad Sci* 1969; 162:717-726
7. Enselberg CD, Simmons HG, Mintz AA: The effects of magnesium upon cardiac arrhythmias. *Am Heart J* 1950; 39:703-712
8. Wester P, Dyckner T: Diuretic treatment and magnesium losses. *Acta Med Scand* 1981; (Suppl) 647:145-152
9. Dyckner T, Wester P: Relation between potassium, magnesium and cardiac arrhythmias. *Acta Med Scand* 1981; (Suppl) 647:163-169
10. Parmituan JC, Dreifus LS, Watanabe Y: Comparative mechanisms of antiarrhythmic agents. *Am J Cardiol* 1970; 26:512-519
11. Kass RS, Lederer WJ, Tsien RW, et al: Role of calcium ions in transient inward currents and aftercontractions induced by strophantidin in cardiac Purkinje fibres. *J Physiol (Lond)* 1978 Aug; 281:187-208
12. Horowitz LN, Greenspan AM, Spielman SR, et al: Torsades de pointes: Electrophysiologic studies in patients without transient pharmacologic or metabolic abnormalities. *Circulation* 1981 May; 63:1120-1128
13. Whang R, Aikawa J: Magnesium deficiency and refractoriness to potassium repletion. *J Chronic Dis* 1977 Feb; 30:65-68