

## **UC Irvine**

### **Western Journal of Emergency Medicine: Integrating Emergency Care with Population Health**

#### **Title**

Asymptomatic Chronic Dislocation of a Cemented Total Hip Prosthesis

#### **Permalink**

<https://escholarship.org/uc/item/60j6w9bf>

#### **Journal**

Western Journal of Emergency Medicine: Integrating Emergency Care with Population Health, 15(1)

#### **ISSN**

1936-900X

#### **Authors**

Salvi, Andrea Emilio  
Florschutz, Anthony Vatroslav  
Grappiolo, Guido

#### **Publication Date**

2014

#### **DOI**

10.5811/westjem.2013.8.19078

#### **Copyright Information**

Copyright 2014 by the author(s). This work is made available under the terms of a Creative Commons Attribution-NonCommercial License, available at <https://creativecommons.org/licenses/by-nc/4.0/>

Peer reviewed

## Asymptomatic Chronic Dislocation of a Cemented Total Hip Prosthesis

Andrea Emilio Salvi, MD\*

Anthony Vatroslav Florschutz, MD, PhD<sup>†</sup>

Guido Grappiolo, PD, MD<sup>‡</sup>

\* Mellino Mellini Hospital Trust, Civil Hospital of Iseo (Brescia), Orthopaedics and Traumatology Department, Italy

<sup>†</sup> Georgia Regents University, Department of Orthopaedic Surgery, Augusta, Georgia, United States

<sup>‡</sup> Clinical Institute "Humanitas", Prosthetic Surgery Unit, Rozzano (Milano), Italy

*Supervising Section Editor:* Sean Henderson, MD

Submission history: Submitted July 27, 2013; Revision received August 13, 2013; Accepted August 26, 2013

Electronically published November 27, 2013

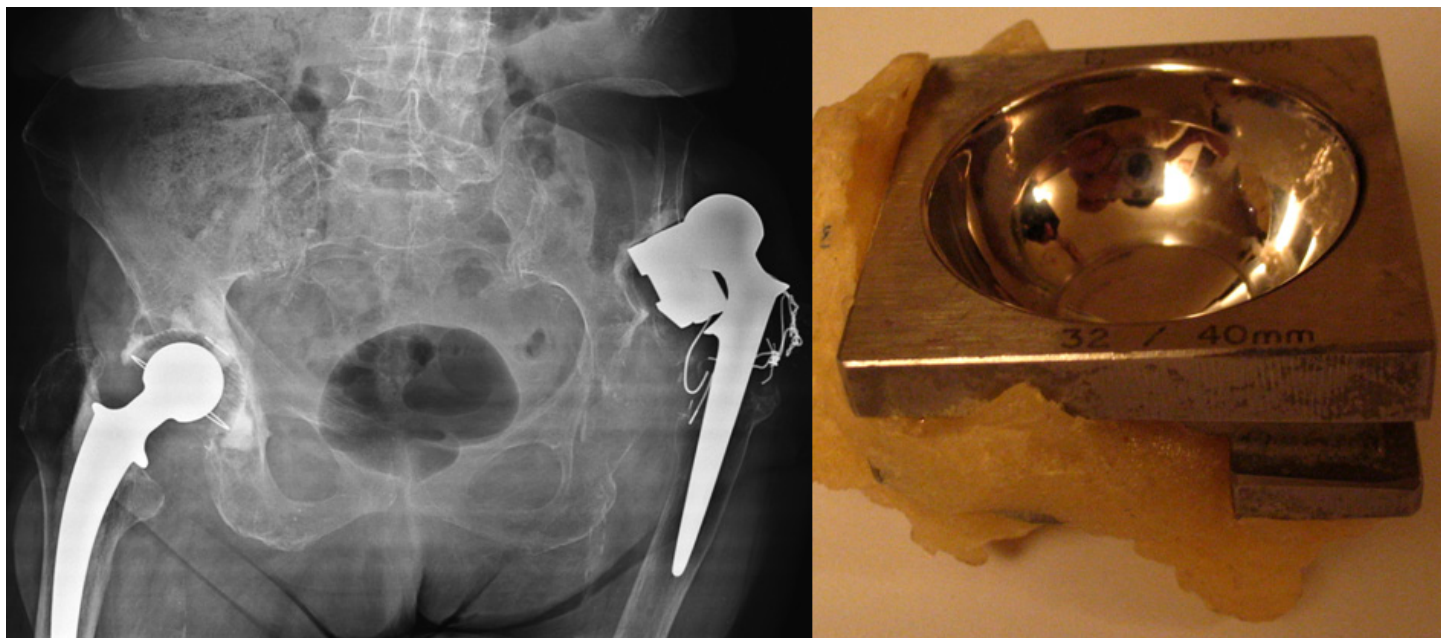
Full text available through open access at [http://escholarship.org/uc/uciem\\_westjem](http://escholarship.org/uc/uciem_westjem)

DOI: 10.5811/westjem.2013.8.19078

[West J Emerg Med. 2014;15(1):107–108.]

Dislocation of a total hip prosthesis is a painful and mentally stressful orthopaedic emergency.<sup>1</sup> It may be long-standing and asymptomatic, typically involving the femoral portion.<sup>2-4</sup> This report describes a peculiar chronic dislocation of both components of a total hip prosthesis. A 93-year-old female patient, thin and of short stature, had come to our attention for recent onset of lumbar pain at the orthopaedic department. She walked with significant unequal lengths of the lower limbs. She had previously been operated on for bilateral total hip replacement, in which the left hip, a Brunelli version (Brescia, Italy, 1977), was performed 30 years ago for dysplasia.<sup>5</sup> At

the emergency department, lumbar spine and pelvis radiographs were taken, showing scoliosis and vertebral arthrotic deformations, along with dislocation of both total left hip replacement components (Figure). It was detected that the femoral stem was loosened. Patient denied any fall injury or accident to the operated left hip. It was decided not to perform surgery because of the patient's age. Many case reports have discussed hip dislocations in which a femoral component was involved. To our knowledge, this is the first case of dislocation of both prosthetic elements of a hip replacement that was completely asymptomatic while walking.



**Figure.** Bilateral hip prosthetization with dislocation of both prosthetic components of the left hip. This is a Brunelli THR version, peculiar for the squared and cemented socket. On the right is visible a color photo of an explanted cup. The cemented socket is rotated and the cemented straight stem is loosened. Surgical approach used was the Watson-Jones (wire cerclage is visible around greater trochanter).

---

*Address for Correspondence:* Andrea Emilio Salvi, MD. Via Cipro 30 25124 Brescia, Italy. Email: andreasalvi@bresciaonline.it

---

*Conflicts of Interest:* By the WestJEM article submission agreement, all authors are required to disclose all affiliations, funding sources and financial or management relationships that could be perceived as potential sources of bias. The authors disclosed none.

## REFERENCES

1. Masaoka T, Yamamoto K, Shishido T, et al. Study of hip joint dislocation after total hip arthroplasty. *Int Orthop.* 2006;30(1):26-30.
2. Lidder S, Ranawat VS, Ranawat NS, et al. Chronic asymptomatic dislocation of a total hip replacement: a case report. *J Med Case Rep.* 2009;19(3):8956.
3. Kindsfater KA, Bureau CA, Sherman CM. Unrecognized acetabular component rotation with formation of a pseudoarticulation after total hip arthroplasty. *J Arthroplasty.* 2010;25(3):498.e11-14.
4. Salvi AE, Pezzoni M, Salvi S, et al. The "wall-socket" technique. Proposal of a new surgical procedure for revision acetabular arthroplasty. *Acta Biomed.* 2008;79(3):233-239.
5. Brunelli G. A new square-contoured acetabulum and straight stem hip replacement. *Int Orthop.* 1977;(1):36-38.