

# UC Davis

## UC Davis Previously Published Works

### Title

Pediatric SubQ-ICD implantation, a single center review of the inter-muscular technique.

### Permalink

<https://escholarship.org/uc/item/602927jg>

### Journal

Indian Pacing and Electrophysiology Journal, 21(1)

### ISSN

0972-6292

### Authors

Erickson, Kari  
Hiremath, Gurumurthy  
Rodgers, Nathan  
[et al.](#)

### Publication Date

2021

### DOI

10.1016/j.ipej.2020.10.007

Peer reviewed



Contents lists available at ScienceDirect

# Indian Pacing and Electrophysiology Journal

journal homepage: [www.elsevier.com/locate/IPEJ](http://www.elsevier.com/locate/IPEJ)

## Pediatric SubQ-ICD implantation, a single center review of the inter-muscular technique



Daniel Cortez<sup>a,\*</sup>, Kari Erickson<sup>b</sup>, Gurumurthy Hiremath<sup>a</sup>, Nathan Rodgers<sup>a</sup>,  
Brenda Dugas<sup>b</sup>, Elizabeth Braunlin<sup>a</sup>, Rebecca Ameduri<sup>a</sup>, Jamie L. Lohr<sup>a</sup>

<sup>a</sup> University of Minnesota/Masonic Children's Hospital, Minneapolis, USA

<sup>b</sup> Fairview Health Systems, Minneapolis, USA

### ARTICLE INFO

#### Article history:

Received 12 May 2020

Received in revised form

29 October 2020

Accepted 31 October 2020

Available online 19 November 2020

#### Keywords:

Subcutaneous ICD

Pediatrics

Intermuscular

### ABSTRACT

**Introduction:** Pediatric patients with cardiomyopathies are at risk for sudden death and may need implantable cardioverter defibrillators (ICD's), but given their small size and duration of use, children are at increased risk for complications associated with ICD use. The subcutaneous ICD presents a favorable option for children without pacing indications. Unfortunately, initial pediatric studies have demonstrated a high complication rate, likely due to the 3-incision technique employed.

**Material and methods:** Patients with ICD but no pacing indication were retrospectively reviewed after implantation of subcutaneous ICD via the two-incision technique. In half of the patients, 10-J impedance test was also performed to compare with impedance obtained after defibrillation threshold testing with 65-J.

**Results:** Twelve patients were included. The median age was 14 years (range 10–16 years) with eight males included (72.7%). The median weight was 55 kg (range 29 kg–75.1 kg). Follow-up had a median of 11.5 months (range 2–27 months). The median body mass index was 18.4 kg/m squared (range 15.5–27.9 kg/m squared). One patient suffered a minor complication after tearing off the incisional adhesive strips early and required a non-invasive repair in clinic. Shock impedance had a median of 55 J (range 48–68 J). There was one appropriate shock/charge and no inappropriate shocks during follow-up.

**Conclusion:** The two-incision, intermuscular technique appears to have a lower acute complication rate than prior reports, in our cohort of 12 pediatric patients.

Copyright © 2020, Indian Heart Rhythm Society. Production and hosting by Elsevier B.V. This is an open access article under the CC BY-NC-ND license (<http://creativecommons.org/licenses/by-nc-nd/4.0/>).

## 1. Introduction

Implantable cardioverter-defibrillators (ICD's) help prevent sudden cardiac death due to ventricular arrhythmias in children with cardiomyopathies and ion-channelopathies. Recent studies have demonstrated feasibility of a three-incision technique in children, whereas a 2-incision technique has only been described in small pediatric cohorts [1,2]. Unfortunately, size-limitations and previous sub-fascial and subcutaneous techniques probably factored into a high rate of short-term complications, as high as 25–40% in the pediatric population [2–4]. We aim to present a case series of pediatric patients with the intermuscular technique. Furthermore, no papers have commented on the necessity of 65 J

defibrillation threshold testing versus 10 J shock for impedance assessment in the pediatric population. We review a single-center population of pediatric patients where the intermuscular technique was used with very low short-term complication rate. We also demonstrate early assessment of low-output shock (10-J) testing and its correlation with 65-J shock impedances testing.

## 2. Materials and methods

This was a retrospective chart review performed at a single pediatric center, in which patients underwent primary or secondary prevention subcutaneous ICD placements, which was approved by the institutional review board of the University of Minnesota.

### 2.1. Subcutaneous ICD screening

All patients with indication for ICD implant, without pacing indication, were screened with the automated electrocardiogram screening through Boston Scientific's device interrogator in the

\* Corresponding author. 5thFloor East Building 8951 H, 2450 Riverside Avenue Floor East Building 8951 H, 2450 Riverside Avenue, Minneapolis, MN, 55454, USA.

E-mail address: [dcortez@umn.edu](mailto:dcortez@umn.edu) (D. Cortez).

Peer review under responsibility of Indian Heart Rhythm Society.

laying, sitting and standing positions, including with the sternal electrode to the left and to the right of the sternum. All patients but one passed at least one vector in the left parasternal position while right parasternal position increased passing vectors in an additional two patients. The primary vector was most compatible in six of the 12 patients (50%) while six patients received the secondary vector (50%) and one patient the alternative vector (8.3%) as the preferred sensing vector.

## 2.2. Implantation procedure

All procedures were performed in the electrophysiology laboratory (approved for surgical procedures). Implantations were all performed, under general anesthesia, by a pediatric electrophysiologist with support from the manufacturer's technicians. The intermuscular approach (between the serratus anterior and the latissimus dorsi) was performed on all patients. All patients received antibiotic (cefuroxime) at implant which was re-dosed according to hospital guidelines. A demonstration device was used to help map and draw surgical lines on the patient, with use of single plan and very brief fluoroscopy (all cases <0.2 min of fluoroscopy). The Emblem A219 model (Boston Scientific, Natick, MA, USA) was implanted in each patient using the two-incision technique, as described by Knops et al. [5]. Specifically, the lead is positioned by means of a standard 11-French peel-away sheath which is placed over the shaft of the insertion tool and tunneled along the parasternal border (either to the left or right) to line up to the desired position at the sterno-manubrial junction. The sheath is left in place while the insertion tool is removed. The lead is then passed through the insertion sheath and the sheath peeled away. Decision to place the lead to the left or to the right of the sternum was based on previous screening vectors with the screen involving electrodes to the left and to the right of the sternum. The top electrode was not sutured in place and thus slack in the sternal lead was present to allow for future growth of the pediatric patient (Fig. 1 and Fig. 2).

## 2.3. Follow-up

Routine follow-up included a one-week postoperative visit; a one-month visit with either the electrophysiologist or primary

cardiologist; and a two-to three-month visit with the electrophysiologist. Subsequent yearly visits were scheduled along with visits to the primary cardiologist. An EKG is taken at each visit and echocardiogram performed during the first year. All patients also received Latitude home monitoring and were active with three-month follow-ups via remote transmissions.

## 2.4. Statistical analysis

Given this is a small descriptive study, and our endpoint of surgical complications occurred in only one patient, statistical analyses of complications could not be performed. Spearman correlation coefficient testing was performed between impedance values for 10 J shock and 65 J defibrillation threshold testing.

## 3. Results

A total of 12 pediatric patients had subcutaneous implantable cardioverter defibrillators placed, with a median age of 14 years (range 8–16 years), and 9 males included (75%). The median weight was 56 kg (range 29 kg–75.1 kg) and median height was 164.5 cm (cm) with range of 130–180 cm, with median body mass index (BMI) of 18.4 kg/m squared (range 15.5–27.9 kg/m squared). Median follow-up was 11.5 months (range 2–27 months). Eight patients met screening criteria in all positions mentioned above while one patient only met primary vector for screening criteria. The median impedance for the 65 J defibrillation threshold testing was 59  $\Omega$  (range 48–68ohms), while the median impedance for the 10-J test shock was 57 J (range 55–72). The Spearman correlation coefficient between the six values for 10-J test and 65-J defibrillation yielded an R-value of 0.87 (p-value 0.05). The median time to charge during defibrillation threshold testing was 14 s (range 11–16 s). One patient had a complication of partial xyphoid wound dehiscence in the setting of removing his Steri-strips early and placing tension on his incision. He did not develop an infection but was treated empirically with five days of antibiotics and the wound was approximated in clinic with Steri-strips and sterile skin-adhesive. There was one appropriate shock/charge during the follow-up period. There were no inappropriate shocks. Please see Table 1 for details.

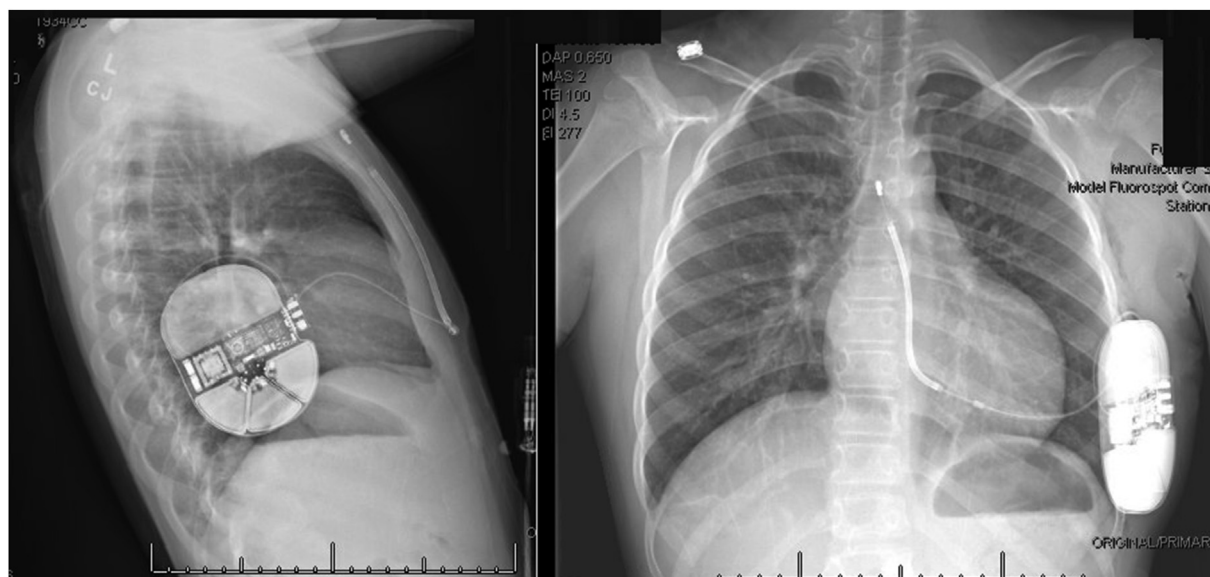


Fig. 1. Subcutaneous ICD placement with slightly angled sternal lead due to patient size.

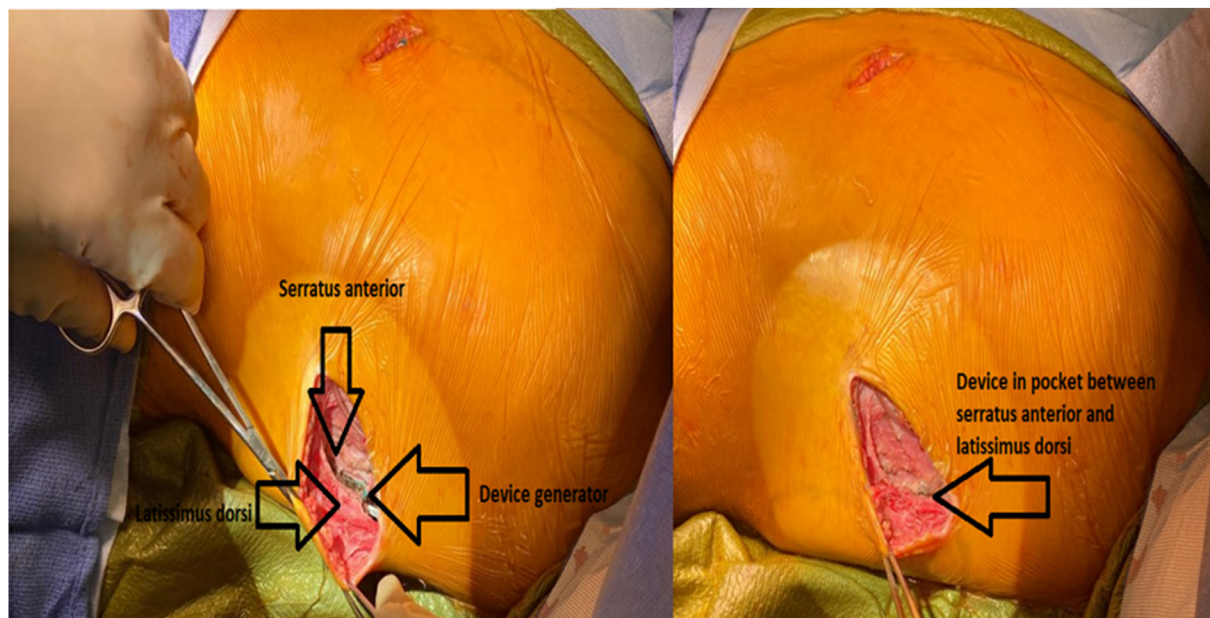


Fig. 2. Subcutaneous ICD in 8-year old demonstrating layers of muscles and device behind latissimus doris prior to incision closure.

4. Discussion

This study demonstrates the largest cohort of pediatric only patients with the intermuscular incision technique for subcutaneous

ICD implantation. Our study results demonstrate safety of this technique with only one complication noted, in a patient who tore his incisional support strips off. Our complication rate of 9% appears to be lower than previous studies. Complications reported in prior

Table 1 Patient characteristics, device implant specifications and follow up data of the cohort.

Patient ID	#1	#2	#3	#4	#5	#6	#7	#8	#9	#10	#11	#12
Age (years)	14	17	10	16	16	15	12	12	14	12	14	8
Sex	Male	Male	Female	Male	Female	Male	Male	Male	Male	Male	Female	Male
Weight (kg)	59	59.1	29	64	64	73.9	35.2	48.6	75.1	34.1	52.5	30
Height (cm)	178	165	130	180	167	178	142	163	164	147	177	139
BMI (kg/meter <sup>2</sup> )	18.6	21.7	17.2	19.8	22.9	23.3	17.5	18.3	27.9	15.8	16.8	15.5
Diagnosis	HCM, SCA	Brugada, SCA	HCM, ALKP3, QTc 500 ms	HCM, SCA	MMVP, VT	HCM, Family SCA	10q22.3 deletion, SCA	HCM, SCA	HCM, MYH7, TNNT2, father-SCA	HCM,MYH7, 30 mm septum	SCA, Long QT 8	SCA, Long QT 8
Primary [1] or Secondary [2] prevention	2	2	1	2	2	1	2	2	1	1		
Follow-up (months)	27	14	12	22	22	25	11	11	10	2	2	2
Screened-in vectors laying, sitting and standing [1–3]^	All	All*	1	1.2	1.2	All	1.2	All	All	All	8	3
Lead position to sternum	Left	Right	Right	Left	Left	Left	Right	Right	Left	Right	2,3	All
65 J shock impedance	53	62	55	53	70	48	65	50	68	59	68	59
10 J shock impedance	N/A	N/A	55	N/A	N/A	N/A	57	55	70	66	72	55
Time to shock during DFT (s)	11	12	15	14	14	15	14	15	16	12	14	12
Sensing vector [1–3]	1	1	1	2	2	2	1	1	3	2	1	2
Discriminating VT zone (bpm)	220	250	220	220	220	230	230	230	230	220	230	230
Ventricular fibrillation zone (bpm)	250	250	250	250	250	250	250	250	250	250	250	250
Complications	none	none	none	none	none	None	Wound dehiscence	none	none	none	none	none
Inappropriate shock	none	none	none	none	none	none	none	none	none	none	None	None
Appropriate shock/charge	none	none	none	none	Yes	none	none	none	none	none	none	none

^1 = primary vector, 2 = secondary vector, 3 = alternate vector, \*screen including procainamide challenge, ALKP3 = alpha kinase 3, HCM = hypertrophic cardiomyopathy, MMVP = Malignant mitral valve prolapse, MYH7 = myosin heavy chain mutation, SCA = sudden cardiac arrest, TNNT2 = Titan mutation [2].

studies included device removal in up to 30% of patients (three in a 10 pediatric patient study-15 total patients but 3 of the pediatric patients had removal), but most of which occurred within the first 1–2 months after implant [4]. Inappropriate shock rates have been demonstrated as high as 25% in the pediatric population [1]. Our small cohort does demonstrate that within our follow-up period, there are no erosions of the device, wound infections, or device removal except at cardiac transplant. No patients had inappropriate shocks during the follow-up period. This is the only technique practiced at our institution due to the first author's experience during training including 15 prior device implantations with various techniques (including subcutaneous and intermuscular) in mainly adult patients of different body sizes, and positive outcomes with the intermuscular technique. Prior centers which have used the subcutaneous and subfascial techniques in pediatric patients and young adults, have demonstrated an erosion rate of 20% with overall complication rate of 27% not including inappropriate shock rate ranging from 7 to 25% [3,4,6]. The erosion rate of 20% was also in a study with smallest patient weight of 38 kg (median 60 kg). Thus, we feel, comparatively, and with similar follow-up duration, the intermuscular two-incision technique has demonstrated improved comparative outcomes in our small cohort of patients thus far.

In our cohort of pediatric patients, the intermuscular, two-incision technique is safe, gives low impedance values during testing, and delivers appropriate therapy. This technique has also been described in a cohort of three pediatric patients and an isolated case report previously with patient weights as low as 19–20 kg [6,7].

This is the first study in pediatric patients to demonstrate the impedance comparisons between the 10-J test shock and 65-J defibrillation threshold testing. We provide this information in five patients with a positive Spearman correlation coefficient of 0.87. To our knowledge, this is the first study to demonstrate a correlation between these impedance values, however, further data is needed to validate that the impedance values are similar enough and with adequate sensing, could possibly be enough to eliminate a defibrillation threshold test on these patients. A future, large cohort, investigation in this regard would be necessary prior to changing any clinical practice.

We found right-sided parasternal lead placement useful in one patient who only screened in via the primary vector, however, during implant had improved sensing (no under-sensing) when the right parasternal location was chosen over the left parasternal location. We also chose this position based on right parasternal screening in other patients, including a patient with Brugada syndrome and a patient with very high left-sided voltages. Right parasternal screening was recently described in adult patients undergoing subcutaneous ICD screening [8].

Clinical implications of our study include that if reproduced on a larger scale, include demonstrating safety of the subcutaneous ICD implantation for children with rare complications. Thus, if safety is improved, venous patency of numerous pediatric patients may be preserved for only if bradycardia-related-pacing or anti-tachycardia

pacing are needed. And in that regard leadless pacing may prove to fill that role one day, however, more studies with larger sample sizes will need to be published before clinical practice can safely be changes.

Limitations of the study include the small cohort of patients. Furthermore, although the first author's prior experience noted improved outcomes with this technique, another limitation includes the lack of 1 to 1 direct comparison of techniques by the same operator/institution in this age group.

## 5. Conclusion

In our cohort of 12 pediatric patients with subcutaneous ICD placements via the intermuscular, two-incision technique, we had only one minor complication, which is less than reported in previous equally small pediatric cohorts.

## Author contributions

DC was responsible for the concept/design, data analysis/interpretation, and article draft. JL, GH, KE, BD, NR, EB and RA were responsible for the concept/design. NR, GH, RA and JL were responsible for critical revision and all authors were responsible for approval of article.

## Declaration of competing interest

The authors declare that they have no known competing financial interests or personal relationships that could have appeared to influence the work reported in this paper.

## References

- [1] Jarman JW, Lascelles K, Wong T, et al. Clinical experience of entirely subcutaneous implantable cardioverter-defibrillators in children and adults: a cause for caution. *Eur Heart J* 2012;33:1351–9.
- [2] Pettit SJ, McLean A, Colquhoun I, et al. Clinical experience of the subcutaneous and transvenous implantable cardioverter defibrillators in children and teenagers. *Pacing Clin Electrophysiol* 2013;36:1532–8.
- [3] Griksaits MJ, Rosengarten JA, Gnanapragasam JP, et al. Implantable cardioverter defibrillator therapy in paediatric practice: a single-centre UK experience with focus on subcutaneous defibrillation. *Europace* 2013;15:523–30.
- [4] Silvetti MS, Pazzano V, Verticelli L, et al. Subcutaneous implantable cardioverter-defibrillator: is it ready for use in children and young adults? A single-centre study. *Europace* 2018;20:1966–73.
- [5] Knops RE, Olde Nordkamp LR, de Groot JR, et al. Two-incision technique for implantation of the subcutaneous implantable cardioverter-defibrillator. *Heart Rhythm* 2013;10:1240.
- [6] Ferreiro-Marzal A, Rodriguez-Serrano F, Esteban-Molina M, et al. Intermuscular S-ICD implantation in pediatric patients. *Thorac Cardiovasc Surg* 2020;68: 068-071.
- [7] von Alvensleben JC, White C, Brateng C, et al. Subcutaneous implantable cardioverter defibrillator in a 5-year-old patient: modifications for the smallest patient. *Heart Rhythm Case Rep* 2019;5:440–4.
- [8] Arias MA, Pachon M, Sanchez-Iglesias I, et al. Impact of routine right parasternal electrocardiographic screening in assessing eligibility for subcutaneous implantable cardioverter-defibrillator. *J Cardiovasc Electrophysiol* 2020;31: 103–11.