

UCSF

UC San Francisco Previously Published Works

Title

Schizophrenia as a mimic of behavioral variant frontotemporal dementia

Permalink

<https://escholarship.org/uc/item/5zr2t9sr>

Journal

Neurocase, 22(3)

ISSN

1355-4794

Authors

Kerssens, Cora J
Krudop, Welmoed A
Prins, Niels D
[et al.](#)

Publication Date

2016-05-03

DOI

10.1080/13554794.2016.1187178

Peer reviewed



Published in final edited form as:

Neurocase. 2016 June ; 22(3): 285–288. doi:10.1080/13554794.2016.1187178.

Schizophrenia as a mimic of behavioral variant frontotemporal dementia

Cora J. Kerssens^a, Welmoed A. Krudop^b, Niels D. Prins^c, Bart N. M. van Berckel^d, Annemieke Rozemuller^e, William W. Seeley^f, Philip Scheltens^b, Max L. Stek^a, and Yolande A. L. Pijnenburg^b

^aDepartment of Old Age Psychiatry, GGZ InGeest, Amsterdam, The Netherlands ^bAlzheimer Center and Department of Neurology, Neuroscience Campus Amsterdam, VU University Medical Center, Amsterdam, the Netherlands ^cAlzheimer Center, Neuroscience Campus Amsterdam, VU University Medical Center, Amsterdam, the Netherlands ^dDepartment of Nuclear medicine and PET Research, Neuroscience Campus Amsterdam, VU University Medical Center, Amsterdam, the Netherlands ^eDepartment of Neuropathology, Neuroscience Campus Amsterdam, VU University Medical Center, Amsterdam, the Netherlands ^fMemory and Aging Center, Departments of Neurology and Pathology, University of California, San Francisco, CA, USA

Abstract

Recently, the diagnostic criteria for the behavioral variant of frontotemporal dementia were revised. Although these criteria offer a relatively high sensitivity, their specificity is yet unknown. We describe a 54-year-old woman fulfilling criteria for both late-onset schizophrenia and probable behavioral variant frontotemporal dementia. Following an initial presentation with psychosis, she developed progressive apathy, compulsiveness, and executive dysfunction. Moreover, bilateral frontotemporal hypometabolism was seen on [¹⁸F]fludeoxyglucose-positron emission tomography. A post-mortem diagnosis of schizophrenia was established, given the clinical picture combined with the pathological exclusion of a neurodegenerative cause. Our case suggests that patients with other brain disorders may meet the current diagnostic criteria for probable frontotemporal dementia. Further clinicopathological validation of these criteria is needed to determine their exact specificity.

This is an Open Access article distributed under the terms of the Creative Commons Attribution-NonCommercial-NoDerivatives License (<http://creativecommons.org/licenses/by-nc-nd/4.0/>), which permits non-commercial re-use, distribution, and reproduction in any medium, provided the original work is properly cited, and is not altered, transformed, or built upon in any way.

CONTACT: Welmoed A. Krudop, w.krudop@vumc.nl.

Disclosure statement

Dr. Prins serves on the advisory board of Boehringer Ingelheim and Forum, and has provided consultancy services for Sanofi. He has been a speaker at symposia organised by Janssen and Novartis and receives research support from Alzheimer Nederland; Dr. Scheltens reports grants from GE Healthcare, grants from Merck, grants from Piramal Imaging, outside the submitted work; Dr. Pijnenburg reports grants from Dutch Brain Foundation, during the execution of the study; the other authors report no conflicts of interest. We report no other role of any funding source. The Dutch Brain Association had no role in the design of the study, in execution of the study, or in the publication of this article.

Keywords

Frontotemporal dementia; schizophrenia; FTDC criteria; imaging; neuropathology

Introduction

The behavioral variant of frontotemporal dementia (bvFTD) is a neurodegenerative disorder primarily affecting the frontal and/or temporal lobes (Mackenzie et al., 2009). The bvFTD syndrome is characterized by deterioration of social–emotional function, followed by progressive changes in behavior and personality and disorders of executive functioning, memory and language (Piguet, Hornberger, Mioshi, & Hodges, 2011).

The clinical diagnosis of bvFTD is based on consensus diagnostic criteria. The formerly used international diagnostic criteria by Neary et al. have recently been revised by the International bvFTD Criteria Consortium (FTDC) (Neary et al., 1998; Rascovsky et al., 2011). One of the considerations inciting this revision was the difficulty in the application of five obligatory core behavioral criteria, which were subject to multiple interpretations. Moreover, a variety of psychiatric disorders could easily be misdiagnosed as bvFTD, based on the presence of overlapping symptoms (Pose et al., 2013).

The FTDC introduced a level of certainty and a more flexible clinical rating system within the new diagnostic criteria. According to these criteria, *probable* bvFTD requires at least three out of six symptom clusters in the presence of both functional decline and characteristic neuroimaging abnormalities. A specific pattern of mainly frontotemporal atrophy can be found on structural magnetic resonance imaging (MRI) (Piguet et al., 2011). [¹⁸F]fludeoxyglucose (FDG)-positron emission tomography ([¹⁸F]FDG-PET) has an added value over MRI alone in identifying disease-specific neuronal correlates in bvFTD (Schroeter et al., 2014). Although it has been confirmed that the new criteria offer a reasonable sensitivity of 76% for probable bvFTD, their specificity is still unknown. The distinction of bvFTD from psychiatric disorders is essential, especially since bvFTD is progressive and will eventually lead to death whereas most psychiatric disorders are potentially treatable.

In this case report, we describe the diagnostic dilemma that may occur when bvFTD symptom clusters occur in late-onset psychiatric disorder and are accompanied by functional decline and neuroimaging abnormalities.

Case

A 54-year-old woman was admitted to a geriatric psychiatry hospital with newly developed psychotic symptoms, consisting of both delusions and auditory hallucinations. According to the patient, strangers entered her house to steal her letters and passing black cars were out to kidnap her. She also heard accusing male voices when she was alone in her house. Twenty years before, she had successfully received behavioral therapy for an anxiety disorder. Nine years prior to admission, she had had complaints of tiredness and lack of energy that had been interpreted as work-related stress. Although previously well functioning in her job as

an executive secretary, thereafter she never returned to her old level of functioning. Her somatic history revealed hypertension and cardiac arrhythmia with an implantable cardioverter defibrillator. Her brother had been diagnosed with schizophrenia and committed suicide at the age of 45 years. The family history was negative for dementia. Although she had always preferred an isolated lifestyle, she had two close friends. Her 15-year lasting relationship ended 5 years prior to presentation.

Apart from the psychotic features, psychiatric examination revealed a paucity of spontaneous speech without any apparent cognitive or motor symptoms.

She was diagnosed by the old-age psychiatrist with late-onset schizophrenia, meeting the Diagnostic and Statistical Manual of Mental Disorders (DSM)-IV criteria of (late-onset) schizophrenia (Diagnostic and Statistical Manual of Mental Disorders, 2000). The persecutory and reference delusions and hallucinations disappeared with 10 mg olanzapine daily within three months. The remaining lack of initiative and paucity of speech were considered so-called “negative” symptoms of schizophrenia. After discharge, however, the clinical picture deteriorated rapidly. She did not cook for herself, forgot her appointments with her therapist, and stayed in bed all day. Moreover, she developed strikingly compulsive behavior, consisting of a strong attachment to daily schedules and preoccupation with the same subjects. Additionally, she was not able to organize complex tasks, such as finances and household tasks. Because of this unexpected behavioral and cognitive decline, within three months, the patient was readmitted for further observation and neurological consultation.

Formal neurological examination revealed no abnormalities. On observation, she was rigid in her day program and fixated on her medication. She became very agitated when challenged to deviation. She had some awareness of her disease, but her disease-insight was reduced. Spatial orientation and memory were not disturbed. On the Frontal Assessment Battery, she scored 15 out of 18. Her Mini-Mental State Examination was 29 out of 30. A neuropsychological examination confirmed the executive dysfunction (reduced planning and flexibility, impulsivity) and demonstrated minor memory impairments, with decreased learning and information retention abilities.

Because of the striking apathy, compulsiveness, and executive dysfunction in the presence of functional decline over a relatively short time, a diagnosis of bvFTD was now considered. MRI of the brain was within normal limits, particularly lacking frontotemporal atrophy (Figure 1(a),(b)). Subsequently, [¹⁸F]FDG-PET was performed and showed bilateral frontal and anterior temporal hypometabolism on visual rating. A voxel-by-voxel analysis using a validated discrimination tool comparing the regions to a mask based on age- and gender-matched controls showed hypometabolism in frontal, temporal, and cingulate regions (Figure 1(c)) (Herholz et al., 2002). Analysis of the cerebrospinal fluid (CSF) showed slightly decreased amyloid-beta(1–42) levels (471 ng/L) in combination with a normal total tau level (59 ng/L) and a normal phosphorylated tau level (<16 ng/L). A decreased CSF amyloid-beta(1–42) level combined with increased total tau and phosphorylated tau levels fit an Alzheimer’s disease (AD) profile. However, the clinical relevance of an isolated decreased amyloid-beta(1–42) level is unclear, especially at an older age (Dubois et al.,

2014; Jansen et al., 2015; McKhann et al., 2011). In order to obtain more certainty, a ^{11}C -Pittsburgh compound B-PET scan was performed, which did not show any amyloid deposition. So even though a frontal variant of AD should be considered in behavioral changes at an older age, this seemed not to be the case in this patient (Ossenkoppele et al., 2015). Based on these findings, a diagnosis of probable bvFTD was deemed plausible, although some diagnostic doubt remained since she kept some awareness of her illness and was remarkably empathic towards personnel and other patients. Because of serious self-neglect, the patient was transferred to a long-stay ward. An attempt lowering the olanzapine dose did not yield any changes in negative symptoms, but led to increased compulsive behavior. This treatment was therefore maintained. Nearly 15 months later, the patient insisted on discharge to her home, which was permitted with intensive psychiatric and domestic support. There were no signs of psychosis. However, her compulsiveness and apathy remained. A few months later, she was found in her home in a confused state and examined at the emergency ward on the suspicion of dehydration and pneumonia. Shortly after admission on the internal medicine department, she suddenly died. Autopsy revealed a fatal thrombus in the pulmonary artery.

Autopsy of the brain was performed and the obtained material was examined independently by the authors Annemieke J. M. Rozemuller and William W. Seeley. Her brain weighed 1283 g, without macroscopic atrophy. There was mild arteriolosclerosis without micro-infarction. Nonspecific neurodegenerative changes, such as superficial spongiosis, gliosis, and neuronal loss, were absent. There was a mild amount of diffuse amyloid plaque in the neocortex, extending lightly into entorhinal cortex and CA1/subiculum. Tau-immunoreactive neurofibrillary pathology was mild and limited to locus ceruleus, entorhinal cortex, subiculum, cornu ammonis1, and amygdala, consistent with Braak Stage 2. Immunostains for transactive response DNA-binding protein-43, alpha-synuclein, and p62 were negative in cortex, basal ganglia, amygdala, substantia nigra, brain stem, pons, locus coeruleus, and cerebellum. A post-mortem diagnosis of frontotemporal lobar degeneration or another neurodegenerative disease was excluded. A diagnosis of schizophrenia was established, given the clinical picture combined with the pathological findings.

Discussion

We describe a case with autopsy verified schizophrenia that fulfilled diagnostic criteria for both late-onset schizophrenia and probable bvFTD. We demonstrate that not only symptom overlap with psychiatric disorders may be a pitfall in bvFTD diagnosis, both also that functional decline and abnormal functional neuroimaging findings may occur in psychiatric disorders, therefore questioning the specificity of the bvFTD diagnostic criteria.

In this case, psychotic symptoms prevailed initially, leading to a diagnosis of schizophrenia. The patient met the DSM-IV criteria for schizophrenia with delusions, hallucinations, and negative symptoms for a period longer than six months. Because compulsive behavior, apathy, and prominent executive dysfunction developed in addition to functional decline, and frontotemporal abnormalities were shown on [^{18}F]FDG-PET, her diagnosis changed to bvFTD according to the FTDC criteria. Because of a decreased CSF, amyloid-beta(1–42) level, a diagnosis of atypical AD was considered, but regarded unlikely and rejected based

on normal CSF tau and phosphorylated tau levels combined with a negative ^{11}C -Pittsburgh compound B-PET scan. Neuropathological examination showed no clinically relevant stage of AD-related pathology.

The differentiation between schizophrenia and bvFTD remains a main diagnostic dilemma: for both diagnoses, functional decline is required. Although not necessary for diagnosing late-onset schizophrenia, executive abnormalities are often seen upon neuropsychological examination (Rajji & Mulsant, 2008). Furthermore, frontotemporal abnormalities on both structural and functional neuroimaging are common in schizophrenia (Kanahara et al., 2013; Olabi, Ellison-Wright, Bullmore, & Lawrie, 2012). The overall prevalence of psychosis in bvFTD is about 10%, with relatively higher frequencies in subjects carrying a C9orf72 repeat expansion or progranulin mutation (Shinagawa et al., 2014). In this case, bvFTD could only be excluded by autopsy.

In the described case, some symptoms cast doubt on the diagnosis of schizophrenia during the course. In contrast to early-onset schizophrenia, the development of negative symptoms and functional decline are uncommon in late-onset schizophrenia, i.e., after the age of 45 years (Howard, Rabins, Seeman, & Jeste, 2000). Moreover, severe compulsiveness is uncommon in schizophrenia (Ongur & Goff, 2005). On the other hand, although the absence of empathy is not obligatory for a diagnosis of bvFTD, the relative preservation of empathy in this case is remarkable.

BvFTD symptoms such as apathy, disinhibition, and compulsive behavior are seen in other psychiatric disorders such as depression, mania, or obsessive-compulsive disorder, but usually do not occur simultaneously in contrast to bvFTD. Apparently, due to this symptom overlap, about 50% of bvFTD patients receive a psychiatric diagnosis initially (Woolley, Khan, Murthy, Miller, & Rankin, 2011). On the other hand, it is currently unknown which proportion of patients with an initial diagnosis of bvFTD turns out to have a psychiatric disorder.

In the FTDC consensus criteria, it is stated that the behavioral syndrome should not be better accounted for by a psychiatric condition (Rascovsky et al., 2011). This issue is difficult to resolve when the specificity of structural and/or functional neuroimaging appears to be insufficient. Prospective studies addressing this issue among subjects presenting with a late-onset frontal lobe syndrome will hopefully bring answers to this question (Krudop et al., 2014).

Acknowledgments

Funding

Dr. Prins reports other from Forum pharmaceuticals, other from Boehringer Ingelheim, from Sanofi, outside the submitted work; Dr. Scheltens reports grants from GE Healthcare, grants from Merck, grants from Piramal Imaging, outside the submitted work; Dr. Pijnenburg reports grants from Dutch Brain Foundation, during the execution of the study.

References

- Diagnostic and Statistical Manual of Mental Disorders. American Psychiatric Association. Diagnostic and statistical manual of mental disorders. 4. Washington, DC: American Psychiatric Association; 2000. text revision (DSM-IV-TR)
- Dubois B, Feldman HH, Jacova C, Hampel H, Molinuevo JL, Blennow K, ... Cummings JL. Advancing research diagnostic criteria for Alzheimer's disease: The IWG-2 criteria. *The Lancet Neurology*. 2014; 13:614–629. DOI: 10.1016/S1474-4422(14)70090-0 [PubMed: 24849862]
- Herholz K, Salmon E, Perani D, Baron JC, Holthoff V, Frölich L, ... Kalbe E. Discrimination between Alzheimer dementia and controls by automated analysis of multicenter FDG PET. *Neuroimage*. 2002; 17:302–316. DOI: 10.1006/nimg.2002.1208 [PubMed: 12482085]
- Howard R, Rabins PV, Seeman MV, Jeste DV. Late-onset schizophrenia and very-late-onset schizophrenia-like psychosis: An international consensus. The International Late-Onset Schizophrenia Group. *American Journal of Psychiatry*. 2000; 157:172–178. DOI: 10.1176/appi.ajp.157.2.172 [PubMed: 10671383]
- Jansen WJ, Ossenkoppele R, Knol DL, Tijms BM, Scheltens P, Verhey FRJ, ... Zetterberg H. Prevalence of cerebral amyloid pathology in persons without dementia: A meta-analysis. *JAMA*. 2015; 313:1924–1938. DOI: 10.1001/jama.2015.4668 [PubMed: 25988462]
- Kanahara N, Sekine Y, Haraguchi T, Uchida Y, Hashimoto K, Shimizu E, Iyo M. Orbitofrontal cortex abnormality and deficit schizophrenia. *Schizophrenia Research*. 2013; 143:246–252. DOI: 10.1016/j.schres.2012.11.015 [PubMed: 23228712]
- Krudop WA, Kerssens CJ, Dols A, Prins ND, Moller C, Schouws S, ... Pijnenburg YAL. Building a new paradigm for the early recognition of behavioral variant frontotemporal dementia: Late onset frontal lobe syndrome study. *The American Journal of Geriatric Psychiatry*. 2014; 22:735–740. [PubMed: 23806681]
- Mackenzie IRA, Neumann M, Bigio EH, Cairns NJ, Alafuzoff I, Kril J, ... Mann DMA. Nomenclature for neuropathologic subtypes of frontotemporal lobar degeneration: Consensus recommendations. *Acta Neuropathologica*. 2009; 117:15–18. DOI: 10.1007/s00401-008-0460-5 [PubMed: 19015862]
- McKhann GM, Knopman DS, Chertkow H, Hyman BT, Jack CR Jr, Kawas CH, ... Phelps CH. The diagnosis of dementia due to Alzheimer's disease: Recommendations from the National Institute on Aging-Alzheimer's Association workgroups on diagnostic guidelines for Alzheimer's disease. *Alzheimer's & Dementia*. 2011; 7:263–269. DOI: 10.1016/j.jalz.2011.03.005
- Neary D, Snowden JS, Gustafson L, Passant U, Stuss D, Black S, ... Benson DF. Frontotemporal lobar degeneration: A consensus on clinical diagnostic criteria. *Neurology*. 1998; 51:1546–1554. DOI: 10.1212/WNL.51.6.1546 [PubMed: 9855500]
- Olabi B, Ellison-Wright I, Bullmore E, Lawrie SM. Structural brain changes in first episode schizophrenia compared with frontotemporal lobar degeneration: A meta-analysis. *BMC Psychiatry*. 2012; 12:104.doi: 10.1186/1471-244X-12-104 [PubMed: 22870896]
- Ongur D, Goff DC. Obsessive-compulsive symptoms in schizophrenia: Associated clinical features, cognitive function and medication status. *Schizophrenia Research*. 2005; 75:349–362. DOI: 10.1016/j.schres.2004.08.012 [PubMed: 15885526]
- Ossenkoppele R, Pijnenburg YAL, Perry DC, Cohn-Sheehy BI, Scheltens NME, Vogel JW, ... Rabinovici GD. The behavioural/dysexecutive variant of Alzheimer's disease: Clinical, neuroimaging and pathological features. *Brain*. 2015; 138:2732–2749. DOI: 10.1093/brain/awv191 [PubMed: 26141491]
- Piguet O, Hornberger M, Mioshi E, Hodges JR. Behavioural-variant frontotemporal dementia: Diagnosis, clinical staging, and management. *The Lancet Neurology*. 2011; 10:162–172. DOI: 10.1016/S1474-4422(10)70299-4 [PubMed: 21147039]
- Pose M, Cetkovich M, Gleichgerrcht E, Ibanez A, Torralva T, Manes F. The overlap of symptomatic dimensions between frontotemporal dementia and several psychiatric disorders that appear in late adulthood. *International Review of Psychiatry*. 2013; 25:159–167. DOI: 10.3109/09540261.2013.769939 [PubMed: 23611346]

- Rajji TK, Mulsant BH. Nature and course of cognitive function in late-life schizophrenia: A systematic review. *Schizophrenia Research*. 2008; 102:122–140. DOI: 10.1016/j.schres.2008.03.015 [PubMed: 18468868]
- Rascovsky K, Hodges JR, Knopman D, Mendez MF, Kramer JH, Neuhaus J, ... Miller BL. Sensitivity of revised diagnostic criteria for the behavioural variant of frontotemporal dementia. *Brain*. 2011; 134:2456–2477. DOI: 10.1093/brain/awr179 [PubMed: 21810890]
- Schroeter ML, Laird AR, Chwiesko C, Deuschl C, Schneider E, Bzdok D, ... Neumann J. Conceptualizing neuropsychiatric diseases with multimodal data-driven meta-analyses – The case of behavioral variant frontotemporal dementia. *Cortex*. 2014; 57:22–37. DOI: 10.1016/j.cortex.2014.02.022 [PubMed: 24763126]
- Shinagawa S, Nakajima S, Plitman E, Graff-Guerrero A, Mimura M, Nakayama K, Miller BL. Psychosis in frontotemporal dementia. *Journal of Alzheimer's Disease*. 2014; 42:485–499.
- Woolley JD, Khan BK, Murthy NK, Miller BL, Rankin KP. The diagnostic challenge of psychiatric symptoms in neurodegenerative disease: Rates of and risk factors for prior psychiatric diagnosis in patients with early neurodegenerative disease. *The Journal of Clinical Psychiatry*. 2011; 72:126–133. DOI: 10.4088/JCP.10m06382oli [PubMed: 21382304]

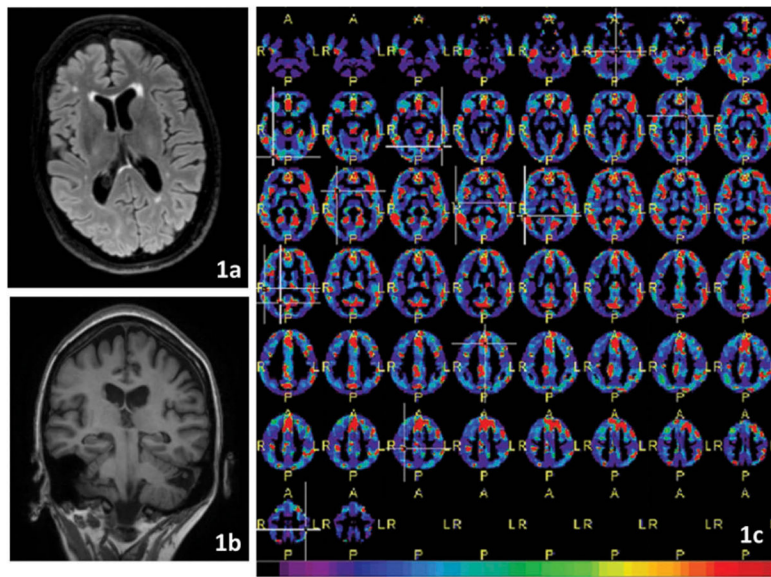


Figure 1.

(a) Structural axial MRI (fluid-attenuated inversion recovery (FLAIR)): Atrophy is within the normal age range. Some white matter hyperintensities in the frontal periventricular regions. (b) Structural coronal MRI (T1): Atrophy is within the normal age range. (c) Results of the $[^{18}\text{F}]\text{FDG}$ -PET images: A substantial amount of voxels in the frontal, temporal, and cingulate cortex were abnormal compared to a healthy reference group. Higher values (red areas) indicate more abnormal voxels and thus more profound metabolic impairment. A: anterior, P: posterior, L: left, and R: right. [To view this figure in color, please see the online version of this journal.]