

UCLA

UCLA Previously Published Works

Title

Changes in Coronary Plaque Volume: Comparison of Serial Measurements on Intravascular Ultrasound and Coronary Computed Tomographic Angiography

Permalink

<https://escholarship.org/uc/item/5zh1v4jq>

Journal

Texas Heart Institute Journal, 45(2)

ISSN

0730-2347

Authors

Nakanishi, Rine
Alani, Anas
Matsumoto, Suguru
et al.

Publication Date

2018-04-01

DOI

10.14503/thij-15-5212

Peer reviewed

Changes in Coronary Plaque Volume:

Comparison of Serial Measurements on Intravascular Ultrasound and Coronary Computed Tomographic Angiography

Rine Nakanishi, MD, PhD
Anas Alani, MD
Suguru Matsumoto, MD
Dong Li, MD, PhD
Michael Fahmy, BS
Jeby Abraham, BS
Christopher Dailing, BS
Alexander Broersen, PhD
Pieter H. Kitslaar, MSc
Khurram Nasir, MD
James K. Min, MD
Matthew J. Budoff, MD, FACC

Key words: Coronary angiography/methods; coronary vessels/diagnostic imaging; disease progression; image interpretation, computer-assisted; plaque, atherosclerotic/diagnostic imaging; predictive value of tests; prospective studies; time factors; tomography, x-ray computed/methods; ultrasonography, interventional/methods

From: Los Angeles Biomedical Research Institute at Harbor-UCLA Medical Center (Drs. Alani, Budoff, Li, Matsumoto, and Nakanishi, and Messrs. Abraham, Dailing, and Fahmy), Torrance, California 90502; Leiden University Medical Center (Dr. Broersen and Mr. Kitslaar), Leiden 2333 ZA, The Netherlands; Center for Prevention and Wellness Research (Dr. Nasir), Baptist Health Medical Group, Miami Beach, Florida 33143; Medis Medical Systems B.V. (Mr. Kitslaar), Leiden 2316 XG, The Netherlands; and Department of Radiology (Dr. Min), Weill Cornell Medical College and the New York Presbyterian Hospital, New York, New York 10021

Address for reprints: Matthew J. Budoff, MD, Los Angeles Biomedical Research Institute at Harbor-UCLA, Torrance, CA 90502

E-mail: mbudoff@labiomed.org

© 2018 by the Texas Heart[®] Institute, Houston

Serial measurements of coronary plaque volume have been used to evaluate drug efficacy in atherosclerotic progression. However, the usefulness of computed tomography for this purpose is unknown. We investigated whether the change in total plaque volume on coronary computed tomographic angiography is associated with the change in segmental plaque volume on intravascular ultrasound.

We prospectively enrolled 11 consecutive patients (mean age, 56.3 ± 5 yr; 6 men) who were to undergo serial invasive coronary angiographic examinations with use of grayscale intravascular ultrasound and coronary computed tomography, performed <180 days apart at baseline and from 1 to 2 years later. Subjects underwent 186 serial measurements of total plaque volume on coronary computed tomography and 22 of segmental plaque volume on intravascular ultrasound. We used semiautomated software to examine percentage relationships and changes between total plaque and segmental plaque volumes.

No significant correlations were found between percentages of total coronary and segment coronary plaque volume, nor between normalized coronary plaque volume. However, in the per-patient analysis, there were strong correlations between the imaging methods for changes in total coronary and segment coronary plaque volume ($r=0.62$; $P=0.04$), as well as normalized plaque volume ($r=0.82$; $P=0.002$).

Per-patient change in plaque volume on coronary computed tomography is significantly associated with that on intravascular ultrasound. Computed tomographic angiography may be safer and more widely available than intravascular ultrasound for evaluating atherosclerotic progression in coronary arteries. Larger studies are warranted. (Tex Heart Inst J 2018;45(2):84-91)

For decades, the serial measurement of coronary plaque volume with use of intravascular ultrasound (IVUS) has enabled drug efficacy in coronary atherosclerotic regression to be evaluated. Because it provides high-resolution views and validation of coronary plaque, numerous investigators have used IVUS to evaluate the efficacy of statins in inhibiting coronary plaque progression, changes in plaque composition, and stabilization of plaque vulnerability.¹⁻⁷ In addition, IVUS findings have characterized the natural history of coronary atherosclerosis in patients with acute coronary syndrome, in association with cardiac events.⁸ However, invasiveness, high cost, and associated morbidity make its routine use impractical, particularly in asymptomatic patients.

Coronary computed tomographic angiography (CCTA)—a robust, noninvasive means of evaluating the presence, extent, and severity of coronary artery disease (CAD)⁹—correlates well with IVUS in determining coronary plaque characteristics,¹⁰ stenosis severity,¹¹ and volume.¹²⁻¹⁵ The diagnostic capabilities of CCTA have been useful in defining the natural history of coronary plaque and its changes over time during drug therapy.¹⁶⁻¹⁹ However, in terms of investigating serial changes in coronary plaque, IVUS and CCTA have not been directly compared. We investigated

This study was funded, in part, by Merck Pharmaceuticals. Dr. Budoff is a consultant for GE Healthcare. Mr. Kitslaar is employed by Medis and has a research appointment at Leiden University Medical Center. Dr. Min serves as a consultant to AstraZeneca and HeartFlow, has served on the medical advisory boards of GE Healthcare, Arineta, AstraZeneca, and Bristol-Myers Squibb; is on the Speakers' Bureau of GE Healthcare; and received research support from GE Healthcare, Vital Images, and Philips Healthcare.

whether serial changes in total coronary plaque volume (TPV), measured by using CCTA, are associated with serial changes in segmental coronary plaque volume (SPV), measured by using IVUS.

Patients and Methods

We prospectively enrolled 11 consecutive patients (mean age, 56.3 ± 5 yr; 6 men) with known or suspected CAD. All underwent serial invasive coronary angiography at our institution from February 2006 through August 2013 via grayscale IVUS and noninvasive CCTA, at baseline and from 1 to 2 years later (mean durations, 705 ± 86 d for IVUS and 698 ± 106 d for CCTA; $P > 0.05$). Intravascular ultrasound and CCTA were performed within a mean of 31 ± 39 days. No patient underwent coronary intervention or had a clinical cardiovascular event (hospitalization for angina, myocardial infarction, or stroke) between the baseline and follow-up examinations. We excluded patients who had renal impairment (serum creatinine level, >1.4 mg/dL), history of coronary artery bypass grafting, or >180 days between CCTA and IVUS examinations. This study was approved by our Institutional Review Board, and all patients gave written informed consent.

All patients underwent invasive coronary angiography by means of IVUS on an iLab™ Ultrasound Imaging System (Boston Scientific Corporation). An automated pullback at 0.5 mm/s was performed on the target vessel. The same vessel was evaluated at baseline and follow-up. No patient had complications. Experienced readers studied the target vessels for the presence and volume of coronary plaque by using semiautomated QIvus® plaque-analysis software (Medis Medical Imaging Systems). The software automatically traced contours of the luminal and vessel walls inside the IVUS pullback stack. When necessary, we manually modified the lines by using cross-sectional images (Fig. 1).

We performed CCTA by using a 64-slice Lightspeed VCT scanner (GE Healthcare). Scanning values were typically 70% to 80% of the R-R interval for prospective electrocardiogram-triggering studies and 35% to 80% for retrospective studies; collimation, 64×0.625 mm; tube voltage, 100 to 120 kV; and tube current, 350 to 780 mA. To attain target heart rates of <60 beats/min before scanning, patients were given oral or intravenous β -blockers, and, immediately before the study, sublingual nitroglycerin or nitroglycerin spray (0.4–0.8 mg). Experienced readers used QAngioCT® Research Edition version 2.0.5 (Medis), a semiautomated plaque-analysis software program, to evaluate CCTAs for the presence and volume of coronary plaques. Detected plaques were assigned locations in accordance with a modified 18-segment American Heart Association coronary tree model.²⁰ The QAngioCT software automatically extracted centerlines, detected the inner

luminal and vessel wall contours from the ostium to the distal end of each artery, and produced straightened multiplanar reformatted images (Fig. 2). When necessary, we manually modified the contours. Window level and width were set at 740 and 220 Hounsfield units, respectively. Only segments ≥ 1.5 mm in diameter and of sufficient image quality were evaluated; those with stents or artifact were excluded.

Coronary Plaque Volume Calculations

At baseline and follow-up, TPV (measured by CCTA) and SPV (measured by IVUS) were derived as follows: vessel volume – luminal volume (mm^3). The percentages of TPV or SPV were then calculated as follows: $[(\text{TPV or SPV}/\text{total vessel volumes}) \times 100]$. Change in percentage was defined as the difference between baseline and follow-up values. Normalized plaque volume was calculated as follows: $[(\text{TPV or SPV}/\text{total or segmental length of coronary artery}) \times \text{mean total or segmental length of all studies}]$.¹⁹

Statistical Analysis

All analyses of CCTA variables were performed independently and with blinding to the IVUS measurements. A paired t test was used to compare variables from CCTA and IVUS at baseline and follow-up for normally distributed variables, and the Kruskal-Wallis test for nonparametrically distributed variables. Agreement between 2 observers in plaque measurements by CCTA and IVUS was evaluated with use of an intraclass correlation coefficient. The Pearson correlation coefficient was calculated to evaluate plaque volume and serial changes between IVUS and CCTA. P values <0.05 were considered statistically significant. Statistical analyses were performed with use of SAS version 9.3 (SAS Institute Inc.).

Results

Table I shows the baseline characteristics of the study population. All patients were taking antihypertensive medications, most took statins, and nearly half took medication for diabetes mellitus.

Table II shows the variables measured on CCTA and IVUS at baseline and follow-up. There were no differences in total vessel, luminal, or plaque volumes. On CCTA, the changes in TPV percentage ($0.7\% \pm 6.2\%$ [median, 0.4%]) and normalized plaque volume ($-4.4 \pm 26.7 \text{ mm}^3$ [median, 3.7 mm^3]) were relatively small. Similar minimal changes on IVUS were found: SPV percentage, $-0.2\% \pm 4.5\%$ (median, -0.3%); and normalized plaque volume, $0.1 \pm 6.2 \text{ mm}^3$ (median, 0.4 mm^3).

We evaluated 93 vascular segments on CCTA (total from baseline and follow-up, 186) and these 11 segments on IVUS (total, 22): left anterior descending

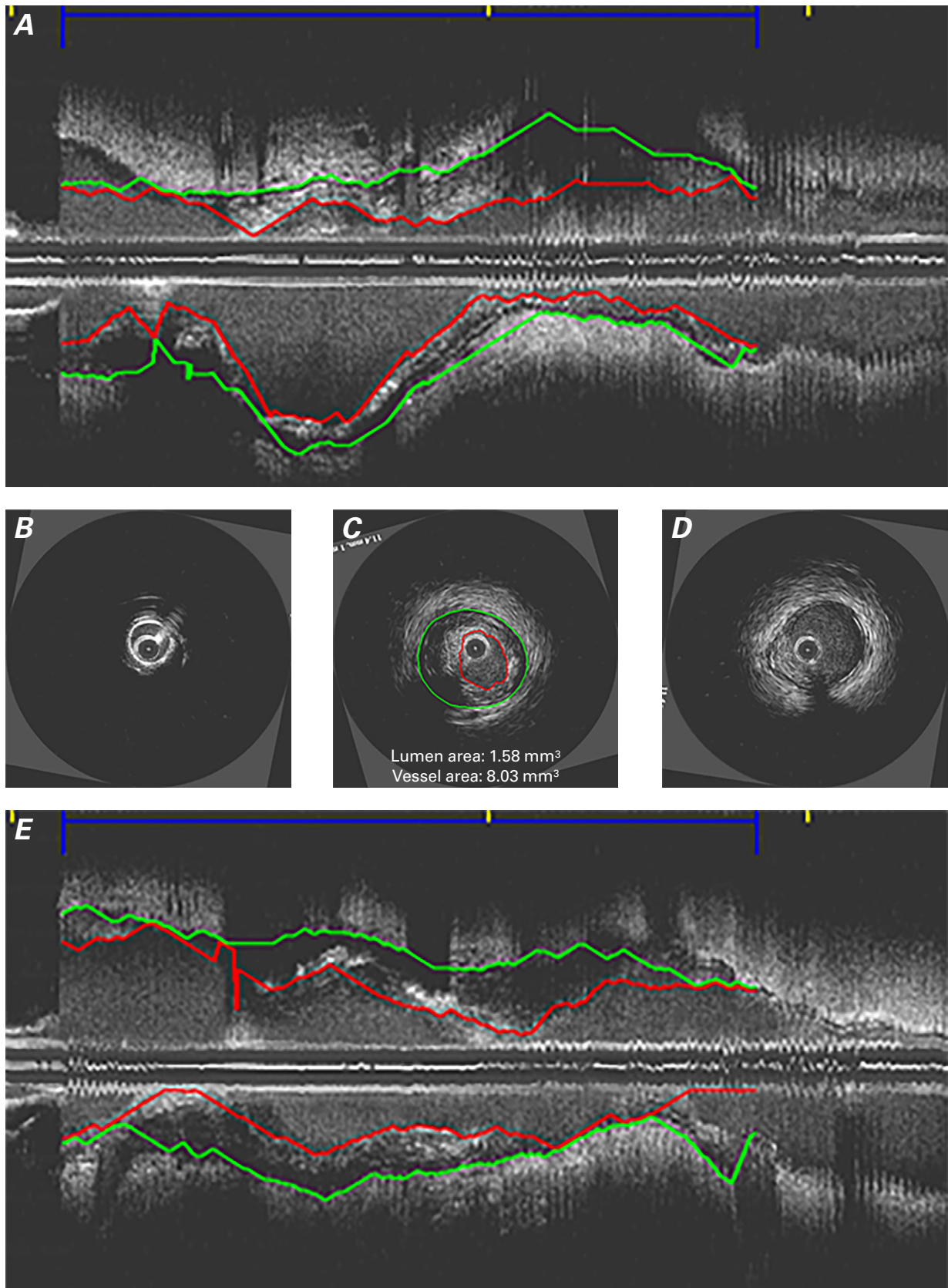


Fig. 1 We measured segment plaque volume (indicated by red lines) with use of intravascular ultrasound **A**) along the length of a left circumflex coronary artery and obtained cross-sectional views of the **B**) proximal, **C**) target, and **D**) distal segments. In **C**), the luminal area of plaque is 1.58 mm² (vessel area, 8.03 mm²). **E**) Longitudinal image shows the vessel at a 90° angle.

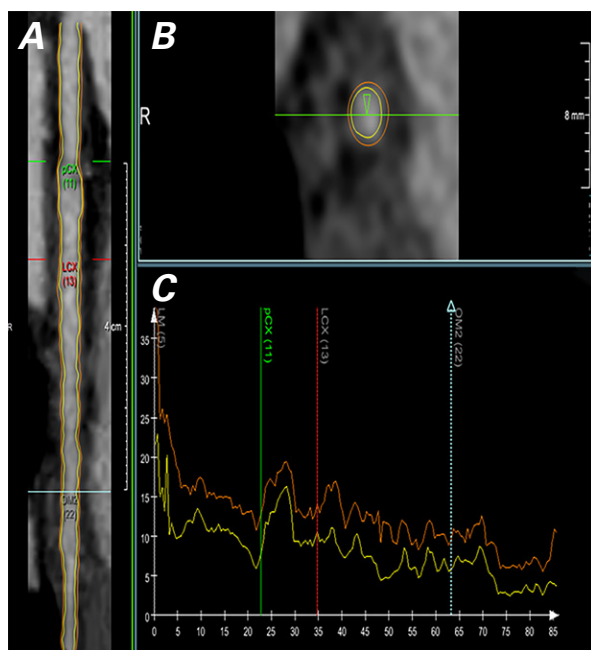


Fig. 2 Using coronary computed tomographic angiography, we summed individual segment plaque volumes in all available vessels to obtain total plaque volumes for each scan. Images show the left circumflex coronary artery (LCx) from the left main coronary artery to the 2nd obtuse marginal branch (OM2) in **A**) longitudinal and **B**) cross-sectional views. **C**) Tracings show vessel and luminal areas.

pCx = proximal left circumflex coronary artery

coronary artery, 3 segments; left circumflex coronary artery, 4; right coronary artery, 3; and ramus intermedius branch, 1. Overall, no significant correlations existed between TPV on CCTA and SPV on IVUS ($r=0.16$; $P=0.47$) (Fig. 3A). When we compared coronary plaque volume by using normalized plaque volume, we found no significant relationship between CCTA and IVUS ($r=0.21$; $P=0.34$) (Fig. 3B). On per-patient analysis, performed to determine whether total plaque change on CCTA was associated with segmental plaque change on IVUS, we found strongly correlated serial changes between TPV-percentage change on CCTA and SPV-percentage change for IVUS ($r=0.62$; $P=0.04$) (Fig. 4A). An even stronger correlation existed between the changes in normalized coronary plaque volume ($r=0.82$; $P=0.002$) (Fig. 4B).

As was previously reported²¹ in regard to interobserver variability of measurements when using CCTA, we too observed moderate correlations in TPV measurement between 2 observers (correlation coefficient, 0.94; 95% CI, 0.80–0.98). When we examined interobserver variability for coronary artery plaque measurements on IVUS among 5 randomly selected cases (10 vessels) in blinded fashion, we observed a moderate variability for SPV (correlation coefficient, 0.52; 95% CI, –0.12 to 0.86).

TABLE I. Baseline Characteristics in 11 Patients

Variable	Value
Clinical characteristics	
Age (yr)	56.3 ± 5
Male	6 (54.5)
Body mass index (kg/m ²)	30.9 ± 7.3
Systolic BP (mmHg)	135.2 ± 16.9
Diastolic BP (mmHg)	80.8 ± 8.8
Heart rate (beats/min)	66 ± 15
HDL cholesterol (mg/dL)	42 ± 6.3
LDL cholesterol (mg/dL)	73.4 ± 18.6
Triglycerides (mg/dL)	135.3 ± 27.8
Diabetes mellitus	5 (45.5)
Hypertension	11 (100)
Prior coronary intervention	5 (45.5)
Drugs	
ACE inhibitor	8 (72.7)
ARB	2 (18.2)
β-blocker	11 (100)
Calcium channel blocker	2 (18.2)
Statins	9 (81.8)
Diabetes medication	5 (45.5)
Nitroglycerin	8 (72.7)

ACE = angiotensin-converting enzyme; ARB = angiotensin-II receptor blocker; BP = blood pressure; HDL = high-density-lipoprotein; LDL = low-density-lipoprotein

Data are presented as mean ± SD or as number and percentage.

Discussion

To our knowledge, this is the first direct comparison of CCTA and IVUS measurements of plaque changes over time. We could not use IVUS to measure total plaque burden, so we compared SPV to TPV on CCTA and found only modest correlations. However, we found significant correlation between SPV and TPV.

Papadopoulou and colleagues¹⁹ reported the potential usefulness of CCTA in evaluating the natural history of coronary atherosclerosis. They measured TPV and changes in plaque over 39 months in 32 patients with acute coronary syndromes who had undergone coronary intervention. Ito and associates²² also studied coronary plaque progression in 148 patients, using serial CCTA (median scan interval, 12 mo). However, neither group directly compared CCTA and IVUS findings.

The results of our study strengthen those of Papadopoulou's group¹⁹ and also indicate that TPV change on CCTA is associated with SPV change on IVUS. Coronary artery disease is systemic, so partial plaque change may be associated with systemic atherosclerotic change.

TABLE II. Findings on CCTA and IVUS at Baseline and Follow-Up in 11 Patients

Variable	Baseline	Follow-Up	P Value	Change
CCTA volumetric findings				
Total vessel (mm ³)	3,341.8 ± 1,952.4 (3,342)	3,373.5 ± 1,780.9 (3,083.7)	0.81	—
Total lumen (mm ³)	2,159.1 ± 1,359.3 (2,355.1)	2,123 ± 1,215.6 (2,013.7)	0.97	—
Total plaque (mm ³)	1,175 ± 624.8 (1,000.9)	1,250.5 ± 626.6 (1,393.1)	0.71	—
Plaque (%)	36.5 ± 4.6 (37)	37.2 ± 6.6 (34.6)	0.97	0.7 ± 6.2 (0.4)
Normalized plaque (mm ³)	48.4 ± 40.9 (32.8)	46.3 ± 31.2 (34.2)	0.92	-4.4 ± 26.7 (3.7)
IVUS volumetric findings				
Segmental vessel (mm ³)	867.1 ± 359.2 (798.2)	764.5 ± 251.6 (726)	0.53	—
Segmental lumen (mm ³)	579.9 ± 273.1 (480.9)	517.5 ± 193.9 (456.7)	0.58	—
Segmental plaque (mm ³)	287.2 ± 127.2 (317.7)	246.9 ± 122.1 (203.4)	0.41	—
Plaque (%)	32.1 ± 11.4 (30.8)	32 ± 11.3 (28.6)	0.76	-0.2 ± 4.5 (-0.3)
Normalized plaque (mm ³)	33.1 ± 11.6 (35.1)	33.1 ± 10.9 (28.1)	0.87	0.1 ± 6.2 (0.4)

CCTA = coronary computed tomographic angiography; IVUS = intravascular ultrasound

Data are presented as mean ± SD and median. *P* < 0.05 was considered statistically significant.

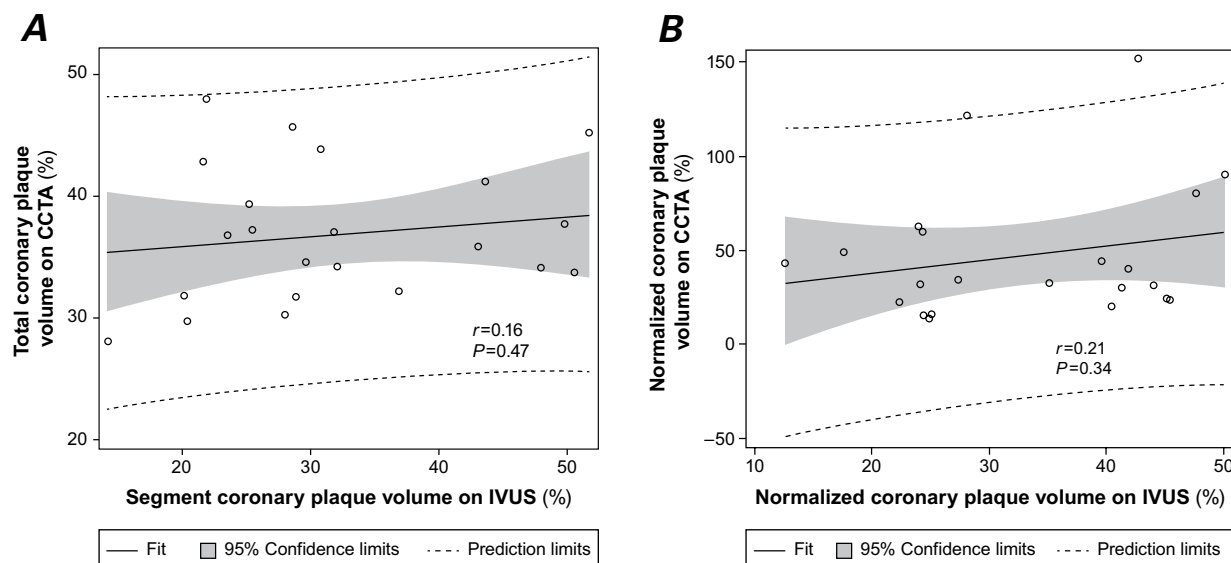


Fig. 3 Scatter plots show no significant correlation between **A**) percentages of total coronary plaque volume on CCTA and segment coronary plaque volume on IVUS, nor between **B**) normalized coronary plaque volume on CCTA and IVUS. *P* < 0.05 was considered statistically significant.

CCTA = coronary computed tomographic angiography; IVUS = intravascular ultrasound

Although our patient numbers are small, our findings support this concept. Because CCTA has lower image resolution than IVUS, one might overestimate plaque volume on CCTA. In particular, calcified plaque from blooming artifact can cause small, insignificant differences between CCTA and IVUS findings.^{13,14} Despite this, distortion of image quality is similar across serial scans. Advantageously, CCTA can produce 3-dimensional coronary artery models, and change in total coronary plaque is more practical than change in SPV for evaluating atherosclerotic progression.

Therefore, we also evaluated normalized plaque volume and changes.^{19,23} We calculated volume percentage by dividing all measured plaque volume by the total measured vessel volume per patient. This might cause errors in calculations, even when the same patients are evaluated at baseline and follow-up. On CCTA images, vessel volume—in particular, luminal volume—can be affected by image quality because of the timing or dosing of nitroglycerin or contrast agents. Because the change in plaque volume over time was relatively small during our observation period, this error potentially af-

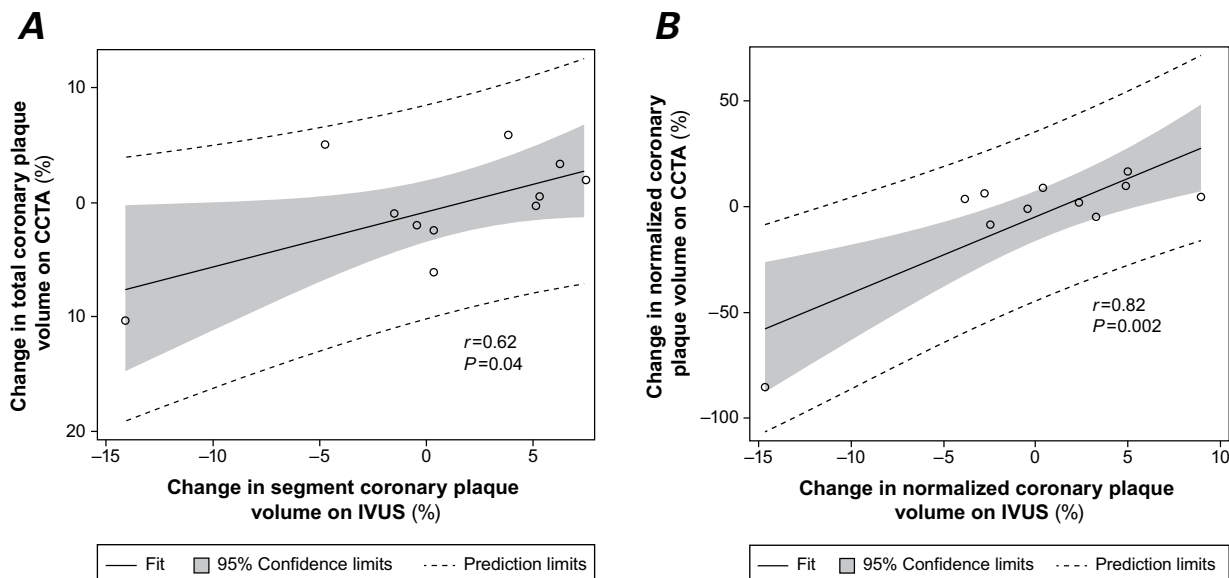


Fig. 4 Scatter plots of per-patient analysis ($n=11$) show strong correlations between **A**) percentages of total coronary plaque volume on CCTA and segment coronary plaque volume on IVUS and between **B**) normalized coronary plaque volume on CCTA and IVUS. $P < 0.05$ was considered statistically significant.

CCTA = coronary computed tomographic angiography; IVUS = intravascular ultrasound

fects the results of our serial CCTA study. Moreover, during serial measurements, total coronary segment length as evaluated by CCTA or IVUS is important when determining TPV.²³ In this regard, normalized plaque volume, which was calculated not by vessel volume but by the mean length for all studies, may be more reliable in evaluating plaque changes in serial CCTA study. This underlying mechanism may explain why the change in normalized plaque volume on CCTA was more strongly associated than that on IVUS in the current study.

Determination of plaque progression might help when selecting patients who would benefit from additional medical intervention or modification of risk factors, or in stratifying further risk.^{22,24-26}

Study Limitations

This was a single-center study. The small sample (11 patients) might have affected some results, such as interobserver variability of plaque volume on IVUS. The plaque changes measured on CCTA and IVUS over time were relatively small, and the difference in plaque change between these modes might be greater in a larger cohort.

Serial CCTA exposes patients to additional radiation; however, newer CCTA technology enables lower radiation exposure and acceptable image quality.²⁷ Moreover, current high-pitch CCTA models might emit radiation doses within <1 mSv for CCTA,²⁸ considerably below the 5-mSv level needed for invasive angiography.²⁹

During investigation of serial changes in plaque volume by examining calcified or noncalcified plaque

(including low-attenuation plaque), fibrous or fibrous-fatty plaques are clinically important. Specifically, non-calcified plaque is associated with faster progression of CAD than is calcified plaque,¹⁶ and its prevalence might influence the occurrence of future cardiovascular events.³⁰ We did not examine plaque characteristics on virtual-histology IVUS, so we could not examine the relationship of plaque-type progression between CCTA and IVUS. Advanced CCTA software can now identify plaque characteristics equally as well as can IVUS³¹ or histology,³² so future studies are warranted to evaluate the correlation of serial change of each plaque characteristic's volume between CCTA and IVUS.

Conclusion

We found a strong, significant correlation of plaque changes between CCTA and IVUS. This suggests that using CCTA—a less invasive imaging method than IVUS—is advantageous in evaluating atherosclerotic progression in patients with CAD; however, larger studies are warranted for validation.

Acknowledgments

We thank Sajad Hamal and Ferdinand R. Flores for contributing to this study.

References

1. Nissen SE, Nicholls SJ, Sipahi I, Libby P, Raichlen JS, Ballantyne CM, et al. Effect of very high-intensity statin therapy on

- regression of coronary atherosclerosis: the ASTEROID trial. *JAMA* 2006;295(13):1556-65.
2. Schoenhagen P, Tuzcu EM, Apperson-Hansen C, Wang C, Wolski K, Lin S, et al. Determinants of arterial wall remodeling during lipid-lowering therapy: serial intravascular ultrasound observations from the Reversal of Atherosclerosis with Aggressive Lipid Lowering Therapy (REVERSAL) trial. *Circulation* 2006;113(24):2826-34.
 3. Hiro T, Kimura T, Morimoto T, Miyauchi K, Nakagawa Y, Yamagishi M, et al. Effect of intensive statin therapy on regression of coronary atherosclerosis in patients with acute coronary syndrome: a multicenter randomized trial evaluated by volumetric intravascular ultrasound using pitavastatin versus atorvastatin (JAPAN-ACS [Japan assessment of pitavastatin and atorvastatin in acute coronary syndrome] study). *J Am Coll Cardiol* 2009;54(4):293-302.
 4. Takayama T, Hiro T, Yamagishi M, Daida H, Hirayama A, Saito S, et al. Effect of rosuvastatin on coronary atheroma in stable coronary artery disease: multicenter coronary atherosclerosis study measuring effects of rosuvastatin using intravascular ultrasound in Japanese subjects (COSMOS). *Circ J* 2009;73(11):2110-7.
 5. Nasu K, Tsuchikane E, Katoh O, Tanaka N, Kimura M, Ehara M, et al. Effect of fluvastatin on progression of coronary atherosclerotic plaque evaluated by virtual histology intravascular ultrasound. *JACC Cardiovasc Interv* 2009;2(7):689-96.
 6. Okazaki S, Yokoyama T, Miyauchi K, Shimada K, Kurata T, Sato H, Daida H. Early statin treatment in patients with acute coronary syndrome: demonstration of the beneficial effect on atherosclerotic lesions by serial volumetric intravascular ultrasound analysis during half a year after coronary event: the ESTABLISH Study. *Circulation* 2004;110(9):1061-8.
 7. Puri R, Libby P, Nissen SE, Wolski K, Ballantyne CM, Barter PJ, et al. Long-term effects of maximally intensive statin therapy on changes in coronary atheroma composition: insights from SATURN. *Eur Heart J Cardiovasc Imaging* 2014;15(4):380-8.
 8. Stone GW, Maehara A, Lansky AJ, de Bruyne B, Cristea E, Mintz GS, et al. A prospective natural-history study of coronary atherosclerosis. *N Engl J Med* 2011;364(3):226-35.
 9. Budoff MJ, Dowe D, Jollis JG, Gitter M, Sutherland J, Halamert E, et al. Diagnostic performance of 64-multidetector row coronary computed tomographic angiography for evaluation of coronary artery stenosis in individuals without known coronary artery disease: results from the prospective multicenter ACCURACY (Assessment by Coronary Computed Tomographic Angiography of Individuals Undergoing Invasive Coronary Angiography) trial. *J Am Coll Cardiol* 2008;52(21):1724-32.
 10. Leber AW, Knez A, Becker A, Becker C, von Ziegler F, Nikolaou K, et al. Accuracy of multidetector spiral computed tomography in identifying and differentiating the composition of coronary atherosclerotic plaques: a comparative study with intracoronary ultrasound. *J Am Coll Cardiol* 2004;43(7):1241-7.
 11. Leber AW, Knez A, von Ziegler F, Becker A, Nikolaou K, Paul S, et al. Quantification of obstructive and nonobstructive coronary lesions by 64-slice computed tomography: a comparative study with quantitative coronary angiography and intravascular ultrasound. *J Am Coll Cardiol* 2005;46(1):147-54.
 12. Leber AW, Becker A, Knez A, von Ziegler F, Sirol M, Nikolaou K, et al. Accuracy of 64-slice computed tomography to classify and quantify plaque volumes in the proximal coronary system: a comparative study using intravascular ultrasound. *J Am Coll Cardiol* 2006;47(3):672-7.
 13. Achenbach S, Moselewski F, Ropers D, Ferencik M, Hoffmann U, MacNeill B, et al. Detection of calcified and noncalcified coronary atherosclerotic plaque by contrast-enhanced, submillimeter multidetector spiral computed tomography: a segment-based comparison with intravascular ultrasound. *Circulation* 2004;109(1):14-7.
 14. Voros S, Rinehart S, Qian Z, Vazquez G, Anderson H, Murieta L, et al. Prospective validation of standardized, 3-dimensional, quantitative coronary computed tomographic plaque measurements using radiofrequency backscatter intravascular ultrasound as reference standard in intermediate coronary arterial lesions: results from the ATLANTA (assessment of tissue characteristics, lesion morphology, and hemodynamics by angiography with fractional flow reserve, intravascular ultrasound and virtual histology, and noninvasive computed tomography in atherosclerotic plaques) I study. *JACC Cardiovasc Interv* 2011;4(2):198-208.
 15. Voros S, Rinehart S, Qian Z, Joshi P, Vazquez G, Fischer C, et al. Coronary atherosclerosis imaging by coronary CT angiography: current status, correlation with intravascular interrogation and meta-analysis. *JACC Cardiovasc Imaging* 2011;4(5):537-48.
 16. Lehman SJ, Schlett CL, Bamberg F, Lee H, Donnelly P, Shturman L, et al. Assessment of coronary plaque progression in coronary computed tomography angiography using a semi-quantitative score. *JACC Cardiovasc Imaging* 2009;2(11):1262-70.
 17. Zeb I, Li D, Nasir K, Malpeso J, Batool A, Flores F, et al. Effect of statin treatment on coronary plaque progression - a serial coronary CT angiography study. *Atherosclerosis* 2013;231(2):198-204.
 18. Inoue K, Motoyama S, Sarai M, Sato T, Harigaya H, Hara T, et al. Serial coronary CT angiography-verified changes in plaque characteristics as an end point: evaluation of effect of statin intervention. *JACC Cardiovasc Imaging* 2010;3(7):691-8.
 19. Papadopoulou SL, Neefjes LA, Garcia-Garcia HM, Flu WJ, Rossi A, Dharampal AS, et al. Natural history of coronary atherosclerosis by multislice computed tomography. *JACC Cardiovasc Imaging* 2012;5(3 Suppl):S28-37.
 20. Raff GL, Abidov A, Achenbach S, Berman DS, Boxt LM, Budoff MJ, et al. SCCT guidelines for the interpretation and reporting of coronary computed tomographic angiography. *J Cardiovasc Comput Tomogr* 2009;3(2):122-36.
 21. Fahmy M, Nakanishi R, Matsumoto S, Alani A, Abraham J, Hamal S, et al. Inter-observer reproducibility in a novel semi-automated coronary plaque quantification software [abstract]. *J Cardiovasc Comput Tomogr* 2014(Suppl):S22.
 22. Ito H, Motoyama S, Sarai M, Kawai H, Harigaya H, Kan S, et al. Characteristics of plaque progression detected by serial coronary computed tomography angiography. *Heart Vessels* 2014;29(6):743-9.
 23. Mintz GS, Garcia-Garcia HM, Nicholls SJ, Weissman NJ, Bruining N, Crowe T, et al. Clinical expert consensus document on standards for acquisition, measurement and reporting of intravascular ultrasound regression/progression studies. *EuroIntervention* 2011;6(9):1123-30, 9.
 24. Nicholls SJ, Tuzcu EM, Wolski K, Bayturan O, Lavoie A, Uno K, et al. Lowering the triglyceride/high-density lipoprotein cholesterol ratio is associated with the beneficial impact of pioglitazone on progression of coronary atherosclerosis in diabetic patients: insights from the PERISCOPE (Pioglitazone Effect on Regression of Intravascular Sonographic Coronary Obstruction Prospective Evaluation) study. *J Am Coll Cardiol* 2011;57(2):153-9.
 25. Nicholls SJ, Hsu A, Wolski K, Hu B, Bayturan O, Lavoie A, et al. Intravascular ultrasound-derived measures of coronary atherosclerotic plaque burden and clinical outcome. *J Am Coll Cardiol* 2010;55(21):2399-407.

26. Nicholls SJ, Tuzcu EM, Kalidindi S, Wolski K, Moon KW, Sipahi I, et al. Effect of diabetes on progression of coronary atherosclerosis and arterial remodeling: a pooled analysis of 5 intravascular ultrasound trials. *J Am Coll Cardiol* 2008;52(4): 255-62.
27. Halliburton SS, Abbara S, Chen MY, Gentry R, Mahesh M, Raff GL, et al. SCCT guidelines on radiation dose and dose-optimization strategies in cardiovascular CT. *J Cardiovasc Comput Tomogr* 2011;5(4):198-224.
28. Achenbach S, Marwan M, Ropers D, Schepis T, Pflederer T, Anders K, et al. Coronary computed tomography angiography with a consistent dose below 1 mSv using prospectively electrocardiogram-triggered high-pitch spiral acquisition. *Eur Heart J* 2010;31(3):340-6.
29. Coles DR, Smail MA, Negus IS, Wilde P, Oberhoff M, Karsch KR, Baumbach A. Comparison of radiation doses from multislice computed tomography coronary angiography and conventional diagnostic angiography. *J Am Coll Cardiol* 2006;47(9):1840-5.
30. Motoyama S, Sarai M, Harigaya H, Anno H, Inoue K, Hara T, et al. Computed tomographic angiography characteristics of atherosclerotic plaques subsequently resulting in acute coronary syndrome. *J Am Coll Cardiol* 2009;54(1):49-57.
31. Dey D, Schepis T, Marwan M, Slomka PJ, Berman DS, Achenbach S. Automated three-dimensional quantification of noncalcified coronary plaque from coronary CT angiography: comparison with intravascular US. *Radiology* 2010;257(2): 516-22.
32. Schlett CL, Ferencik M, Celeng C, Maurovich-Horvat P, Scheffel H, Stolzmann P, et al. How to assess non-calcified plaque in CT angiography: delineation methods affect diagnostic accuracy of low-attenuation plaque by CT for lipid-core plaque in histology. *Eur Heart J Cardiovasc Imaging* 2013;14 (11):1099-105.