

# UC Irvine

## UC Irvine Previously Published Works

### Title

Improvement in pulmonary hypertension discrimination using multiple MRA pant-leg parameters of pulmonary artery

### Permalink

<https://escholarship.org/uc/item/5vq8v1r2>

### Journal

Journal of Cardiovascular Magnetic Resonance, 16(Suppl 1)

### ISSN

1548-7679

### Authors

Kilgas, Phillip  
Schrauben, Eric M  
Roldán-Alzate, Alejandro  
[et al.](#)

### Publication Date

2014

### DOI

10.1186/1532-429x-16-s1-o73

### Copyright Information

This work is made available under the terms of a Creative Commons Attribution License, available at <https://creativecommons.org/licenses/by/4.0/>

Peer reviewed

# Improvement in Pulmonary Hypertension Discrimination using Multiple MRA Pant-leg Parameters of Pulmonary Artery

P. Kilgas,<sup>1</sup> E. Schrauben,<sup>2</sup> A. Roldán-Alzate,<sup>1</sup> N.C. Chesler,<sup>3</sup> O. Wieben,<sup>2</sup> C.J. Francois,<sup>1</sup> M L Schiebler.<sup>1</sup>  
 UW-Madison Departments of Radiology<sup>1</sup> Medical Physics,<sup>2</sup> and Biomedical Engineering<sup>3</sup>, Madison Wisconsin

**PURPOSE:** Pulmonary arterial hypertension (PAH) is a potentially severe disease that can lead to exercise intolerance, systemic congestion, and heart failure. The extraction of vasculature anatomical changes from a high-resolution imaging method, such as MRA, may eliminate the need for invasive measurements. As a result of increased pulmonary pressures, dilation and expansion of the pulmonary artery vasculature often occurs [1]. Therefore, it is possible to non-invasively diagnose PAH through a high-resolution volumetric imaging method such as a magnetic resonance angiogram (MRA). The aim of this study was to explore the use of volumetric imaging of the pulmonary trunk and proximal right and left arteries using MRA as a new metric for diagnosing pulmonary arterial hypertension.

**METHODS:** Following IRB approval, eight PAH patients referred for right heart catheterization (RHC) for systemic sclerosis were evaluated with MRA. For comparison, 8 healthy volunteers underwent the same MRA protocol. In all patients with PAH, the diagnostic RHC for treatment purposes was completed within one week of the MRA. All MRA exams were performed on 3.0T clinical scanners (GE Healthcare, Waukesha, WI) following the venous administration of gadolinium-based contrast agents (gadobenate dimeglumine, *Bracco*, Milan). Approximate breath-hold time was 20 seconds for each three-dimensional (3D) scan, with acquisition time varying (15-21 seconds) based on the number of slices and patient size. Post-processing was evaluated using dynamic magnitude images in a commercial software (*Mimics*, *Materialise*, Belgium) to calculate diameter, volume, surface area, branch sum, and area sum pant-leg (P-L)

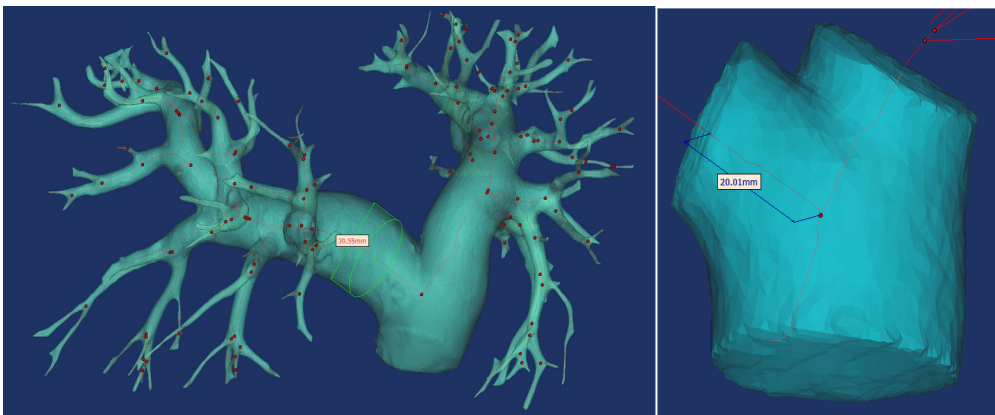
(main, left, and right pulmonary artery) measurements (Fig. 1a). Each P-L was obtained by user-defined measurements two centimeters in each direction of bifurcation (Fig. 1b). These parameters were evaluated as mean  $\pm$  standard deviation in units of millimeters (mm). Differences in these measurements were statistically analyzed using a paired Student t-test.

	PAH Patients	Normal Volunteers	P-Values
<b>MPA (mm)</b>	36.10 $\pm$ 3.66	30.15 $\pm$ 3.24	0.003951
<b>LPA (mm)</b>	27.45 $\pm$ 2.83	19.08 $\pm$ 2.81	0.000036
<b>RPA (mm)</b>	27.27 $\pm$ 2.74	19.73 $\pm$ 2.86	0.000097
<b>P-L Volume (mm<sup>3</sup>)</b>	44155.81 $\pm$ 12340.40	23978.23 $\pm$ 5009.86	0.001912
<b>P-L Surface Area (mm<sup>2</sup>)</b>	7336.98 $\pm$ 1260.08	5154.16 $\pm$ 764.20	0.001366
<b>Pant-leg Branch Sum (mm)</b>	54.72 $\pm$ 5.31	38.81 $\pm$ 5.57	0.000042
<b>Pant-leg Area Sum (mm<sup>2</sup>)</b>	1186.46 $\pm$ 234.13	602.61 $\pm$ 170.31	0.000055

**RESULTS:** Table 1 summarizes average ( $\pm$  standard deviation) diameter, volume, surface area, pant-leg branch sum, and pant-leg area sum results between PAH patients and healthy controls. Figure 1a demonstrates volumetric segmentation and quantification of the pulmonary arterial tree using thresholding and centerline extraction. Figure 1b shows a close-up image of pant-leg measurement from bifurcation. In all eight PAH cases, dilation and expansion increased compared to healthy volunteers. Each measurement proved to be statistically significant with a

p-value  $\leq$  .05. Interestingly the LPA measurement, at the cuff of the pant-leg, showed the best discriminatory power in this analysis.

**CONCLUSION:** Use of the pant-leg (index) for pulmonary arterial volume resulted in an improved



ability to discriminate for the presence of PAH when compared with the current standard of pulmonary artery diameter.X

**REFERENCES:** 1. Badagliacca et al. 2012

**Figure 1:** A diameter (a) and distance from bifurcation (b) measurement on the right pulmonary artery of a PAH patient. The diameter and distance measurements are based on the best fit centerline