

UC Davis

Dermatology Online Journal

Title

Radiation-induced localized bullous pemphigoid in a patient with breast carcinoma

Permalink

<https://escholarship.org/uc/item/5vq3f1sx>

Journal

Dermatology Online Journal, 22(1)

Authors

Campa, Molly
Mansouri, Bobbak
Wilcox, Barry
[et al.](#)

Publication Date

2016

DOI

10.5070/D3221029800

Copyright Information

Copyright 2016 by the author(s). This work is made available under the terms of a Creative Commons Attribution-NonCommercial-NoDerivatives License, available at <https://creativecommons.org/licenses/by-nc-nd/4.0/>

Peer reviewed

Photo vignette

Radiation-induced localized bullous pemphigoid in a patient with breast carcinoma

Molly Campa MD¹, Bobbak Mansouri MD², Barry Wilcox MD³, John R Griffin MD¹

Dermatology Online Journal 22 (1): 15

¹Division of Dermatology, Baylor University Medical Center, Dallas, TX

²Department of Dermatology, Scott and White Medical Center, Temple, TX

³Texas Oncology, Baylor University Medical Center, Dallas, TX

Correspondence:

Dr. John Griffin MD
Texas Dermatology Associates
3900 Junius Street, Suite 145
Dallas, TX 75246
972-386-7546
johnrgriffin@gmail.com

Abstract

Bullous pemphigoid (BP) is a common pemphigoid disorder, which is localized in approximately 16-29% of cases. A small subset of localized BP cases is associated with prior radiation therapy, most commonly for breast carcinoma. We present a patient with an unusual presentation of localized BP after receiving partial accelerated breast irradiation (a type of brachytherapy that has a decreased amount of radiation to the skin as compared to the more common external beam radiation therapy).

Keywords: bullous pemphigoid, radiation therapy, brachytherapy, breast cancer

Introduction

Bullous pemphigoid (BP) is the most common of the pemphigoid disorders [1]. It typically presents as tense bullae, erosions, and erythema, with or without urticarial plaques involving multiple sites on the body. Localized BP is estimated to account for only 16% to 29% of BP cases [2]. Rarer still is radiation-induced localized BP. We report a patient who developed localized BP following completion of radiation therapy for breast carcinoma.

Case report

An 86-year-old woman presented to our dermatology clinic with a painful, pruritic, erythematous rash on her left breast with erosions and vesicles containing cloudy and clear fluid (Figure. 1a,b). Approximately five months prior, she completed accelerated partial irradiation (brachytherapy) to the left breast with a total radiation dose of 34 Gy for an estrogen and progesterone receptor positive, HER2 negative, T2N1 invasive ductal breast carcinoma. Additional management included breast conservation therapy (lumpectomy) with sentinel lymph node biopsy and tamoxifen therapy.

A punch biopsy of a vesicle showed a subepidermal blister with an infiltrate of lymphocytes and eosinophils (Figure. 2). Direct immunofluorescence studies were negative, but indirect immunofluorescence studies demonstrated basement membrane zone IgG antibodies (titer >1:40,960, monkey esophagus substrate; titer >1:20,480, human split skin substrate). IgA antibodies were negative. Serum BP180 and BP230 levels were elevated (IgG BP180=14 units, positive reference range ≥ 9

units and IgG BP230=120 units, positive reference range ≥ 9 units). This was consistent with bullous pemphigoid at a previously irradiated site. The patient was treated with topical clobetasol ointment 0.05% twice daily and her symptoms gradually improved (Figure. 1b,c). Six months later, the patient reported occasional development of isolated blisters, which were successfully treated with topical 0.05% clobetasol ointment twice daily as needed.

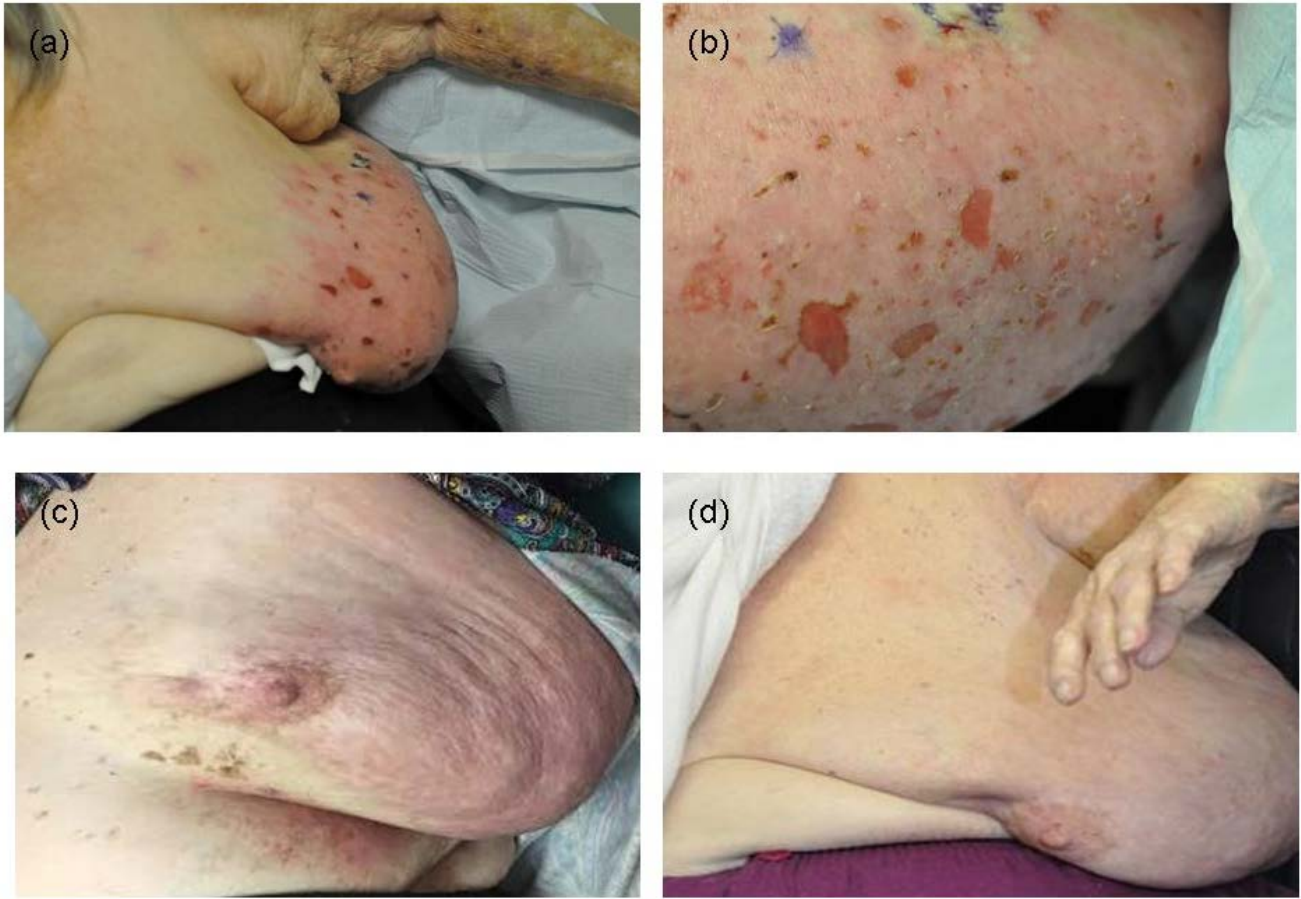


Figure 1. Radiation-induced bullous pemphigoid on the breast (a) and (b) pretreatment and (c) and (d) post-treatment with topical clobetasol.

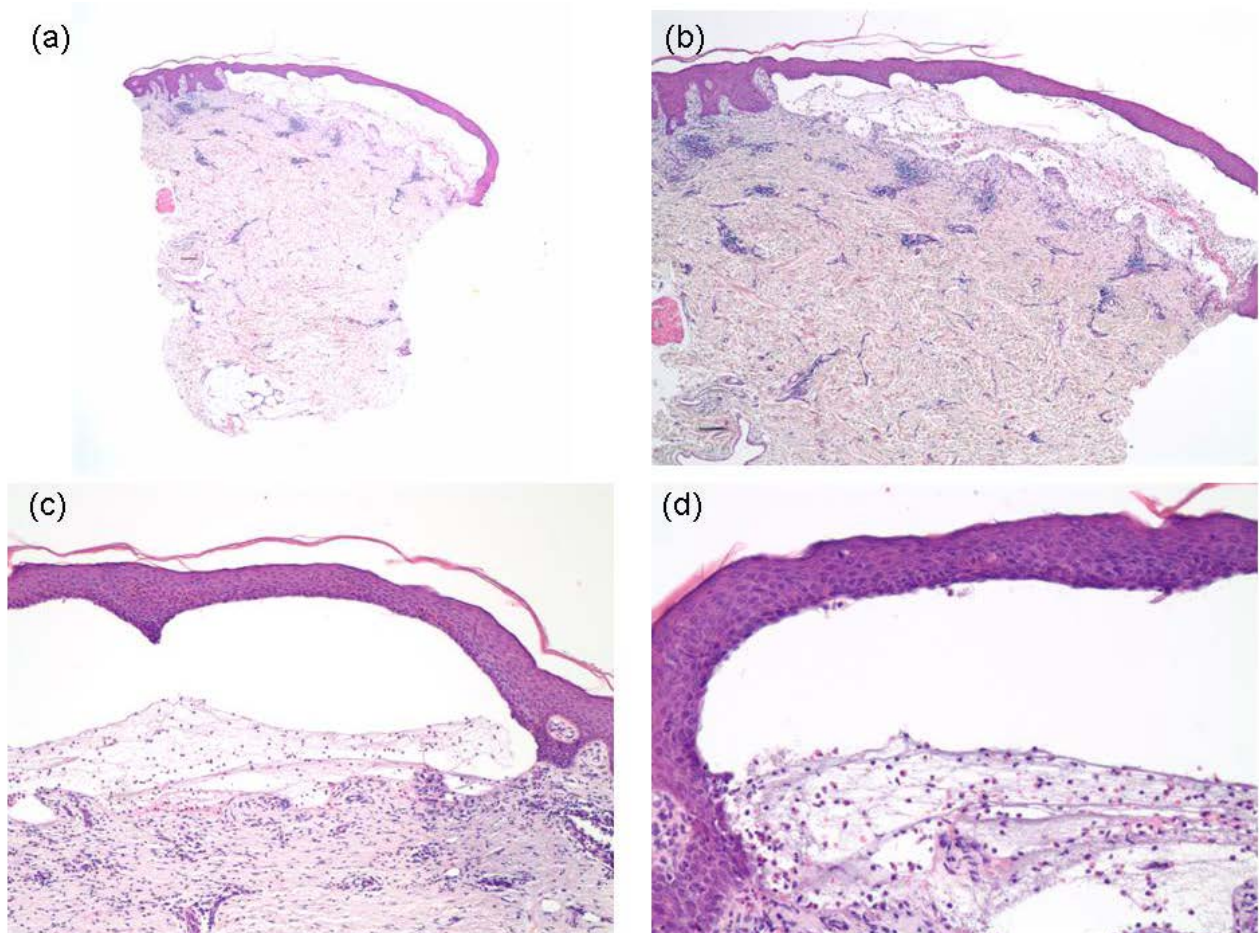


Figure 2. Punch biopsy of the breast with radiation-induced bullous pemphigoid with a subepidermal blister with a mixed population of inflammatory cells (a) Hematoxylin and eosin stain (20 x), (b) hematoxylin and eosin stain (40 x), (c) hematoxylin and eosin stain (100 x), and (d) hematoxylin stain (200 x).

Discussion

Bullous pemphigoid typically presents as tense bullae located on the lower abdomen, groin, thighs, and inner arms and is characterized by the presence of autoantibodies against two epidermal hemidesmosomal proteins, BP180 and BP230, at the dermal-epidermal junction (DEJ). Bullous pemphigoid typically spares mucosal surfaces with mild oral lesions developing in 10-20% of patients and rare mucosal involvement elsewhere [1].

Bullous pemphigoid has previously been reported as a rare side effect of radiation therapy with the majority of cases occurring in patients with breast carcinoma after the completion of radiotherapy [3,4]. Although the pathogenesis of radiation-induced BP remains unclear, several theories have been suggested including the unmasking of basement membrane antigens, changes in MMP-9 levels, and deposition of previously circulating antibodies onto the exposed basement membrane site at the DEJ [3,4].

Radiation-induced BP has primarily been reported as confined to the radiation field [3]. However, our patient's BP extended beyond the margins of the radiation field even though she received accelerated partial breast irradiation, a type of radiation treatment that involves internal radiation to the tumor cavity to limit the radiation exposure of the skin and uninvolved breast tissue [5]. Many of the previous studies do not indicate the modality of radiation therapy (external beam versus brachytherapy) and it is unclear whether this affects a patient's risk for radiation-induced BP.

Radiation-induced BP remains an uncommon but relatively benign side effect of radiotherapy. It generally responds to topical therapies and only occasionally requires the use of systemic therapies. At her six month follow-up appointment, our patient's BP was well-controlled, although she continued to develop occasional blisters, which were successfully treated with topical 0.05% clobetasol ointment.

Radiation-induced BP may be a side effect of irradiation, which is separate from radiation dermatitis and should not disrupt radiation therapy, because it is typically rapidly responsive to super-potent topical steroids. Albeit uncommon, radiation-induced BP should be considered in the differential diagnosis for a vesiculobullous eruption occurring status-post radiation, particularly in patients with breast carcinoma.

References

1. Schmidt E, Zillikens D. Pemphigoid diseases. *Lancet*. 2013;381(9863):320-32. doi: 10.1016/S0140-6736(12)61140-4. [PMID: 23237497]
2. Tran JT, Mutasim DF. Localized bullous pemphigoid: a commonly delayed diagnosis. *Int J Dermatol*. 2005;44(11):942-5. doi: 10.1111/j.1365-4632.2004.02288.x. [PMID: 16336529]
3. Mul VE, van Geest AJ, Pijls-Johannesma MC, Theys J, Verschueren TA, Jager JJ, et al. Radiation-induced bullous pemphigoid: a systematic review of an unusual radiation side effect. *Radiother Oncol*. 2007;82(1):5-9. doi: 10.1016/j.radonc.2006.11.014. [PMID: 17161479]
4. Nguyen T, Kwan JM, Ahmed AR. Relationship between radiation therapy and bullous pemphigoid. *Dermatology*. 2014;229(2):88-96. doi: 10.1159/000362208. PMID: 24861031]
5. Yashar CM, Scanderbeg D, Kuske R, Wallace A, Zannis V, Blair S, et al. Initial clinical experience with the Strut-Adjusted Volume Implant (SAVI) breast brachytherapy device for accelerated partial-breast irradiation (APBI): first 100 patients with more than 1 year of follow-up. *Int J Radiat Oncol Biol Phys*. 2011;80(3):765-70. doi: 10.1016/j.ijrobp.2010.02.018. [PMID: 20646847]