

UC Davis

UC Davis Previously Published Works

Title

Pericardial rupture leading to cardiac herniation after blunt trauma.

Permalink

<https://escholarship.org/uc/item/5vc62954>

Authors

Guenther, Timothy
Rinderknecht, Tanya
Phan, Ho
[et al.](#)

Publication Date

2020-06-01


DOI

10.1016/j.tcr.2020.100309

Peer reviewed

Contents lists available at [ScienceDirect](https://www.sciencedirect.com)

Trauma Case Reports

journal homepage: www.elsevier.com/locate/tcr

Case Report

Pericardial rupture leading to cardiac herniation after blunt trauma[☆]

Timothy Guenther^{a,b,*}, Tanya Rinderknecht^a, Ho Phan^a, Curtis Wozniak^b,
Victor Rodriquez^a

^a Department of Surgery, University of California Davis, 2315 Stockton Blvd, Sacramento, CA 95817, United States of America

^b Department of Cardiothoracic Surgery, David Grant USAF Medical Center, 101 Bodin Circle, Travis AFB, CA 95433, United States of America

ARTICLE INFO

Keywords:

Pericardial rupture
Cardiac herniation
Cardiac subluxation
Cardiac trauma

ABSTRACT

Pericardial rupture with cardiac herniation is a rare traumatic injury with an estimated incidence of 0.37% after blunt trauma. Most commonly occurring after high-speed impact, such as in motor vehicle or motorcycle collisions, pericardial rupture is associated with a high mortality rate. Radiologic diagnosis can be challenging; cross-sectional imaging findings can be suggestive of pericardial rupture but are often non-specific, and echocardiography windows are often obscured. Definitive diagnosis is generally made intra-operatively. Treatment involves reduction of the heart into normal anatomic position with repair of the pericardium, either primarily or with a patch. Fewer than 60 cases of pericardial rupture from blunt trauma have been reported in the literature. We describe a 65 year old poly-trauma patient who sustained pericardial rupture with subsequent cardiac herniation with cardiovascular collapse, and we discuss the considerations and complexities of his successful repair.

Introduction

Pericardial rupture with/without cardiac herniation is a rare sequela of blunt thoracic trauma [1]. With an estimated incidence of 0.37% in blunt trauma, this injury pattern is associated with a mortality rate between 20 and 60% [2]. While it is most commonly observed after motor vehicle or motorcycle collision, pericardial rupture has also been observed after skiing accidents, falls, and airplane crashes [3,4]. With fewer than 60 cases of pericardial rupture from blunt trauma reported in the literature, little is known about the presentation and clinical course of this rare injury [5]. We describe a 65 year old man who sustained pericardial rupture with cardiac herniation and cardiovascular collapse which was successfully surgically corrected.

Case

A 65 year old man was admitted to our institution after sustaining a high speed motor vehicle collision. The patient was breathing comfortably, had an initial blood pressure (BP) of 117/88, and was GCS 14 (E4V4M6). On secondary survey the patient had a tender left chest wall and tender abdomen without peritonitis. A chest x-ray showed an elevated left hemidiaphragm with gastric fundus projecting over the heart, suggestive of left diaphragmatic rupture (Fig. 1). Ten minutes after arrival, the patient became hypotensive

[☆] The work was not presented at any scientific meeting.

* Corresponding author at: 2335 Stockton Blvd, North Addition 5th floor, Sacramento, CA 95817, United States of America.

E-mail address: guenther.tim@gmail.com (T. Guenther).

<https://doi.org/10.1016/j.tcr.2020.100309>

Accepted 3 May 2020

2352-6440/ © 2020 The Author(s). Published by Elsevier Ltd. This is an open access article under the CC BY-NC-ND license (<http://creativecommons.org/licenses/by-nc-nd/4.0/>).

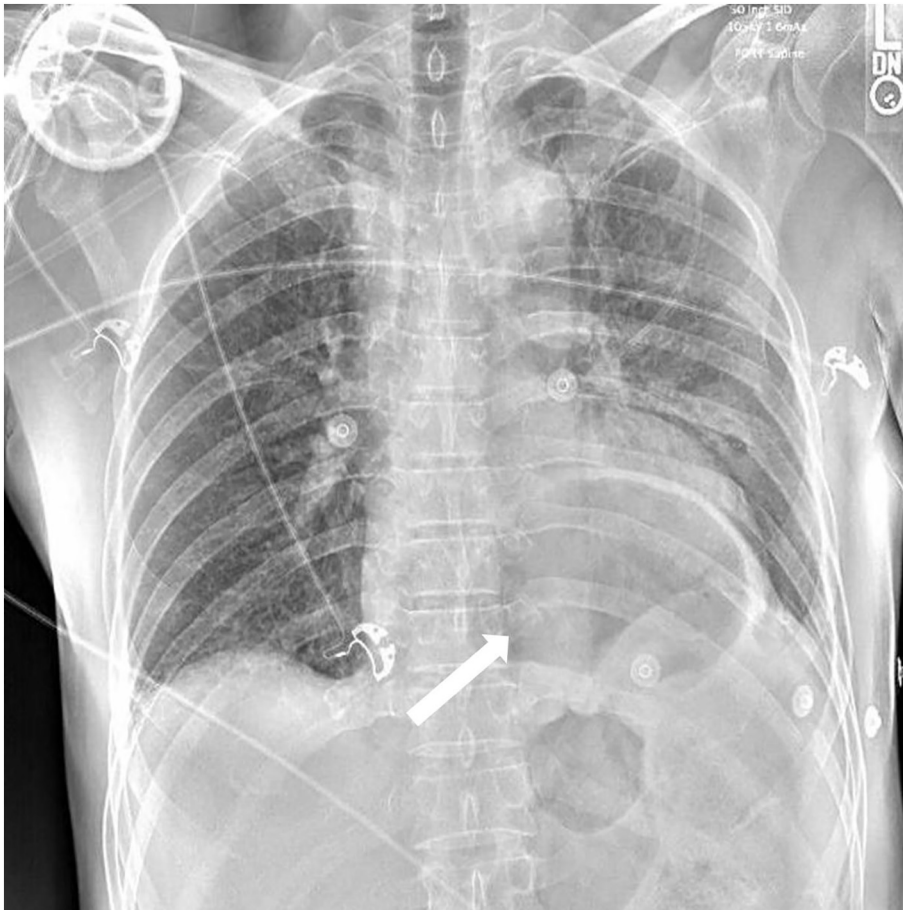


Fig. 1. Initial chest x-ray obtained in the trauma bay. The white arrow shows a large gastric bubble projecting over the heart, raising the suspicion for a diaphragmatic injury in the setting of blunt trauma.

(BP 60/50) and a focused assessment with sonography in trauma (FAST) exam showed free fluid in the abdomen. The patient was taken urgently to the operating room where splenectomy was performed for a grade 3 splenic laceration with associated hemo-peritoneum. Additionally, three separate left-sided diaphragmatic linear tears (10, 2, and < 1 cm in length) were identified and primarily repaired.

Post-operatively, the patient's blood pressure improved some but remained low despite aggressive resuscitation. Immediate post-operative CT imaging identified left-sided rib fractures (6th–12th) and multiple pelvic fractures. Additionally, pneumopericardium with possible compression effect on the anterior heart was seen (Fig. 2). Echocardiogram was unable to adequately image the heart secondary to pneumopericardium obscuring the imaging windows. Cardiac herniation with subsequent tension physiology was suspected given the imaging findings and persistent hypotension unresponsive to resuscitation. The patient was returned to the operating room for exploration of the mediastinum, approximately 12 h after presentation.

Upon induction the patient became profoundly hypotensive, and thus a median sternotomy was expediently performed. The anterior pericardium was entered, revealing biventricular herniation into the left chest through a defect in the left posterior pericardium. This caused stretching of the IVC/SVC and kinking of the left main pulmonary artery. The heart was reduced into normal anatomic position, resulting in normalization of the patient's BP. A large rupture of the left pericardium was observed, extending from the diaphragm to the pericardial reflection surrounding the left main pulmonary artery (Fig. 3). This was repaired using a running permanent monofilament suture. In order to obtain adequate exposure, a Medtronic® “urchin heart-positioner” was used to retract the apex of the heart anteriomedially, as manual rotation caused profound hypotension (Fig. 4). This exposure was associated with moderate hypotension, and while repair under cardiopulmonary bypass was considered, it was deferred to prevent systemic heparinization in light of the patient's other injuries. After closing the sternotomy, the patient became hypotensive, difficult to ventilate, and was noted to have a tense abdomen. Transesophageal echocardiogram was normal, chest tube output minimal, and thus abdominal compartment syndrome was suspected. The prior laparotomy incision was re-opened with improvement in the patient's hemodynamics.

The patient underwent serial abdominal washouts and his abdominal closure was delayed until post-operative day 8 secondary to edema. His pelvis was repaired and the rest of the patient's post-operative recovery was slow but unremarkable. He was discharged to

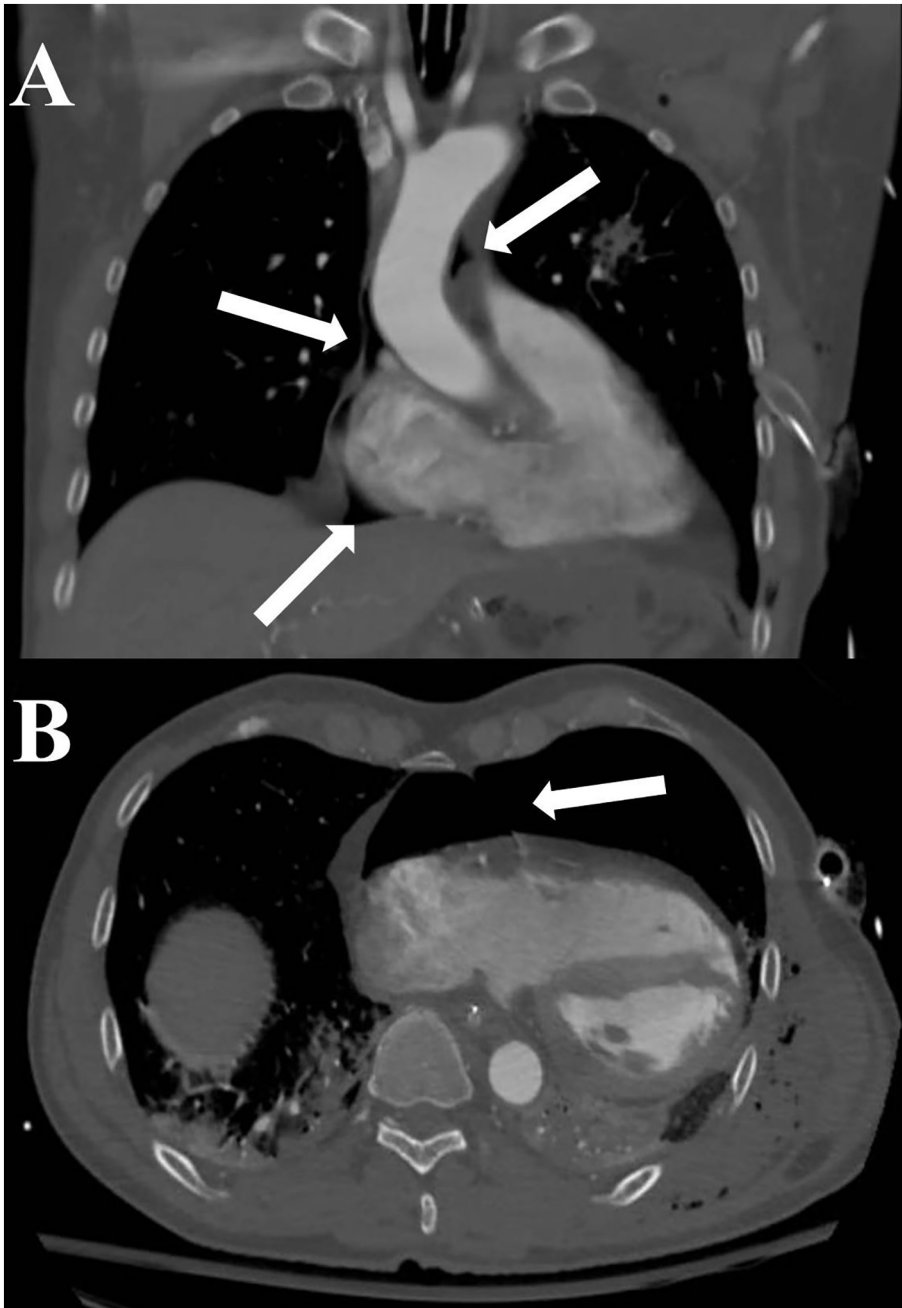


Fig. 2. Representative images from the patient's chest CT scan. (A) A coronal view with multiple arrows highlighting pneumopericardium within the pericardial recesses. (B) An axial view highlighting pneumopericardium with some compressive effects on the anterior aspect of the heart.

a rehab facility on post-operative day 26 and has since been discharged home.

Discussion

Pericardial rupture after blunt trauma is a very rare injury associated with rapid deceleration mechanisms [6]. While the base of the heart is more fixed given its attachments to the pulmonary vasculature and aorta, the apex is relatively mobile and can exert force on the lateral pericardium during episodes of blunt trauma. A literature review of 58 cases of pericardial rupture showed that almost 90% of cases involved some degree of cardiac herniation through a pericardial defect, as in our patient. However, it's certainly possible that there is a diagnostic bias towards cases with herniation, as these are much more likely to be clinically symptomatic. Given the potential hemodynamic sequelae of cardiac herniation, this injury pattern is important to consider and identify as soon as

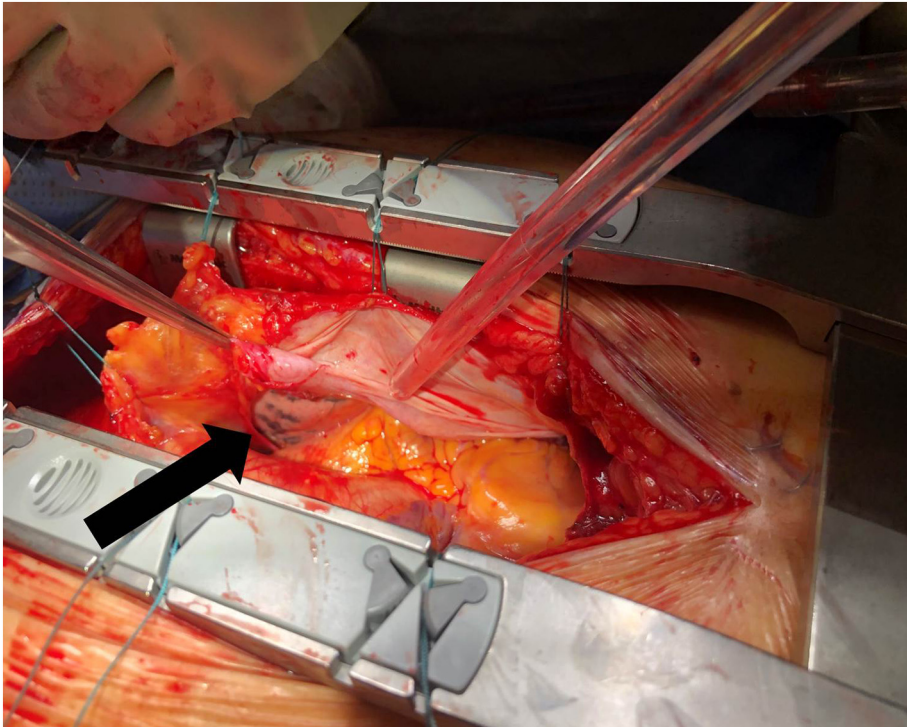


Fig. 3. Intraoperative photo demonstrating a large left sided pericardial defect, highlighted by the black arrow. The patient's head is oriented towards the left of the image. Lung tissue can be seen through the defect. The posterior pericardium is detached and is pulled anterior by the surgical instrument.

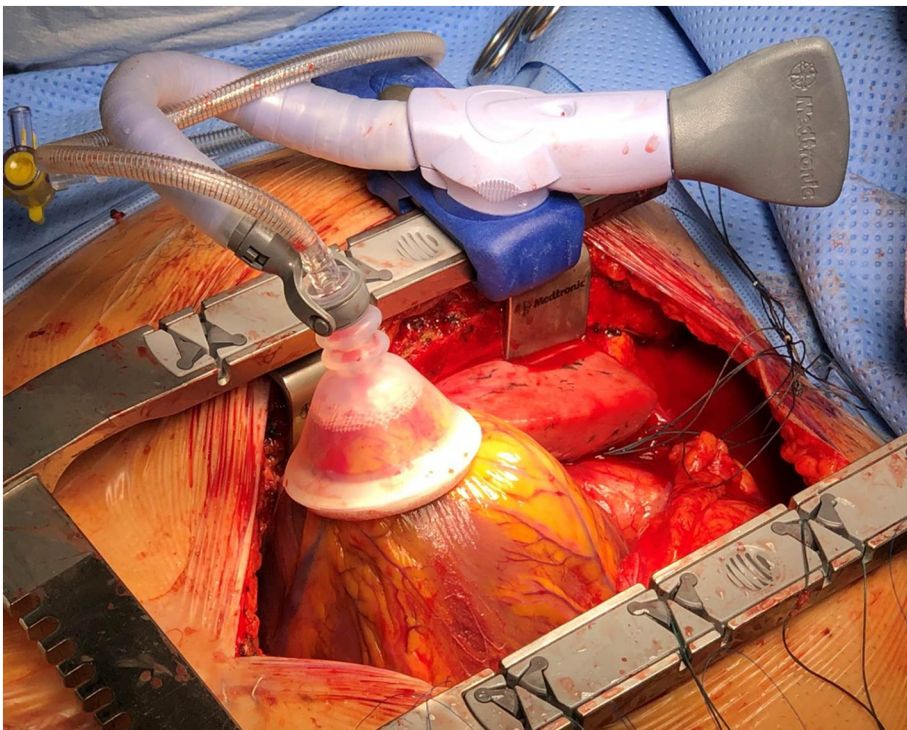


Fig. 4. Intraoperative photo demonstrating anterior/medial elevation of the cardiac apex using a Medtronic® "urchin heart-positioner" to allow exposure for pericardial repair. The patient's head is oriented towards the right of the image.

possible. Our patient's initial shock, for example, was attributed to bleeding from his splenic injury, and he was appropriately treated with an emergent laparotomy and splenectomy. However, he had persistent hypotension after bleeding was controlled and his volume status corrected, raising the possibility of another source of shock, which was confirmed to be cardiogenic. After restoration of the heart to the normal position, his hypotension improved markedly, implicating an anatomic/cardiogenic problem rather than ongoing hypovolemia. Not only does early identification of pericardial rupture and cardiac herniation allow for the appropriate treatment, but it also may prevent ongoing ineffective - and potentially harmful - therapy for other types of shock. In our case, the ongoing volume resuscitation that the patient received likely contributed to the development of abdominal compartment syndrome.

Like diaphragmatic rupture, pericardial rupture can be very difficult to diagnose using cross sectional imaging given the thin nature of the pericardium [7]. However, direct evidence such as protrusion of the heart into the thoracic cavity is near diagnostic of pericardial rupture. Indirect imaging findings such as pneumopericardium/hemopericardium can also be suggestive, but are certainly not definitive [8]. Treatment is aimed at reducing the heart into its normal anatomic position and closing the pericardial defect to prevent recurrent herniation [9]. Closure of the pericardium can be done primarily or with a patch for large defects [10]. An open unilateral thoracotomy has been the most commonly utilized surgical approach when repairing a pericardial rupture, though sternotomy, clamshell thoracotomy, and video assisted thoroscopic surgery (VATS) techniques have been described [5]. One aspect of repair through a sternotomy that became apparent in our case, given the posterior pericardial injury, was the need to retract the heart medially to obtain adequate exposure. The medial retraction caused inflow and outflow obstruction and subsequent hypotension, and the additional fluids required to support his hemodynamics during repair likely contributed to the development of compartment syndrome. Had a cardiac stabilizer not been available and digital retraction of the heart prohibitive, a deep midline pericardial retraction suture could have been placed to retract the heart anterior/medially. Alternatively, cardiopulmonary bypass without cardiac arrest was another viable option, and would have decompressed the heart and made the repair technically easier, but would have increased the patient's bleeding risk from other injuries. Posterolateral thoracotomy may minimize the amount of cardiac manipulation needed for repair, but can make reduction and repair of a potential cardiac injury more difficult and is not the ideal approach for an unstable patient.

In conclusion, pericardial rupture with cardiac herniation is a rare injury seen after blunt trauma. Clinicians should have a high index of suspicion in patients with rapid deceleration mechanisms who present with hypotension and either direct/indirect evidence of pericardial rupture on cross-sectional imaging – especially when hemodynamics don't improve as expected after resuscitation and treatment of other injuries.

Funding

No funds were used in the preparation of this manuscript.

Declaration of competing interest

The views expressed in this manuscript are solely of the authors and do not reflect the views of the United States Air Force or the Department of Defense.

Acknowledgements

None.

References

- [1] J. Lindenmann, et al., Traumatic pericardial rupture with cardiac herniation, *Ann. Thorac. Surg.* 89 (2010) 2028–2030, <https://doi.org/10.1016/j.athoracsur.2009.10.048>.
- [2] G. Fulda, A. Rodriguez, S.Z. Turney, R.A. Cowley, Blunt traumatic pericardial rupture. A ten-year experience 1979 to 1989, *J. Cardiovasc. Surg.* 31 (1990) 525–530.
- [3] N. Farhataziz, M.J. Landay, Pericardial rupture after blunt chest trauma, *J. Thorac. Imaging* 20 (2005) 50–52, <https://doi.org/10.1097/01.rti.0000139391.26138.dd>.
- [4] M. Fukuoka, et al., Traumatic pericardial rupture involved with complication by blunt chest trauma, *Jpn. J. Thorac. Cardiovasc. Surg.* 52 (2004) 423–425, <https://doi.org/10.1007/s11748-004-0036-9>.
- [5] F. Graef, et al., Traumatic cardiac dislocation-a case report and review of the literature including a new classification system, *J. Trauma Acute Care Surg.* 87 (2019) 944–953, <https://doi.org/10.1097/ta.0000000000002445>.
- [6] R. Gao, D. Jia, H. Zhao, Z. WeiWei, W.F. Yangming, A diaphragmatic hernia and pericardial rupture caused by blunt injury of the chest: a case review, *J. Trauma Nurs.* 25 (2018) 323–326, <https://doi.org/10.1097/jtn.0000000000000395>.
- [7] N. Nassiri, A. Yu, N. Statkus, M. Gosselin, Imaging of cardiac herniation in traumatic pericardial rupture, *J. Thorac. Imaging* 24 (2009) 69–72, <https://doi.org/10.1097/RTI.0b013e31818d12de>.
- [8] N. Verma, J.D. Robinson, M.L. Gunn, Pericardial rupture and cardiac herniation in blunt trauma, *Radiol. Case Rep.* 13 (2018) 573–575, <https://doi.org/10.1016/j.radcr.2018.02.013>.
- [9] C. Banfi, et al., Successful repair despite late diagnosis of traumatic pericardial rupture with cardiac herniation, *Int. J. Cardiol.* 177 (2014) e147–e149, <https://doi.org/10.1016/j.ijcard.2014.09.048>.
- [10] D.A. Motto, S. Kurapati, D.C. Atencio, M.A. Miller, K.R. Stahlfeld, Pericardial rupture with intermittent cardiac luxation, *Tex. Heart Inst. J.* 45 (2018) 115–116, <https://doi.org/10.14503/thij-16-5803>.